

Simulation of KTP Laser–Based Zenker Diverticulotomy with a Porcine Model and Laryngeal Dissection Station

Matthew R. Hoffman, MD, PhD¹, Heidi Kletzien, MS¹,
 Seth H. Dailey, MD¹, and J. Scott McMurray, MD¹

OTO Open

1–4

© The Authors 2017

Reprints and permission:

sagepub.com/journalsPermissions.nav

DOI: 10.1177/2473974X17736288

http://oto-open.org



Sponsorships or competing interests that may be relevant to content are disclosed at the end of this article.

Abstract

Zenker's diverticulum is a rare cause of progressive dysphagia that is treated surgically. Potassium titanyl phosphate (KTP) laser–based diverticulotomy is one effective treatment. Developing a simulation model is helpful for rare conditions. Pigs have a natural hypopharyngeal pouch similar to a diverticulum. We present a model for performing rigid endoscopic KTP laser diverticulotomy in a porcine model with a laryngeal dissection station. Eleven pigs were examined to confirm presence of the hypopharyngeal pouch. A specimen was mounted on the modified laryngeal dissection station, and a KTP laser–based diverticulotomy was performed. Novel aspects include use of the laryngeal dissection station and application of the model for simulating rigid endoscopic KTP laser diverticulotomy. This model allows trainees to practice equipment setup, positioning of the laryngoscope to isolate the cricopharyngeal bar, tissue handling, laser safety techniques, and use of the KTP laser through the laryngoscope under microscopic visualization.

Keywords

Zenker's diverticulum, KTP laser, cricopharyngeal myotomy, porcine model, surgical simulation

Received June 18, 2017; revised June 19, 2017; accepted September 20, 2017.

Zenker's diverticulum is a pulsion diverticulum in Killian's triangle,^{1–4} characterized by progressive symptoms including dysphagia with obstruction, regurgitation, cough, globus, and halitosis.³ This can lead to aspiration and pneumonia.⁵ Disease prevalence is 2 per 100,000,⁶ and treatment is surgical.

As patients are typically older,⁷ endoscopic approaches can be desirable, offering shorter operative time, reduced

hospital stay, and earlier oral intake.^{8–11} Recent reviews demonstrated a mortality of 0.2% to 0.4% with endoscopic approaches, compared with 0.6% to 0.9% with open procedures.^{12,13} Notably, endoscopic procedures are not feasible for patients with unfavorable anatomy, recurrent diverticulum, or small or large diverticulum.^{14–17} Furthermore, open procedures have a lower rate of symptom recurrence and need for revision procedures.¹⁸ When an endoscopic approach is feasible, options include stapler,¹⁹ carbon dioxide laser,²⁰ and potassium titanyl phosphate (KTP) laser.² The KTP laser has advantages, such as coagulation around the incision, which seals the wound edges, and a lower probability of postoperative leakage.¹

Given the rare prevalence, simulation training is desirable. There has been an emphasis on simulation from the American Residency Review Committee for Surgery,²¹ and surgeons with prior simulation training demonstrate greater skill and make fewer errors than do those without.²²

There are 2 models of endoscopic treatment for Zenker's diverticulum. The first uses a latex glove on a wooden frame to simulate stapler diverticulotomy.²³ Trainees can become familiar with the Weerda laryngoscope and stapler; however, this model does not allow for tissue handling and cannot be used with lasers. A second model simulates flexible endoscopic approaches on a porcine model.²⁴ The domestic pig has a natural hypopharyngeal pouch,^{24–26} making it an ideal animal model for Zenker's diverticulum. We used the porcine model to simulate rigid endoscopic treatment of Zenker's diverticulum using an adapted laryngeal dissection station²⁷ and KTP laser. Novel aspects

¹Division of Otolaryngology–Head and Neck Surgery, Department of Surgery, School of Medicine and Public Health, University of Wisconsin, Madison, Wisconsin, USA

Corresponding Author:

J. Scott McMurray, MD, Division of Otolaryngology–Head and Neck Surgery, Department of Surgery, School of Medicine and Public Health, University of Wisconsin, 600 Highland Ave, Box 7375 Clinical Science Center, Madison, WI 53792, USA.
 Email: mcmurray@surgery.wisc.edu



Creative Commons CC-BY-NC: This article is distributed under the terms of the Creative Commons Attribution 4.0 License (<http://www.creativecommons.org/licenses/by/4.0/>) which permits any use, reproduction and distribution of the work without

further permission provided the original work is attributed as specified on the SAGE and Open Access pages (<https://us.sagepub.com/en-us/nam/open-access-at-sage>).

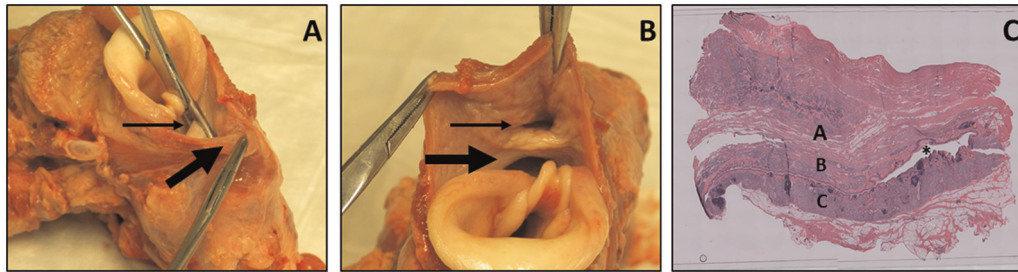


Figure 1. (A) Hemostat with tine in esophagus (left) and diverticulum (right); small arrow identifies bar. Second hemostat holds posterior pouch border (large arrow). (B) Esophagus (large arrow) and diverticulum (small arrow). (C) 4X hematoxylin and eosin–stained axial section of hypopharyngeal pouch (asterisk): A, anterior esophageal wall; B, common wall; C, posterior hypopharyngeal wall.

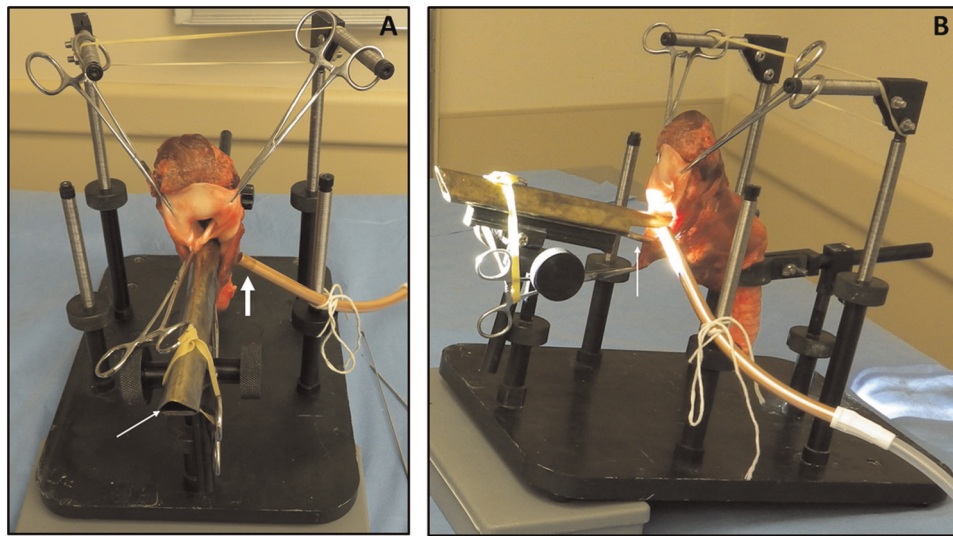


Figure 2. (A) Hemostats grasp epiglottis, interarytenoid notch, and posterior diverticulum. Laryngoscope opening (small arrow). Suction (large arrow) eliminates smoke. (B) Two lips of laryngoscope (arrow) expose cricopharyngeal bar: upper lip in esophagus, lower lip in pouch.

include use of the laryngeal dissection station and application of the model for simulating rigid endoscopic KTP laser diverticulotomy.

Methods

This study was exempt from animal protocol review. The larynx, pharynx, and cervical esophagus were excised from 11 pigs obtained from slaughterhouses. All had a hypopharyngeal pouch (**Figure 1**). The trachea was trimmed. The station is portable, easy to clean, and applicable for open and endoscopic laryngeal procedures, and it costs about \$800.²⁷

The laryngoscope has 2 ends: an end simulating the Zeitels glottiscope and a dual-lipped end used for balancing instruments. This is similar to the Hollinger-Benjamin laryngoscope used to expose a cricopharyngeal bar. For this simulation, the laryngoscope is turned 180° such that this end exposes the segment between the hypopharyngeal pouch and esophageal lumen. Hemostats next to the epiglottis provide anterolateral tension, and additional hemostats grasping the interarytenoid space and posterior pouch are suspended along

the laryngoscope to provide superior tension (**Figure 2**). Hemostats are secured with rubber bands. Setup takes approximately 3 minutes once the specimen is prepared. Laser safety precautions are instituted, including goggles, towels, statement on oxygen level, placement of pledgets in the esophagus, and orders for “laser on”/“laser off.”

An operating microscope is used. Continuous suction is provided next to the laryngoscope (**Figure 2A**). The KTP laser at 5 W continuously incises the cricopharyngeal bar in anterior-to-posterior fashion while a Bouchayer forceps provides countertraction (**Figure 3**). Outcomes for trainee performance include isolation of the cricopharyngeal bar, appropriate laser safety precautions, proper instrument handling, and division of the cricopharyngeal bar.

For hematoxylin and eosin staining, the hypopharyngeal pouch and cervical esophagus were embedded in optimum cutting compound, snap-frozen in 2-methylbutane cooled by liquid nitrogen, and stored at -80°C . The optimum cutting compound–embedded tissue was cut into 25- μm axial sections with a -12°C cryostat (Leica CM1850; Leica Biosystems, Wetzlar, Germany); sections were mounted and stained with

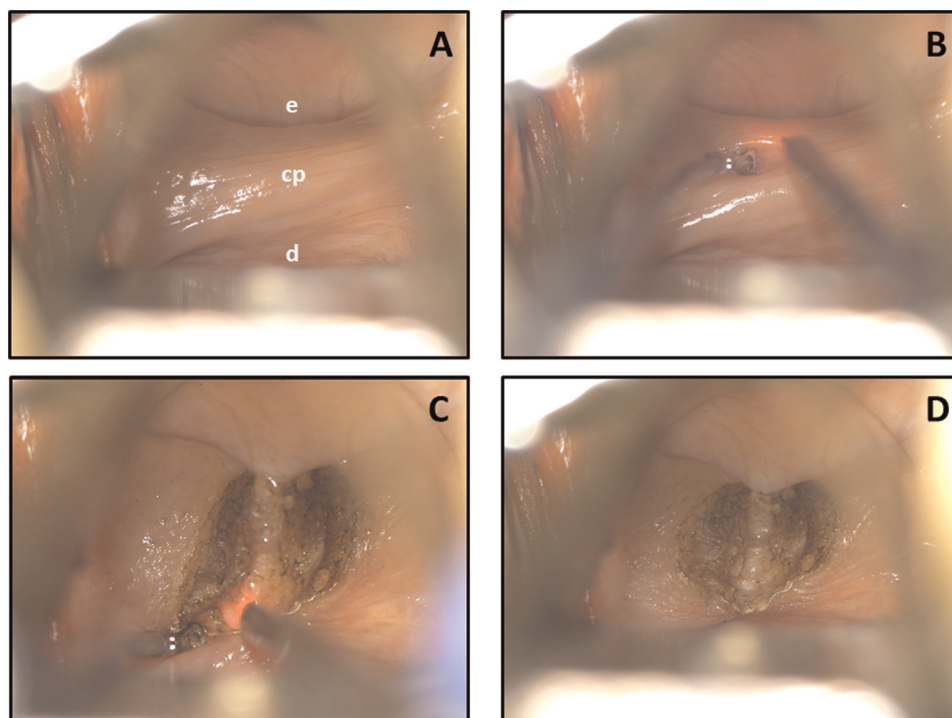


Figure 3. KTP laser diverticulotomy. (A) Exposing cricopharyngeal bar (cp), esophagus (e) anteriorly, and diverticulum (d) posteriorly. (B) Bouchayer forceps provides traction while laser handpiece is positioned. (C) Posterior bar is divided. (D) Partially divided cricopharyngeal bar.

standard hematoxylin-eosin protocol. Photographs were taken with 4× magnification and combined to generate 1 image with Olympus cellSens Imaging Software (**Figure 1C**).

Results

The hypopharyngeal pouch simulated Zenker's diverticulum (**Figure 1**); the laryngoscope exposed the cricopharyngeal bar (**Figure 2**); and the cricopharyngeal bar could be ablated with the KTP laser (**Figure 3**).

Discussion

Surgical simulation gives trainees exposure to uncommon procedures and is linked to improved patient outcomes.^{21,22} Zenker's diverticulum represents an ideal disorder for simulation: it is rare⁶; resident and attending cannot participate in the procedure simultaneously; and the porcine hypopharyngeal pouch closely approximates the pathology, providing an *ex vivo* model without need for animal sacrifice specific to the simulation.

This model is useful to help trainees with equipment setup, endoscope positioning around the cricopharyngeal bar, laser safety, tissue handling, simultaneous retraction and laser treatment, and use of the KTP laser, including application of laser energy, suctioning of laser plume, and tissue ablation. Furthermore, pig specimens are inexpensive, available from slaughterhouses, and similar size to human specimens. The laryngeal dissection station is easily adapted to simulating rigid endoscopic interventions. A key limitation of the model is its lack of an oral cavity and oropharynx to practice laryngoscope placement without incurring

dental injury. Study limitations include the lack of a formal performance evaluation and confirmation that the trainee's comfort level increased following the simulation; future studies will address these issues.

Recent literature on the KTP laser approach following the initial 10-patient series² in 1992 is limited, with an 18-patient series in 1998 and a case report in 2005.^{1,28} Potential benefits include decreased bleeding intraoperatively and decreased leak risk postoperatively. Furthermore, one can see the cricopharyngeal fibers as they are being divided to increase precision. With an available model, providers may become comfortable with the procedure and perform it more frequently. This model description is an initial step in that direction.

Author Contributions

Matthew R. Hoffman, study concept and design, drafting of manuscript, approval of final version of manuscript; **Heidi Kletzien**, histology, drafting of manuscript, approval of final version of manuscript; **Seth H. Dailey**, study concept and design, critical revision of manuscript for important intellectual content, approval of final version of manuscript; **J. Scott McMurray**, study concept and design, critical revision of manuscript for important intellectual content, approval of final version of manuscript.

Disclosures

Competing interests: None.

Sponsorships: None.

Funding source: This work was supported in part by the National Institutes of Health, National Institute on Aging (grant F31AG054315).

References

1. Hazarinka P, Pillai S, Balakrishnan R, Singh R, Hazarika M. Endoscopic KTP-532 laser assisted diverticulotomy for Zenker's diverticulum. *Indian J Otolaryngol Head Neck Surg.* 2005;57:71-74.
2. Kuhn FA, Bent JP. Zenker's diverticulotomy using the KTP/532 laser. *Laryngoscope.* 1992;102:946-950.
3. Dissard A, Gilain L, Pastourel R, Mom T, Saroul N. Functional results in endoscopic Zenker's diverticulum surgery [published online March 21, 2017]. *Eur Ann Otorhinolaryngol Head Neck Dis.* doi:10.1016/j.anorl.2017.02.009
4. Cook IJ, Gabb M, Panagopoulos V, et al. Pharyngeal (Zenker's) diverticulum is a disorder of upper esophageal sphincter opening. *Gastroenterol.* 1992;103:1229-1235.
5. Case DJ, Baron TH. Flexible endoscopic management of Zenker diverticulum: the Mayo Clinic experience. *Mayo Clin Proc.* 2010;85:719-722.
6. Scher RL, Puskas L. Zenker diverticulum. In: Flint PW, Haughey BH, Lund VL, et al, eds. *Cummings Otolaryngology.* 6th ed. Philadelphia, PA: WB Saunders; 2015:1025-1034.
7. Laing MR, Murthy P, Ah-See KW, Cockburn JS. Surgery for pharyngeal pouch: audit of management with short- and long-term follow-up. *J R Coll Surg Edinb.* 1995;40:315-318.
8. Johnson CM, Postma GN. Zenker diverticulum— which surgical approach is superior? *JAMA Otolaryngol Head Neck Surg.* 2016;142:401-403.
9. Chang CW, Burkey BB, Netterville JL, Courey MS, Garrett CG, Bayles SW. Carbon dioxide laser endoscopic diverticulotomy versus open diverticulectomy for Zenker's diverticulum. *Laryngoscope.* 2004;114:519-527.
10. Leibowitz JM, Fundakowski CE, Abouyared M, et al. Surgical techniques for Zenker's diverticulum: a comparative analysis. *Otolaryngol Head Neck Surg.* 2014;151:52-58.
11. Wirth D, Kerb B, Guenin MO, et al. Outcome and quality of life after open surgery versus endoscopic stapler-assisted esophagodiverticulostomy for Zenker's diverticulum. *Dis Esophagus.* 2006;19:294-298.
12. Verdonck J, Morton RP. Systematic review on treatment of Zenker's diverticulum. *Eur Arch Otorhinolaryngol.* 2015;272:3095-3107.
13. Yuan Y, Zhao YF, Hu Y, Chen LQ. Surgical treatment of Zenker's diverticulum. *Dig Surg.* 2013;30:207-218.
14. Courson AM, Landry AM, Lott DG, Hinni ML. Open staple diverticulectomy for a large recurrent Zenker's diverticulum: still a valid procedure. *Ann Otol Rhinol Laryngol.* 2013;122:729-733.
15. Bloom JD, Bleier BS, Mirza N, Chalian AA, Thaler ER. Factors predicting endoscopic exposure of Zenker's diverticulum. *Ann Otol Rhinol Laryngol.* 2010;119:736-741.
16. Rizzetto C, Zaninotto G, Costantini M, et al. Zenker's diverticula: feasibility of a tailored approach based on diverticulum size. *J Gastrointest Surg.* 2008;12:2057-2065.
17. Visosky AMB, Parke RB, Donovan DT. Endoscopic management of Zenker's diverticulum: factors predictive of success or failure. *Ann Otol Rhinol Laryngol.* 2008;117:531-537.
18. Shahawy S, Janisiewicz AM, Annino D, Shapiro J. A comparative study of outcomes for endoscopic diverticulotomy versus external diverticulectomy. *Otolaryngol Head Neck Surg.* 2014;151:646-651.
19. Chang CY, Payyapilli RJ, Scher RL. Endoscopic staple diverticulostomy for Zenker's diverticulum: review of literature and experience in 159 consecutive cases. *Laryngoscope.* 2003;113:957-965.
20. Van Overbeek JJ, Hoeksema PE, Edens ET. Microendoscopic surgery of the hypopharyngeal diverticulum using electrocoagulation or carbon dioxide laser. *Ann Otol Rhinol Laryngol.* 1984;93:34-36.
21. Kurashima Y, Hirano S. Systematic review of the implementation of simulation training in surgical residency curriculum. *Surg Today.* 2017;47:777-782.
22. Seymour NE, Gallagher AG, Roman SA, et al. Virtual reality training improves operating room performance: results of a randomized, double-blinded study. *Ann Surg.* 2002;236:458-464.
23. Richtsmeier WJ. Simulated Zenker's endoscopic staple-assisted esophagodiverticulostomy (ESED) surgery. *Laryngoscope.* 2002;112:1230-1234.
24. Seaman DL, de la Mora Levy J, Gostout CJ, Rajan E, Herman L, Knipschild M. An animal training model for endoscopic treatment of Zenker's diverticulum. *Gastrointest Endoscopy.* 2007;65:1050-1053.
25. Lewis FT, Thyng F. The regular occurrence of intestinal diverticula in embryos of the pig, rabbit, and man. *Am J Anat.* 1908;7:505-519.
26. Sisson S, Grossman JD, Getty R, eds. *Sisson and Grossman's the Anatomy of Domestic Animals.* Vol 2. 5th ed. Philadelphia, PA: WB Saunders; 1975.
27. Verma SP, Dailey SH, McMurray JS, Jiang JJ, McCulloch TM. Implementation of a program for surgical education in laryngology. *Laryngoscope.* 2010;120:2241-2246.
28. Halvorson DJ. The treatment of cricopharyngeal dysmotility with a transmucosal cricopharyngeal myotomy using the potassium-titanyl-phosphate (KTP) laser. *Endoscopy.* 1998;30:46-50.