

Efficacy and safety of therapeutic ERCP in patients with ectopic papilla of Vater

Junbo Hong, MD^a, Weiping Pan, BS^a, Wei Zuo, MD^b, Anjiang Wang, MD^a, Liang Zhu, MD^a, Xiaodong Zhou, MD^a, Xiaojiang Zhou, MM^a, Guohua Li, MD^a, Zhijian Liu, MM^a, Pi Liu, MD^a, Hao Zhen, MM^a, Yong Zhu, MM^a, Jiuhong Ma, MM^c, Jianhui Yuan, MM^{d,e}, Xu Shu, MD^a, Yin Zhu, MD^a, Nonghua Lu, MM^a, Youxiang Chen, MM^{a,*}

Abstract

It remains challenging for endoscopists to manage pancreaticobiliary diseases in patients with ectopic papilla of Vater by endoscopic retrograde cholangiopancreatography (ERCP). The present study sought to evaluate the efficacy and safety of ERCP for this issue.

Consecutive patients with ectopic papilla of Vater who underwent initial ERCP due to pancreaticobiliary diseases were retrospectively analyzed.

One hundred seven patients with ectopic papilla of Vater were included. The success rate of cannulation was 83.2%. Endoscopic sphincterotomy, endoscopic papillary balloon dilation, and mechanical lithotripsy were performed in 12 (11.2%), 25 (23.4%), and 1 (0.9%) patients, respectively. The technical success rate was 83.2%; of these, endoscopic nasobiliary drainage, endoscopic retrograde biliary drainage, endoscopic retrograde pancreatic drainage, and stone extraction was conducted in 61 (57.0%), 17 (15.9%), 5 (4.7%), and 45 (42.1%) patients, respectively. Bile duct stone size ≥ 1 cm, number ≥ 2 , and duodenum stenosis were risk factors for stone extraction inability. Adverse events occurred in 20 (18.7%) patients, including post-ERCP pancreatitis (3.7%), hyperamylasemia (12.1%), and infection of biliary tract (2.8%); all of the adverse events were mild and alleviated by conventional therapies.

ERCP is an appropriate choice for pancreaticobiliary diseases in patients with ectopic papilla of Vater due to its high efficacy and safety. Bile duct stone size ≥ 1 cm, number ≥ 2 , and duodenum stenosis increase difficulties for stone extraction.

Abbreviations: AOSC = acute obstructive suppurative cholangitis, ENBD = endoscopic nasobiliary drainage, EPBD = endoscopic papillary balloon dilation, ERBD = endoscopic retrograde biliary drainage, ERCP = endoscopic retrograde cholangiopancreatography, EST = endoscopic sphincterotomy.

Keywords: choledocholithiasis, ectopic papilla of Vater, ERCP

1. Introduction

The ampulla of Vater is commonly situated in the posteromedial wall of the second portion of the duodenum. Ectopic papilla of Vater does not frequently occur in the third and

fourth portions of the duodenum, the duodenal bulb, duodenal bulbar descending junction, or even in the stomach (gastric antrum and pylorus).^[1–4]

As mentioned previously, the papilla of Vater was abnormally located in 67.8% patients with congenital biliary dilatation, strongly suggesting that ectopic papilla of Vater might be responsible for congenital biliary dilatation.^[5] In addition, ectopic papilla of Vater has been considered a rare cause of choledocholithiasis and cholangitis.^[1,6–8] These results confirm that ectopic papilla of Vater contributes to pancreaticobiliary diseases. Furthermore, recurrent duodenal ulcer and duodenal stenosis always occur in patients with ectopic papilla of Vater,^[6,9] which may increase the difficulty of endoscopic operation.

Endoscopic retrograde cholangiopancreatography (ERCP) is putatively effective for managing pancreaticobiliary disorders.^[10,11] Post-ERCP pancreatitis (PEP), bleeding, perforation, cholangitis, and cholecystitis are not frequent complications for ERCP.^[12] Although the role of ERCP for pancreaticobiliary diseases in patients with ectopic papilla of Vater has been demonstrated predominantly in some case reports and clinical studies with small sample sizes,^[1,2,6] the efficacy and safety of ERCP has not been systematically evaluated in a relatively large population of these patients to date. This goal was achieved in the present study.

2. Methods

2.1. Study design and patients

We performed a retrospective study of all patients with ectopic papilla of Vater who underwent initial ERCP due to pancreaticobiliary

Editor: Maria Kapritsou.

JH and WP contributed equally to this work.

Funding: This work was supported by the National Natural Science Foundation of China (no. 81760106) and Doctoral Scientific Research Foundation of the First Affiliated Hospital of Nanchang University (no. 700648002).

The authors have no conflicts of interest to disclose.

^a Department of Gastroenterology, ^b Department of Respiratory Medicine, ^c Digestive Endoscopy Center, ^d Endoscopy Center, ^e Department of Anesthesiology, The First Affiliated Hospital of Nanchang University, Nanchang, Jiangxi, China.

* Correspondence: Youxiang Chen, Department of Gastroenterology, The First Affiliated Hospital of Nanchang University, Nanchang 330006, Jiangxi, China (e-mail: chenyouxiang102@163.com).

Copyright © 2020 the Author(s). Published by Wolters Kluwer Health, Inc. This is an open access article distributed under the terms of the Creative Commons Attribution-Non Commercial License 4.0 (CCBY-NC), where it is permissible to download, share, remix, transform, and buildup the work provided it is properly cited. The work cannot be used commercially without permission from the journal.

How to cite this article: Hong J, Pan W, Zuo W, Wang A, Zhu L, Zhou X, Zhou X, Li G, Liu Z, Liu P, Zhen H, Zhu Y, Ma J, Yuan J, Shu X, Zhu Y, Lu N, Chen Y. Efficacy and safety of therapeutic ERCP in patients with ectopic papilla of Vater. *Medicine* 2020;99:1(e18536).

Received: 15 June 2019 / Received in final form: 31 October 2019 / Accepted: 30 November 2019

<http://dx.doi.org/10.1097/MD.00000000000018536>

disorders from October 2009 to August 2018 at the First Affiliated Hospital of Nanchang University. Only the first session of ERCP was included when more than 1 procedure was performed in the patient. Medical records, clinical presentation, laboratory results, radiological studies, endoscopic and cholangiographic findings, and complications were reviewed for all patients included in the study. The exclusion criteria were as follows:

1. repeated ERCP;
2. contraindications to ERCP;
3. duodenal ulcer bleeding;
4. age less than 18 years;
5. pregnancy.

The Ethics Committee of the First Affiliated Hospital of Nanchang University approved the study. Written informed consent was obtained from all patients.

2.2. Perioperative preparation

The results of routine blood tests, coagulation tests, biochemical function (liver and renal function, electrolytes, serum myocardial enzymogram, and amylase), blood gas analysis, electrocardiograms, and echocardiography were obtained. Antimicrobial therapies were administered to patients with cholangitis and/or cholecystitis.^[13] Indications and contraindications for ERCP were evaluated by endoscopists and anesthesiologists before the procedure. Routine blood tests, liver function, and serum amylase were conducted 24 hours after the ERCP.

2.3. ERCP procedures

The ERCP procedures were performed by 6 experienced endoscopists (more than 1000 ERCP per person) in a large-sized (more than 2000 ERCP per year) Gastrointestinal Endoscopy Center of the First Affiliated Hospital of Nanchang University. Side-viewing endoscope and cap-assisted forward-viewing endoscope were used for patients as determined by endoscopists according to the location of the ectopic papilla of Vater. Wire-guided cannulation with sphincterotome (Dreamtome, Boston Scientific, Natick, MA) was performed in all patients; therapeutic manipulations (sphincterotomy, balloon dilation, stone extraction, nasobiliary drainage and stenting, etc) were performed when appropriate. A precut sphincterotomy or the double-wire technique was used as an alternative when cannulation failed.^[14] Prophylactic pancreatic stent placement was performed when repeated pancreatic cannulation occurred.^[15] Bile duct stone number and size were evaluated by the endoscopists performing the ERCP. The largest size of the stone was the index size when more than 1 stone existed. In addition, the number and size were defined as 1 and less than 1 cm, respectively, for a muddy stone.

2.4. Outcome evaluation

The primary outcome was technical success, which was defined as the completion of ERCP with successful deployment of a biliary stent, endoscopic retrograde pancreatic drainage, endoscopic nasobiliary drainage (ENBD), and/or stone extraction.^[16] The secondary outcome was the occurrence of complications, including PEP, hyperamylasemia, biliary tract infection, perforation, and bleeding.^[12] Patients were contacted at 30 days to evaluate late complications (delayed duodenal

papilla bleeding or pancreatitis), and this served as the final follow-up.

2.5. Definition and classification of ectopic papilla of Vater

Ectopic papilla of Vater was defined as follows:

1. no papillary structure was available in the posteromedial wall of the second portion of the duodenum;
2. an ectopic opening was detected in the bulb or duodenal bulbar descending junction in the third or fourth portion of the duodenum or in the stomach.^[4]

Ectopic papilla of Vater was classified into 4 types according to the location: I, duodenal bulb; II, duodenal bulbar descending junction; III, ascending part of duodenum; IV, pars horizontalis duodeni.

2.6. Definition of acute obstructive suppurative cholangitis

Acute obstructive suppurative cholangitis (AOSC) was characterized by obstruction, inflammation, and pyogenic infection of the biliary tract associated with the clinical pentad of fever, jaundice, pain, shock, and central nervous system depression.^[17]

2.7. Definition of complications

Hyperamylasemia was defined as an elevation in serum amylase levels >2-fold higher than the upper normal limit at 24 hours following ERCP.^[18] The definition of PEP included new or worsened abdominal pain, new or prolongation of hospitalization for at least 2 days, and serum amylase levels at least 3 times the upper limit of normal measured more than 24 hours after the procedure. The severity of PEP was determined as mild (pancreatitis after the procedure requiring admission or prolongation of planned admission to 2–3 days), moderate (pancreatitis after the procedure requiring hospitalization of 4–10 days), or severe (pancreatitis after the procedure requiring hospitalization for more than 10 days or hemorrhagic pancreatitis, phlegmon, pseudocyst, or intervention).^[9] The definition of biliary tract infection was defined as fever (>38°C), abnormal liver function test, and/or biliary dilation or stone.^[20]

2.8. Statistical analysis

The χ^2 -test or Fisher exact test (for categorical data) was used to estimate the significance of differences, which were described by the odds ratio and 95% confidence interval. Multivariate logistic regression analysis was used to determine the risk factors for stone extraction inability. All tests were two-sided, and a *P* value of less than .05 was considered statistically significant. All statistical analyses were performed with the Statistical Package for Social Science software suite (version 17.0; SPSS, Inc., Chicago, IL).

3. Results

3.1. Patient screening

A total of 138 cases of ERCP in 118 patients were screened. Of these, 11 cases were excluded due to repeated ERCP (*n*=7), severe cardiopulmonary disease (*n*=3), and duodenal ulcer bleeding (*n*=1). Finally, 90, 14, and 3 patients underwent 1, 2, or 3 ERCP procedures, respectively. Thus, a total of 107 initial patients were included. The prevalence of males and females was

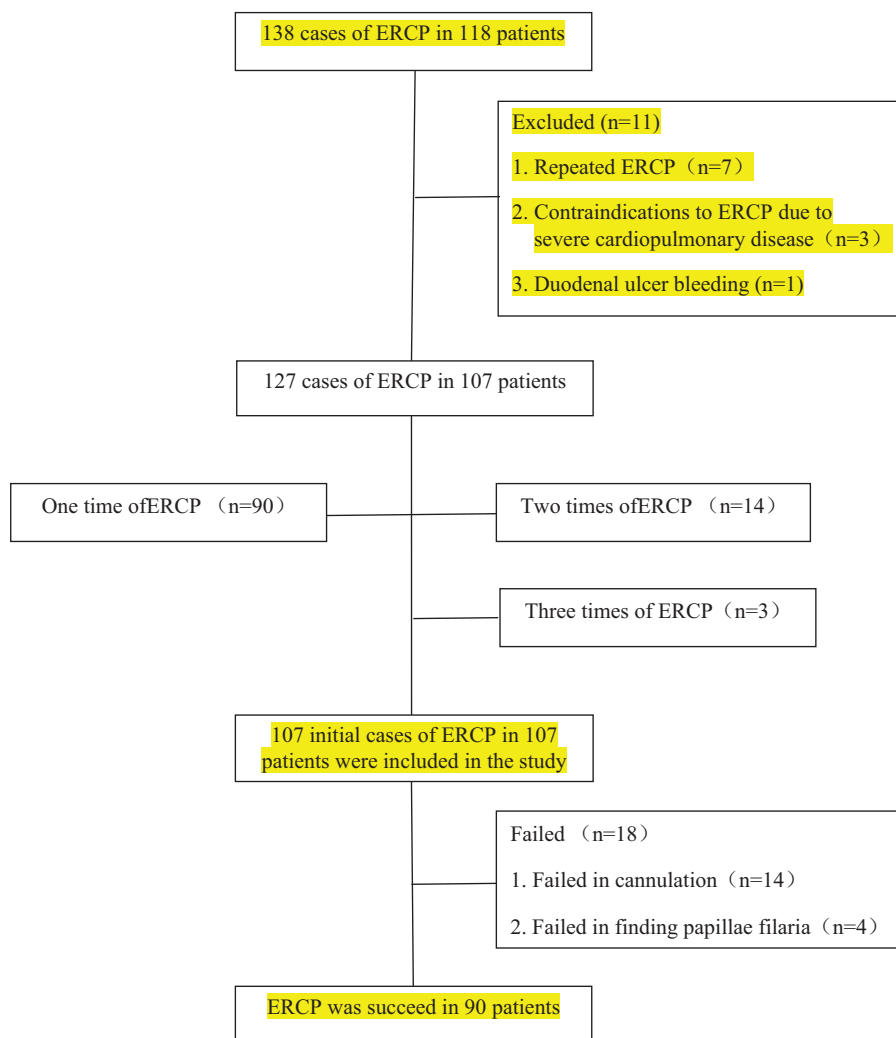


Figure 1. . Flow chart of the study. ERCP=endoscopic retrograde cholangiopancreatography.

78.5% and 21.5%, respectively, with ages of 55.8 ± 13.1 and 57.7 ± 12.6 years, respectively (Fig. 1).

3.2. Endoscopic findings

The ectopic papilla of Vater more frequently occurred in duodenal bulbar descending junction (72.0%) followed by duodenal bulb (15.9%), pars horizontalis duodeni (8.4%), and ascending part of duodenum (3.7%). Hook-shaped configurations occurred in majority of patients with the ectopic papilla of Vater located in duodenal bulbar descending junction and duodenal bulb (n=94). The prevalence of duodenal ulcer and stenosis was 10.3% and 55.1%, respectively (Table 1).

3.3. Indications of the ERCP

ERCP was performed in 85 (79.4%), 9 (8.4%), 11 (10.3%), 1 (0.9%), and 1 (0.9%) cases of bile duct stone, acute biliary pancreatitis caused by bile duct stone, bile duct stenosis due to ectopic papilla of Vater, pancreas divisum, and benign hilar bile duct stenosis, respectively (Table 1).

3.4. ERCP procedures

Cannulation was successfully performed in 89 patients with an overall rate of 83.2% (89/107), whereas the lowest rate was noted in duodenal bulbar descending junction (79.2%). Endoscopic sphincterotomy (EST) and endoscopic papillary balloon dilation (EPBD) were conducted in 12 (11.2%) and 25 (23.4%) patients, respectively. Of these, EST was less frequently used in the duodenal bulb and duodenal bulbar descending junction, whereas EPBD was more frequently performed in the duodenal bulbar descending junction (Table 2).

The technical success rate was 83.2%. Of these cases, ENBD, endoscopic retrograde biliary drainage (ERBD), endoscopic retrograde pancreatic drainage, and stone extraction were performed in 61 (57.0%), 17 (15.9%), 5 (4.7%), and 45 (42.1%) patients, respectively. Specifically, ERBD was less frequently conducted in the duodenal bulb and duodenal bulbar descending junction, whereas ENBD was the most commonly used procedures in these locations. The bile duct stone was extracted in 4 (23.5%), 33 (42.9%), 4 (100%), and 4 (44.4%) patients with ectopic papilla of Vater located in the duodenal bulb, duodenal bulbar descending junction, ascending part of

Table 1
Demographics, endoscopic findings, and indications (n, %).

Parameters	n = 107
Gender	
Male	84 (78.5%)
Female	23 (21.5%)
Age (yr)	
Male	55.8 ± 13.1
Female	57.7 ± 12.6
Endoscopic findings	
Locations of ectopic papilla of Vater	
I	17 (15.9%)
II	77 (72.0%)
III	4 (3.7%)
IV	9 (8.4%)
Duodenal ulcer	11 (10.3%)*
Duodenum stenosis	59 (55.1%)†
Hook-shaped	94 (87.9%)
Indications	
Bile duct stone	85 (79.4%)
Acute biliary pancreatitis caused by bile duct stone	9 (8.4%)
Bile duct stenosis due to ectopic papilla of Vater	11 (10.3%)
Pancreas divisum	1 (0.9%)
Benign hilar bile duct stenosis	1 (0.9%)

Locations: I, duodenal bulb; II, duodenal bulbar descending junction; III, ascending part of duodenum; IV, pars horizontalis duodeni.

* A total of 2 and 9 cases in locations I and II, respectively.

† A total of 6 and 53 cases in locations I and II, respectively.

duodenum, and pars horizontalis duodeni, respectively; and the overall stone clearance rate was 88.9% (40/45) (Table 2).

3.5. Risk factors for failure of stone extraction

Bile duct stone size ≥1 cm ($P=.003$), number ≥2 ($P=.047$), and duodenum stenosis ($P=.046$) were risk factors for stone extraction inability. Duodenal ulcer, location in the duodenal bulb and duodenal bulbar descending junction, and AOSC increased the risk of failure of stone extraction but not significantly (Table 3).

Table 2
ERCP procedures and complications (n, %).

	Locations			
	I (n=17)	II (n=77)	III (n=4)	IV (n=9)
Cannulation (n=89, 83.2%)	16 (94.1)	61 (79.2)	4 (100)	8 (88.9)
EST (n=12, 11.2%)	0	2 (2.6)	3 (75)	7 (77.8)
EPBD (n=25, 23.4%)	1 (5.9)	21 (27.3)	2 (50)	1 (11.1)
ML	0	1 (1.3)	0	0
Technical success rate (89, 83.2%)				
ENBD (n=61, 57.0%)	10 (58.8)	46 (58.7)	1 (25)	4 (44.4)
ERBD (n=17, 15.9%)	3 (17.6)	9 (11.7)	2 (50)	3 (33.3)
ERPD (n=5, 4.7%)	0	2 (2.6)	0	3 (33.3)
Stone extraction (n=45, 42.1%)*,†	4 (23.5)	33 (42.9)	4 (100)	4 (44.4)
Complications (n=20, 18.7%)				
PEP (n=4, 3.7%)	0	3 (3.9)	1 (25)	0
Hyperamylasemia (n=13, 12.1%)	3 (17.6)	8 (10.4)	0	2 (22.2)
Biliary tract infection (n=3, 2.8%)	0	2 (2.6)	1 (25)	0
Procedure time	18.1 ± 14.7 min (2–56 min)			

ENBD=endoscopic nasobiliary drainage, EPBD=endoscopic papillary balloon dilation, ERBD=endoscopic retrograde biliary drainage, ERCP=endoscopic retrograde cholangiopancreatography, ERPD=endoscopic retrograde pancreatic drainage, EST=endoscopic sphincterotomy, ML=mechanical lithotriptors, PEP=post-ERCP pancreatitis.

* Stone extraction was conducted in 94 cases (85 and 9 cases of bile duct stones and acute biliary pancreatitis caused by bile duct stone, respectively).

† Bile duct stone was clearly extracted in 40 patients (88.9%).

3.6. Adverse events

The prevalence of adverse events was 18.7% (20/107), including PEP (3.7%), hyperamylasemia (12.1%), and infection of biliary tract (2.8%). Hemorrhage of ectopic papilla and gastrointestinal perforation were not observed (Table 2). All of the adverse events were mild and alleviated by conventional therapies.

3.7. Other treatments

As a result of failure in cannulation and stone extraction, a total of 23 (21.5%) and 8 (7.5%) patients were referred to surgery and percutaneous transhepatic biliary drainage, respectively.

4. Discussion

The present study systematically evaluated the efficacy and safety of the initial ERCP in patients with ectopic papilla of Vater, demonstrating a technical success rate of 83.2%. Stone extraction was conducted in 42.1% patients, bile duct stone size ≥1 cm, number ≥2, and duodenum stenosis were risk factors for stone extraction inability. Adverse events occurred in 18.7% patients, including PEP (3.7%), hyperamylasemia (12.1%), and infection of biliary tract (2.8%). All of the adverse events were mild and alleviated by conventional therapies.

Ectopic papilla of Vater is a rare entity that occurs more frequently in elderly males.^[1,9,21] However, a similar rate of gender and age was certified in another study with a small size (n=11).^[4] These inconsistent results need to be clarified in a relatively large study. Our study (n=107) presented a predominance of males (78.5%) but no difference in age between males and females.

Ectopic opening of the common bile duct has been reported mainly in the third and fourth parts of the duodenum followed by the duodenal bulb^[1,3] and should be considered especially in elderly male patients with duodenal deformity/stenosis who undergo ERCP.^[22] Indeed, it is not an uncommon etiology of duodenal deformity/stenosis in numerous studies.^[3,8,21] In addition, refractory and complicated duodenal ulcers may be caused by ectopic papilla of Vater in the duodenal bulb.^[1,6,21]

Table 3
Influencing factors for stone extraction in 78 cases^{*}

	Stone extraction		Univariate analysis		Multivariate analysis	
	Yes (n=45)	No (n=33)	95% CI	P	95% CI	P
Stone Size						
<1.0 cm	30 (66.7%) [†]	9 (27.3%) [‡]	5.333 (1.991–14.288)	.001	5.489 (1.793–16.801)	.003
≥1.0 cm	15 (33.3%)	24 (72.7%)				
Stone number						
n=1	34 (75.6%) [†]	18 (54.5%) [‡]	2.576 (0.981–6.763)	.052	3.545 (1.020–12.322)	.047
n ≥ 2	11 (24.4%)	15 (45.5%)				
Duodenal ulcer						
No	43 (95.6%)	28 (84.8%)	3.839 (0.696–21.174)	.127	1.347 (0.152–11.894)	.789
Yes	2 (4.4%)	5 (15.2%)				
Duodenal stenosis						
No	28 (62.2%)	13 (39.4%)	2.534 (1.007–6.373)	.046	3.767 (1.022–13.886)	.046
Yes	17 (37.8%)	20 (60.6%)				
Location						
III+IV	8 (17.8%)	2 (6.1%)	3.351 (0.662–16.957)	.177	2.127 (0.321–14.088)	.434
I+II	37 (82.2%)	31 (93.9%)				
AOSC						
No	43 (95.6%)	27 (81.8%)	4.778 (0.898–25.408)	.065	5.311 (0.771–36.601)	.09
Yes	2 (4.4%)	6 (18.2%)				

AOSC=acute obstructive suppurative cholangitis, CI=confidence interval.

^{*} A total of 70 and 8 cases of bile duct stones and acute biliary pancreatitis caused by bile duct stone, respectively. Contains muddy stones.

[†] n=11.

[‡] n=3.

Our study indicated that the majority of ectopic papilla of Vater cases are located in the duodenal bulb (15.9%) and duodenal bulbular descending junction (72.0%) and accompanied by duodenal ulcer (10.3%) and stenosis (55.1%).

Ectopic papilla of Vater in the duodenal bulb may be associated with some pancreaticobiliary disorders, such as choledocholithiasis, acute cholangitis, and acute pancreatitis.^[3,4,8,22] Furthermore, 2 small studies (n=18 and n=11) reveal that the prevalence of bile duct stone, cholangitis, and acute pancreatitis is 56%, 39%, and 18.2%, respectively, mainly due to the hook-shaped configuration of the distal common bile duct.^[11,9] The present study showed that the prevalence of bile duct stone and acute pancreatitis was 79.4% and 8.4%, respectively. In addition, we identified a single distal bile duct stenosis rate of 10.3% by ERCP possibly due to the indications of acute cholangitis and bile duct stones, which may be spontaneously passed from the common bile duct before the ERCP.

Hook-shaped configuration has been considered the main cholangiographic view when the ectopic papilla of Vater located in the stomach and duodenal bulb, and its prevalence varies greatly from 50% to 100% in different studies.^[1,4,9,21] The present study indicated that hook-shaped configuration existed in all of the ectopic papilla of Vater located in the duodenal bulb and duodenal bulbular descending junction. The reason for these inconsistent results has not been identified, one of the far-fetched interpretations is that the configuration of common bile duct recorded on fluoroscopic film may alter dynamically according to the patients position.^[21]

The cannulation rate for the patients with ectopic papilla of Vater has not been evaluated. As mentioned previously, although the pancreatic and biliary duct were open separately in all of the 74 cases,^[9] its ectopic opening is obscure in the majority of cases. Thus, the difficulty of cannulation may still be increased during the ERCP. In the present study, with the exception of 18 patients who failed in cannulation and the identification of ectopic opening, cannulation was successfully performed in 83.2%

patients. Of these, the cannulation rate was the lowest in ectopic openings located in the duodenal bulbular descending junction possibly due to duodenal stenosis.

EST and EPBD are standard procedures for bile duct stones extraction, various endoscopic diagnoses, and other therapies for the bile duct.^[23–25] EPBD can be safely performed in patients with ectopic papilla of Vater, whereas EST may not be recommended in these patients due to potential risks of bleeding and perforation.^[3,9] Similarly, the present study demonstrated that EST was rarely conducted in ectopic openings located in the bulb and duodenal bulbular descending junction, whereas EPBD represents an efficient alternative for these patients.

Little is known on the therapeutic efficacy of ERCP in patients with ectopic papilla of Vater. Only 1 study has revealed that after an average of 1.7 ERCP procedures, endoscopic treatments were achieved in 81.1% (60/74) patients with opening anomalies.^[9] Our study systematically illustrated that the initial ERCP procedure was completed in 89 patients with a technical success rate of 83.2%.

ENBD and ERBD are the mainstay therapeutic options for releasing biliary obstruction, and ERBD with plastic stent was performed as a transitional alternative for retained common bile duct stones.^[26] However, the role of ENBD and ERBD has not been well evaluated in patients with ectopic papilla of Vater. Limited studies with small samples have utilized the 2 strategies in these patients, especially before the surgery as the bile duct stones were not able to be extracted mainly due to hook-shaped configuration.^[1,4,9] The present study demonstrated rates of 57.0% and 15.9% for ENBD and ERBD, respectively, partly due to low rate (42.1%) of stone extraction.

ERCP is the primary method for bile duct stone extraction by EST and/or EPBD.^[15,25,27] A recent meta-analysis confirmed superior stone removal rates both in the EST (93.5%) and EST plus EPBD groups (97.4%) for large stones (diameter of the largest stone ≥10 mm) or multiple stones.^[28] However, nothing is known about the stone removal rate in specific patients with

ectopic papilla of Vater. Our study identified a relative low rate (42.1%) of stone extraction, ENBD, and ERBD was more frequently conducted to release obstruction of biliary tract. A total of 23 (21.5%) patients were referred to surgery.

The difficulty of common bile duct stone clearance increased in patients with a large stone (≥ 15 mm), more acute distal common bile duct angulation ($\leq 135^\circ$), and short distal common bile duct arm (≤ 36 mm).^[29] However, the reasons for low stone extraction rates in patients with ectopic papilla of Vater have not been verified. As mentioned previously, a typical hook-shaped appearance together with a short distal common bile duct exists in patients with an abnormal papilla of Vater location.^[1,9] Furthermore, gastroscopy-based ERCP is more frequently performed due to a high rate of duodenal stenosis in these patients (55.1% in this study) with ectopic papilla of Vater located in the bulb and duodenal bulbar descending junction^[4,9]; thus, it is difficult to maintain a straight line among distal of gastroscopy, reticular basket, and distal common bile duct, which potentially increases challenges to stone extraction for endoscopists. In addition, EST and EPBD were less frequently conducted in this study. Based on these reasons, this study achieved a rate of 42.1% for stone extraction and clarified that bile duct stone size ≥ 1 cm, number ≥ 2 , and duodenum stenosis were risk factors for stone extraction inability.

Single-stage endoscopic stone extraction may be effectively and safely performed in patients with mild-to-moderate and even severe acute cholangitis associated with choledocholithiasis.^[30–32] However, adverse events may be declined in patients with acute cholangitis undergoing stone extraction by delayed endoscopic papillary large balloon dilation after EST compared to immediate concurrent EST and endoscopic papillary large balloon dilation.^[33] The present study also indicated a nonsignificant lower rate of stone extraction in AOSC patients with ectopic papilla of Vater to reduce the potential complications.

The most common complications for ERCP were PEP (1.6%–15.7%), hemorrhage (0.3%–2%), cholangitis (less than 1%), and gastrointestinal perforation (0.1%–0.6%).^[12] However, to the best of our knowledge, the complications of therapeutic ERCP in patients with ectopic papilla of Vater have not been evaluated. The overall rate of complication was 18.7%, including PEP (3.7%), biliary tract infection (2.8%), and hyperamylasemia (12.1%). All of these complications were mild and were alleviated by conventional therapies. In addition, hemorrhage and perforation did not occur possibly due to a low rate of EST and EPBD. Altogether, therapeutic ERCP is safe for the patients with ectopic papilla of Vater.

Certain limitations are present in this study. The efficacy and safety was evaluated in patients with ectopic papilla of Vater in this retrospective observational study, which were not compared to general populations. In addition, repeated cases were excluded as the ERCP may be more easily performed in these patients, which may not reflect the general clinical outcome.

In summary, ERCP is effective and safe to manage pancreaticobiliary diseases in patients with ectopic papilla of Vater. Bile duct stone size ≥ 1 cm, number ≥ 2 , and duodenum stenosis significantly increase the difficulty for stone extraction. Prospective studies are needed to verify these results.

Acknowledgments

We are sincerely grateful to the medical staff in our endoscopy unit for their collaboration on this work. The authors also

acknowledge Wiley Editing Services for assisting in the preparation of the manuscript.

Author contributions

Conceptualization: Junbo Hong, Wei Zuo, Youxiang Chen.

Data curation: Junbo Hong, Wei Zuo, Anjiang Wang.

Formal analysis: Junbo Hong, Anjiang Wang.

Funding acquisition: Junbo Hong.

Investigation: Liang Zhu, Xiaodong Zhou, Xiaojiang Zhou, Guohua Li, Zhijian Liu, Pi Liu, Hao Zhen, Yong Zhu, Jiahong Ma, Jianhui Yuan, Xu Shu, Yin Zhu, Nonghua Lu.

Methodology: Junbo Hong, Anjiang Wang, Youxiang Chen.

Project administration: Junbo Hong, Nonghua Lu, Youxiang Chen.

Supervision: Youxiang Chen.

Writing – original draft: Junbo Hong.

Writing – review & editing: Anjiang Wang, Youxiang Chen.

References

- Lee SS, Kim MH, Lee SK, et al. Ectopic opening of the common bile duct in the duodenal bulb: clinical implications. *Gastrointest Endosc* 2003;57:679–82.
- Guerra I, Rábago LR, Bermejo F, et al. Ectopic papilla of Vater in the pylorus. *World J Gastroenterol* 2009;15:5221–3.
- Saritas U, Senol A, Ustundag Y. The clinical presentations of ectopic biliary drainage into duodenal bulb and stomach with a thorough review of the current literature. *BMC Gastroenterol* 2010;10:2.
- Sezgin O, Altıntaş E, Uçbilek E. Ectopic opening of the common bile duct into various sites of the upper digestive tract: a case series. *Gastrointest Endosc* 2010;72:198–203.
- Li L, Yamataka A, Wang YX, et al. Anomalous pancreatic duct anatomy, ectopic distal location of the papilla of Vater and congenital biliary dilatation: a new developmental triad? *Pediatr Surg Int* 2003;19:180–5.
- Song MH, Jun DW, Kim SH, et al. Recurrent duodenal ulcer and cholangitis associated with ectopic opening of bile duct in the duodenal bulb. *Gastrointest Endosc* 2007;65:324–5.
- Ersoz G, Akay S, Oztemiz O, et al. Patients with bulbar papilla and choledocholithiasis and their endoscopic management. *Hepatogastroenterology* 2009;56:29–33.
- Taş A, Kara B, Ölmez S, et al. Retrospective analysis of cases with an ectopic opening of the common bile duct into duodenal bulb. *Adv Clin Exp* 2018;27:1361–4.
- Parlak E, Dişibeyaz S, Cengiz C, et al. Ectopic opening of the common bile duct and duodenal stenosis: an overlooked association. *BMC Gastroenterol* 2010;4:142.
- Adler DG, Baron TH, Davila RE, et al. Standards of Practice Committee of American Society for Gastrointestinal Endoscopy/ASGE guideline: the role of ERCP in diseases of the biliary tract and the pancreas. *Gastrointest Endosc* 2005;62:1–8.
- Fogel EL, Sherman S. ERCP for gallstone pancreatitis. *N Engl J Med* 2014;370:150–7.
- Anderson MA, Fisher L, Jain R, et al. ASGE Standards of Practice Committee/Complications of ERCP. *Gastrointest Endosc* 2012;75:467–73.
- Gomi H, Solomkin JS, Takada T, et al. Tokyo Guideline Revision Committee. TG13 antimicrobial therapy for acute cholangitis and cholecystitis. *J Hepatobiliary Pancreat Sci* 2013;20:60–70.
- Luo H, Zhao L, Leung J, et al. Routine pre-procedural rectal indometacin versus selective post-procedural rectal indometacin to prevent pancreatitis in patients undergoing endoscopic retrograde cholangiopancreatography: a multicentre, single-blinded, randomised controlled trial. *Lancet* 2016;387:2293–301.
- Williams E, Beckingham I, El Sayed G, et al. Updated guideline on the management of common bile duct stones (CBDS). *Gut* 2017;66:765–82.
- Staub J, Siddiqui A, Taylor LJ, et al. ERCP performed through previously placed duodenal stents: a multicenter retrospective study of outcomes and adverse events. *Gastrointest Endosc* 2018;87:1499–504.
- Chock E, Wolfe BM, Matolo NM. Acute suppurative cholangitis. *Surg Clin North Am* 1981;61:885–92.

- [18] Wang G, Xiao G, Xu L, et al. Effect of somatostatin on prevention of post-endoscopic retrograde cholangiopancreatography pancreatitis and hyperamylasemia: a systematic review and meta-analysis. *Pancreatology* 2018;18:370–8.
- [19] Cotton PB, Lehman G, Vennes J, et al. Endoscopic sphincterotomy complications and their management: an attempt at consensus. *Gastrointest Endosc* 1991;37:383–93.
- [20] Kiriya S, Kozaka K, Takada T, et al. Tokyo Guidelines 2018: diagnostic criteria and severity grading of acute cholangitis (with videos). *J Hepatobiliary Pancreat Sci* 2018;25:17–30.
- [21] Peng YC, Chow WK. Ectopic papilla of Vater in duodenum bulb: a hospital-based study. *Medicine (Baltimore)* 2019;98:e14642.
- [22] Lee JM, Kim HJ, Ha CY, et al. Ectopic opening of the common bile duct into the duodenal bulb accompanied with cholangitis and gallbladder cancer: a report of two cases. *Clin Endosc* 2015;48:260–4.
- [23] Ryoza S, Itoi T, Katanuma A, et al. Japan Gastroenterological Endoscopy Society guidelines for endoscopic sphincterotomy. *Dig Endosc* 2018;30:149–73.
- [24] Itoi T, Ryoza S, Katanuma A, et al. Japan Gastroenterological Endoscopy Society guidelines for endoscopic papillary large balloon dilation. *Dig Endosc* 2018;30:293–309.
- [25] Trikudanathan G, Arain MA, Attam R, et al. Advances in the endoscopic management of common bile duct stones. *Nat Rev Gastroenterol Hepatol* 2014;11:535–44.
- [26] Horiuchi A, Nakayama Y, Kajiyama M, et al. Biliary stenting in the management of large or multiple common bile duct stones. *Gastrointest Endosc* 2010;71:1200–3.
- [27] Manes G, Paspatis G, Aabakken L, et al. Endoscopic management of common bile duct stones: European Society of Gastrointestinal Endoscopy (ESGE) guideline. *Endoscopy* 2019;51:472–91.
- [28] Dong SQ, Singh TP, Zhao Q, et al. Sphincterotomy plus balloon dilation versus sphincterotomy alone for choledocholithiasis: a meta-analysis. *Endoscopy* 2019;51:763–71.
- [29] Kim HJ, Choi HS, Park JH, et al. Factors influencing the technical difficulty of endoscopic clearance of bile duct stones. *Gastrointest Endosc* 2007;66:1154–60.
- [30] Eto K, Kawakami H, Haba S, et al. Single endoscopic treatment for mild to moderate acute cholangitis associated with choledocholithiasis: a multicenter, non-randomized, open-label and exploratory clinical trial. *J Hepatobiliary Pancreat Sci* 2015;22:825–30.
- [31] Sato J, Nakahara K, Morita R, et al. Efficacy and safety of single session endoscopic stone removal for acute cholangitis associated with choledocholithiasis. *Can J Gastroenterol Hepatol* 2018;2018:3145107.
- [32] Zhang X, Li G, Pan L, et al. The efficacy and safety of one stage endoscopic treatment for ascending acute cholangitis caused by choledocholithiasis with severe comorbidities. *Surg Endosc* 2019.
- [33] Lee JC, Moon JH, Choi HJ, et al. Delayed endoscopic papillary large balloon dilation after sphincterotomy for removing large bile duct stone in patients with acute cholangitis. *Dig Dis Sci* 2014;59:1302–6.