

# Ki-67 is overexpressed in human laryngeal carcinoma and contributes to the proliferation of HEp2 cells

YANXIA BAI<sup>1\*</sup>, YUAN SHAO<sup>1\*</sup>, HUAJING LI<sup>1</sup>, WANLI XUE<sup>2</sup>, FANG QUAN<sup>1</sup> and SHENGLI WU<sup>3</sup>

<sup>1</sup>Department of Otorhinolaryngology, The First Affiliated Hospital of Xi'an Jiaotong University;

<sup>2</sup>Department of Public Health, Xi'an Jiaotong University School of Medicine; <sup>3</sup>Department of Hepatobiliary Surgery, The First Affiliated Hospital of Xi'an Jiaotong University, Xi'an, Shaanxi 710061, P.R. China

Received April 16, 2015; Accepted July 20, 2016

DOI: 10.3892/ol.2016.4980

**Abstract.** Ki-67 is one of the most useful markers to evaluate cell proliferative activity and has been widely used in tumor treatment and research. However, its role in human laryngeal carcinoma remains poorly defined. The aim of the present study was to investigate the expression of Ki-67 in human laryngeal squamous carcinoma and the effect of Ki-67 gene silencing by small interfering (si)RNA on the proliferation of human laryngocarcinoma HEp2 cells. Immunohistochemistry and reverse transcription-quantitative polymerase chain reaction were performed to examine the expression of Ki-67 in human laryngeal squamous carcinoma tissues and adjacent non-cancer tissues from 50 patients with laryngeal squamous carcinoma. RNA interference was used to knock down the expression of Ki-67 in the HEp2 cell line, and the proliferation of the treated cells was observed *in vitro*. Western blot analysis was used to determine the expression levels of epidermal growth factor receptor (EGFR) and E-cadherin in the treated cells. The expression of Ki-67 in the laryngeal squamous carcinoma tissues was significantly higher than that of the adjacent non-tumor tissues ( $P=0.028$ ). The high expression of Ki-67 in cancer was significantly correlated with cervical lymph node metastasis and clinical outcomes (all  $P<0.001$ ). The silencing of Ki-67 resulted in the inhibition of proliferation of the HEp2 human laryngocarcinoma cells ( $P<0.001$ ). In addition, compared with the control group, the expression levels of EGFR and E-cadherin in the Ki-67 siRNA-treated cells were significantly decreased ( $P<0.001$ ) and increased ( $P<0.001$ ), respectively. These results suggested

that Ki-67 is important in regulating the proliferation of human laryngocarcinoma HEp2 cells and that the mechanism may at least partially be associated with the upregulation of EGFR and the downregulation of E-cadherin. Overall, Ki-67 can be used as an important indicator for judging clinical progress and estimating prognosis in human laryngeal squamous carcinoma.

## Introduction

Laryngeal carcinoma is the most common malignancy among head and neck tumors, accounting for 1-2.5% of all malignancies throughout the body. Although the clinical outcome of laryngeal carcinoma has gradually improved, the prognosis of this tumor remains poor, with a 5-year overall survival rate of ~60% (1). Local invasion, lymph node metastasis and distant metastasis of laryngeal carcinoma are primarily responsible for this unsatisfactory prognosis (2). The symptoms of laryngeal carcinoma are frequently non-specific and consequently, the diagnosis and appropriate therapy are usually delayed. In one study, only 27.8% of patients with laryngeal carcinoma were noted to have undergone surgery due to a late diagnosis (3). Therefore, a better understanding of the molecular mechanisms driving laryngeal carcinogenesis may aid in the identification of novel predictive and prognostic biomarkers, and in the development of novel treatment strategies for this cancer.

The marker for cellular proliferation, Ki-67, has been generally used in judging clinical progress and estimating the prognosis of malignant tumors. It has been demonstrated that Ki-67 acts as a positive regulator of cancer progression in gliomas, breast cancer, salivary gland tumors and squamous cell carcinoma (4-7). However, Ki-67 expression in laryngeal carcinoma and its significance in laryngeal carcinoma progression remain largely unknown. The present study investigated the expression of Ki-67 in human laryngeal squamous carcinoma tissues and adjacent non-cancerous tissues from 50 laryngeal squamous carcinoma patients using immunohistochemistry and reverse transcription-quantitative polymerase chain reaction (RT-qPCR). Moreover, the effects of Ki-67 gene silencing by small interfering (si)RNA on the proliferation of HEp2 human laryngocarcinoma cells were observed *in vitro*.

---

*Correspondence to:* Dr Shengli Wu, Department of Hepatobiliary Surgery, The First Affiliated Hospital of Xi'an Jiaotong University, 277 Yanta West Road, Xi'an, Shaanxi 710061, P.R. China  
E-mail: victorywu2000@163.com

\*Contributed equally

**Key words:** laryngeal squamous carcinoma, Ki-67, epidermal growth factor receptor, E-cadherin

## Materials and methods

**Cell culture and tissues samples.** This study was approved by the Institutional Review Board and Human Ethics Committee of the First Affiliated Hospital of Xi'an Jiaotong University School of Medicine (Xi'an, Shaanxi, China). All experiments were performed in accordance with the principles of the Declaration of Helsinki and all participants provided their written informed consent to participate in the study. The human laryngeal carcinoma HEP2 cell line was obtained from the Center of Biomedical Research in Xi'an Jiaotong University School of Medicine and routinely cultured in RPMI 1640 medium (Wuhan Boster Biological Technology, Ltd., Wuhan, China) with 10% fetal bovine serum (Wuhan Boster Biological Technology, Ltd.) at 37°C. In total, 100 paraffin embedded tissues, consisting of 50 laryngeal squamous carcinoma and 50 adjacent normal tissues, were obtained from patients treated with surgical resection between January 2013 and February 2015 in the First Affiliated Hospital of Xi'an Jiaotong University School of Medicine. None of these patients received pre-operative radiotherapy and chemotherapy regimens. The histological diagnosis of the carcinoma was determined according to World Health Organization criteria (8).

**Immunohistochemical staining.** Immunohistochemical staining was performed by the standard streptavidin-peroxidase technique with the ready-to-use immunohistochemical detection MaxVision kit (Fuzhou Maixin Biotech. Co., Ltd., Fuzhou, China). Rabbit monoclonal antibody against human Ki-67 was obtained from Neomarkers (catalog no., PA5-16446; 1:100 dilution; Fremont, CA, USA). The primary antibody was replaced with phosphate-buffered saline for the negative control group. For each tissue section, 10 representative high-power fields (x400 magnification) were selected for histological evaluation. The expression of the protein was evaluated based on the positive rate (the percentage of positively-stained cells: ≤10% scored as 0, 11-30% scored as 1, 31-60% scored as 2 and >60% scored as 3) and staining intensity (0, absence of staining; 1, weakly-positive; 2, moderately-positive and strongly-positive). The sum of the scores provide the final score for Ki-67 expression in each sample, in which a final score of <4 was defined as low/negative expression and a final score of ≥4 was defined as high expression.

**RT-qPCR.** Total RNA was isolated from paraffin-embedded tissues using the RecoverAll™ Total Nucleic Acid Isolation kit (Ambion, TX, USA) according to the manufacturer's instructions. For cultured cells, total RNA was extracted using TRIzol reagent (Invitrogen; Thermo Fisher Scientific, Inc., Waltham, MA, USA) according to the manufacturer's protocols. RT-qPCR was performed to evaluate Ki-67 expression using the PrimeScript RT reagent kit (Takara Bio, Inc., Shiga, Japan) according to the manufacturer's instructions. Each reaction was performed in a total volume of 25 µl, containing 12.5 µl of 2X Tli RNaseH Plus, 2 µl of primers, 2 µl of template cDNA, and 8.5 µl of dH<sub>2</sub>O. The thermal profile for the qPCR was 95°C for 30 sec, followed by 40 cycles of 95°C for 5 sec, 60°C for 30 sec and 72°C for 5 sec on a Bio-Rad CFX96 RT-qPCR system (Bio-Rad, Hercules, CA, USA). The primers for Ki-67 gene were as follows:

Forward, 5'-AATTCAGACTCCATGTGCCTGAG-3' and reverse, 5'-CTTGACACACACATTGTCCCTCAGC-3'. The β-actin gene (forward, 5'-CATCCGTAAAGACCTCTATGCCAAC-3' and 5'-ATGGAGCCACCGATCCACA-3') was used as an internal control. Melting curve analysis was then performed. The RT-qPCR procedures were performed in triplicate and the data were analyzed using the comparative Cq method (9).

**siRNA transfection.** For the downregulation of endogenous Ki-67 expression, the following siRNA duplex (Aoke Biological Technology Co., Ltd., Shanghai, China) was used: 5'-GGU AUGAAAUGAAAGUCUTT-3'. The unspecific scrambled siRNA duplex (5'-AAUGGGAAGAAUAGUCUTT-3'; Aoke Biological Technology Co., Ltd.) was used as negative control.

A total of 1x10<sup>5</sup> HEP2 cells were seeded in 6-well plates 24 h prior to transfection. The transfection of the cells was performed using Oligofectamine (Invitrogen; Thermo Fisher Scientific, Inc.) according to the manufacturer's instructions. Specific silencing of targeted genes was confirmed by at least three independent experiments.

Four groups were included in the present study: i) The blank control group; ii) the Lipo2000 group (cells treated with 5 µl Lipofectamine 2000); iii) the control siRNA group (cells treated with 5 µl Lipofectamine 2000 plus 50 pmol negative control siRNA); and iv) the Ki-67-siRNA group (cells treated with 5 µl Lipofectamine 2000 plus 50 pmol Ki-67 siRNA).

**Cell proliferation assay.** Cell proliferation was evaluated using the 3-(4,5-dimethylthiazol-2-yl)-2,5-diphenyltetrazolium bromide (MTT) colorimetric assay daily over a 3-day time course. The HEP2 cells were seeded into eight 96-well plates and incubated in RPMI 1640 medium (Wuhan Boster Biological Technology, Ltd.) at a density of 2x10<sup>3</sup> cells/well at 37°C for 24, 48 and 72 h following treatment, respectively. Cell culture was added with 20 µl of 5 mg/ml MTT agent (Sigma, Saint Louis, MO, USA) and incubated at 37°C for 4 h, followed by addition of 200 µl dimethylsulfoxide and a further 15-min incubation. The absorbance was then determined using a Multiskan Spectrum microplate reader (Thermo Fisher Scientific Inc.) at 490 nm. A growth curve was produced according to the optical density value alterations. The experiment was performed three times independently.

**Western blot analysis.** Cells were lysed in radioimmunoprecipitation assay buffer. Cellular proteins were collected and subjected to 10% sodium dodecyl sulfate-polyacrylamide gel electrophoresis, and then electrotransferred onto Immobilon-P membranes (Invitrogen; Thermo Fisher Scientific, Inc.). The membranes were then incubated for 2 h at 37°C with rabbit anti-human EGFR (catalog no., sc-367974; 1:1,000 dilution; Santa Cruz Biotechnology, Inc., Dallas, TX, USA) or rabbit anti-human E-cadherin (catalog no., sc-7870; 1:1,000 dilution; Santa Cruz Biotechnology, Inc.). This was followed by incubation with horseradish peroxidase-conjugated donkey anti-rabbit immunoglobulin G secondary antibody for 1 h at 37°C (catalog no., NA934; 1:1,000 dilution; Amersham Pharmacia Biotech, Piscataway, NJ, USA). The rabbit anti-human

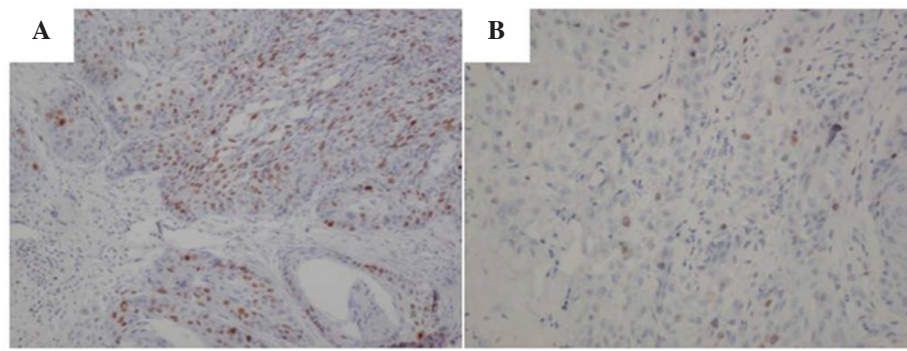


Figure 1. Immunohistochemical staining of Ki-67 protein of laryngeal squamous carcinoma tissues and the corresponding non-cancerous tissues (magnification, x200). (A) Strong immunostaining for Ki-67 protein in laryngeal squamous carcinoma tissue. (B) Ki-67 protein expression is absent in non-cancerous laryngeal tissue.

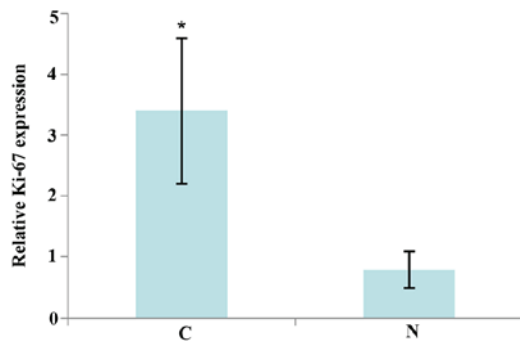


Figure 2. Ki-67 is upregulated in laryngeal squamous carcinoma tissue (C) compared with adjacent non-cancerous tissues (N). Data are presented as the mean  $\pm$  standard deviation. \* $P=0.028$  vs. N.

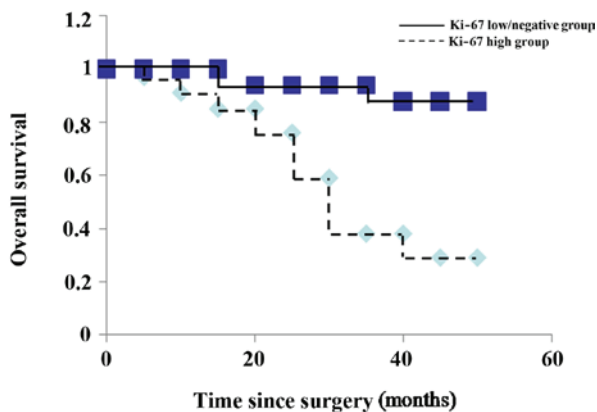


Figure 3. Kaplan-Meier curves based on Ki-67 expression. Kaplan-Meier estimates for overall survival (months) based on Ki-67 status. Log rank test;  $P<0.001$ .

$\beta$ -actin antibody (catalog no., sc-7210; 1:1,000 dilution; Santa Cruz Biotechnology, Inc.) was used as an internal marker for control purposes.

**Statistical analysis.** Continuous data were presented as mean  $\pm$  standard deviation and categorical data were presented as frequencies. Statistical differences were calculated by Student's *t*-test or chi-square test using SPSS 16.0 statistical software (SPSS Inc., Chicago, IL, USA).  $P<0.05$  was considered to indicate a statistically significant difference.

## Results

**Expression of Ki-67 protein in paired human laryngeal squamous carcinoma tissues and corresponding non-cancerous tissue samples.** Ki-67 was detected in 34 out of 50 (68%) laryngeal squamous carcinoma tissues and in only 8 out of 50 (16%) corresponding non-cancerous tissues (Fig. 1). The frequency of Ki-67 in the laryngeal squamous carcinoma tissues was significantly higher than that in the non-cancerous tissues ( $P<0.001$ ).

The study further analyzed the expression level of Ki-67 in the aforementioned tissue samples by RT-qPCR. As shown in Fig. 2, Ki-67 expression was significantly increased in the laryngeal squamous carcinoma tissues compared with the adjacent normal tissues. These observations suggest that Ki-67 may be a tumor promoter in this cancer.

**Increase in Ki-67 expression correlates with cervical lymph node metastasis and clinical outcome.** All 50 patients were followed up regularly after surgery. The median follow-up period was 32 months (range, 5-50 months). The expression of Ki-67 in the patients was compared with regard to gender, age, type of cancer, cervical lymph node metastasis, histological grade, tumor-node-metastasis stage (10), recurrence and clinical outcome. The levels of Ki-67 expression significantly correlated with cervical lymph node metastasis and clinical outcome. During the follow-up of 34 patients with high Ki-67 expression, 24 succumbed. This percentage was significantly higher than that in the patients with low Ki-67 expression (70.6 vs. 12.5%;  $P<0.001$ ; Table I). Using the Kaplan-Meier method, it was observed that the overall survival time was significantly shorter in the high Ki-67 expression group than that in the low/negative Ki-67 expression group ( $P<0.001$ ) (Fig. 3). These results imply that the high expression of Ki-67 may be a valuable predictor for the prognosis of laryngeal squamous carcinoma.

**Ki-67-knockdown in HEP2 cells.** RT-qPCR and western blot analysis were applied to validate the silencing efficiency of the target gene after RNA interference. Stable Ki-67 siRNA-transfected HEP2 cells (Ki-67-siRNA) and a mock-transfected control cell line (control siRNA) were established as aforementioned. Compared with the parental

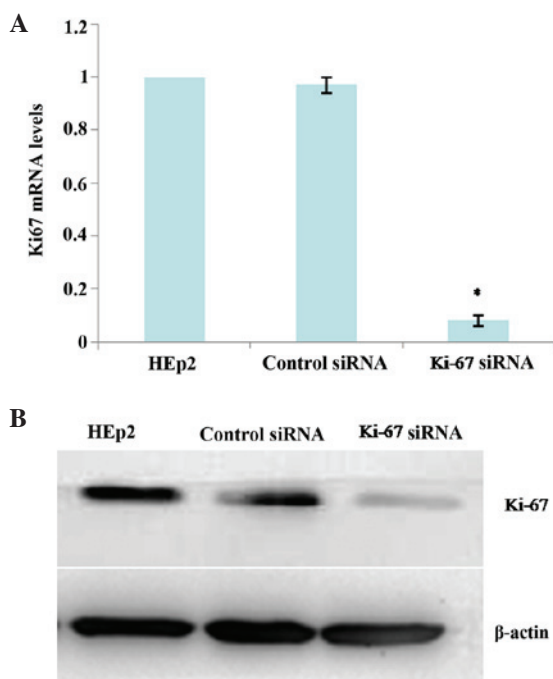


Figure 4. Knockdown of Ki-67 expression in HEp2 cells at 24 h after siRNA transfection. (A) Ki-67 mRNA levels were determined by RT-qPCR. Relative fold induction for Ki-67 mRNA (means  $\pm$  SD) in the mock- and Ki-67 siRNA-transfected HEp2 cells is presented relative to the expression in the parental HEp2 cells ( $P < 0.001$  compared with the parental HEp2 cells). (B) Western blot analysis for Ki-67 protein expression in the indicated cell lines.  $\beta$ -actin was used as a loading control. Parental HEp2 cells, control siRNA (mock-transfected control), and Ki-67-siRNA represent three different clones, respectively.

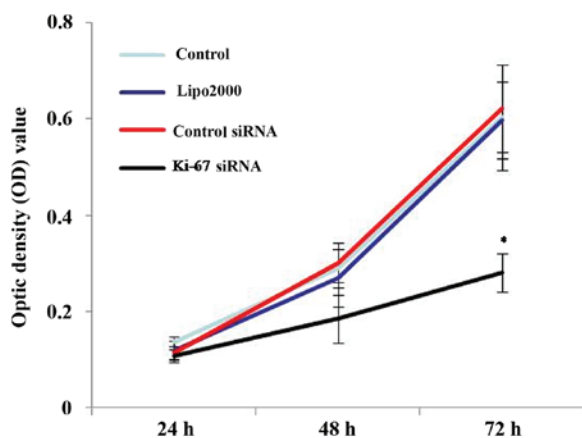


Figure 5. Gene silencing of Ki-67 reduces cell proliferation in HEp2 cells. Cell proliferation was analyzed in the cells using the 3-(4,5-dimethylthiazol-2-yl)-2,5-diphenyltetrazolium bromide assay and monitored for 72 h. The optical density (OD)490 (mean  $\pm$  standard deviation) for each cell line is shown. Cells transfected with Ki-67 small interfering (si)RNA demonstrated a reduced cell growth relative to the blank control, Lipo2000 and control siRNA group cells at 72 h post-transfection ( $P < 0.001$  compared with the blank control, Lipofectamine (Lipo)2000 and control siRNA groups, respectively).

HEp2 cells and control siRNA cells, the mRNA and protein expressions of Ki-67 was significantly reduced in the Ki-67-siRNA cells at 24 h after siRNA transfection (all  $P < 0.001$ ; Fig. 4A and B), which persisted for at least 72 h (data not shown).

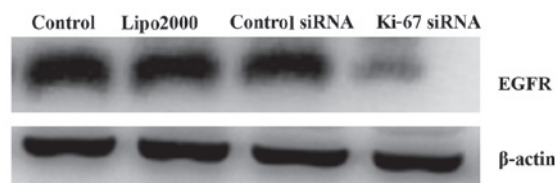


Figure 6. EGFR expression in HEp2 cells 72 h after Ki-67 small interfering (si)RNA transfection. Western blot assay of epidermal growth factor receptor (EGFR) protein expression was performed in the indicated cell lines.  $\beta$ -actin was used as a loading control. Control (parental HEp2 cells), Lipofectamine (Lipo)2000, control siRNA (mock-transfected) and Ki-67-siRNA represent the different clones, respectively.

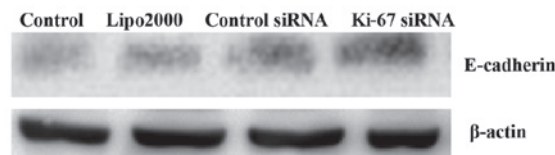


Figure 7. E-cadherin expression in HEp2 cells 72 h after Ki-67 siRNA transfection. Western blot assay of E-cadherin protein expression was performed in the indicated cell lines.  $\beta$ -actin was used as a loading control. Control (parental HEp2 cells), Lipofectamine (Lipo)2000 group cells, control siRNA (mock-transfected) and Ki-67-siRNA represent the different clones, respectively.

*Gene silencing of Ki-67 reduces cell proliferation in HEp2 cells.* To test the effect of the knockdown of Ki-67 on HEp2 cell growth, a MTT cell proliferation assay was performed. As demonstrated by MTT assays, Ki-67-siRNA group cells showed decreased cell proliferation compared with the blank control, Lipo2000 and control siRNA group cells, supporting the role of Ki-67 in cell growth in HEp2 cells ( $P < 0.001$ ; Fig. 5).

*Silencing of Ki-67 by siRNA stimulates the activation of E-cadherin and suppresses the activation of EGFR in HEp2 cells.* In this study, changes in the protein levels of EGFR and E-cadherin after transfection were detected by western blot analysis. The results demonstrated that at 72 h after Ki-67-siRNA transfection, the protein levels of EGFR and E-cadherin were significantly decreased and increased, respectively, in the treated HEp2 cells, compared with those in the cells in the other groups (all  $P < 0.001$ ; Figs. 6 and 7).

## Discussion

Ki-67 is a type of DNA binding protein that is mainly located in the cell nucleus and is closely associated with cell proliferation. Ki-67 expression begins to appear in the G1 phase of the cell cycle, then increases gradually, reaches the peak in the M phase and declines quickly in the late stage of cell division (11). Ki-67 is involved in maintaining the structure of the stable DNA in mitosis and has been used as an indicator of the proliferation rate in a number of human malignancies (12). Various studies have shown that the level of Ki-67 is closely associated with the development and progression of a variety of cancer types, including lung adenocarcinoma, breast cancer, adrenocortical carcinoma and gastric cancer (13-16). In laryngeal carcinoma, however, there is no consensus on the role of

Table I. Association between clinicopathological variables and Ki-67.

Features	Cases, n	Expression of Ki-67, n		P-value
		+	-	
Gender				0.938
Male	34	23	11	
Female	16	11	5	
Age, years				0.895
>50	35	24	11	
≤50	15	10	5	
Type of cancer				0.960
Supraglottic	31	21	10	
Glottic	19	13	6	
Cervical lymph node metastasis				0.021 <sup>a</sup>
Yes	37	29	8	
No	13	5	8	
Histological grade				0.884
I	15	10	5	
II	17	11	6	
III	18	13	5	
TNM stage				0.909
I	7	4	3	
II	15	10	5	
III	18	13	5	
IV	10	7	3	
Recurrence				0.054
Yes	19	16	3	
No	31	18	13	
Clinical outcome				0.000 <sup>a</sup>
Alive	24	10	14	
Succumbed	26	24	2	

<sup>a</sup>P<0.05. -, Low/negative expression of Ki-67 in cancer tissues; +, high expression of Ki-67 in cancer tissues. TNM, tumor-node-metastasis.

Ki-67. Leopardi *et al* found a higher degree of Ki-67 positivity in the neoplastic tissue of laryngeal epithelial lesions compared with in the pre-cancerous tissues or in benign lesions (17). Liu *et al* reported that Ki-67 expression was significantly higher in primary squamous cell carcinoma of the larynx and hypopharynx with lymph node metastasis compared with the expression in those without lymph node metastasis, and that it was correlated with pathological T-stage and tumor differentiation. In univariate analysis, the high expression of Ki-67 was inversely correlated with overall and disease-free survival (18). However, in another study, Teppo *et al* reported that Ki-67 did not significantly affect the prognosis of laryngeal cancer when using the Cox regression model (19). In the present study, it was found that the mRNA and protein levels of Ki-67 in the laryngeal squamous carcinoma tissues were significantly higher compared with those in the adjacent non-tumor tissues. Based on that, further clinical pathological analysis found that the high expression of Ki-67 in cancer was significantly correlated with cervical lymph node metastasis

and clinical outcome. These results suggested that Ki-67 may play a promotive role in the development and progression of laryngeal squamous carcinoma, and that it could be used as a predictor of poor prognosis for laryngeal squamous carcinoma patients.

To provide evidence for this assumption, the effect of Ki-67 silencing on the proliferation of human laryngocarcinoma HEP2 cells *in vitro* was investigated. The expression of Ki-67 in the cells was specifically knocked down using RNA interference. The results demonstrated that the downregulation of Ki-67 resulted in a significant suppression of HEP2 cell proliferation, which strongly indicated that Ki-67 was involved in the canceration processes of laryngeal carcinoma. These data are in line with previous studies on the expression and functional roles of Ki-67 (13-16).

EGFR is a member of the ErbB family of receptors and activation of EGFR signaling may trigger a series of intracellular signals that ultimately promote cell proliferation and cell growth (20). Overexpression of EGFR has been found in

numerous cancer types, including hepatocellular carcinoma, lung cancer, bladder cancer and laryngeal carcinoma (21-24). Li *et al* demonstrated that EGFR expression was significantly correlated with separate Ki-67 expression in gliomas (25). Yang *et al* reported that in primary and relapse nasopharyngeal cancer, a strong significant correlation between EGFR and Ki-67 molecules expression was obtained (26). In the present study, the expression of EGFR was significantly down-regulated in the Ki-67 siRNA-treated cells compared with that in the control group. This indicated a positive correlation between Ki-67 and EGFR, and suggested that Ki-67 may regulate the proliferation of HEP2 cells via modulating the EGFR signaling pathway.

E-cadherin participates in calcium-dependent somatic cell adhesion and loss of E-cadherin is believed to enable metastasis by disrupting intercellular contacts (27). Nakagawa *et al* found that in T1 esophageal squamous cell carcinoma, reduced E-cadherin expression was observed in 58.1% of cases and that E-cadherin expression were closely correlated with nodal metastasis. The study concluded that after endoscopic treatment, additional therapy may be required if reduced E-cadherin expression is observed in the primary tumor specimen (28). Rodrigo *et al* found that E-cadherin was an independent predictor of nodal metastases in supraglottic squamous cell carcinomas (29). In another study, Simionescu *et al* found that in low-grade squamous intraepithelial lesions, E-cadherin had a membranous pattern and the Ki-67 proliferation index was low, whereas in high-grade lesions, E-cadherin expression became aberrant and the Ki-67 proliferation index was high (30). Consistent with this finding, the present study demonstrated that the expression of E-cadherin was significantly upregulated in Ki-67 siRNA-treated cells compared with that in the control group, which indicated a negative correlation between Ki-67 and E-cadherin, and suggested that Ki-67 may promote HEP2 cell proliferation through the modulation of cell adhesion and contact.

In summary, the present study data revealed that the Ki-67 expression in the examined laryngeal squamous carcinoma tissues was significantly higher than that in the adjacent non-tumor tissues. High Ki-67 expression was significantly correlated with cervical lymph node metastasis and may be a valuable predictor for the prognosis of laryngeal squamous carcinoma. The cellular proliferation of Ki-67 siRNA-transfected HEP2 cells was significantly decreased, indicating that Ki-67 may be involved in the canceration processes of laryngeal carcinoma. The upregulation of EGFR and the downregulation of E-cadherin may at least partly contribute to the mechanisms of action of Ki-67. Further studies are necessary to elucidate the detailed molecular mechanisms underlying the involvement of Ki-67 in the tumorigenesis and progression of human laryngeal squamous carcinoma.

## References

1. Markou K, Christoforidou A, Karasmanis I, Tsiropoulos G, Triaridis S, Constantinidis I, Vital V and Nikolaou A: Laryngeal cancer: Epidemiological data from Northern Greece and review of the literature. *Hippokratia* 17: 313-318, 2013.
2. Iovănescu GH, Poenaru M, Doros C and Borugă O: Histopathological prognostic and risk factors in patients with laryngeal neoplasms. *Rom J Morphol Embryol* 54: 1087-1092, 2013.
3. Traoré CB, Kamaté B, Kéita M, Tchoupa MM, Timbo SK, Ag MA and Bayo S: Laryngo-pharyngeal cancer at a health service of last resort in Mali: Anatomico-clinical and therapeutic aspects. *Mali Med* 23: 51-54, 2008 (In French).
4. Arshad H, Ahmad Z and Hasan SH: Gliomas: Correlation of histologic grade, Ki67 and p53 expression with patient survival. *Asian Pac J Cancer Prev* 11: 1637-1640, 2010.
5. Klinton M, Bendahl PO, Graban D, Lövgren K, Malmström P and Fernö M; South Sweden Breast Cancer Group: The prognostic value of Ki67 is dependent on estrogen receptor status and histological grade in premenopausal patients with node-negative breast cancer. *Mod Pathol* 23: 251-259, 2010.
6. Tadbir AA, Pardis S, Ashkavandi ZJ, Najvani AD, Ashraf MJ, Taheri A, Zadeh MA and Sardari Y: Expression of Ki67 and CD105 as proliferation and angiogenesis markers in salivary gland tumors. *Asian Pac J Cancer Prev* 13: 5155-5159, 2012.
7. Jalayer Naderi N, Tirgari F, KharaziFard MJ and Farahani Parsa F: A study on the relationship between clinical features with Ki67 expression and eosinophil cells infiltration in oral squamous cell carcinoma. *Med J Islam Repub Iran* 28: 115, 2014.
8. Thompson L: World Health Organization classification of tumours: pathology and genetics of head and neck tumours. *Ear Nose Throat J* 85: 74, 2006.
9. Schmittgen TD and Livak KJ: Analyzing real-time PCR data by the comparative C(T) method. *Nat Protoc* 3: 1101-1108, 2008.
10. Edge SB and Compton CC: The American Joint Committee on Cancer: The 7th edition of the AJCC cancer staging manual and the future of TNM. *Ann Surg Oncol* 17: 1471-1474, 2010.
11. Zhou Y, Jiang HG, Lu N, Lu BH and Chen ZH: Expression of ki67 in papillary thyroid microcarcinoma and its clinical significance. *Asian Pac J Cancer Prev* 16: 1605-1608, 2015.
12. Li LT, Jiang G, Chen Q and Zheng JN: Ki67 is a promising molecular target in the diagnosis of cancer (review). *Mol Med Rep* 11: 1566-1572, 2015.
13. Liu HB, Gao XX, Zhang Q, Liu J, Cui Y, Zhu Y and Liu YF: Expression and prognostic implications of FOXO3a and Ki67 in lung adenocarcinomas. *Asian Pac J Cancer Prev* 16: 1443-1448, 2015.
14. Chen LY, Tsang JY, Ni YB, Chan SK, Chan KF, Zhang S and Tse GM: Bcl2 and Ki67 refine prognostication in luminal breast cancers. *Breast Cancer Res Treat* 149: 631-643, 2015.
15. Beuschlein F, Weigel J, Saeger W, Kroiss M, Wild V, Daffara F, Libé R, Ardito A, Al Ghuzlan A, Quinkler M, *et al*: Major prognostic role of ki67 in localized adrenocortical carcinoma after complete resection. *J Clin Endocrinol Metab* 100: 841-849, 2015.
16. Li N, Deng W, Ma J, Wei B, Guo K, Shen W, Zhang Y and Luo S: Prognostic evaluation of Nanog, Oct4, Sox2, PCNA, Ki67 and E-cadherin expression in gastric cancer. *Med Oncol* 32: 433, 2015.
17. Leopardi G, Serafini G, Simoncelli C, Ludovini V, Pistola L and Altissimi G: Ki67 and p53 in laryngeal epithelial lesions: Correlations with risk factors. *Acta Otorhinolaryngeal Ital* 21: 243-247, 2001 (In Italian).
18. Liu M, Lawson G, Delos M, Jamart J, Chatelain B, Remacle M and Marbaix E: Prognostic value of cell proliferation markers, tumour suppressor proteins and cell adhesion molecules in primary squamous cell carcinoma of the larynx and hypopharynx. *Eur Arch Otorhinolaryngol* 260: 28-34, 2003.
19. Teppo H, Soini Y, Melkko J, Koivunen P and Alho OP: Prognostic factors in laryngeal carcinoma: The role of apoptosis, p53, proliferation (Ki-67) and angiogenesis. *APMIS* 111: 451-457, 2003.
20. Normanno N, De Luca A, Bianco C, Strizzi L, Mancino M, Maiello MR, Carotenuto A, De Feo G, Caponigro F and Salomon DS: Epidermal growth factor receptor (EGFR) signaling in cancer. *Gene* 366: 2-16, 2006.
21. Buckley AF, Burgart LJ, Sahai V and Kakar S: Epidermal growth factor receptor expression and gene copy number in conventional hepatocellular carcinoma. *Am J Clin Pathol* 129: 245-251, 2008.
22. Carcereny E, Morán T, Capdevila L, Cros S, Vilà L, de Los Llanos Gil M, Remón J and Rosell R: The epidermal growth factor receptor (EGFR) in lung cancer. *Transl Respir Med* 3: 1, 2015.
23. Carlsson J, Wester K, De La Torre M, Malmström PU and Gårdmark T: EGFR-expression in primary urinary bladder cancer and corresponding metastases and the relation to HER2-expression. On the possibility to target these receptors with radionuclides. *Radiol Oncol* 49: 50-58, 2015.
24. Li F, Kang N, Fu W, Sun X, Gao H and Sun K: Detection of epidermal growth factor receptor gene amplification in human laryngeal carcinomas by means of fluorescence in situ hybridization. *Zhonghua Yi Xue Yi Chuan Xue Za Zhi* 17: 278-280, 2000 (In Chinese).

25. Li M, Wei M, Jiang Z, Wei H, Lu W, Dou W and Lu S: BRAF overexpression induces rampant glioma proliferation independent of phospho-EGFR expression. *Adv Clin Exp Med* 23: 893-899, 2014.
26. Yang Y, Xuan J, Yang Z, Han A, Xing L, Yue J, Hu M and Yu J: The expression of epidermal growth factor receptor and Ki67 in primary and relapse nasopharyngeal cancer: A micro-evidence for anti-EGFR targeted maintenance therapy. *Med Oncol* 29: 1448-1455, 2012.
27. Onder TT, Gupta PB, Mani SA, Yang J, Lander ES and Weinberg RA: Loss of E-cadherin promotes metastasis via multiple downstream transcriptional pathways. *Cancer Res* 68: 3645-3654, 2008.
28. Nakagawa Y, Ohira M, Kubo N, Yamashita Y, Sakurai K, Toyokawa T, Tanaka H, Muguruma K, Shibutani M, Yamazoe S *et al*: Tumor budding and E-cadherin expression are useful predictors of nodal involvement in T1 esophageal squamous cell carcinoma. *Anticancer Res* 33: 5023-5029, 2013.
29. Rodrigo JP, Dominguez F, Alvarez C, Manrique C, Herrero A and Suárez C: Expression of E-cadherin in squamous cell carcinomas of supraglottic larynx with correlations to clinico-pathological features. *Eur J Cancer* 38: 1059-1064, 2002.
30. Simionescu C, Mărgăritescu C, Stepan A, Georgescu CV, Niculescu M and Muntean M: The utility of p16, E-cadherin and Ki67 in cervical squamous intraepithelial lesions diagnosis. *Rom J Morphol Embryol* 51: 621-626, 2010.