



## Case report

# Continuous epidural catheter for anaesthesia management and post-op pain relief in colorectal surgery, complicated by epidural haematoma and bilateral paraplegia: A case report

Mohammad Ashouri<sup>a</sup>, Kasra Karvandian<sup>b</sup>, Zahra Ataie-Ashtiani<sup>c</sup>, Narjes Mohammadzadeh<sup>a,\*</sup>

<sup>a</sup> Department of Surgery, Imam Khomeini Hospital Complex, Iran

<sup>b</sup> Department of Anesthesiology, Imam Khomeini Hospital Complex, Iran

<sup>c</sup> Doctor of Medicine, University of Melbourne, Australia



## ARTICLE INFO

## Keywords:

Epidural haematoma  
Continuous epidural analgesia  
Epidural anaesthesia  
Colorectal cancer surgery  
Paraplegia post-op  
Surgical case report

## ABSTRACT

**Introduction:** Utilising epidural analgesia (EA) during major abdominal surgery in combination with general anaesthetic, is a proven approach to decrease anaesthetic requirement in patients with severe comorbidities, enhance recovery and improve pain management.

**Case presentation:** Herein we report a case of an 81-years-old female with bilateral lower limb sensory loss, saddle paraesthesia, paraplegia, and incontinence following a thoracic epidural catheterisation required for low anterior resection of rectal adenocarcinoma. The complication was reported by the patient on the third day of post-op.

**Clinical discussion:** The magnetic resonance imaging results revealed an extradural extramedullary hyperintense haematoma in the spinal cord at T12-L2 vertebral level. The neurological deficit was addressed urgently with laminectomy; and following implementation of intensive inpatient physiotherapy and rehabilitation regimen the patient restored mild motor function.

**Conclusion:** We believe the culprit of the acute focal neurology deficits in this patient could be due to the epidural catheterisation and the post-op local anaesthetic injections. From this case, we anecdotally recommend performing thoracolumbar MRI as part of pre-op workup in patients with long standing back issues or claudication, considering x-ray guided catheterisation in higher risk patients for epidural hematoma, and early and repeated neurological examination and rapid investigation for any mild neurological deficits.

## 1. Introduction

Enhanced recovery after surgery (ERAS) protocols are the cornerstone in abdominal surgery with the major component of it being an effective multimodal method of post-op pain control, nonetheless, we still lack an evidence-based standardised approach for pain management in this group of patients [1]. One of the key methods includes utilising epidural analgesia (EA), which involves the delivery of local anaesthetic with or without opioids [2]. Based on a 2011 randomised study, EA provides better pain management in patients undergoing rectal surgery compared to patients with post-op intravenous infusion [2]. In addition to enhanced pain management, the combined regional-general anaesthesia decreases anaesthetic requirement in patients with severe comorbidities and improves the quality of anaesthesia management [3].

Complications of EA can include hypotension, bradycardia, post dural puncture headache (PDPH), injury to local structures or nerves and hematoma formation [4]. Epidural haematoma due to regional anaesthesia is a rare complication which can cause catastrophic neurologic deficits for patients [5,6].

Herein, we discuss a rare case of EA induced epidural haematoma in a patient who underwent an anterior rectal resection, which resulted in bilateral lower limb and saddle paraplegia, paraesthesia and incontinence, in line with SCARE Criteria [7]. As far as we are aware, there has been few similar cases in the literature, reporting a bilateral manifestation of epidural haematoma following EA.

\* Corresponding author at: Tehran University of Medical Sciences, Imam Khomeini Hospital Complex, Department of Surgery, Keshavarz Blvd, District 6, Tehran, Iran.

E-mail addresses: [nmohammadzadeh@sina.tums.ac.ir](mailto:nmohammadzadeh@sina.tums.ac.ir), [Imamhospital@tums.ac.ir](mailto:Imamhospital@tums.ac.ir) (N. Mohammadzadeh).

<https://doi.org/10.1016/j.ijscr.2021.106039>

Received 9 March 2021; Received in revised form 23 May 2021; Accepted 23 May 2021

Available online 26 May 2021

2210-2612/© 2021 Published by Elsevier Ltd on behalf of IJS Publishing Group Ltd. This is an open access article under the CC BY-NC-ND license

(<http://creativecommons.org/licenses/by-nc-nd/4.0/>).

## 2. Case presentation

An 81-year-old female with a known rectal adenocarcinoma was referred to the general surgical team at a high-volume centre in Tehran, after 23 sessions of neoadjuvant chemoradiation. Colonoscopy results reported an ulcerated mass located nine to ten cm proximal to the anal verge. Fortunately, based on the CT Pan-Can, there was no evidence of local or distant metastasis. Following in-depth discussions about the risks, the patient indicated that regardless of the outcome, she was adamant to have the surgery. Subsequently, she was scheduled for a low anterior resection, eight weeks after her last chemo radiation session.

The patient was from a remote area with a low socioeconomic background, she spoke a dialectal language which created a language barrier. She was fully independent and mobilised unaided. She had a BMI of 32 kg/m<sup>2</sup> with an extensive 30-year history of ischemic heart disease and long-standing back pain. Her regular medications included 100 mg metoprolol, 80 mg aspirin and 6.2 mg TNG; and she had no known allergies. On admission, her vitals and preoperative lab data including coagulation tests, were within the normal range. Preoperative anaesthetic risk assessments indicated high risk situation for general anaesthesia and the patient was in ASA class II-III. On the day of surgery, a T12/L1 epidural catheterisation was performed to achieve a combined regional-general anaesthesia and post-op pain management. This procedure was done by an expert and highly skilled anaesthesiologist. For a combined anaesthetic effect, the general anaesthesia was preserved in BSI 40–60 and instead, intermittent doses of Ropivacaine 0.5% were used intra-operatively via an epidural catheter. The surgery was done by a consultant general surgeon, who approximately performs over 40 colorectal cancer cases annually, with the aid of PGY4/5. After the operation the patient was transferred to ICU for post-operative care. Infusion of Marcaine (Bupivacaine) 0.5% was continued for three days during the recovery phase. Her neurological examination was unremarkable at the recovery room.

The recovery took an unexpected turn, and on the third day of post-op, the patient reported paralysis and paraesthesia of both lower limbs, however the reporting was delayed due to the language barriers and mild delirium developed in the first 24-h post-op. However once informed, the epidural infusion was discontinued, and rapid investigation was initiated. A neurology consult was arranged, and neurological assessment indicated spinal shock (Table 1). Based on the clinical presentation, epidural haematoma with cord compression at L1-S2 was suspected, which was confirmed by the thoracolumbar MRI imaging (Fig. 1A and B).

The neurosurgical team performed an urgent decompressive laminectomy and one week after laminectomy, improvement in sphincter tone was noticed on examination. By three weeks post-op she regained urinary and faecal continence and with the aid of intensive inpatient rehabilitation and physiotherapy, and the patient had measurable neurological recovery and improvement in sensation and motor function, with paraplegia persisting by the time she was discharged home. She was discharged with prophylactic enoxaparin 40 mg subcut daily, planned outpatient physio-sessions and occupational therapy review and support. She had a telehealth follow-up two weeks post-discharge due to distance, with patient reporting further improvement in mobility and an in-person review ordered in two weeks' time. However, before the review time, the patient sadly had a fatal AMI at home.

**Table 1**

Results of neurological assessment, scoring according to the standardised muscle grading system.

Neurological assessment	Right			Left			Sphincter tone
	Sensation	Motor function	Deep tendon reflex	Sensation	Motor function	Deep tendon reflex	
First, Post-op Examination	0	0	0	0	0	0	0
Following laminectomy	0	0	0	0	1	0	0
Following rehabilitation	1	0	1	1	1	1	2

## 3. Discussion

Epidural analgesia is an effective method of anaesthesia and post-op pain management which associates with a faster recovery in abdominal surgery [1]. Despite low incidence, epidural catheter-induced complications including epidural haematoma, abscess, spinal cord injury or infarction have been reported in the literature. These complications remain extremely rare, with an estimated incidence rate between 0.006% and 0.03%, yet they are often associated with prolonged recovery time and devastating impact on patient functionality [8].

The incidence of epidural catheter-induced hematoma is reported to be as low as 0.00055 and 0.00008% [5,6]. Risk factors such as stenosis of spinal canal, use of anti-coagulant and antiplatelets, have been associated with increased incidence of an epidural haematoma. Other Risk factors include advanced age, female sex, traumatic and multiple attempts at puncture for neuraxial anaesthesia, vascular malformations and arterial hypertension [9]. In this case, the patient was on a single antiplatelet agent and had canal stenosis and osteophytes on MRI imaging. Perhaps, the reason for the delayed formation of epidural hematoma in this patient was the canal stenosis and low capacity of epidural space.

In other case studies, the use of intermittent bolus instead of continuous infusion of local anaesthetic and early motor function assessment have been suggested, to minimise these complications [10]. Yet, this needs to be balanced with the knowledge that a continuous low dose administration of narcotics via epidural catheter tends to associate with a lower incidence of side effects such as hypotension, respiratory depression and urinary retention compared to bolus administration [11]. In summary, this case brings to attention, the importance of using MRI as part of pre-op workup in individuals with chronic back pain and history of canal stenosis, serious consideration of using x-ray guided epidural catheter insertion, and post operation repeated neurological monitoring, in particular in cases with a higher risk of complications [9].

## 4. Conclusion

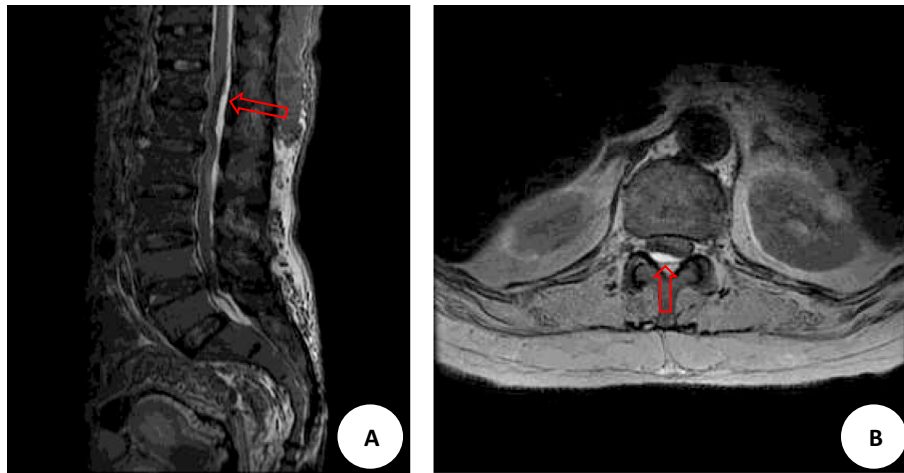
Combined epidural analgesia remains an important modality for effective pain management in patients during major abdominal surgery, including but not limited to oncological cases. Epidural catheterisation associates with rare complications such as nerve injury, epidural haematoma formation, spinal abscess and spinal infarction, which often need urgent interventions. To optimise patients' outcome, we advocate for stratification of high-risk patients, detailed discussion with patients when consenting patients, consideration of thoracolumbar MRI imaging in patients with history of back pain/lower limb claudication as part of routine pre-op workup, using x-ray guided epidural catheter insertion by an experienced anaesthesiologist, and post operation repeated neurological monitoring.

### Provenance and peer review

Not commissioned, externally peer-reviewed.

### Sources of funding

None.



**Fig. 1.** Magnetic resonance T1-weighted imaging of view of the thoracolumbar spine. Sagittal view (A) and axial view (B) indicate a well-defined hyperintense region in the extradural extramedullary space at T12-L1, shown by the red arrows. (For interpretation of the references to color in this figure legend, the reader is referred to the web version of this article.)

### Ethical approval

N/A.

### Consent

Written informed consent was obtained from the patient for publication of this case report and accompanying images. A copy of the written consent is available for review by the Editor-in-Chief of this journal on request.

### Author contribution

1. Ashouri, Mohammad, Assistant professor, overseeing the case study, overseeing and editing the report.
2. Karvandian, Kasra, Associate professor, Anaesthesiologist of the case, overseeing and editing the report.
3. Ataie, Zahra, Medical student, writing the case study.
4. Mohammadzadeh, Narjes, surgeon, corresponding author.

### Research registration (for case reports detailing a new surgical technique or new equipment/technology)

NA.

### Guarantor

Narges Mohammadzadeh.

### Declaration of competing interest

None.

### References

- [1] E.D. Staren, M.L. Cullen, Epidural catheter analgesia for the management of postoperative pain, *Surg Gynecol Obstet* 162 (1986) 389–404.
- [2] M. Wongyingsinn, G. Baldini, P. Charlebois, S. Liberman, B. Stein, F. Carli, Intravenous lidocaine versus thoracic epidural analgesia: a randomized controlled trial in patients undergoing laparoscopic colorectal surgery using an enhanced recovery program, *Reg. Anesth. Pain Med.* 36 (2011) 241–248.
- [3] N. Rawal, Combined regional and general anaesthesia, *Curr. Opin. Anaesthesiol.* 13 (2000) 531–537.
- [4] J. Nizamuddin, M. O'Connor, Anaesthesia for surgical patients, in: F.C. Brunicaudi, D.K. Andersen, T.R. Billiar, D.L. Dunn, L.S. Kao, J.G. Hunter (Eds.), *Text Book of Schwartz's Principles of Surgery*, 11th ed., McGraw-Hill Education, New York, 2019, pp. 20–22.
- [5] T.M. Cook, D. Counsell, J.A.W. Wildsmith, Major complications of central neuraxial block: report on the third National Audit Project of the Royal College Anaesthetists, *Br. J. Anaesth.* 102 (2009) 179–190.
- [6] W. Ruppen, S. Derry, H. McQuay, R.A. Moore, Incidence of epidural hematoma, infection, and neurologic injury in obstetric patients with epidural analgesia/ anaesthesia, *Anaesthesiology* 105 (2006) 394–399.
- [7] R.A. Agha, T. Franchi, C. Sohrabi, G. Mathew, A. Kerwan, A. Thoma, et al., The SCARE 2020 guidelines: updating Consensus Surgical Case Report (SCARE) guidelines, *Int. J. Surg.* 84 (2020) 226–230.
- [8] B.H. Jeon, H.J. Bang, G.M. Lee, O.P. Kwon, Y.J. Ki, Flaccid leg paralysis caused by a thoracic epidural catheterization: a case report, *Ann. Rehabil. Med.* 37 (2013) 453–458.
- [9] A. Makris, E. Gkliatis, M. Diakomi, I. Karmanioulou, A. Mela, Delayed spinal epidural hematoma following spinal anaesthesia, far from needle puncture site, *Spinal Cord* 52 (Suppl. 1) (2014) S14–S16.
- [10] S. Anipindi, N. Ibrahim, Epidural haematoma causing paraplegia in a patient with ankylosing spondylitis: a case report, *Anesth. Pain. Med.* 7 (2017), e43873.
- [11] Guay J, Nishimori M, Kopp S. Epidural local anaesthetics versus opioid-based analgesic regimens for postoperative gastrointestinal paralysis, vomiting and pain after abdominal surgery. *Cochrane Database Syst. Rev.* 2016;7:CD001893.