

Cystic pilomyxoid astrocytoma on suprasellar region in 7-year-old girl: Treatment and strategy

Mardjono Tjahjadi, M. Zafrullah Arifin, Mirna Sobana, Astri Avianti, M. Sinatrya Caropeboka, Priandana Adya Eka, Hasrayati Agustina¹

Departments of Neurosurgery and ¹Pathology Anatomy, Medical Faculty of Padjadjaran University, Hasan Sadikin Hospital, Bandung, Indonesia

ABSTRACT

Pilomyxoid astrocytoma (PMA) is a recently described entity with similar features to pilocytic astrocytoma but with a rare occurrence. As a new diagnosis, no treatment guideline of PMA has been established; but generally, as for any low-grade gliomas, radical resection is performed if the location is favorable. In this report, we wished to share our experience treating the PMA. The authors presented a case of a 7-year-old girl with bitemporal hemianopia. From the history, the patient had a 4-month history of headache, following with nausea and projectile vomiting 1 week before hospital admission. Past history of seizure, weakness of left extremities, and decreased consciousness were reported. Computed tomography (CT) scanning showed acute obstructive hydrocephalus and an isohypodense mass at suprasellar region with the cystic component. We performed ventriculo-peritoneal-shunt to reduce the acute hydrocephalus, followed by craniotomy tumor removal 2 weeks later. The patient underwent radiotherapy and medical rehabilitation. Diagnosis of PMA was made on the basis of pathologic anatomy result, which showed a myxoid background with pseudorosette. Postoperative CT showed a residual tumor at right parasellar area without hydrocephalus. After the surgery, the treatment was followed with radiotherapy for 20 times within 2 months. Postradiation CT performed 1-year later showed a significant reduction of the tumor mass. There were no new postoperative deficits. The patient had improvement of the visual field and motor strength. The authors reported a case of a 7-year-old girl with PMA. Surgical resection combined with radiotherapy was performed to control the growth of PMA. More observation and further studies are required to refine the treatment methods.

Key words: Pediatric brain tumor, pilomyxoid astrocytoma, suprasellar tumor

Introduction

Pilomyxoid astrocytoma (PMA) is a type of tumor resembling pilocytic astrocytoma (PA), yet differs in a clinical course and histopathological findings. As a new diagnosis, there were no treatment guidelines for PMA established. We reported a case of cystic PMA on suprasellar region in a 7-year-old girl at our institution.

Case Report

Chief complaint

A 7-year-old girl was presented in the authors' department with decreased consciousness.

Medical history and examination

The patient had a headache since 4 months prior to admission, which has gotten worse since 6 weeks before being hospitalized. She also vomited 1–2 times/day. Visual field disturbance was also noted. One day before admission, she complained of severe headache and projectile vomiting. Physical examination revealed decreased consciousness with the Glasgow coma scale score of 12 (E3M5V4) accompanied by weakness on left extremities with motor strength score of 4. Other physical examinations were found within normal limit.

Imaging

Head computed tomography (CT) scan of this patient showed an isohypodense mass at suprasellar region with solid and cystic configuration, ventricular systems were enlarged with the periventricular edema suggesting acute hydrocephalus.

Access this article online

Quick Response Code:



Website:

www.asianjns.org

DOI:

10.4103/1793-5482.154989

Address for correspondence:

Dr. Mardjono Tjahjadi, Department of Neurosurgery, Medical Faculty of Padjadjaran University, Hasan Sadikin Hospital, Bandung, Indonesia.
E-mail: brainchirurg@gmail.com

Nonhomogenous contrast enhancement was found particularly at suprasellar region [Figure 1].

Operative treatment

The authors performed an emergency ventriculo-peritoneal (VP)-shunt to reduce intracranial pressure (ICP) caused by hydrocephalus. Shortly after the procedure, patient's general condition improved. Craniotomy tumor removal was performed 2 weeks afterward using pterional transsylvian approach. The tumor was firm and reddish in color, it wrapped the internal carotid artery (ICA), the proximal part of middle cerebral artery, anterior cerebral artery, and its branches. Optic apparatus and pituitary stalk were also wrapped by the tumor [Figure 2a]. An intratumoral cyst was found containing a yellowish liquid. Tumor had extended into the third ventricle and attached in the wall of the third ventricle. The tumor was partially removed about 80%; parts that strongly attached to the ICA, pituitary stalk and hypothalamus were left behind [Figure 2b]. Postoperative CT showed reduction of the tumor mass with visible remnant especially at right parasellar area [Figure 3a and b]. Radiotherapy was eventually proposed to control the residual tumor.

Adjuvant treatment

In the postoperative course, some neurological deficits included weakness on the extremities, headache, and visual problems were improved. Within 3 weeks after surgery, the patient was directly sent to the radiotherapy department to receive linear accelerator (LINAC) electron shot at 180 cGy for 20 times within 2 months. The mass measurement for radiation was constructed in three-dimensional and the area of radiation was extended to 2 mm of the tumor border. If the surrounding area is vital, we only radiate the tumor within the border. During radiation therapy, there was no major complaint, except minimal nausea. Concerning the child's growth, the patient was followed-up in the neurosurgery outpatient clinic, altogether with neuropsychiatrist, ophthalmologist and physiatrist. Further improvement on motor strength, visual acuity, and visual field were reported. Only slight astigmatism was found on both eyes. One-year postradiotherapy CT showed a significant reduction of the mass size [Figure 3c and d].

Histopathological evaluation

The tumor cells are dominated markedly by mucoid matrix and composed of monomorphic bipolar cells with angiocentric cells arrangement [Figure 4a-c]. This finding was consistent with the diagnosis of PMA. Cerebrospinal fluid (CSF) analysis did not reveal any malignant cells.

Discussion

Pilomyxoid astrocytoma was proposed in 1999 by Tihan *et al.* as a separate diagnosis from PA because of its histological configurations which determine patient's prognosis.^[1] As a recently described astrocytic neoplasm entity, this lesion

has not been included in the current (2000) World Health Organization classification.^[2-4] Characteristically, PMA is more aggressive with higher rate of local recurrence and leptomeningeal dissemination.^[2] PMA usually found in infant and very young children (3 months to 2 years), with mean presentation about 10–18 months.^[2,4-7] Some reports mentioned about PMA in older patients.^[8,9] The survival rates of PMA are worse than PA; with progression-free-survival about 26 months and overall survival of 63 months.^[2,4]

The predilection of PMA is in the neuraxis, especially in the hypothalamus or optic chiasm.^[2,6,10] Seldom, this tumor was found in the cerebellum and cervical spinal cord.^[4,6,11,12] Histologically, PMA shows marked myxoid matrix with small, compact, piloid, and highly monomorphic cells. Perivascular rosettes were often found. Different from PA, this tumor shows no Rosenthal fibers and rare eosinophilic granular bodies.^[1,12,13]

As with the majority of pediatric brain tumors, PMA most commonly presents with symptoms of increased ICP or parenchymal compression, including failure to thrive, developmental delay, altered level of consciousness, vomiting, feeding difficulties, and generalized weakness.^[7,9,11,14] Several studies revealed patients with decreased visual field and acuity while others reported the presence of diencephalic syndromes.^[5,6,11] In cases of spinal cord PMA, the presenting symptoms are neck pain and weakness of extremities.^[12,14]

Until this time, there were no definitive pathognomonic imaging findings to distinguish PMA from PA.^[2,8,10] On head CT, PAs typically shows heterogeneous enhancement with a substantial cystic component, while PMAs typically enhance homogeneously and demonstrate solid composition; those facts could help in differentiating PMA from PA.^[4] Hemorrhage due to spontaneous intratumoral bleeding was reported in PMA but not in PA; however it also requires further investigation.^[10] In several studies, magnetic resonance imaging was used as a gold standard to differentiate PMA from PA but still did not reveal any specific difference. One study has suggested the usage of magnetic resonance spectroscopy to distinguish PMA from PA, although further studies were needed.^[4,10]

The management for PMA is still controversial and was greatly influenced by tumor location.^[1,4] Gross total resection of newly diagnosed tumors, provided it can be performed without unacceptable sequelae, is the most powerful predictor of a favorable outcome in children. For the patient with hydrocephalus, CSF diversion by external drainage or VP-shunt could be performed.^[9,11] As for residual tumors, the role of adjuvant therapy is still questionable.^[1-4] Chemotherapy as an adjuvant therapy for PMA has been mentioned in several reports. For the time being, chemotherapy is usually applied judiciously for inoperable or partially resected tumors and may delay the need for radiotherapy in early childhood. Radiotherapy is generally reserved for patients older than

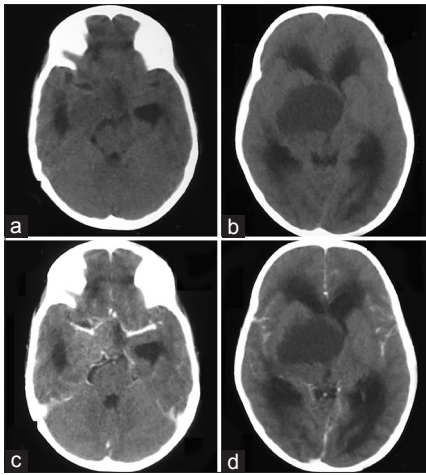


Figure 1: (a and b) Noncontrast preoperative head computed tomography (CT) scan showed isohypodense mass at suprasellar region that extends into parasellar region and third ventricle; an acute obstructive hydrocephalus was shown. (c and d) Postcontrast preoperative head CT scan showed inhomogeneous enhancement of the mass at suprasellar region (c) Mass size was measured 5 cm × 5 cm × 4 cm

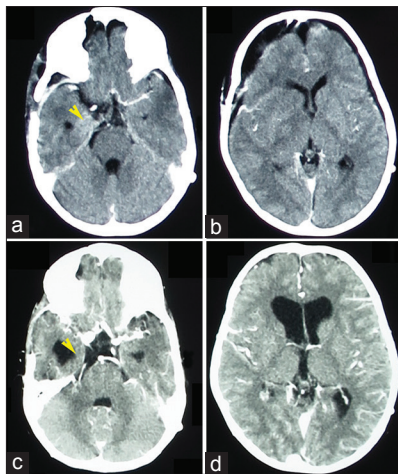


Figure 3: (a and b) Postoperative computed tomography (CT) scan showed a reduction of the tumor mass especially at the suprasellar region. (c and d) 1-year postradiotherapy CT scan, the enhancement of tumor remnant as shown on (a) (yellow arrowhead) was significantly reduced after radiotherapy (c), yellow arrow head]. Ventricle system was enlarged, but the shunt pump was still effective, and the patient did not complain any intracranial hypertension sign

5 years old after an initial surgical resection and have tumors located near the midline.^[2,10] In the authors' case, the treatment course was begun by performing CSF diversion by VP-shunt in order to manage the hydrocephalus followed by craniotomy tumor removal as the patient's general condition improved. Postoperative radiotherapy was performed, as the patient is considered old enough to accept the radiation dose. The patient's condition improved after the authors' course of treatment. Twenty-six months after radiotherapy, no clinical deterioration was reported, and the patient could perform her daily activities well.

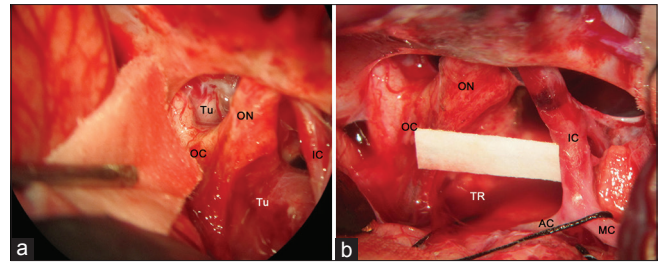


Figure 2: (a) Intraoperative finding: A reddish gray tumor mass with firm consistency was encountered at suprasellar region. Tumor mass encased optic apparatus, internal carotid artery with its branches and pituitary stalk. (b) After subtotal tumor removal: Majority of neurovascular structures were released from the tumor encasement. Tumor mass attached to the hypothalamus, pituitary stalk, and ICA branches was left behind. AC = Anterior cerebral artery; ICA = Internal carotid artery; MCA = Middle cerebral artery; OC = Optic chiasm; ON = Optic nerve; Tu = Tumor mass; TR = Tumor remnant

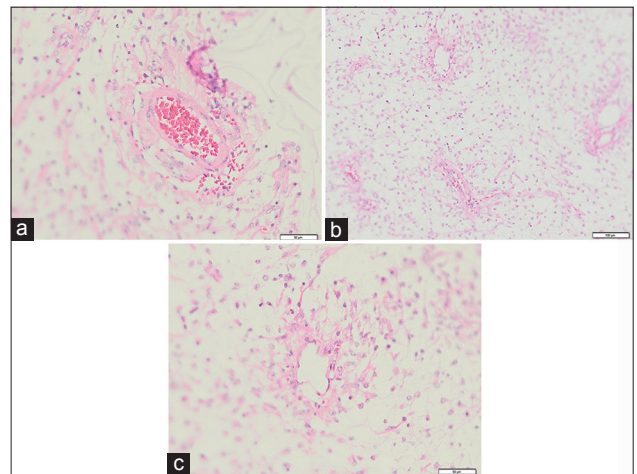


Figure 4: (a) Histopathological result revealed pseudorosette formation (H and E, magnification × 200). (b) Monomorphic population of tumor cells in a myxoid matrix (H and E, magnification × 100). (c) Angiocentric arrangement of tumor cells (H and E, magnification × 200)

Conclusion

The authors reported a case of a 7-year-old girl with PMA. Surgical resection combined with radiotherapy was performed to control the growth of PMA. More observation and further studies are required to refine the treatment methods.

References

1. Tihan T, Fisher PG, Kepner JL, Godfraind C, McComb RD, Goldthwaite PT, *et al.* Pediatric astrocytomas with monomorphic pilomyxoid features and a less favorable outcome. *J Neuropathol Exp Neurol* 1999;58:1061-8.
2. Komotar RJ, Mocco J, Carson BS, Sughrue ME, Zacharia BE, Sisti AC, *et al.* Pilomyxoid astrocytoma: A review. *MedGenMed* 2004;6:42.
3. Matsuzaki K, Kageji T, Watanabe H, Hirose T, Nagahiro S. Pilomyxoid astrocytoma of the cervical spinal cord successfully treated with chemotherapy: Case report. *Neurol Med Chir (Tokyo)* 2010;50:939-42.
4. Terasaki M, Bouffet E, Maeda M, Sugita Y, Sawamura Y, Morioka M. Successful treatment of leptomeningeal gliomatosis of pilomyxoid astrocytoma after failed frontline chemotherapy. *Neurologist* 2012;18:32-5.

5. Komotar RJ, Mocco J, Jones JE, Zacharia BE, Tihan T, Feldstein NA, *et al.* Pilomyxoid astrocytoma: Diagnosis, prognosis, and management. *Neurosurg Focus* 2005;18:E7.
6. Kim SH, Kang SS, Jung TY, Jung S. Juvenile pilomyxoid astrocytoma in the optichypothalamus. *J Korean Neurosurg Soc* 2010;48:445-7.
7. Forbes JA, Mobley BC, O'Lynnner TM, Cooper CM, Ghiassi M, Hanif R, *et al.* Pediatric cerebellar pilomyxoid-spectrum astrocytomas. *J Neurosurg Pediatr* 2011;8:90-6.
8. Linscott LL, Osborn AG, Blaser S, Castillo M, Hewlett RH, Wieselthaler N, *et al.* Pilomyxoid astrocytoma: Expanding the imaging spectrum. *AJNR Am J Neuroradiol* 2008;29:1861-6.
9. Ajani OA, Al Sulaiti G, Al Bozom I. Pilomyxoid astrocytoma of the cerebellum. *J Neurosurg Pediatr* 2011;7:539-42.
10. Arslanoglu A, Cirak B, Horska A, Okoh J, Tihan T, Aronson L, *et al.* MR imaging characteristics of pilomyxoid astrocytomas. *AJNR Am J Neuroradiol* 2003;24:1906-8.
11. Mahore A, Kammar A, Dange N, Epari S, Goel A. Diencephalic juvenile pilomyxoid astrocytoma with leptomeningeal dissemination. *Turk Neurosurg* 2011;21:222-5.
12. Johnson MW, Eberhart CG, Perry A, Tihan T, Cohen KJ, Rosenblum MK, *et al.* Spectrum of pilomyxoid astrocytomas: Intermediate pilomyxoid tumors. *Am J Surg Pathol* 2010;34:1783-91.
13. Tsugu H, Oshiro S, Yanai F, Komatsu F, Abe H, Fukushima T, *et al.* Management of pilomyxoid astrocytomas: Our experience. *Anticancer Res* 2009;29:919-26.
14. Paraskevopoulos D, Patsalas I, Karkavelas G, Foroglou N, Magras I, Selviaridis P. Pilomyxoid astrocytoma of the cervical spinal cord in a child with rapid progression into glioblastoma: Case report and literature review. *Childs Nerv Syst* 2011;27:313-21.

How to cite this article: Tjahjadi M, Arifin MZ, Sobana M, Avianti A, Caropeboka MS, Eka PA, *et al.* Cystic pilomyxoid astrocytoma on suprasellar region in 7-year-old girl: Treatment and strategy. *Asian J Neurosurg* 2015;10:154-7.

Source of Support: Nil, **Conflict of Interest:** None declared.