

Intervertebral disc regeneration using platelet-rich plasma-containing bone marrow-derived mesenchymal stem cells: A preliminary investigation

SHAN-ZHENG WANG^{1*}, JI-YANG JIN^{2*}, YU-DONG GUO¹, LIANG-YU MA¹, QING CHANG¹, XIN-GUI PENG², FANG-FANG GUO³, HAI-XIANG ZHANG¹, XIN-FENG HU⁴ and CHEN WANG¹

Departments of ¹Orthopaedics, ²Radiology and ³Plastic Surgery, Zhongda Hospital, Medical School of Southeast University, Nanjing, Jiangsu 210009; ⁴Department of Orthopaedics, Qidong People's Hospital, Qidong, Jiangsu 226200, P.R. China

Received March 28, 2015; Accepted December 30, 2015

DOI: 10.3892/mmr.2016.4983

Abstract. Platelet-rich plasma (PRP) is a promising strategy for intervertebral disc degeneration (IDD). However, the short half-life of growth factors released from PRP cannot continuously stimulate the degenerated discs. Thus, the present study hypothesized that the combined use of PRP and bone marrow-derived mesenchymal stem cells (BMSCs) may repair the early degenerated discs in the long term for their synergistic reparative effect. In the present study, following the induction of early IDD by annular puncture in rabbits, PRP was prepared and mixed with BMSCs (PRP-BMSC group) for injection into the early degenerated discs. As controls, phosphate-buffered saline (PBS; PBS group) and PRP (PRP group) were similarly injected. Rabbits without any intervention served as a control group. At 8 weeks following treatment, histological changes of the injected discs were assessed. Magnetic resonance imaging (MRI) was used to detect the T2-weighted signal intensity of the targeted discs at weeks 1, 2 and 8 following treatment. Annular puncture resulted in disc narrowing and decreased T2-weighted signal intensity. At weeks 1 and 3, MRI examinations showed regenerative changes in the PRP-BMSC group and PRP group, whereas the PBS group exhibited a continuous degenerative process of the discs. At 8 weeks post-injection, the PRP-BMSCs induced a statistically significant restoration of discs, as shown by MRI (PRP-BMSCs, vs. PRP and PBS; $P < 0.05$), which was also confirmed by histological evaluations. Thus, compared with

PRP, the administration of PRP-containing BMSCs resulted in a superior regenerative effect on the early degenerated discs, which may be a promising therapeutic strategy for the restoration of early degenerated discs.

Introduction

Intervertebral disc degeneration (IDD), a major cause of lower back pain, is a serious problem with substantial financial and health care implications worldwide (1,2). Current clinical treatments for IDD include conservative approaches and spinal surgery. Conservative treatments, including non-steroidal anti-inflammatory drugs and physiotherapy, can often alleviate the pain, however, the degenerative process of IDD cannot be reversed (3). Spinal surgery to remove the degenerated discs and fuse the adjacent spinal segments may cause increased degeneration and instability of the neighboring discs (4). Biological strategies for IDD have been developed with promising prospects (5), and the injection of active substances into the early degenerated disc has been suggested to be an ideal approach for IDD regeneration (6).

The commonly applied active substances in IDD include a variety of growth factors with potent effects on cell proliferation and extracellular matrix (ECM) synthesis (7-9). Currently, PRP, a growth factor cocktail, is suggested as the ideal approach for early IDD regeneration (10). PRP is a fraction of whole blood with a platelet concentration above baseline (11). When activated, multiple growth factors, including transforming growth factor (TGF)- β 1, insulin-like growth factor-1, platelet-derived growth factor, vascular endothelial growth factor and epidermal growth factor are released from α -granules of platelets, with regenerative effects (12). However, the short half-life of growth factors may prohibit the continuous regenerative process of IDD (11).

Cell transplantation is also an ideal approach for IDD regeneration (13). Bone marrow-derived mesenchymal stem cells (BMSCs), as a potential substitute for native disc cells, represents another biological strategy to restore the degenerated discs (14). BMSCs are capable of long-term self-renewal and differentiation into other cell lineages, exhibiting potent proliferation and differentiation potential (15). BMSCs are

Correspondence to: Professor Chen Wang, Department of Orthopaedics, Zhongda Hospital, Medical School of Southeast University, 87 Ding Jia Qiao Road, Nanjing, Jiangsu 210009, P.R. China
E-mail: wangchen_seu_edu@163.com

*Contributed equally

Key words: intervertebral disc degeneration, platelet-rich plasma, bone marrow-derived mesenchymal stem cells, rabbit

reported to have the ability to survive and proliferate within the micro-environment of degenerated discs, which offers potential for the continuous restoration of their normal structure and function (16). Considering these factors, the present study hypothesized that the administration of PRP-containing BMSCs into degenerated discs may have a synergistic regenerative effect on the degenerated discs.

The overall purpose of the present study was to investigate the regenerative effect of PRP-containing BMSCs on early degenerated discs *in vivo*. To achieve this aim, histological and magnetic resonance imaging (MRI) evaluations were used to monitor changes in the treated discs.

Materials and methods

Laboratory animals and groups. All experimental procedures involving animals in the present study conformed with the National Institutes of Health Guidelines for the Care and Use of Laboratory Animals, and were approved by the Administration Committee of Experimental Animals (Jiangsu, China). A total of 40 male adult New Zealand white rabbits (weight, 2.5-3.0 kg; age, ~3 months) were purchased from the Jiangsu Academy of Agricultural Sciences (Jiangsu, China) for use in the present study. The rabbits were maintained in cages at the Animal Center of Southeast University (Nanjing, China) at 24°C under a 12-h light/dark cycle with *ad libitum* access to food and water. A total of 30 rabbits were used to establish IDD models, and were subsequently randomly divided into three groups: 200 μ l PRP or phosphate-buffered saline (PBS; Sigma-Aldrich, St. Louis, MO, USA) were injected into the degenerated discs (PRP group and PBS group, respectively) using a 26-gauge needle; 200 μ l PRP-containing BMSCs was also injected (PRP-BMSC group). Another 10 rabbits without intervention were used as the control group. The present study was approved by the ethics committee of Southeast University.

Isolation, culture and characterization of BMSCs. The BMSCs were isolated from a New Zealand white rabbit, as described previously (17). Briefly, 2 ml iliac bone marrow was collected from the rabbits and immediately mixed with 2 ml PBS. Following size-fractionation using a Ficoll-Paque Plus (1.077 g/ml; GE Healthcare Life Sciences, Shanghai, China), BMSCs were isolated by centrifugation at 400 x g for 30 min at room temperature. The isolated BMSCs were seeded (10^5 cells/cm²) into a 25 cm² culture flask (Corning, Inc., Acton, MA, USA), and cultured in Dulbecco's modified Eagle's medium with low glucose (DMEM-LG; Gibco; Thermo Fisher Scientific, Inc., Waltham, MA, USA), supplemented with 10% (v/v) fetal bovine serum (FBS; Wisent., Inc., St-Jean-Baptiste, QC, Canada) at 37°C under a 5% CO₂ atmosphere. The culture medium was replaced every 2-3 days and BMSCs after three passages were used in the present study. The expanded BMSCs were induced towards adipogenic, osteogenic and chondrogenic lineages, as previously described (18).

Adipogenic differentiation induction. BMSCs (2×10^3 cells/cm²) at passage three were cultured in 6-well culture plates containing the adipogenic induction medium, which consisted of 10% (v/v) FBS, 200 μ M indomethacin,

0.5 mM 3-isobutyl-1-methylxanthine (IBMX) 1 μ M dexamethasone, 10 μ g/ml insulin (all: Cyagen Biosciences, Inc., Santa Clara, CA, USA) and DMEM-LG. The culture medium was changed every 3-4 days. After 4 weeks of induction, the formation of oil droplets was tested using Oil Red O staining, in which the induced BMSCs were fixed in 70% ethanol for 10 min and stained with 0.3% fresh Oil Red O solution (Sigma-Aldrich) for 2 h prior to observation under a microscope (Leica DMRXA2; Leica Microsystems GmbH, Wetzlar, Germany).

Osteogenic differentiation induction. BMSCs (2×10^3 cells/cm²) at passage three were cultured in 6-well culture plates containing the osteogenic induction medium, which consisted of 10% (v/v) FBS, 100 nM dexamethasone, 10 mM β -glycerophosphate (Sigma-Aldrich), 0.05 mM ascorbic acid (Sigma-Aldrich) and DMEM-LG. The culture medium was changed every 3-4 days. After 4 weeks of induction, the formation of calcium nudes were examined by Alizarin red staining, in which the induced BMSCs were fixed with 70% ethanol for 10 min and stained with 0.5% alizarin red solution (pH 4.1; Sigma-Aldrich) for 2 h, prior to observation under a microscope (Leica DMRXA2).

Chondrogenic differentiation induction. A pellet culture system was applied to confirm the chondrogenesis of the isolated BMSCs. Briefly, 2.5×10^5 cells were centrifuged at 450 x g for 10 min at room temperature to form a small pellet and cultured in 15 ml polypropylene tubes (Sigma-Aldrich). The chondrogenic induction medium, including 10 nM dexamethasone, 10 ng/ml TGF- β 3 (Cyagen Biosciences, Inc.), 50 mg/ml ascorbic acid and 50 mg/ml ITS+Premix (Cyagen Biosciences, Inc.) in DMEM with high glucose was used, and replaced every 3 days. Following culturing in the chondrogenic induction medium at 37°C under a 5% CO₂ atmosphere for 4 weeks, the pellets were fixed in formalin (Sigma-Aldrich) and sectioned for staining with 1% toluidine blue solution (Seebio Biotech, Inc., Shanghai, China) for 2 h. Following washing with PBS, the sections were mounted using neutral gum (China Sinopharm International, Co., Ltd., Shanghai, China) for observation under a microscope (Leica DMRXA2).

Preparation of autologous PRP and the PRP-BMSC mixture. The PRP was prepared, according to a method described by Landesberg *et al* (19) with modifications. Briefly, under general anesthesia with pentobarbitone sodium (30 mg/kg; Sigma-Aldrich), 6 ml fresh blood was obtained from the central artery of the rabbits ear using a syringe containing 0.6 ml acid citrate dextrose-A solution (Kermel Chemical Reagent Co., Ltd., Tianjin, China) as an anticoagulant. Subsequently, 0.2 ml whole blood was obtained to perform a platelet count. The obtained whole blood was primarily centrifuged by a centrifuge (SC-04; Zhongke Meiling Cryogenics Co., Ltd., Hefei, China) at 200 g for 10 min. Subsequently, the plasma fraction was collected and further centrifuged at 1,000 g for another 10 min. The upper three-quarters of supernatant plasma was carefully removed, and the remaining plasma and platelets were gently agitated and designated as PRP (~0.6 ml). Subsequently, 0.2 ml of the prepared PRP was drawn for platelet counting, and the remaining PRP (~0.4 ml) was retained for further use. To prepare the PRP-BMSC mixture, the BMSCs were trypsinized (Sigma-Aldrich) and

diluted in PBS to 1×10^6 cells/ml, and 0.2 ml volumes of cell suspension were carefully mixed with the previously prepared PRP (~0.4 ml).

Establishment and evaluation of IDD models in rabbits. The rabbit lumbar IDD models of the PRP, PBS and PRP-BMSC groups were established by needle puncture into the annulus fibrosis (Fig. 1). Briefly, under general anesthesia, the L4-5 and L5-6 lumbar discs were exposed using a contralateral side approach under a sterile environment. Following puncture of the discs with a 21-gauge needle to the depth of 5 mm, the surgical wound was immediately sutured. To confirm early degeneration of the punctured discs, the spines of the rabbits were evaluated using a 3.0-T MRI scan 2 weeks following post-needle puncture), the targeted discs were exposed again for the respective treatments. At weeks 1, 2, and 8 following the different treatments, the targeted discs of the groups were scanned using 3.0-T MRI. At week 8 following intervention, the rabbits in each group were sacrificed by intravenous injection with an overdose of pentobarbitone sodium (120 mg/kg). The vertebral body-disc-vertebral units of the targeted segments were carefully cut off and fixed in 10% (v/v) formalin in neutral buffer for paraffin (Sigma-Aldrich) embedding. The paraffin blocks were sectioned at a thickness of 5 μ m. Type II collagen immunohistochemistry and hematoxylin and eosin (H&E; Sigma-Aldrich) staining were performed to evaluate the histological changes in the treated discs. At 200x magnification, five visual fields were randomly selected from each sample for evaluation under a microscope (Leica DMRXA2). The Image-Pro Plus 6.0 image analysis system (Media Cybernetics, Inc., Rockville, MD, USA) was utilized to analyze the integrated absorbance (IA) value of the yellow-stained type II collagen.

MRI evaluation. MRI was performed using a 3.0T imager unit (Verio 3.0T MR; Siemens Medical Solutions, Erlangen, Germany). Following general anesthesia with pentobarbitone sodium (30 mg/kg), the rabbits were placed in the supine position on a quadrature surface coil for MRI scanning. The parameters of the T2-weighted images were as follows: Time-to-repeat=1,800 ms; time-to-echo=71 ms; field of view=140x140 mm; slice thickness=2 mm; averages=9; image matrix=288x384. The signal intensity of the discs was evaluated using T2-weighted images. IDD grade was evaluated using the modified Thompson classification (20) of grades I-IV, as follows. Grade I, normal signal intensity; grade II, minimal decreased signal intensity without obvious narrowing of high signal area; grade III, moderate decrease of signal intensity; grade IV, severe decrease of signal intensity. Two senior radiologists evaluated the images to reach a consensus.

Statistical analysis. Statistical analysis was performed using SPSS 20.0 software (IBM SPSS, Armonk, NY, USA). Data of all treatment groups are presented as the mean \pm standard error of the mean and were analyzed using one way analysis of variance. Pairwise comparisons were analyzed using a Student-Newman-Kuells test. The level data of the MRI images were analyzed using a Mann-Whitney U-test. $P < 0.05$ was considered to indicate a statistically significant difference.

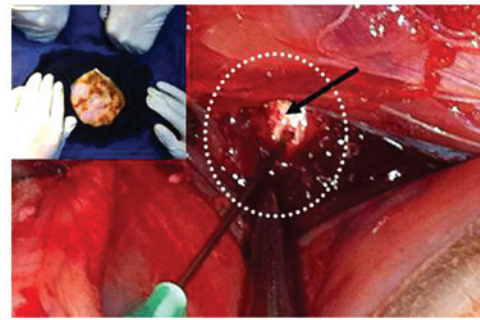


Figure 1. Intervertebral disc degeneration model in rabbits induced by annulus needle puncture. Under general anesthesia (upper left), the white intervertebral disc (black arrow) of the rabbit was exposed and then punctured with a needle (21-gauge) to undermine the integrity of the annulus.

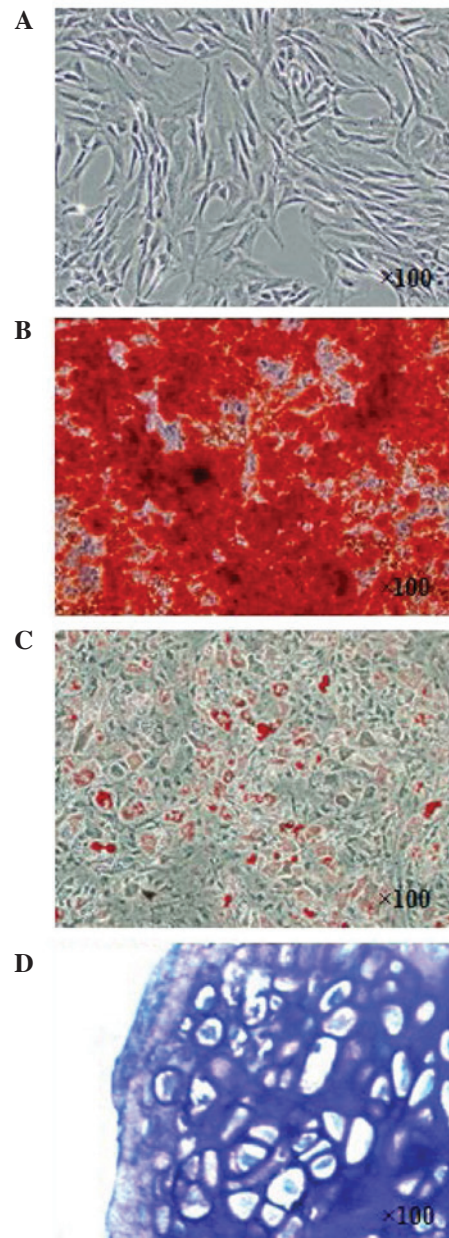


Figure 2. Isolation and characterization of BMSCs. (A) BMSCs after two passages (magnification, x100). (B) Alizarin red staining (magnification, x100). (C) Oil Red O staining (magnification, x100). (D) Toluidine blue staining (magnification, x200). BMSCs, bone marrow-derived mesenchymal stem cells.

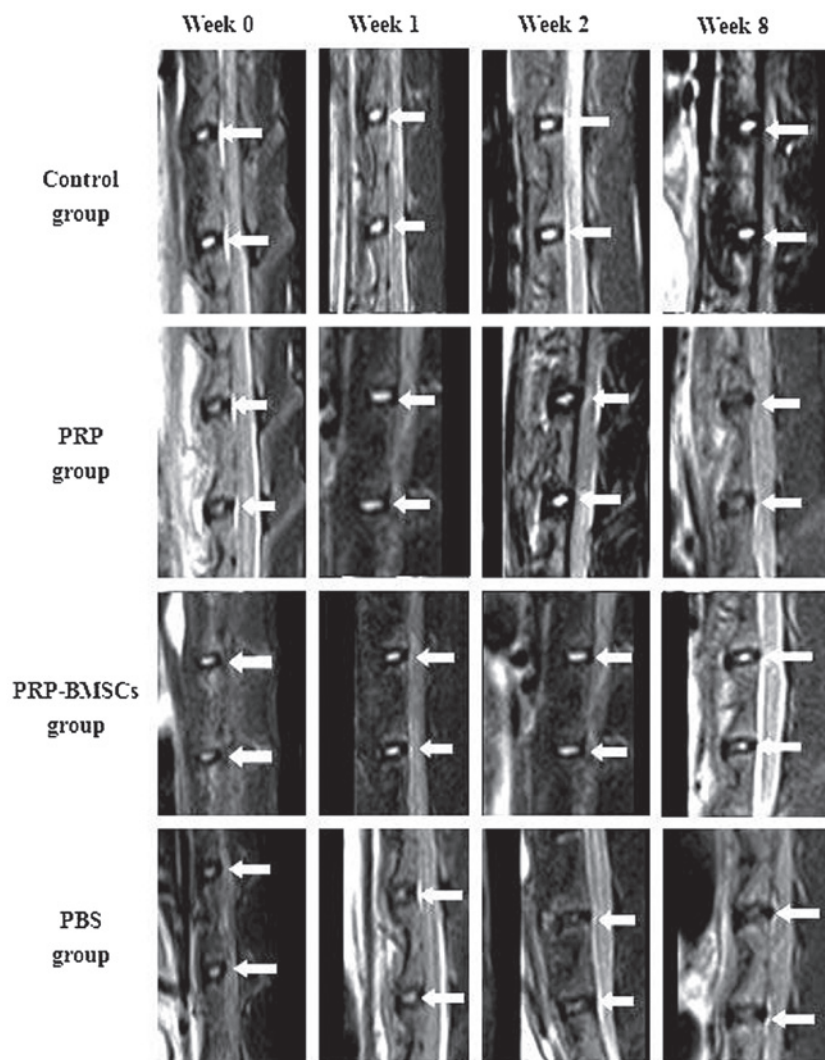


Figure 3. MRI evaluation of targeted discs at each time point. The MRI T2-weighted signal intensity of intervertebral discs in the PRP and PBS groups decreased significantly 8 weeks following injection, whereas the targeted discs in the PRP-BMSC groups showed maintained signal intensity, which was similar to that in the control group. White arrows indicate the signal intensity area. PBS, phosphate-buffered saline; PRP, platelet-rich plasma; BMSCs, bone marrow-derived mesenchymal stem cells; MRI, magnetic resonance imaging.

Results

Characterization of isolated BMSCs. At 3 weeks post-induction, the isolated BMSCs (Fig. 2A) were successfully induced toward adipogenic, osteogenic and chondrogenic lineages. The osteogenic differentiation potential of the isolated BMSCs was confirmed using Alizarin-red staining (Fig. 2B). Lipid droplets were formed and confirmed using Oil Red O staining (Fig. 2C). As for chondrogenic induction of the BMSCs, the cell pellets sectioned for toluidine blue staining (Fig. 2D) were positive, indicating the chondrogenic potential of the isolated BMSCs.

Platelet concentration of the PRP. The platelet concentration of the prepared PRP was $776 \pm 48 \times 10^9/l$, whereas the concentration in the whole blood was only $159 \pm 21 \times 10^9/l$. The PRP prepared in the present study contained almost five times the number of platelets in the whole blood.

MRI evaluation. Representative sagittal MRI images showed the variation of the targeted discs with high T2-weighted signal

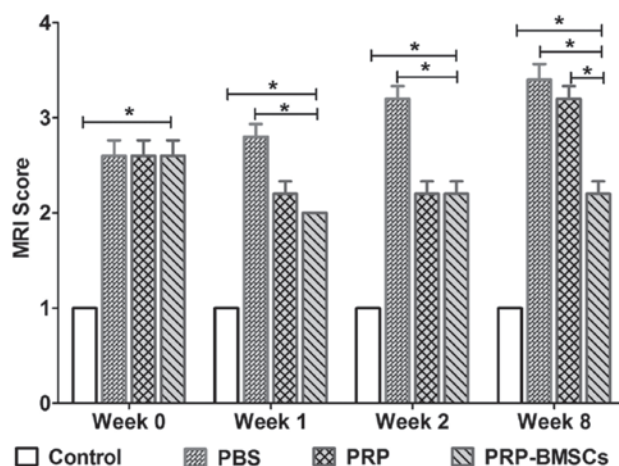


Figure 4. Mean MRI scores (modified Thompson classification) of targeted discs in the PRP, PRP-BMSCs, PBS and control groups at weeks 0, 1, 2 and 8. Level data of the MRI images were analyzed using a Mann-Whitney U-test. * $P < 0.05$. Data are presented as the mean \pm standard error of the mean. PBS, phosphate-buffered saline; PRP, platelet-rich plasma; BMSCs, bone marrow-derived mesenchymal stem cells; MRI, magnetic resonance imaging.

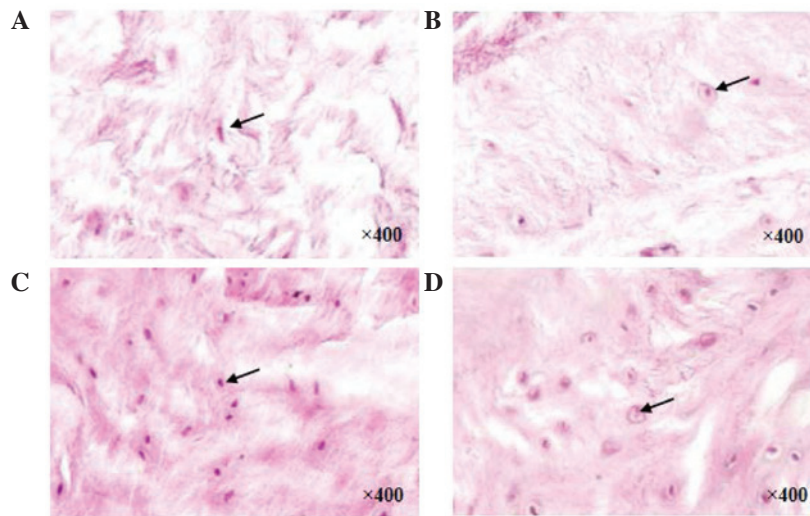


Figure 5. H&E staining of targeted discs at week 8 (magnification x400). H&E staining of the discs showed loss of ECM and cell density in the (A) PRP group and (B) PBS group at week 8. ECM and cell density were well restored and preserved in the (C) PRP-bone marrow-derived mesenchymal stem cell group, which was similar to that in the (D) control group. Black arrows indicate the stained cells. H&E, hematoxylin and eosin; ECM, extracellular matrix; PBS, phosphate-buffered saline; PRP, protein-rich plasma.

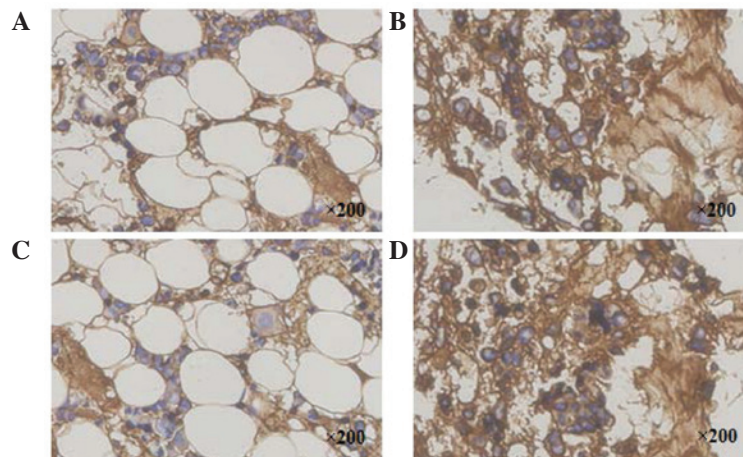


Figure 6. Type II collagen immunohistochemistry staining of discs at week 8 (magnification x200). The staining of the discs showed loss of type II collagen in the (A) PRP group. Type II collagen was well preserved in the (B) PRP-BMSC group. Loss of type II collagen was observed in the (C) PBS group. The staining in the PRP-BMSC group was similar to that in the (D) control group. PBS, phosphate-buffered saline; PRP, protein-rich plasma; BMSC, bone marrow-derived mesenchymal stem cell.

intensity in all groups (Fig. 3). T2 signal intensity was stable at each time point in the control group. At 2 weeks following needle puncture (week 0), the injected discs experienced mild signal loss. The treated discs of the PBS group experienced continuous T2 signal loss during the 8-week period, whereas the discs in the PRP-BMSC group showed an increase in signal intensity over time. PRP exhibited a regenerative effect on the degenerated discs at 1 and 2 weeks following treatment by increasing the signal intensity. However, at week 8 post-treatment, the discs of the PRP group exhibited decreased signal intensity. To determine the degenerative changes of the targeted discs, the mean MRI score of each group was presented (Fig. 4). At weeks 1 and 2, no significant differences were found in the MRI grading between the PRP and PRP-BMSC groups ($P < 0.05$). At week 8, the PRP-BMSC group showed a significantly higher MRI grading score, compared with the PRP group ($P < 0.05$).

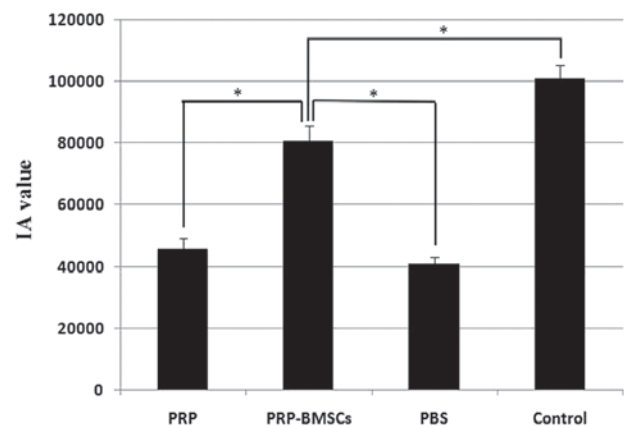


Figure 7. IA values of type II collagen at week 8. IA values were determined in the PRP, PRP-BMSC, PBS and control groups at week 8. * $P < 0.05$. IA, integrated absorbance; PBS, phosphate-buffered saline; PRP, protein-rich plasma; BMSC, bone marrow-derived mesenchymal stem cell.

H&E staining assessment. In the control group, discs without any interventions exhibited a high density of ECM. At 8 weeks following the different treatments, the discs in the PRP (Fig. 5A) and PBS (Fig. 5B) groups exhibited decreased ECM. In the PRP-BMSC group (Fig. 5C), ECM and cell density were well preserved, however, fewer NP cells were observed in the PRP and PBS groups, compared with the control group (Fig. 5D).

Immunohistochemical staining of type II collagen. Representative immunohistochemistry of type II collagen staining exhibited brown staining. The type II collagen staining of the targeted discs in the PRP group (Fig. 6A) became weakly positive, whereas the staining in the PRP-BMSC group (Fig. 6B) was strongly positive at week 8. As with the PRP group, the staining in the PBS group (Fig. 6C) became weakly positive at week 8, whereas staining in the control group was strongly positive (Fig. 6D). The IA values of the control group (100910.06 ± 4319.57) and PRP-BMSC group (80620.30 ± 5030.62) were significantly higher, compared with those of the PRP group (45682.05 ± 3501.89) and PBS group (43768.22 ± 2275.67), as shown in Fig. 7 ($P < 0.05$).

Discussion

The present study investigated the efficacy of PRP-containing BMSCs on the regeneration of early degenerated discs induced by needle puncture. The results of the present study demonstrated that the injection of PRP-containing BMSCs was effective in restoring the early degenerated discs on histological evaluation. MRI examination at different time points revealed the reparative effects of the PRP-BMSCs on the early degenerated discs.

Currently, there remains no comprehensively accepted classification standard of IDD. Thompson *et al.* (21) suggested a grading system, according to the gross morphology of the human intervertebral discs (IVDs). Subsequently, Pfirrmann *et al.* (22) established a new grading system of IDD, based on MRI (modified Thompson classification). In these two grading systems, normal IVD is defined as grade I. As the severity of the degeneration increases, the degeneration increases between grades II and V. Zhang *et al.* (23) suggested IDD grades II and III be defined as early stage IDD. In the present study, the efficacy of 21-gauge needle puncture in inducing the early degeneration of IVD was confirmed using the modified Thompson classification. The results revealed that the 21-gauge needle induced more severe degeneration of the punctured discs, compared with that of a previous study reported by Masuda *et al.* (20). However, the rabbits used in the present study weighed less, suggesting the discs were of smaller size, which may be the cause of the inconsistent result.

PRP is a small fraction of the plasma with a high platelet concentration. The regenerative effect of PRP is based on its growth factor cocktail effect (24,25). BMSCs, as a promising therapeutic strategy, have also been widely investigated in IDD repair and regeneration (26). The results of the present study indicated that the combined use of PRP and BMSCs exerted a superior effect, compared with the use of PRP alone. Over the 8 week period, MRI T2 signal intensity was well maintained in the PRP-BMSC group, whereas this signal intensity was lower

in the PRP group at week 8. However, at week 2, the regenerative effect of PRP was similar to that of the PRP-BMSCs, as indicated by MRI. These variations in IDD regeneration may be a result of the following pathways.

Firstly, subsequent to the intradiscal injection of the PRP-BMSCs, the activation of PRP contributed to the release of multiple bio-active growth factors, which assisted in promoting the restoration of the degenerated discs for the initial 2 weeks. During this period, the proliferation and migration of the BMSCs embedded in the PRP did not exhibit such a significant regenerative effect. However, with degradation of the growth factors, PRP did not maintain this regenerative effect, whereas BMSCs proliferated to continuously repair the degenerated discs.

Secondly, the injected PRP may have been activated by the surrounded tissue, which formed a three-dimensional scaffold for the BMSCs. Growth factors released from the PRP may effectively stimulate BMSCs to produce type II collagen and aggrecan, as indicated by a previous study of Xie *et al.* (27). The increased collagen may provide tensile strength and anchor the tissue to the bone, and aggrecan may contribute to high osmotic pressure for the absorption of water. Thus, the increased ECM may effectively assist in restoring the biological and mechanical functions of the degenerated discs.

Thirdly, the residual NP cells within the discs may interact with the injected BMSCs to repair the degenerated discs. In a previous *in vitro* study, Strassburg *et al.* (28) suggested that cellular interactions between MSCs and degenerate NP cells stimulate the endogenous degenerated NP cell population to regain a non-degenerate phenotype and consequently enhance matrix synthesis for self-repair. In addition, the BMSCs may also exhibit the NP-like phenotype with the stimulation of NP cells.

In rabbit IDD models, Obata *et al.* (29) injected PRP-releasate into the degenerated discs, which contributed to the structural restoration of IVD over an 8-week period. These results were different from those of the present study, as PRP only exhibited a regenerative effect in the initial 2 weeks. However, similar to the present study, Nagae *et al.* (30) suggested that PRP alone was not able to effectively suppress the degenerative trend of IDD. To slow the release of growth factors from PRP, PRP was injected within gelatin hydrogel microspheres (PRP-GHMs), therefore, the immobilized PRP was released in a gradual manner, accompanied by degradation of the microspheres (31). The PRP-GHMs exhibited a superior regenerative effect, compared with PRP alone. However, the different processing methods of the PRP and IDD models in the present study may account for the conflicting results.

A limitation of the present study is that the rabbit IDD model used does not reflect the natural course of human IDD. In addition, the PRP-containing BMSCs were effective in the early degenerated discs in the present study, however, whether this therapy can also be effective for severely degenerated discs remains to be fully elucidated. In the present study, the PRP-BMSCs were confirmed to exert a regenerative effect, however, the treated discs were not restored to the level of the normal discs in control group, following histological and radiographical evaluations within the 8 weeks. The regenerative trend induced by the PRP-BMSCs in the long term remains to be elucidated. Currently, there is no comprehensively accepted

PRP preparation or evaluation method, and the quality of the PRP prepared using commonly applied laboratory centrifugation procedures is biased. Therefore, the present study provided preliminary support for PRP-containing BMSCs as a more effective alternative to PRP in the restoration of early degenerated discs.

In conclusion, the present study showed that the administration of autologous PRP-containing BMSCs was more effective than PRP alone in restoring early degenerated discs induced by annular needle puncture in a rabbit model. The PRP injected into the discs was activated by the surrounding tissue, and formed a three-dimensional scaffold for the proliferation and differentiation of BMSCs, maintaining a continuous regenerative effect. The results of the present study suggested that PRP-containing BMSCs offer an effective and promising therapeutic strategy for IVD regeneration, providing valuable information for the clinical use of PRP, based on BMSCs.

Acknowledgements

The present study was supported by the National Natural Science Foundation of China (grant no. 81572188) and the Jiangsu Provincial Special Program of Medical Science (grant no. BL 20122004).

References

- Dagenais S, Caro J and Haldeman S: A systematic review of low back pain cost of illness studies in the United States and internationally. *Spine J* 8: 8-20, 2008.
- McBeth J and Jones K: Epidemiology of chronic musculoskeletal pain. *Best Pract Res Clin Rheumatol* 21: 403-425, 2007.
- Mirza SK and Deyo RA: Systematic review of randomized trials comparing lumbar fusion surgery to nonoperative care for treatment of chronic back pain. *Spine* 32: 816-823, 2007.
- Karppinen J, Shen FH, Luk KD, Andersson GB, Cheung KM and Samartzis D: Management of degenerative disk disease and chronic low back pain. *Orthop Clin North Am* 42: 513-528, 2011.
- Zhang Y, Chee A, Thonar EJ and An HS: Intervertebral disk repair by protein, gene, or cell injection: a framework for rehabilitation-focused biologics in the spine. *PM R* 3 (6 Suppl 1): S88-S94, 2011.
- Masuda K: Biological repair of the degenerated intervertebral disc by the injection of growth factors. *Eur Spine J* 17 (Suppl 4): S441-S451, 2008.
- Xie X, Zhang C and Tuan RS: Biology of platelet-rich plasma and its clinical application in cartilage repair. *Arthritis Res Ther* 16: 204, 2014.
- Finnson KW, McLean S, Di Guglielmo GM and Philip A: Dynamics of transforming growth factor beta signaling in wound healing and scarring. *Adv Wound Care (New Rochelle)* 2: 195-214, 2013.
- Spencer EM, Tokunaga A and Hunt TK: Insulin-like growth factor binding protein-3 is present in the alpha-granules of platelets. *Endocrinology* 132: 996-1001, 1993.
- Longo UG, Petrillo S, Franceschetti E, Maffulli N and Denaro V: Growth factors and anticatabolic substances for prevention and management of intervertebral disc degeneration. *Stem Cells Int* 2012: 897183, 2012.
- Wang SZ, Rui YF, Tan Q and Wang C: Enhancing intervertebral disc repair and regeneration through biology: Platelet-rich plasma as an alternative strategy. *Arthritis Res Ther* 15: 220, 2013.
- Marx RE: Platelet-rich plasma (PRP): What is PRP and what is not PRP? *Implant Dent* 10: 225-228, 2001.
- Huang YC, Leung VY, Lu WW and Luk KD: The effects of microenvironment in mesenchymal stem cell-based regeneration of intervertebral disc. *Spine J* 13: 352-362, 2013.
- Benneker LM, Andersson G, Iatridis JC, Sakai D, Härtl R, Ito K and Grad S: Cell therapy for intervertebral disc repair: Advancing cell therapy from bench to clinics. *Eur Cell Mater* 27: 5-11, 2014.
- Ikehara S and Li M: Stem cell transplantation improves aging-related diseases. *Front Cell Dev Biol* 2: 16, 2014.
- Sakai D: Stem cell regeneration of the intervertebral disk. *Orthop Clin North Am* 42: 555-562, 2011.
- Cai F, Wu XT, Xie XH, Wang F, Hong X, Zhuang SY, Zhu L, Rui YF and Shi R: Evaluation of intervertebral disc regeneration with implantation of bone marrow mesenchymal stem cells (BMSCs) using quantitative T2 mapping: A study in rabbits. *Int Orthop* 39: 149-159, 2015.
- Schilling T, Nöth U, Klein-Hitpass L, Jakob F and Schütze N: Plasticity in adipogenesis and osteogenesis of human mesenchymal stem cells. *Mol Cell Endocrinol* 271: 1-17, 2007.
- Landesberg R, Roy M and Glickman RS: Quantification of growth factor levels using a simplified method of platelet-rich plasma gel preparation. *J Oral Maxillofac Surg* 58: 297-300, 2000.
- Masuda K, Aota Y, Muehleman C, Imai Y, Okuma M, Thonar EJ, Andersson GB and An HS: A novel rabbit model of mild, reproducible disc degeneration by an annulus needle puncture: Correlation between the degree of disc injury and radiological and histological appearances of disc degeneration. *Spine (Phila Pa 1976)* 30: 5-41, 2005.
- Thompson JP, Pearce RH, Schechter MT, Adams ME, Tsang IK and Bishop PB: Preliminary evaluation of a scheme for grading the gross morphology of the human intervertebral disc. *Spine* 15: 411-415, 1990.
- Pfirrmann CW, Metzendorf A, Zanetti M, Hodler J and Boos N: Magnetic resonance classification of lumbar intervertebral disc degeneration. *Spine* 26: 1873-1878, 2001.
- Zhang Y, Chee A, Thonar EJ and An HS: Intervertebral disk repair by protein, gene, or cell injection: A framework for rehabilitation-focused biologics in the spine. *PM R* 3 (6 Suppl 1): S88-S94, 2011.
- Fréchet JP, Martineau I and Gagnon G: Platelet-rich plasmas: Growth factor content and roles in wound healing. *J Dent Res* 84: 434-439, 2005.
- Abrams GD, Frank RM, Fortier LA and Cole BJ: Platelet-rich plasma for articular cartilage repair. *Sports Med Arthrosc* 21: 213-219, 2013.
- Wang SZ, Rui YF, Lu J and Wang C: Cell and molecular biology of intervertebral disc degeneration: Current understanding and implications for potential therapeutic strategies. *Cell Prolif* 47: 381-390, 2014.
- Xie X, Wang Y, Zhao C, Guo S, Liu S, Jia W, Tuan RS and Zhang C: Comparative evaluation of MSCs from bone marrow and adipose tissue seeded in PRP-derived scaffold for cartilage regeneration. *Biomaterials* 33: 7008-7018, 2012.
- Strassburg S, Richardson SM, Freemont AJ and Hoyland JA: Co-culture induces mesenchymal stem cell differentiation and modulation of the degenerate human nucleus pulposus cell phenotype. *Regen Med* 5: 701-711, 2010.
- Obata S, Akeda K, Imanishi T, Masuda K, Bae W, Morimoto R, Asanuma Y, Kasai Y, Uchida A and Sudo A: Effect of autologous platelet-rich plasma-releasate on intervertebral disc degeneration in the rabbit annular puncture model: A preclinical study. *Arthritis Res Ther* 14: R241, 2012.
- Nagae M, Ikeda T, Mikami Y, Hase H, Ozawa H, Matsuda K, Sakamoto H, Tabata Y, Kawata M and Kubo T: Intervertebral disc regeneration using platelet-rich plasma and biodegradable gelatin hydrogel microspheres. *Tissue Eng* 13: 147-158, 2007.
- Sawamura K, Ikeda T, Nagae M, Okamoto S, Mikami Y, Hase H, Ikoma K, Yamada T, Sakamoto H, Matsuda K, *et al*: Characterization of in vivo effects of platelet-rich plasma and biodegradable gelatin hydrogel microspheres on degenerated intervertebral discs. *Tissue Eng Part A* 15: 3719-3727, 2009.