

Tension Bullae With Peripheral Pneumothorax

Journal of Investigative Medicine High
Impact Case Reports
Volume 8: 1–3
© 2020 American Federation for
Medical Research
DOI: 10.1177/2324709620963646
journals.sagepub.com/home/hic


Tushar Bajaj, MD¹ , Bushra Malik, MS¹,
and Sudhagar Thangarasu, MD, FACP¹ 

Abstract

The differentiation between tension bullae, chronic tension pneumothorax, and atypical pneumothorax is difficult just from history and physical examination alone. A chest X-ray may help determine the underlying etiology; however, further imaging with computed tomography in stable patients may be necessary for accurate assessment of size, number, and location before considering any interventions. In this article, we present a rare case report of tension bullae with peripheral pneumothorax and recommend against needle thoracostomy in stable patients with tension bullae in order to obtain further imaging that may result in a change in the standard management.

Keywords

pneumothorax, tension bullae, pulmonary, imaging, education

Case Presentation

A 49-year-old male smoker presented to the emergency department complaining of chest pain and progressive dyspnea for the past 4 days. The chest pain was constant, sharp, nonradiating in nature noticed over both sides of the chest. The pain progressively worsened over time and with deep inspiration. The patient has a 10 pack-year smoking history.

On arrival his heart rate was 119 beats/minute, respiratory rate 23 breaths/minute, blood pressure 109/59 mm Hg, and peripheral capillary oxygen saturation of 84% on room air. Chest examination revealed diminished breath sounds and increased resonance on the left thorax. His jugular venous pressure measured up to 12 cm of H₂O.

Laboratory results were significant for white blood cell count of 12 200/μL, absolute neutrophil count of 10 300/μL, bands 8%, hemoglobin 16.1 g/dL, hematocrit 47%, platelets 247 000/μL, sodium 125 mEq/L, potassium 4.3 mEq/L, chloride 91 mEq/L, bicarbonate 24 mEq/L, blood urea nitrogen 18 mg/dL, creatinine 0.99 mg/dL, glucose 114 mg/dL, albumin 2.7 g/dL, and calcium of 8.1 mg/dL. Troponins were negative. Lactic acid was 1.7 mmol/L. A stat chest X-ray revealed the entire left lung occupied by thin-walled bullae, left-to-right mediastinal shift, heterogeneous opacification of the right upper lobe, and a 1-cm nodule in the right mid-zone (Figure 1). Subsequently, computed tomography (CT) with contrast of the chest was obtained which revealed giant bullae in the hemithorax, atelectasis of the left lower lobe, peripheral pneumothorax in posterior medial sulcus as well as the anterolateral base

of the hemithorax, marked mediastinal shift to the right, and consolidation with bronchiectasis in the right upper/middle/lower lobes (Figure 2). Thoracic Surgery was consulted for a video-assisted thoracoscopy for distinguishing the etiology of tension from giant bullae versus undiagnosed chronic tension pneumothorax and possible bullectomy. The patient was found to have tension giant bullae and underwent bullectomy.

Discussion

Giant bullous emphysema (GBE) is defined as the enlargement of one bulla or more bullae, which occupies greater than one third of the hemithorax unilateral or bilaterally destroying the pulmonary architecture, predominantly involving the upper lobe. It is a rare radiological, progressive condition first described by Burke in 1937 as vanishing lung syndrome, where the lungs appear to be disappearing on X-ray.¹ The giant bullae can form slowly by gradually filling with air, or they may rapidly enlarge and progress into tension bullae. The pathophysiology behind this phenomenon involves mass

¹UCLA—Kern Medical, Bakersfield, CA, USA

Received April 24, 2020. Revised August 31, 2020. Accepted September 5, 2020.

Corresponding Author:

Tushar Bajaj, MD, Department of Medicine, Kern Medical Center, 1700 Mount Vernon Avenue, Bakersfield, CA 93306, USA.
Email: tusharbajajMD@gmail.com



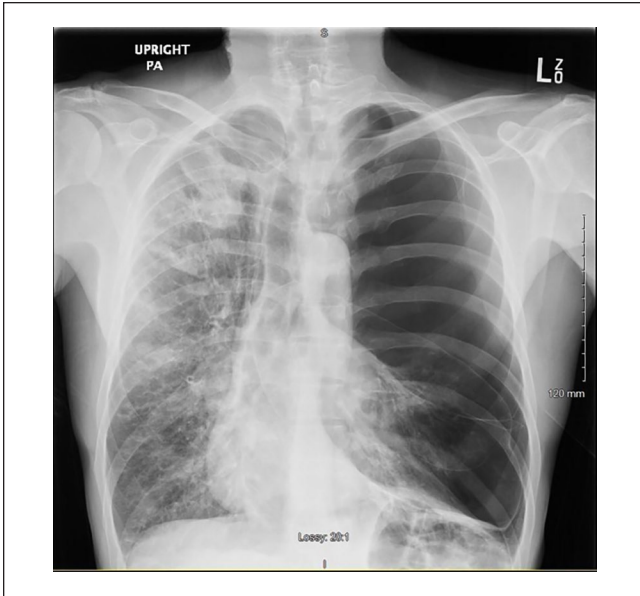


Figure 1. Upright posterior-anterior chest X-ray demonstrates the entire left lung occupied by thin-walled bullae, left-to-right mediastinal shift, heterogeneous opacification of the right upper lobe, and a 1-cm nodule in the right mid-zone.

effect on the underlying lung parenchyma and mediastinum comprising lung ventilation and gaseous exchange.² Pneumothorax on the other hand is a life-threatening condition that develops when air is trapped in the pleural space with subsequent lung collapse. In both of these conditions, the plain chest radiographs demonstrate black pleural space where lung markings are absent making it difficult to differentiate bullae from pneumothorax. Patients may present with dyspnea, hypoxia, chest pain and pressure, and or hemoptysis, which can be complicated by pneumothorax, infection of the bullae and respiratory failure.³ In this case, it was important to obtain further imaging promptly as performing a needle thoracostomy could lead to iatrogenic pneumothorax, hemothorax, shock, or even death as a consequence of unintentional needle placement. It is unclear in the current literature whether to perform immediate needle thoracostomy followed by a chest tube, perform a video-assisted thoracoscopy, or proceed to emergent bullectomy.

Kupferschmid et al recommend that in these unclear cases, a video-assisted thoracoscopy for establishing a diagnosis.⁴ Ferreira et al report a GBE patient mistaken for traumatic pneumothorax, who developed bilateral high-flow fistulas as a result of chest tube insertions prior to CT.³ Chest tube placement is contraindicated in patients with extensive pulmonary blebs or GBE due to risk of bronchial fistula formation. Bronchopleural fistula is the abnormal connection between the pleural space and the bronchial tree. It is a complication of chest tube placement and can be difficult to manage and is associated with high morbidity and mortality.⁵ Although our

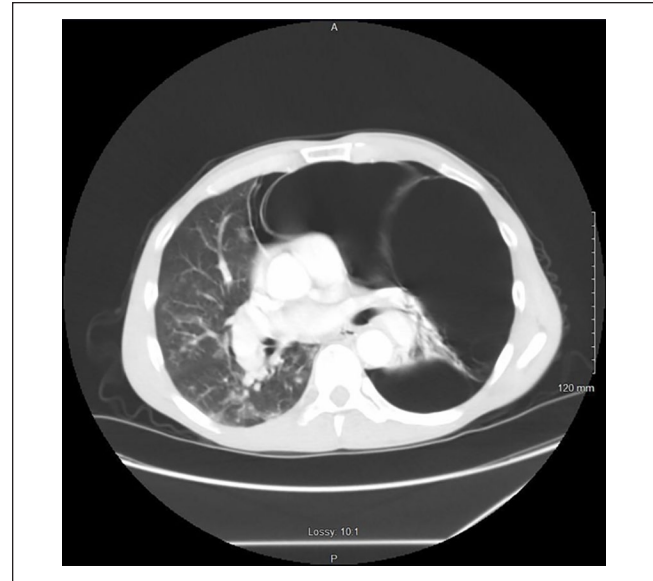

Figure 2. Computed tomography scan of chest with contrast demonstrates giant bullae in the hemithorax, atelectasis of the left lower lobe, peripheral pneumothorax in posterior medial sulcus as well as the anterolateral base of the hemithorax, marked mediastinal shift to the right, and consolidation with bronchiectasis in the right upper/middle/lower lobes.

patient was in moderate respiratory distress, based on our clinical judgment and hemodynamic stability, it was safe to perform CT before determining the next step in management. It remains clear that if the patient is unstable, in acute distress, a needle thoracostomy is the current standard of care. However, without imaging, it may be difficult to diagnose the underlying etiology of the patient's pathology.

In the case of the Gorlin-Goltz syndrome, a patient can present with a tension pneumothorax and then develop multiple bullae, which may eventually lead to lobectomy.⁶ In another case, a patient with a tension pneumothorax, with 2 chest drains, developed a giant bulla that was rapidly expanding with tension physiology, once again necessitating bullectomy.⁷ These 2 cases demonstrate, despite inserting emergent chest tubes, once the patient is stable, it is necessary to evaluate with further imaging. Figure 3 proposes an algorithm for patients and an informed calculated risk of performing a thoracostomy versus proceeding to a CT should be thoroughly explored.

Conclusion

In this case, the key step in diagnosis was elicited after the chest X-ray was performed; however, the imaging presented a diagnostic dilemma. As tension pneumothorax, atypical pneumothorax, and giant bullae can produce similar signs, symptoms, and radiological appearances, therefore, further imaging with a CT with contrast of the chest was necessary

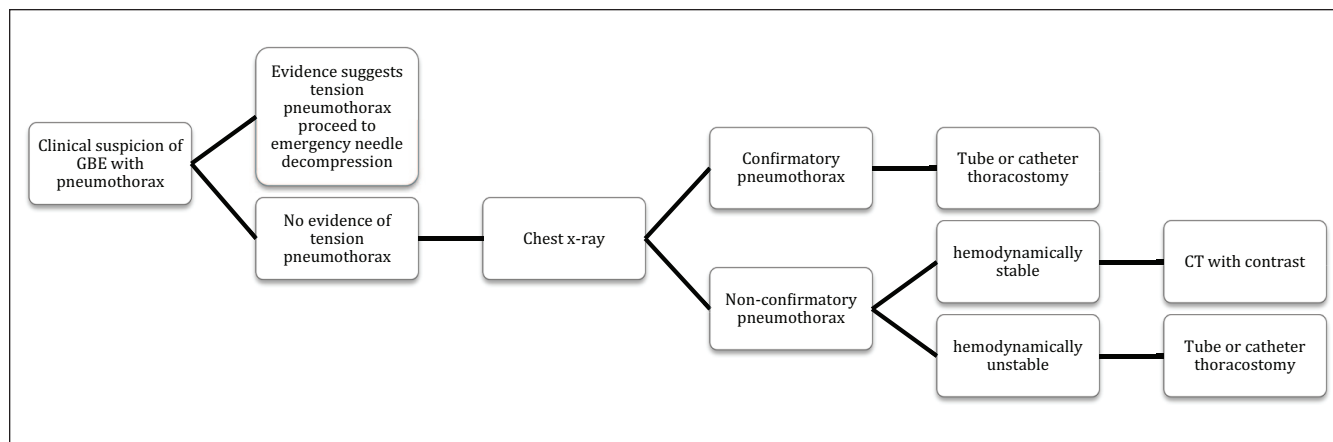


Figure 3. Algorithm for the clinical management of giant bullous emphysema with pneumothorax.

to determine the next step in management. We present a rare case report of tension bullae with peripheral pneumothorax and suggest early radiographical imaging for stable patients before considering invasive interventions.

Authors' Note

An abstract of this case report was published in *Journal of Investigative Medicine*. 2020;68(suppl 1):A1-A228.

Declaration of Conflicting Interests

The author(s) declared no potential conflicts of interest with respect to the research, authorship, and/or publication of this article.

Funding

The author(s) received no financial support for the research, authorship, and/or publication of this article.

Ethics Approval

Ethical approval to report this case was obtained from our institutional review board (IRB #19003).

Informed Consent

Written informed consent was obtained from the patient for their anonymized information to be published in this article.

ORCID iDs

Tushar Bajaj  <https://orcid.org/0000-0002-8863-9399>

Sudhagar Thangarasu  <https://orcid.org/0000-0002-1464-0709>

References

- Burke RM. Vanishing lungs: a case report of bullous emphysema. *Radiology*. 1937;28:367-371.
- Garg I, Agarwal KC, Gopal P, et al. Giant bulla or tension pneumothorax: diagnostic dilemma in emergency. *Chest*. 2016;150:929A.
- Ferreira EG Jr, Costa PA, Silveira LMFG, et al. Giant bullous emphysema mistaken for traumatic pneumothorax. *Int J Surg Case Rep*. 2019;56:50-54.
- Kupferschmid JP, Carr T, Fonger JD, Aldea GS, Vosburgh E. Chronic tension pneumothorax mimicking tension bullae. Use of video-assisted thoracoscopy for diagnosis. *Chest*. 1993;104:1913-1914.
- Kwiat M, Tarbox A, Seamon MJ, et al. Thoracostomy tubes: a comprehensive review of complications and related topics. *Int J Crit Illn Inj Sci*. 2014;4:143-155.
- Yap D. Gorlin-Goltz syndrome: first reported case of bullae in the lungs complicated with tension pneumothorax. *BMJ Case Rep*. 2018;2018:bcr2017223689.
- Waxman MJ, Waxman JD, Forman JM. Tension bulla: a cause of reversible pulmonary hypertension. *J Bronchology Interv Pulmonol*. 2015;22:69-72.