

# A New Horizontal Plane of the Head

Ehab El Kattan<sup>1\*</sup>, Mohamed El Kattan<sup>1</sup>, Omnia A. Elhiny<sup>2</sup>

<sup>1</sup>Faculty of Oral and Dental Medicine, Cairo University, Cairo, Egypt; <sup>2</sup>National Research Centre, Cairo, Egypt

## Abstract

**Citation:** El Kattan E, El Kattan M, Elhiny OA. A New Horizontal Plane of the Head. Open Access Maced J Med Sci. 2018 May 20; 6(5):767-771. <https://doi.org/10.3889/oamjms.2018.172>

**Keywords:** Cephalometrics; Frankfort Horizontal; True vertical; Natural head position

**\*Correspondence:** Ehab El Kattan, Faculty of Oral and Dental Medicine, Cairo University, Cairo, Egypt. E-mail: [ehabelkattan@windowslive.com](mailto:ehabelkattan@windowslive.com)

**Received:** 09-Jan-2018; **Revised:** 20-Mar-2018; **Accepted:** 24-Mar-2018; **Online first:** 19-May-2018

**Copyright:** © 2018 Ehab El Kattan, Mohamed El Kattan, Omnia A Elhiny. This is an open-access article distributed under the terms of the Creative Commons Attribution-NonCommercial 4.0 International License (CC BY-NC 4.0)

**Funding:** This research did not receive any financial support

**Competing Interests:** The authors have declared that no competing interests exist

**AIM:** This study aimed to attempt to introduce a new extracranial horizontal plane of the head (K plane that extends from SN to SAE bilaterally) that could act as a substitute to the Frankfort horizontal intracranial reference plane; both clinically and radiographically.

**MATERIAL AND METHODS:** The new K plane depended on three points of the head. The first was the soft tissue nasion (NS) on the interpupillary line when the subject looked forward at a distant point at eye level. The other two points were the superior attachments of the ears (SAE).

**RESULTS:** The student "t" test comparing mean values of K/V and FH/V was not significant; -0.21. The coefficient of correlation between different variables was highly positively significant ( $r = 0.98$  with probability = 0.001).

**CONCLUSION:** Within the limitations of this prospective study, the new K plane was found to be both reliable and reproducible. It can be used as a reliable reference plane instead of Frankfort horizontal plane both clinically and radiographically; as it is an accurate tool for head orientation in the natural head position.

## Introduction

Before the development of the roentgenographic cephalometric technique, anthropologists had studied and recorded craniofacial structures using direct craniometric techniques for many years. Brodbent, [1] in 1931 introduced a "new X-ray technique" which provided a standardised method of recording craniofacial structures. The Frankfort horizontal plane; a plane extending from left Orbitale to both Porion points, was officially defined in 1884 in the anthropologic conference in Frankfort, Germany. This plane had been accepted as the plane most reflective of the true horizontal when the patient's eyes were cast at the horizon [2] [3] [4] [5] [6] [7]. Initially, it was established as a craniometric reference plane for classification purposes. By the development of precise X-ray techniques, radiographic cephalometry became the natural extension of craniometry, and Frankfort horizontal was adopted as a reliable reference plane for cephalometric studies.

However, Krogman and Sussouni [8] claimed that defining Porion by cephalometric instrumentation might be brought by through possible error since the ear rod positioning and the "ear-hole size and inclination" were considerably variable. Downs [4] [5] [6] used Frankfort horizontal, in his cephalometric analysis, with the angle of the facial plane (N-Pog) to classify facial forms. He found that it was tipped upward anteriorly about +1.3°. Sassouni [10] also reported that the optic plane was tipped up anteriorly. Also, when Moorees and Kean [7] used the true vertical as an extracranial reference plane (with the patients in the natural head position); they found Frankfort Horizontal to be 92° to the true vertical opening postero-inferiorly. Some authors hence, believed that the patient positioning technique could be standardised with minimal error; [4] while others, because of reported low measurement reliability, favoured dropping Porion and thus Frankfort horizontal [2] [8].

The vestibular method of orientation, specifically by the lateral semicircular canals, has

perceived the attention of many researchers [3] [11] [12] [13].

De Beer [3] showed that most mammals, except man, maintained a head posture in the alert state with the lateral canals being parallel to the true horizontal. The man, however, does not exhibit an identical situation to animals. In fact, it has been shown that the lateral semicircular canals were canted down and back approximately  $30^\circ$  about Frankfort horizontal when a person was in the natural head posture with his eyes cast at the horizon [14] [15].

Lundstrom et al., [16] studied the accuracy and validity of the natural head orientation. They concluded that the extra-cranial reference line "sella-horizontal" should substitute, or at least supplement the use of intracranial reference lines for the cephalometric analysis of patients with malocclusion. They also recommended the use of estimated natural head orientation (NHO) performed by experienced clinicians, in addition to the natural head position concept.

Consequently, it was important to attempt to introduce a new extracranial horizontal plane of the head (K plane that extends from SN to SAE bilaterally) that combined anatomical points and the natural head position, at the same time. This plane was evaluated for its reliability and reproducibility as a clinical and radiographic substitute to the Frankfort horizontal intracranial reference plane.

## Material and Methods

The new plane (K plane) extended through three points on the head. The first was the soft tissue nasion (SN) on the interpupillary line; when the subject looked forward at a distant point at the eye level. The other two points were the superior attachments of the ears (SAE). The three points were confirmed by a metal frame "Orienter" which is a preformed three armed stainless steel wire with a cross-section of 1.5 mm; Figure 1. The frontal arm rested on the SN point (marked by a black wax pencil) and was secured in place by a scorching tape. The two lateral arms were perpendicular to the front arm and in the same horizontal plane. They could be adjusted according to the width of the face and rested on the SAE bilaterally. The metal Orienter is radio-opaque; this facilitated its identification in X-ray (Figure 2). The design of the front arm included two semicircles facing the eyes to clear the vision of the subject.

The sample of this prospective study consisted of 40 adult subjects (20 males and 20 females) with an age range of 18-24 years. They were orthodontic patients selected from the outpatient clinic

of Orthodontic Department, Faculty of Oral and Dental Medicine, Cairo University.




Figure 1: The Orienter

All subjects did not receive any previous orthodontic treatment and were free from any history of significant medical diseases. All the subjects signed informed consent. Lateral cephalometric radiographs were taken for each subject in the natural head position according to Solow and Tallgren, [17] except that the Orienter was fixed in place.

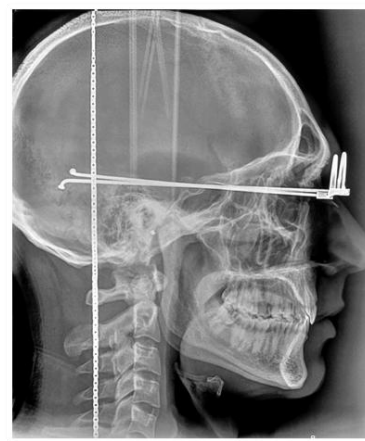


Figure 2: A Lateral cephalometric radiograph with the Orienter in place

## Clinical Procedure

- 1- The subjects were instructed to stand upright with their arms at their sides, looking straight forward at a distant point at the same level of their eyes. The SN point was identified by a black wax pencil between the forehead and the nasal bridge on the interpupillary line.
- 2- The Orienter was scotched in place over the mark; the two lateral arms rested on the SAE after their adjustment to fit the subject's facial width.
- 3- After the subjects oriented their heads in the natural head position (NHP), the posterior inferior angle between the lateral arm of the Orienter and the true vertical was measured by the plump line

method; according to Vig and associates<sup>(18)</sup> (weight hanging from a lead line or a metal chain on the center of a protractor, Figure 3).

4- The readings were recorded three times at 5-minute intervals, where the subjects were asked to tilt their heads during rest and then return to the NHP using the same procedure. The mean values of these angles were taken to establish the clinical orientation angle of the subjects.

5- The orientation angle of each subject was used to orient the subject's head during the cephalometric X-ray (Figure 3).

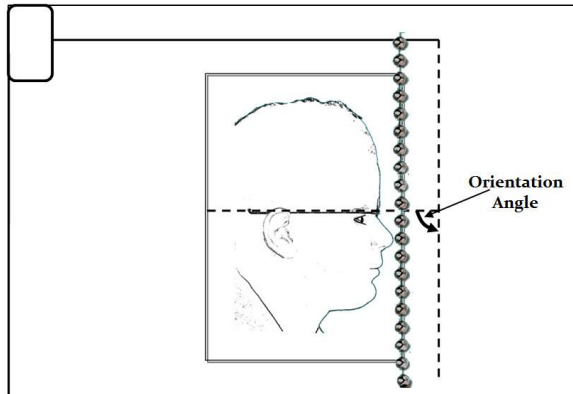


Figure 3: Orientation angle

*The cephalometric reference lines used:*

(FH): Frankfort horizontal plane: passing through orbitale and porion (the midpoint of the upper contour of the external auditory meatus).

(SN): a line passing through nasion and sella.

(KP): the image of the metal orienter on the film either by one line or two parallel lines.

(TV): true vertical; the vertical line on the film represented by the suspended metal chain.

*The cephalometric angular measurements used:*

(KP/FH): the inferior posterior angle between KP and Frankfort Horizontal.

(KP/SN): the inferior posterior angle between KP and SN line.

(FH/SN): the inferior posterior angle between Frankfort Horizontal and SN line.

(FH/TV): the inferior posterior angle between Frankfort Horizontal and the true vertical.

(SN/TV): the inferior posterior angle between SN line and the true vertical.

(KP/TV): the inferior posterior angle between KP and the true vertical.

*Error detection:*

After tracing the cephalometric radiographs the orientation angle, which had been made by the image of the Orienter and the true vertical (posterior-inferior angle), was checked by comparing it to the original clinical orientation angle of the subject. Any deviation or error during exposure was adjusted without repeating the exposure by modifying the orientation angle of the tracing to fit the original clinical orientation angle. This was done by adjusting the true vertical (the image of the metal chain).

The reliability and reproducibility of placement of the Orienter in the natural head position were examined through taking five measurements of the natural head position for 5 consecutive days. Similarly, the recorded plumb-line measurements with and without the Orienter were compared. Measurements were found to be nearly the same; which showed that the Orienter did not influence the reliability and reproducibility of the natural head position.

The lateral cephalometric radiographs were repeated for 10 subjects using the same method and technique after one month to assess the reproducibility of the method. Dahlberg's formula (method error) was used to assess the method error where (d) was the difference between the first and second records and (n) was the number of double determination. The mean difference was found to be 0.29° for both FH/TV and KP/TV.

$$\sqrt{\frac{\sum d^2}{2n}}$$

*Statistical analysis was performed using SAS computer software to calculate:*

- A) Descriptive statistics (mean values, standard deviation, standard error and range).
- B) The coefficient of correlation between different variables.
- C) Paired "t" test to examine the significance of differences between variables.

**Results**

Descriptive statistics of the different measurements were shown in Table 1.

**Table 1: Descriptive statistics of the different measurements (in degrees)**

Variables	No.	Range	Mean	SD	SE
KP/FH	40	0-1	0.06	0.22	0.04
KP/SN	40	2.5-12	7.60	2.64	0.54
FH/SN	40	2.5-12	7.58	2.55	0.52
FH/TV	40	88.5-96	89.28	4.65	0.74
SN/TV	40	78.2-87.3	82.28	4.24	0.67
KP/TV	40	88.5-96	89.05	4.94	0.78

The coefficient of correlation between different variables showed a high positive significance ( $r = 0.98$  with probability = 0.001) shown in Table 2.

**Table 2: Coefficient of correlation between the different variables**

V1	V2	Correlation	Probability
FH/SN	KP/SN	$r = 0.98$	0.001**
FH/TV	KP/TV	$r = 0.98$	0.001**

The results of the paired "t" test between the original clinical angle and the cephalometric orientation angle were not significant;  $89.98 \pm 4.94$  and  $89.05 \pm 4.94$ , respectively (Table 3).

**Table 3: Paired "t" test between the original clinical angle and the cephalometric orientation angle**

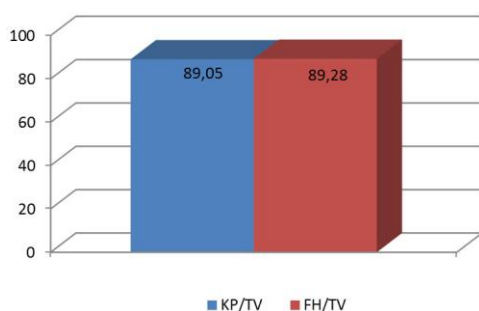
Clinical orientation angle	Cephalometric orientation angle	Mean % Difference	"t" value	Probability
$89.98 \pm 3.4$	$89.05 \pm 4.94$	0.90%	0.981	0.330 NS

The student's "t" test comparing mean values of KP/TV and FH/TV was not significant; -0.21, as shown in Table 4.

**Table 4: Independent student "t" test comparing the mean values of KP/TV and FH/TV**

KP/TV	FH/TV	"t" value	Probability
$89.05 \pm 4.94$	$89.28 \pm 4.65$	-0.21	0.83 NS

Mean values of KP/TV and FH/TV were illustrated in Figure 4.



**Figure 4: A bar graph illustrating the comparison of mean values of KP/TV and FH/TV**

## Discussion

A reliable reference plane was the first demand for cephalometric interpretation. Many reference planes were used, most of them relied on anatomical points or intracranial reference points. The natural head position (NHP) was an alternative to the traditional cephalometric method. It was a trial to relate the face and cranium to extracranial reference lines; the true vertical and true horizontal lines [18] [21].

A new horizontal plane, the K plane, was introduced in this study; it was determined according to anatomical and physiological reference points. Its anatomical reference point anteriorly was soft tissue nasion (SN) while posteriorly the reference points were the superior attachments of the ears (SAE). Both SN and SAE points have been used in profile photographs, as well as the interpupillary line in facial photographs, to orient the head in the horizontal plane [22] [23]. The visual axis was physiologically determined when the subject looked at the horizon; thus the head was oriented in the NHP. Every time this was done the pupils of the eyes were fixed in the same position without any change. Hence this showed that it was both reproducible and reliable [21].

The new K plane (KP) was found to be nearly parallel to the Frankfort horizontal plane (FH) with a very high positive correlation ( $r = 0.98$ ) and a range of  $0-1^\circ$ . Also, KP to FH was found to be  $0.06^\circ \pm 0.22$  with a range of  $0-1^\circ$ . KP to SN and FH to SN were found to be  $7.60^\circ \pm 2.64$  and  $7.58^\circ \pm 2.55$ , respectively. From these results, it could be deduced that the K plane might be used instead of the FH plane.

The metal Orienter, when fixed in position, represented the new K plane clinically, photographically, and cephalometrically as it was radio-opaque in the X-ray. Accordingly, it could be used in any radiographic imaging technique; like the cone-beam computed tomography. Using the Orienter to determine the clinical orientation angle facilitated the measurement of the inferior posterior angle, before and after cephalometric radiography, to assess any errors (Figures 2 & 3). The mean percentage difference, in this study, was found to be 0.90% while the "t" value was not statistically significant; 1.39. This denoted that some errors could occur during cephalometry which could not be noticed using the ordinary method for recording the NHP without the use of the Orienter.

As a result, 2D and 3D radiographic imaging, as well as 2D and 3D photographs performed with the Orienter in place, might give us the opportunity to analyse the face and the profile in the NHP according to the new horizontal K plane of the head. Also, any error during recording could be adjusted by modifying the orientation angle on the film according to the original clinical orientation angle recorded before imaging, for every patient (Figure 3); which reduced the possible errors. This is considered as a valuable finding as it was shown by Madsen et al., [24] that the true vertical and the true horizontal planes were more valid when recorded from the NHP. Shetty et al., [25] also reported that the Frankfurt horizontal plane was recommended as a reference plane only when the radiographs were not recorded in the natural head position.

Furthermore, the K plane was found, during the analysis, to be on the same level of the insertion of the trapezius muscle (neuchal line at the back of



the head) separating the skull into 2 portions; cranial and facial. These observations need further studies.

In conclusion, within the limitations of this prospective study, the new K plane was found to be both reliable and reproducible. It can be used as a reliable reference plane instead of Frankfort horizontal plane both clinically and radiographically; as it is an accurate tool for head orientation in the natural head position.

A new appliance design was constructed based on the new K plane with the Orienter to fix the head in the natural head position. This appliance will be used as a reliable 3D non-radiographic; extra-oral and intra-oral, mean of diagnosis, to overcome the errors produced by traditional methods and prevent patient irradiation. The appliance can perform static and dynamic measurements at the same time, and it could be digitised as well.

Studies will be conducted on the new appliance.

## References

- Broadbent BH. A new x-ray technique and its application to orthodontia. *The Angle Orthodontist*. 1931; 1(2):45-66.
- Bjerin BA. A comparison between the Frankfort horizontal and the sella turcica-nasion as reference planes in cephalometric analysis, *Acta Odont Scand*. 1957; 15:1-12. <https://doi.org/10.3109/00016355709041090>
- De Beer GR. How animals hold their heads. *Proc Linnean Soc London*. 1947; 159:125-139. <https://doi.org/10.1111/j.1095-8312.1947.tb00491.x>
- Downs WB. Variation in facial relationship: Their significance in treatment and prognosis. *Am J Orthod*. 1948; 34:812-840. [https://doi.org/10.1016/0002-9416\(48\)90015-3](https://doi.org/10.1016/0002-9416(48)90015-3)
- Downs WB. The role of cephalometrics in orthodontic case analysis and diagnosis. *Am J Orthod*. 1952; 38:162-182. [https://doi.org/10.1016/0002-9416\(52\)90106-1](https://doi.org/10.1016/0002-9416(52)90106-1)
- Downs WB. Analysis of the dentofacial profile. *Angle Orthod*. 1956; 26:191-211.
- Moorres CF, Kean MR. Natural head position, a basic consideration in the interpretation of cephalometric radiograph. *Am J Phys Anthropol* 1958; 16: 213-234. <https://doi.org/10.1002/ajpa.1330160206>
- Krogman WM, Sassouni V. A Syllabus in roentgenographic cephalometry. Philadelphia 1957, Philadelphia Growth Center for Research in Child Growth, 1957.
- Koski K, Violarinen K. On the relationships between roentgenographic-cephalometric lines of reference. *Acta Odont Scand*. 1956; 14:23-32. <https://doi.org/10.3109/00016355609007501>
- Sassouni V. A roentgenographic cephalometric analysis of cephalofacial-dental relationship. *Am J Orthod*. 1955; 41:735-764. [https://doi.org/10.1016/0002-9416\(55\)90171-8](https://doi.org/10.1016/0002-9416(55)90171-8)
- Fenart R, Lie Fooghe J. Relation entre la posture et la form. *J Sci Med Lille*. 1956; 83:279-288.
- Kronman WM. Craniometry and cephalometric as research tools in growth of head and face. *Am J Orthod*. 1951; 37:406-414. [https://doi.org/10.1016/0002-9416\(51\)90190-X](https://doi.org/10.1016/0002-9416(51)90190-X)
- Mohl ND. Craniofacial relationships and adaptation in bats. Ph.D. dissertation state University of New York at Buffalo, Buffalo, N.Y., 1971.
- Broca P. Sur L'angle orbito-occipital *Bull. Soc Anthropol Paris*. 1877; 12:325-333.
- Delattre A, Fenart R. La method vestibulaire. *Morphal Anthropol*. 1958; 49:90-114.
- Lundstrom A, Lundstrom F, Leuret LL, Moorrees CF. Natural head position and natural head orientation: basic considerations in cephalometric analysis and research. *Europ J Orthod*. 1995; 17: 111-117. <https://doi.org/10.1093/ejo/17.2.111>
- Solow B, Tallgren A. Natural head position in standing subjects. *Acta Odont scand*. 1971; 29: 591-607. <https://doi.org/10.3109/00016357109026337> PMID:5290983
- Vig P.S., Rink J.F., Show Fety K.J.: Adaptation of head posture in response to relocating the center of mass. A pilot study. *Am J Orthod* 1983; 83:138-142. [https://doi.org/10.1016/S0002-9416\(83\)90299-3](https://doi.org/10.1016/S0002-9416(83)90299-3)
- Slow B, Tallgren A. Head posture and craniofacial morphology. *Am J Phys Anthropol*. 1976; 44: 417-435. <https://doi.org/10.1002/ajpa.1330440306> PMID:937521
- Marcotte MR. Head posture and dentofacial proportions. *Angle Orthod*. 1981; 51: 208-213. PMID:6943949
- Peterson CB, Evans WG, Todress J. The relation between orthohead posture and head posture measured during walking. *Am J Orthod Dent Ortho*. 1997; 111:283-287. [https://doi.org/10.1016/S0889-5406\(97\)70186-0](https://doi.org/10.1016/S0889-5406(97)70186-0)
- Virgilio F, Chiarello S, Domenica G, Luca D, Alessandro M. An integrated Head Posture and cephalometric analyses photographic radiographic technique. *Am J Orthod Dent ortho*. 1994; 106: 257-263. [https://doi.org/10.1016/S0889-5406\(94\)70045-1](https://doi.org/10.1016/S0889-5406(94)70045-1)
- Davidson T. Photography in facial plastic and reconstructive surgery. *J Biol Photogr*. 1979; 47: 59-67.
- Madsen DP, Sampson WJ, Townsend GC. Craniofacial reference plane variation and natural head position. *Europ J of Orthod* Oct. 2008; 30(5):532-540. <https://doi.org/10.1093/ejo/cjn031> PMID:18632837
- Shetty D, Bagga DK, Goyal S, Sharma P. A cephalometric study of various horizontal planes in natural head position. *J Ind Orthod Soc*. 2013; 47(3):143-147. <https://doi.org/10.5005/jp-journals-10021-1146>