



Successful conservative management of suspected Fournier's gangrene in cats: three cases

Journal of Feline Medicine and Surgery
 Open Reports
 1–9

© The Author(s) 2015
 Reprints and permissions:
sagepub.co.uk/journalsPermissions.nav
 DOI: 10.1177/2055116915589837
jfmsopenreports.com



Heather H Vaske¹, Izabela K Ragan¹, Kenneth R Harkin¹,
 Karen Lee² and Sarah E Hicks³

Abstract

Case series summary Three cats with suspected Fournier's gangrene had an acute onset of clinical signs and bloodwork changes consistent with sepsis. All cases had similar progression of wounds that were managed without aggressive surgical debridement, which is the currently accepted treatment of choice. All cats survived and have maintained an excellent long-term quality of life.

Relevance and novel information Fournier's gangrene is a potentially fatal disease, with few cases reported in the veterinary literature. This retrospective case series describes the only known reports of survival from suspected Fournier's gangrene cats, none of which required aggressive surgical debridement.

Accepted: 21 November 2014

Introduction

Fournier's gangrene in humans is a rare form of necrotizing fasciitis that affects the perianal and genital regions, with a reported overall mortality of 8–45%.^{1–6} In humans, middle-aged-to-older men are most commonly affected, outnumbering women 10 to 1.^{4,7} The origin of sepsis is often determined to arise from local skin, the urinary tract or colorectal region, with a subset (up to 36%) of patients having an unidentified source.^{2,4,5} There are multiple comorbidities associated with Fournier's gangrene in humans, including diabetes mellitus, alcoholism and malignancy, all of which can lead to reduced cellular immunity of the patient.^{2,4,8,9} Formation of septic thrombi within the small subcutaneous arteries is a hallmark of necrotizing fasciitis, and the resultant ischemia then allows the gangrenous process to spread to the subcutaneous fat and superficial fascia.

Fournier's gangrene is a synergistic polymicrobial infection typically involving both aerobic and anaerobic bacteria from the normal flora of the anorectal, urogenital tract or skin of the perineum.^{2,4,8,10,11} It is not known if the infection associated with Fournier's gangrene is the primary disease or a secondary complication of a primary ischemic process.⁴ The specificity of Fournier's gangrene in affecting the genitalia is secondary to the anatomy of the fascia of the perineum, external genitalia and abdominal

wall, which prevent lateral and posterior spread of infection, with the urogenital diaphragm preventing extension into the pelvis.^{2,8,12} The extent of disease in males varies from a small scrotal wound to entire scrotal involvement and sloughing with extension to the abdominal wall; however, testicular involvement is rare.^{2,4} Since the 1920s, the adopted standard of care for Fournier's gangrene is immediate, aggressive surgical debridement of necrotic tissue in addition to broad-spectrum antibiotics, with only a select few cases of localized disease successfully treated without surgical intervention.^{4,13,14}

This report describes suspected Fournier's gangrene in three cats, all of which survived their disease with conservative management, and returned to a good quality of life following resolution of the wounds. This

¹Department of Clinical Sciences, Veterinary Health Center, Kansas State University, Manhattan, KS, USA

²Veterinary Centers of America (VCA) Central Animal Hospital, Upland, CA, USA

³Indian Hills Animal Clinic, Wichita, KS, USA

Corresponding author:

Heather H Vaske DVM, Department of Clinical Sciences, Veterinary Health Center, Kansas State University, 1800 Denison Ave, Manhattan, KS 66505-5605, USA
 Email: heatherhvp@vet.k-state.edu



Table 1 Case 1: serial complete blood count values

	Reference interval	Day 1	Day 2	Day 3	Day 4
Leukocyte count ($\times 10^3/\mu\text{l}$)	6–17	10.8	1.4	6.3	11.8
Segmented neutrophil concentration ($\times 10^3/\mu\text{l}$)	3–11.5	7.2	0.5	2.1	8.9
Band neutrophil concentration ($\times 10^3/\mu\text{l}$)	0–0.3	1.4	0.4	0.9	0.5
Hematocrit (%)	37–55	40	45	32	26
Platelets ($\times 10^3/\mu\text{l}$)	164–510	267	144	156	164

The bold text indicates values outside of the reference interval.

Table 2 Case 1: serial serum biochemistry values

	Reference interval	Day 1	Day 2	Day 4	Day 5
Glucose (mg/dl)	73–113 (4.1–6.3 mmol/l)	338 (18.8 mmol/l)	202 (11.2 mmol/l)	196 (10.9 mmol/l)	142 (7.9 mmol/l)
Total protein (g/dl)	5.4–7.6 (54–76 g/l)	6.6 (66 g/l)	5.4 (54 g/l)	4.7 (47 g/l)	5.2 (52 g/l)
Albumin (g/dl)	3.4–4.2 (34–42 g/l)	3.8 (38 g/l)	3.1 (31 g/l)	2.1 (21 g/l)	2.3 (23 g/l)
ALT (U/l)	28–171	68	74	191	174
ALP (U/l)	1–142	99	70	14	10
CK (U/l)	128–328	496	4282	28,145	14,469
Total bilirubin (mg/dl)	0.1–0.3 (1.7–5.1 $\mu\text{mol/l}$)	<0.1 (<1.7 $\mu\text{mol/l}$)	0.4 (6.8 $\mu\text{mol/l}$)	3.4 (58.1 $\mu\text{mol/l}$)	2.3 (39.3 $\mu\text{mol/l}$)

ALT = alanine transaminase; ALP = alkaline phosphatase; CK = creatine kinase

documents the first report of successful treatment of suspected Fournier's gangrene in the veterinary species and illustrates an alternative therapy to aggressive surgical debridement.

Case series description

Case 1

A 7-month-old, 3.8 kg intact male Manx cat presented to the Kansas State University Veterinary Health Center for acute onset of vomiting and tenesmus. The cat was previously healthy, being fed Purina Healthy Kitten dry food, but was incompletely vaccinated, with only one feline leukemia virus (FeLV; Purevax Feline Leukemia [Merial]) and FVRCP vaccine (HESKA Feline UltraNasal FVRCP Vaccine; HESKA) at 14 weeks of age. The cat lived strictly indoors, along with one dog.

On initial evaluation, the patient was lethargic, tachycardic (240 beats per minute [bpm]) and tachypneic (80 respirations per minute [rpm]), with apparently normal heart and lung sounds. The cat was febrile (40.8°C), and frequent tenesmus was appreciated throughout the examination. Abdominal palpation revealed a small, soft urinary bladder, and rectal examination was unremarkable.

A complete blood count (CBC), serum biochemistry profile and urinalysis (collected by cystocentesis) were performed on day 1 (see Tables 1 and 2). CBC and serum biochemistry abnormalities included an inflammatory leukogram, with a normal total white blood cell (WBC) count, elevated band neutrophils, lymphopenia, hyperglycemia and mildly elevated alkaline phosphatase. Urinalysis revealed a urine specific gravity >1.050, glycosuria (3+) and proteinuria (3+). Owing to the

presence of glycosuria, urine was submitted for bacterial culture, which revealed no growth on day 3 of hospitalization. Abdominal radiographs were obtained and interpreted as unremarkable. The patient was hospitalized and started on intravenous (IV) Lactated Ringer's Solution (LRS) at 25 ml/h for 12 h, which was then reduced to 15 ml/h. In addition, buprenorphine (0.01 mg/kg IV q8h) was administered for perceived pain associated with tenesmus.

The following day, the patient remained lethargic and febrile (40.5°C). Systolic blood pressure was recorded from the right forelimb and measured to be 138 mmHg. An abdominal ultrasound was performed, which revealed a hypoechoic liver and spleen, multifocal lymphadenopathy, and scant peritoneal effusion. The amount of abdominal effusion was insufficient for collection, and cytological evaluation of an ultrasound-guided fine-needle aspirate of the liver revealed mild vacuolar hepatopathy. A CBC revealed an acute inflammatory leukogram with marked leukopenia, characterized by neutropenia, lymphopenia, elevated bands and mild toxic changes in the neutrophils (see Table 1). Significant abnormalities on a serum biochemistry profile performed on day 2 included hypoproteinemia, hypoalbuminemia and elevated creatine kinase (Table 2). Treatment with IV LRS (15 ml/h) and buprenorphine was continued. Owing to continued vomiting, maropitant (1 mg/kg SC q24h) was initiated along with ampicillin/sulbactam (22 mg/kg IV q8h) and azithromycin (10 mg/kg PO q24h).

On day 3 of hospitalization the cat remained febrile (40.5°C) and mucous membranes appeared mildly icteric. Systolic blood pressure remained within a normal range of 120–130 mmHg, vomiting and tenesmus had stopped,

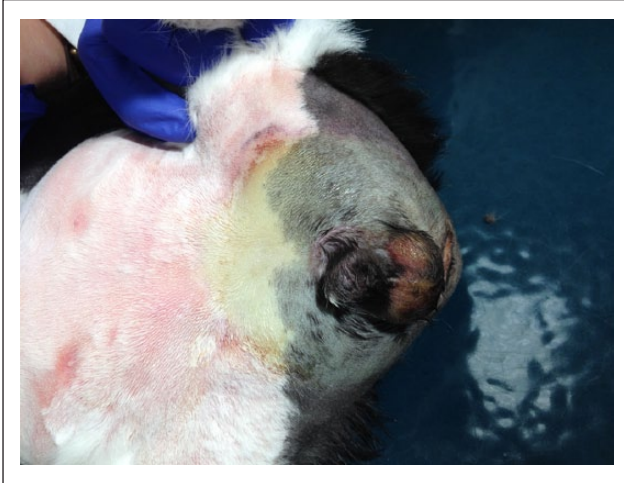

Figure 1 Day 4 post-presentation of case 1 illustrates the first indication of necrotic skin formation as seen by the yellow–gray skin discoloration that extends 5 cm cranial to the prepuce, 1 cm lateral to the scrotum and prepuce, and extends toward the lateral and caudal margins of the tail base. A tissue marker was used to outline the delineation between normal and abnormal skin for the purposes of monitoring for further progression

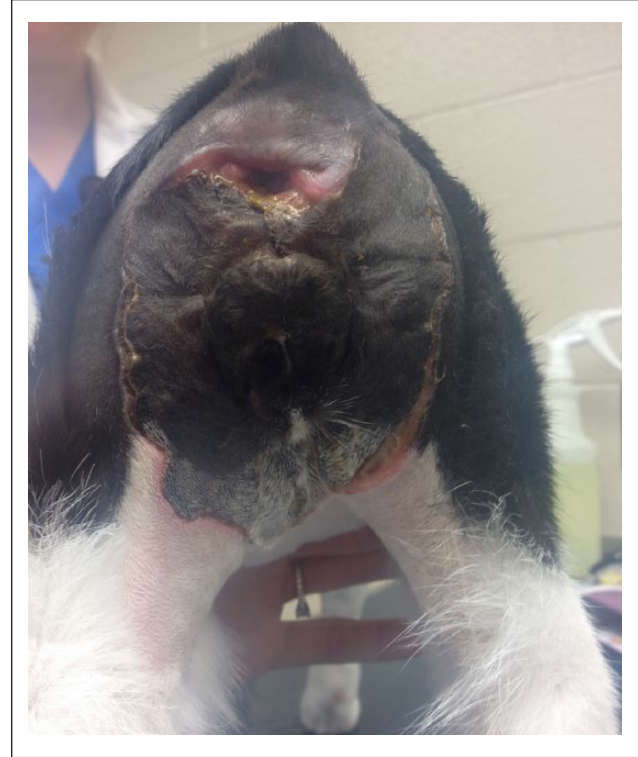

Figure 2 Day 11 post-presentation of case 1 illustrates the extent of the necrotic lesion, with the wound edges pulling away from the underlying tissue. The necrotic skin was left in place to protect the underlying tissue from fecal contamination

and the cat was more active and began to eat. Cellulitis was noted on the caudal ventral abdomen extending around the prepuce, scrotum and rectum, and significant pain was elicited when palpating the lumbar–sacral spine. A repeat CBC revealed an improved total WBC, with neutropenia and elevated bands with moderate toxic changes in neutrophils (see Table 1). Significant abnormalities on serum biochemistry revealed a persistent hypoproteinemia, hypoalbuminemia, increased creatine kinase and hyperbilirubinemia (Table 2).

The caudal ventral abdominal and perineal cellulitis showed necrotic changes on day 4, with yellow–gray skin discoloration and swelling, with a distinct demarcation between affected and non-affected tissue (Figure 1). Margins were traced with permanent marker to monitor for progression. The affected area extended 5 cm cranial to the prepuce with 1 cm margins lateral to the scrotum and prepuce, and extended to the lateral and caudal margins of the tail base. In addition, it was noted that anal tone and sensation were decreased. A CBC on day 4 revealed a resolved neutropenia (see Table 1), and serum biochemistry revealed a lower serum total bilirubin (see Table 2). A contrast cystourethrogram was performed to eliminate the possibility of urethral tear as the cause of cellulitis and necrosis, and the urethra was found to be intact. The patient remained febrile (40.6°C); however, owing to a reliable appetite and continued improvement in attitude, IV ampicillin/sulbactam and IV buprenorphine were discontinued. Amoxicillin/clavulanic acid (16 mg/kg PO q12h) was initiated in addition to the previously prescribed azithromycin, and buprenorphine was administered subcutaneously.

On day 5 the patient was normothermic (37.8°C), and the necrotic skin changes were more prominent, with no change in wound size/margins. Owing to wound contamination from fecal incontinence and ongoing diarrhea, it was decided that the patient would remain in hospital for broad-spectrum antibiotic administration (amoxicillin/clavulanic acid was continued as above, azithromycin was discontinued and enrofloxacin [4.7 mg/kg PO, q24h] was initiated owing to continued fecal contamination of the wound) in addition to daily wound management/monitoring. The necrotic/sloughing skin was left in place to allow coverage of the underlying tissue from fecal contamination (Figure 2). The necrotic tissue eventually completely sloughed off naturally around day 30 of hospitalization (Figure 3), revealing a well-contracted and granulated wound, at which time the cat was discharged from the hospital for further supportive care at home. The patient made a complete recovery (Figure 4), and was eventually castrated 71 days after initial presentation. The testicles were sent for histological examination, and were found to be atrophied.

Case 2

A 1-year-old, 6.4 kg, strictly indoor, castrated male domestic shorthair cat presented to Veterinary Centers of America Central Animal Hospital in Upland, CA,

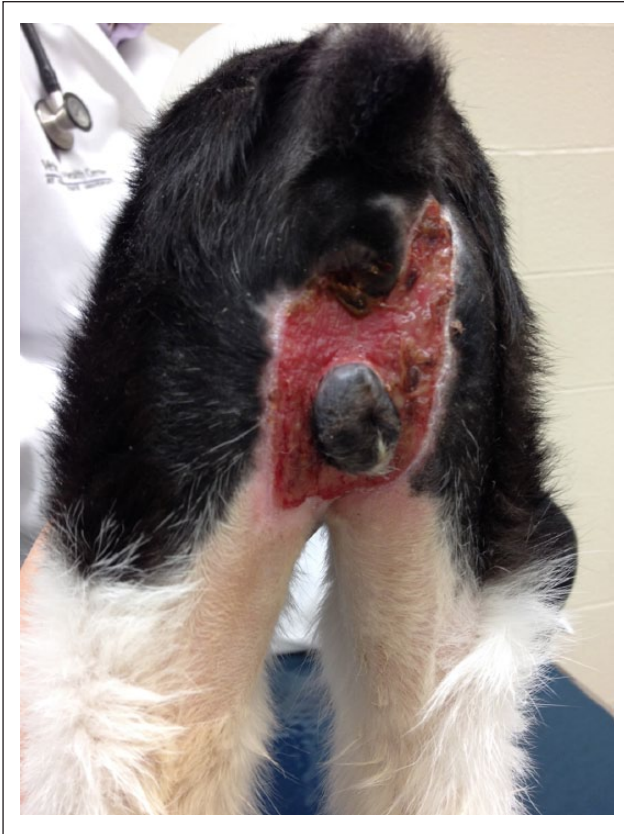

Figure 3 Day 30 post-presentation of case 1. The necrotic tissue has completely sloughed on its own, revealing significant wound contraction and presence of granulation tissue

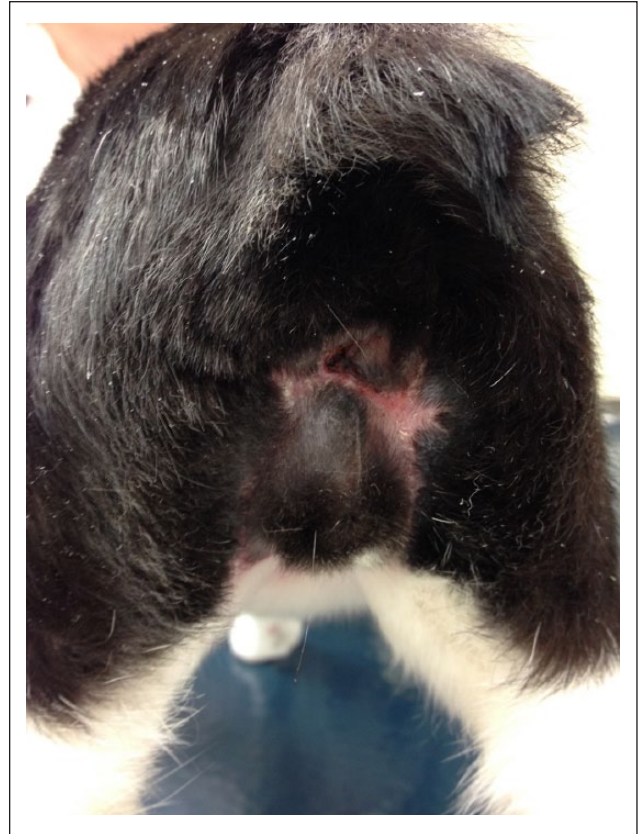

Figure 4 Day 57 post-presentation of case 1 illustrates complete wound healing, at which time normal anal tone was present and the fecal incontinence had resolved. The cat was neutered 2 weeks later

USA, for an evaluation of acute-onset vomiting, tenesmus and lethargy. The cat's diet consisted of Nutro Natural Choice adult dry cat food, with the canned variety occasionally added in. Examination revealed the cat had a slightly elevated temperature (39.3°C), with tacky mucous membranes and tachycardia (230 bpm). Upon palpating the abdomen, tenesmus was induced with only a clear mucoid discharge produced. The bladder palpated soft and small, and a rectal examination revealed an empty colon with clear mucous on the glove.

Abdominal and thoracic radiographs were unremarkable. An initial in-house abbreviated serum biochemistry profile revealed mild hyperglycemia (156 mg/dl [8.7 mmol/l]; reference interval 75–145 mg/dl [4.2–8.0 mmol/l]), with normal blood urea nitrogen, creatinine, alkaline phosphatase and alanine transaminase (ALT). In-house packed cell volume was 45% and total solids was 7.5 mg/dl. FeLV/FIV SNAP (IDEXX) and Parvovirus SNAP (IDEXX) tests were both negative. The cat was hospitalized and started on LRS (30 ml/h IV), maropitant (0.8 mg/kg SC q24h) and metronidazole (19.5 mg/kg PO q12h). Throughout the night, the patient's temperature increased (40.1°C), and, owing to perceived discomfort, buprenorphine (0.01 mg/kg IV as needed) was given.

The following day, a CBC (see Table 3) and serum biochemistry (see Table 4) were sent to an outside reference laboratory (Antech Diagnostics, Irvine, CA, USA) (see Tables 3 and 4). Similar to case 1, the CBC revealed moderate leukopenia characterized by neutropenia and lymphopenia. Significant abnormalities on serum biochemistry included hyperbilirubinemia and mildly elevated creatine kinase. Urinalysis revealed a urine specific gravity of 1.030, bilirubinuria (3+), hematuria (11–20 red blood cells [RBC] per high-power field [HPF]; reference interval 0–3 RBC/HPF), pyuria (4–10 WBC/HPF; reference interval 0–3 WBC/HPF) and no bacteria. In addition to the previously prescribed metronidazole and buprenorphine, the patient was started on amoxicillin/clavulanic acid (14.6 mg/kg PO q12h), enrofloxacin (5.3 mg/kg PO q24h) and robenacoxib (1.87 mg/kg PO q24h) was administered for 3 days.

On day 3 of hospitalization, the patient was normothermic (38.9°C), more alert and had a better appetite. However, pain could be elicited on palpation of the caudal lumbar area. The following day the patient's mucous membranes showed evidence of mild icterus, and the rectal temperature was again elevated (40.6°C). An abdominal ultrasound was performed on day 5 and revealed a slightly enlarged and hypoechoic liver, and

Table 3 Case 2: complete blood count values

	Reference interval	Day 2	Day 5
Leukocyte count ($\times 10^3/\mu\text{l}$)	3.5–16.0	2.9	20.8
Segmented neutrophil concentration ($\times 10^3/\mu\text{l}$)	2.5–8.5	2.2	17.8
Band neutrophil concentration ($\times 10^3/\mu\text{l}$)	0–0.3	NA	NA
Hematocrit (%)	29–48	41	29
Platelets ($\times 10^3/\mu\text{l}$)	200–500	202	148 (with clumps)

NA = not available

Table 4 Case 2: serum biochemistry values

	Reference interval	Day 2	Day 5
Glucose (mg/dl)	64–170 (3.6–9.4 mmol/l)	169 (9.4 mmol/l)	214 (11.9 mmol/l)
Total protein (g/dl)	5.2–8.8 (52–88 g/l)	5.6 (56 g/l)	5.4 (54 g/l)
Albumin (g/dl)	2.5–3.9 (25–39 g/l)	3.1 (31 g/l)	2.3 (23 g/l)
ALT (U/l)	10–100	45	113
AST (U/l)	10–100	23	122
ALP (U/l)	10–100	47	27
CK (U/l)	56–529	546	7910
Total bilirubin (mg/dl)	0.1–0.4 (1.7–6.8 $\mu\text{mol/l}$)	0.8 (13.7 $\mu\text{mol/l}$)	3.9 (66.7 $\mu\text{mol/l}$)

ALT = alanine transaminase; AST = aspartate transaminase; ALP = alkaline phosphatase; CK = creatine kinase

intestinal hypermotility. Bloodwork was again sent to an outside reference laboratory (ANTECH Diagnostics) on day 5. The CBC revealed a mild leukocytosis with neutrophilia (see Table 3). Significant abnormalities on serum biochemistry included worsening hyperbilirubinemia, mild hypoalbuminemia, mildly elevated ALT, mildly elevated aspartate transaminase and a more significant elevation in creatine kinase (see Table 4).

Beginning on the evening of day 6 and progressing to day 7 of hospitalization, the skin from the medial aspects of both caudal thighs, extending towards the inguinal area and the ventral tail base, appeared yellow and necrotic with a distinct line of demarcation from the adjacent skin. As in case 1, conservative wound management was elected, with the cat remaining in hospital (Figure 5). On day 10 the oral antibiotics were discontinued and cefovacin (7.5 mg/kg) was administered subcutaneously every 2 weeks until sufficient granulation tissue was present, and the wounds were cleansed as needed with dilute Betadine (Purdue Products L.P., Stamford, CT). The necrotic skin sloughed on day 43 of hospitalization, revealing a bed of granulation tissue. The patient was discharged on day 56 with recommendations to clean the wound as needed, and made a complete recovery.

Case 3

A spayed female domestic shorthair cat aged 1 year and 7 months and weighing 3.8 kg presented to Indian Hills Animal Clinic in Wichita, KS, USA, for acute onset of

vomiting and acting as if in pain. The cat lived exclusively indoors, was being fed Rachael Ray dry cat food (Rachael Ray Nutrish), and had no prior illness until 3 days prior to presentation, when it vomited multiple times and had diarrhea. On physical examination, the cat was febrile (39.5°C) and tachypneic (44 rpm). The cat was painful on palpation of the lumbar spine and manipulation of the tail base, with obvious bruising on the under-portion of the tail, which extended approximately 3 cm distal to the base of the tail. Abdominal palpation was unremarkable. A CBC revealed leukopenia and thrombocytopenia (see Table 5), and significant serum biochemistry abnormalities included elevated ALT and hyperbilirubinemia (see Table 6). Whole-body radiographs were unremarkable. The cat was discharged with buprenorphine (0.01 mg/kg transmucosally q8h) for pain management and amoxicillin/clavulanic acid (16 mg/kg PO q12h).

Five days later, the cat was evaluated for worsening of the tail base skin lesion: the previous bruise had a distinct line of demarcation of necrotic skin that extended around the anus and toward the medial thighs, similar to both cases 1 and 2, with subcutaneous tissue beginning to slough. An FeLV/FIV SNAP (IDEXX) test was negative. The previously prescribed antibiotics and pain medications were continued, and the wounds were monitored for further progression at home. Five days later (day 10), the necrotic/sloughing skin had extended to the ventrum and larger portion of the medial aspects of both hindlimbs.

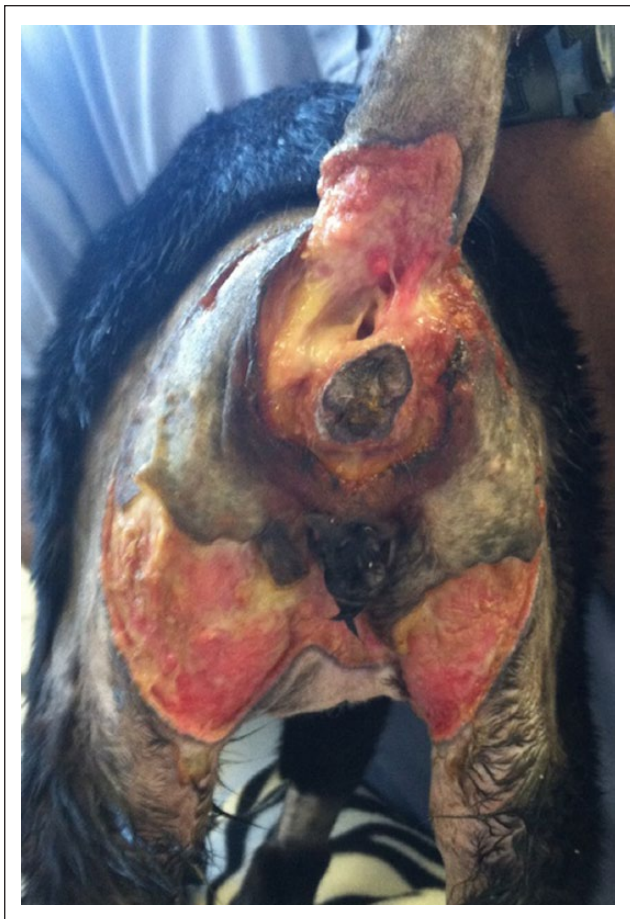

Figure 5 Day 18 post-presentation of case 2 illustrates the extent of the wound at its worse. The necrotic tissue has started to slough, with a portion of necrotic skin still present

A CBC revealed resolution of leukopenia and thrombocytopenia (see Table 5), and serum biochemistry was unremarkable (see Table 6). The previously prescribed therapy (buprenorphine and amoxicillin/clavulanic acid) was continued for an additional 2 weeks, and the cat began cold laser therapy of the wound the following day.

On day 15, the portion of sloughing skin was progressively pulling away from the underlying tissue, and the decision was made to remove the piece of necrotic tissue. On day 18 the cat was briefly anesthetized for removal of the necrotic skin (Figure 6). The cat remained in the hospital for wound management with cold laser therapy three times weekly, and hydrotherapy three times daily until a healthy granulation bed was present. The patient was discharged on day 33 and made a full recovery.

Discussion

This report of suspected feline Fournier's gangrene in three cats is, to our knowledge, the first in veterinary medicine to describe the use of conservative management with 100% survival. All cases involved young,

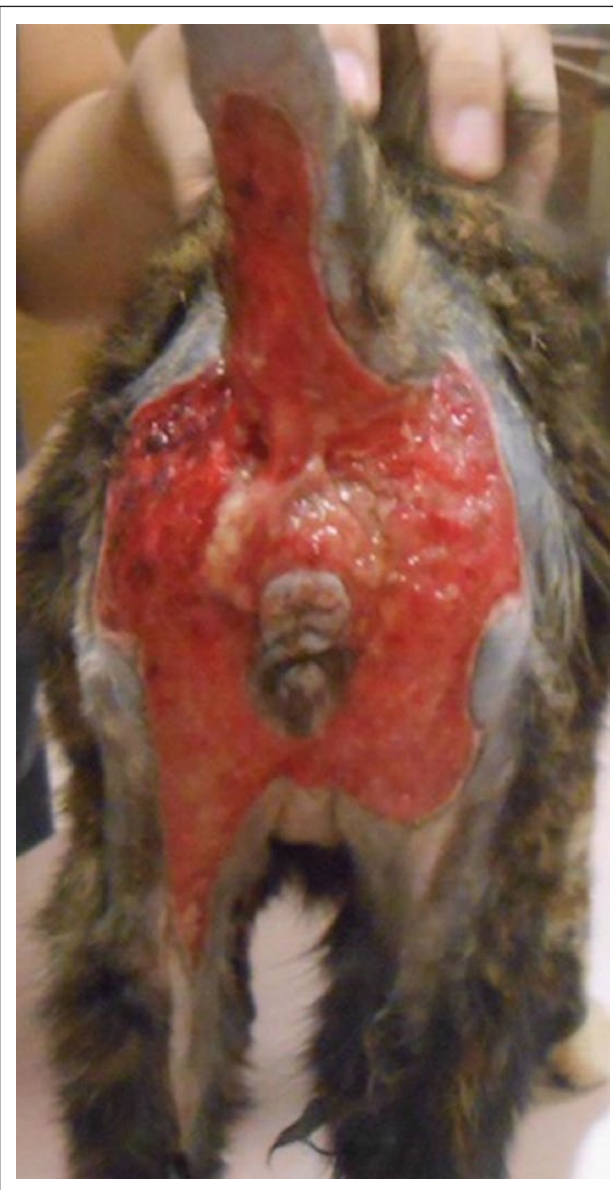


Figure 6 Day 18 post-presentation of case 3 illustrates the wound extent without the necrotic/sloughing skin present

indoor-only, otherwise healthy cats, with no identifiable comorbidity. Furthermore, all cats had similar presenting complaints (acute-onset vomiting and tenesmus and/or diarrhea), and clinicopathological abnormalities (significant leukopenia and hyperbilirubinemia), and wound location and progression were nearly identical, with the anus and prepuce or vulva being spared. Unfortunately, without biopsy and culture samples in any of the cases, a definitive diagnosis of Fournier's gangrene cannot be made. However, the rapid progression of a necrotizing soft-tissue infection in the specific genitourinary region is consistent with the human syndrome of Fournier's gangrene,^{5,8} lending the diagnosis of suspected Fournier's gangrene in these cats.

Table 5 Case 3: complete blood count values

	Reference interval	Day 1	Day 10
Leukocyte count ($\times 10^3/\mu\text{l}$)	5.5–19.5	3.87	5.3
Segmented neutrophil concentration ($\times 10^3/\mu\text{l}$)	2.5–12.5	2.8	2.5
Band neutrophil concentration	NA	NA	NA
Hematocrit (%)	30–45	51.3	34.3
Platelets ($\times 10^3/\mu\text{l}$)	175–600	88	677

NA = not available

Table 6 Case 3: serum biochemistry

	Reference interval	Day 1	Day 10
Glucose (mg/dl)	74–159 (4.1–8.8 mmol/l)	174 (9.7 mmol/l)	94 (5.2 mmol/l)
Total protein (g/dl)	5.7–8.9 (57–89 g/l)	6.9 (69 g/l)	6.0 (60 g/l)
Albumin (g/dl)	2.2–4.0 (22–40 g/l)	2.7 (27 g/l)	2.7 (27 g/l)
ALT (U/l)	12–130	197	54
ALP (U/l)	14–111	15	11
Total bilirubin (mg/dl)	0.0–0.9 (0–15.4 $\mu\text{mol/l}$)	3.4 (58.1 $\mu\text{mol/l}$)	0.3 (5.1 $\mu\text{mol/l}$)

ALT = alanine transaminase; ALP = alkaline phosphatase

There is limited information regarding Fournier's gangrene in the veterinary literature. To our knowledge, there are only two previous case reports of Fournier's gangrene in the veterinary literature.^{15,16} The first of which was a case report of an indoor-only, 2-year-old domestic shorthair cat that presented to an emergency animal hospital for the acute onset of lethargy, mild ataxia and mucoid anal discharge.¹⁵ On initial examination, the cat was febrile (40.4°C), and although there was no evidence of cutaneous lesions, a painful swelling was appreciated around the rectum.¹⁵ By the seventh day of hospitalization the cat had an area of necrosis around the perineum and caudal thighs, similar to the images provided in our case series.¹⁵ Ultimately, surgical debridement of the necrotic perianal area was performed with biopsy, and culture samples obtained.¹⁵ The histopathology report was consistent with Fournier's gangrene, and the aerobic culture had moderate growth of *Enterococcus faecium*, *Staphylococcus epidermidis* and *Escherichia coli*.¹⁵ Unfortunately, the cat's clinical picture declined post-surgical debridement and the owners elected humane euthanasia.¹⁵ The other case report was in a 37-year-old male chimpanzee that was evaluated for acute scrotal swelling and a 5 day history of intermittent diarrhea.¹⁶ The scrotal swelling progressed to the perineal and inguinal regions, as well as the proximal hindlimbs.¹⁶ Surgical debridement was performed, with histopathology being consistent with Fournier's gangrene and cultures having abundant growth of *Streptococcus* species and *Fusobacterium necrophorum*, as well as moderate growth of *Salmonella typhimurium* and slight growth of *Proteus mirabilis*.¹⁶ Unfortunately, the chimpanzee

remained minimally responsive post-surgery and eventually went into cardiac arrest, with cardiopulmonary resuscitation being unsuccessful.¹⁶

The present paper is the first report in veterinary medicine to demonstrate successful treatment, without the use of aggressive surgical debridement, of three cases of suspected Fournier's gangrene in cats. There were several common features of the cases described in this case series that were responsible for the failure to acquire skin biopsies and cultures. First, these cats were presented for signs referable to the gastrointestinal tract, not the cutaneous lesions, prompting therapy for acute enterocolitis. Second, antibiotic therapy had already been initiated for the fever, leukopenia and enterocolitis prior to the discovery of the cutaneous lesions, which likely would have affected later cultures of the skin lesions. Third, the appearance of the necrotic cutaneous lesions was presumed to be suggestive of a local thromboembolic event secondary to the initial sepsis from enterocolitis, as Fournier's gangrene was unknown to us at the time these cases presented. Finally, the lack of worsening of the necrotic areas after the first days of recognition did not prompt an urgent need for skin biopsies in these cases. In future cases of suspected Fournier's gangrene, acquisition of skin biopsy, aerobic and anaerobic culture, potentially even utilizing fluorescent in situ hybridization assays may allow for a definitive diagnosis of Fournier's gangrene while potentially providing better organism identification to guide antibiotic choices.

The findings of leukopenia and mild hyperbilirubinemia in the affected cats reported here were suspected to be evidence of underlying sepsis, which has also been

described in humans.^{2,9} The concern for sepsis led to the early institution of broad-spectrum antibiotics in each case. Owing to the preferences of the managing veterinarian at each hospital, the antibiotic choices differed slightly between cases. However, in all cases, treatment with a potentiated penicillin (ampicillin/sulbactam or amoxicillin/clavulanic acid) was instituted to target common commensal skin organisms, such as *Staphylococcus* species and *Streptococcus* species, as well as some enteric bacteria such as *E coli*, enterobacteria and *Salmonella* species. The initial addition of azithromycin in case 1 increased the spectrum to include gram-negative bacteria such as *Helicobacter* species and *Bartonella* species, as well as other organisms such as *Mycoplasma* species. When the index of concern for gastrointestinal translocation of bacteria increased in cases 1 and 2, enrofloxacin was instituted for its increased gram-negative spectrum and activity against enteropathogens. To decrease the risk of irreversible retinotoxicity associated with enrofloxacin, the daily dose of enrofloxacin did not exceed 5mg/kg daily. The rationale for initial use of metronidazole in case 2 was to target anaerobic organisms associated with many intestinal infections.

The affected tissue in the cats follows the typical pattern seen in human Fournier's gangrene; however, the age of onset and lack of identifiable comorbidities contrasts the disease process in humans. In humans, the most common comorbidities associated with Fournier's gangrene are associated with decreased host immunity, which may add to the described rapid progression of wounds that require immediate and aggressive surgical debridement. It is possible that the lack of concurrent illness and associated compromised immunity prevented the development and progression of severe bacterial infection in these cats, allowing for successful conservative wound management. In addition, the early initiation of broad-spectrum antibiotics in each of the cats of this report was likely critical to their successful therapy, although culture and susceptibility would have been ideal to guide the antimicrobial use.

Owing to lack of any identifiable comorbidity in these cats, the underlying etiology in each case remains unknown. With a history of leukopenia in all cases, tenesmus in cases 1 and 2, subsequent fecal incontinence in case 1 and a history of diarrhea in case 3, it is speculated that the sepsis could have originated from the colorectal region, as commonly described in humans. Although not detected, the potential for exposure to pathogenic gram-negative bacteria (eg, *Salmonella*, *Yersinia enterocolitica*, *Francisella tularensis*) leading to colitis with tenesmus and diarrhea cannot be ruled out in these cats. The common colorectal diseases associated with Fournier's gangrene in humans include ruptured appendicitis, colonic carcinoma and diverticulitis,⁴ none of which were suspected in the cases reported here. Severe colitis may have led to the fecal incontinence

observed in case 1, as well as the vomiting seen in all cases. The second most likely source for disease in the described cats is from the urinary tract, as straining to urinate may have been misidentified as tenesmus in cases 1 and 2. However, this is unlikely given that the urinary bladder was small, soft and appeared to be non-painful in both cases. Additionally, a urine culture was performed in case 1 owing to the presence of glycosuria, with the final result being negative. Urinary tract lesions such as urethral rupture, urethral stones and renal abscesses were ruled out in case 1 based on abdominal ultrasound and contrast cystourethrogram. Owing to previous antibiotic administration, urine was not submitted or cultured for case 2, and although no identifiable urinary tract disease was observed on abdominal ultrasound, lesions within the pelvic canal or infection resistant to the previously administered antibiotics cannot be ruled out. Owing to the indoor nature of each cat, and lack of penetrating wounds, a cutaneous infection leading to perianal necrosis is unlikely.

All cases reported here had almost identical wound progression, which followed the description of Fournier's gangrene lesions in the human literature. The successful outcome of these cats without surgical debridement provides an important alternative for companion animals to the standard of care described in the human literature.

Conclusion

Conservative management of suspected Fournier's gangrene in cats, with broad-spectrum antibiotics and daily wound care is a viable treatment option for a successful outcome.

Funding The authors received no specific grant from any funding agency in the public, commercial or not-for-profit sectors for the preparation of this case series.

Conflict of interest The authors do not have any potential conflicts of interest to declare.

References

- 1 Spirnak JP, Resnick MI, Hampel N, et al. **Fournier's gangrene: report of 20 patients.** *J Urol* 1984; 131: 289–291.
- 2 Clayton MD, Fowler JE and Sharifi R. **Causes, presentation and survival of fifty-seven patients with necrotizing fasciitis of the male genitalia.** *Surg Gynecol Obstet* 1990; 170: 49–53.
- 3 Stephens BJ, Lathrop JC, Rice WT, et al. **Fournier's gangrene: historic (1764–1978) versus contemporary (1979–1988) differences in etiology and clinical importance.** *Am Surg* 1993; 59: 149–154.
- 4 Eke N. **Fournier's gangrene: a review of 1726 cases.** *Br J Surg* 2000; 87: 718–728.
- 5 Norton KS, Johnson LW, Perry T, et al. **Management of Fournier's gangrene: an eleven-year retrospective analysis of early recognition, diagnosis, and treatment.** *Am Surg* 2002; 68: 709–713.

- 6 Basoglu M, Ozbey I, Atamanalp SS, et al. **Management of Fournier's gangrene: review of 45 cases.** *Surg Today* 2007; 37: 558–563.
- 7 Benjelloun EB, Souiki T, Yakla N, et al. **Fournier's gangrene: our experience with 50 patients and analysis of factors affecting mortality.** *World J Emerg Surg* 2013; 8: 13–17.
- 8 Paty R and Smith AD. **Gangrene and Fournier's gangrene.** *Urol Clin North Am* 1992; 19: 149–155.
- 9 Yenyol CO, Suelozgen T, Arslan M, et al. **Fournier's gangrene: experience with 25 patients and use of Fournier's gangrene severity index score.** *Urology* 2004; 64: 218–222.
- 10 Rudolph R, Soloway M, DePalma RG, et al. **Fournier's syndrome: synergistic gangrene of the scrotum.** *Am J Surg* 1975; 129: 591–596.
- 11 Baskin LS, Carrol PR and Cottolica EV. **Necrotizing soft tissue infections of the perineum and genitalia: bacteriology, treatment and risk assessment.** *Br J Urol* 1990; 65: 524–529.
- 12 Huber P. **Acute perineal infection: diagnosis and management.** *Urol Clin North Am* 1982; 9: 237–243.
- 13 Meleney FL. **Hemolytic streptococcus gangrene.** *Arch Surg* 1924; 9: 317–364.
- 14 Malik AM, Sheikh S and Pathan R. **The spectrum of presentation and management of Fournier's gangrene – an experience of 73 cases.** *J Pak Med Assoc* 2010; 60: 617–619.
- 15 Berube DE, Whelan MF, Tater KC, et al. **Fournier's gangrene in a cat.** *J Vet Emerg Crit Care* 2010; 20: 148–154.
- 16 Okeson DM, Marrow J, Carpenter JW, et al. **Fournier's gangrene syndrome in a chimpanzee (*Pan troglodytes*).** *J Zoo Wildl Med* 2010; 41: 169–173.