

Case Report: Trigeminal Neuralgia Caused by a Minute Meningioma with Hyperostosed Suprameatal Tubercle

Yukitomo Ishi^a Katsuyuki Asaoka^a Taku Sugiyama^a Yuka Yokoyama^a
Kazuyoshi Yamazaki^a Sumire Echizenya^a Koji Itamoto^a
Kohei Echizenya^b

^aDepartment of Neurosurgery, Teine Keijinkai Hospital, Sapporo, and ^bEchizenya Neurosurgery Clinic, Otaru, Japan

Key Words

Trigeminal neuralgia · Brain tumor · Meningioma · Cerebellopontine angle · Meckel's cave

Abstract

Cerebellopontine angle tumors might occasionally provoke trigeminal neuralgia but are usually large enough to be diagnosed radiographically. We present a case of trigeminal neuralgia caused by a very small meningioma covering the suprameatal tubercle that displayed hyperostosis at the entrance of Meckel's cave and was not obvious on routine magnetic resonance (MR) images. A 72-year-old woman with intractable trigeminal neuralgia in the left V3 territory was referred to our institution. Preoperative imaging studies revealed that the left trigeminal nerve was medially distorted at the entrance of Meckel's cave by a laterally seated bone bulge covered by a minute enhanced lesion. Trigeminal nerve decompression surgery was performed via a retrosigmoid intradural suprameatal approach. We found a small meningioma that had compressed and flattened the trigeminal nerve root at the entrance of Meckel's cave, which was grossly and totally removed by suprameatal tubercle resection. There was no vascular compression of the trigeminal nerve root. The trigeminal neuralgia ceased completely after the operation. Accurate preoperative determination of the causative pathologies is essential to achieve adequate surgical results after microvascular decompression for neurovascular compression syndrome. Because conventional MR sequences are inadequate for the precise interpretation of complex neurovascular anatomy in the cerebellopontine angle and such small tumors can be overlooked on routine MR studies,

high-resolution thin-slice MR examinations and careful radiological interpretations are required for correct diagnosis and treatment.

© 2015 S. Karger AG, Basel

Introduction

Trigeminal neuralgia (TN) is generally caused by vascular compression of the nerve root. Cerebellopontine angle (CPA) tumors might also sometimes provoke TN by directly compressing the trigeminal nerve root or indirectly by displacing arteries. In such cases, the tumors are usually large enough to be diagnosed radiographically. We present herein a case of TN caused by a very small meningioma covering the suprameatal tubercle that displayed hyperostosis at the entrance of Meckel's cave and was not obvious on routine magnetic resonance (MR) images.

Case Report

A 72-year-old woman presented with paroxysmal stabbing pain in her left mandibular region. She initially visited a local neurosurgical service and was administered carbamazepine (200 mg/day) and diagnosed with TN of unknown etiology. The dosage of carbamazepine could not be further increased because of drowsiness and dizziness. However, her facial pain worsened over the following year, despite the addition of pregabalin (75 mg/day) to her medication. She consulted another neurosurgical service and underwent a thorough MR imaging study in which a bony bulge with a faint gadopentetate dimeglumine (Gd-DTPA) enhancement was finally detected at a location lateral to the entrance of the left Meckel's cave. Although gamma-knife radiosurgery was first planned to shrink the enhanced lesion that was suspected to cause the TN, it was cancelled because we considered that the bony bulge also contributed to the nerve root compression.

The patient was referred to our institution for surgical exploration. A neurological examination revealed no abnormalities except for TN in the left V3 territory. Bone-window computed tomography (CT) scans showed the suprameatal tubercle with hyperostosis on the left side (fig. 1a). On MR images, the lesion that covered the bony bulge appeared isointense on T1- (fig. 1b) and hyperintense on T2-weighted (fig. 1c) images and was enhanced with Gd-DTPA (fig. 1d). The lesion was very small, with an approximate diameter of 5 mm, and was only detectable in 1 slice on the usual MR sequences. High-resolution 3-dimensional (3D) fast imaging employing steady-state acquisition (FIESTA) MR images (fig. 2) taken at the same time demonstrated a more obvious extra-axial tumor at the entrance of the left Meckel's cave that was medially compressing and distorting the trigeminal nerve root. The left superior cerebellar artery (SCA) ran medially proximal to the trigeminal nerve and might also have compressed the nerve root. We diagnosed the small tumor as a meningioma with hyperostosis.

The patient underwent surgery via a retrosigmoid intradural suprameatal approach. Under the operating microscope, we found a small meningioma that covered the bulged dura of the suprameatal tubercle. After removing the dural surface tumor, we intradurally resected the suprameatal tubercle to expose the tumor invading Meckel's cave with a Sonopet bone dissector (Stryker Corporate, Kalamazoo, Mich., USA) via a narrow surgical corridor between the petrosal vein and vestibulocochlear bundle. Removal of the tumor and the bony bulge gradually unveiled the underlying compressed and thinned trigeminal nerve root. Finally, the meningioma was grossly and totally removed, thereby achieving complete tri-

geminal nerve root decompression. Intraoperatively, we observed no TN-causing vascular compression.

The patient's TN ceased completely after the operation. Postoperative 3D FIESTA MR images (fig. 3) confirmed the gross total removal of the tumor and the decompressed and straightened trigeminal nerve root. The pathological diagnosis was meningothelial meningioma (World Health Organization grade 1). The patient was discharged without any neurological deficits.

Discussion

It is well known that TN is usually triggered by vascular compression of the trigeminal nerve root, most frequently by the SCA. Other less frequent causes include posterior fossa tumors, cerebral aneurysms, arteriovenous malformations, multiple sclerosis plaques, etc. The incidence rates of posterior fossa tumor-induced TN range from 2.1–11.6% in the literature; these cases mainly comprise meningiomas (14–54%), epidermoid tumors (8–64%), and vestibular schwannomas (7–31%) [1–4].

Mechanisms Underlying Intracranial Tumor-Induced TN

Intracranial tumors can cause TN via several different mechanisms. Hasegawa et al. [5] classified CPA tumor-associated mechanisms into 4 types: type A, the nerve is totally encased by the tumor; type B, the nerve axis is distorted by the tumor; type C, the nerve is shifted by the tumor and contralaterally compressed by the artery, and type D, the nerve is compressed by the tumor-displaced artery. According to this classification, the present case corresponds to type B because the meningioma directly compressed and distorted the trigeminal nerve root without vascular contact. Although Hasegawa's classification was made on the assumption that the responsible tumors were located ipsilaterally near the affected trigeminal nerve, a large and distant tumor [6] could rarely cause contralateral TN remotely as a result of a distorted brainstem. In addition to these mechanical factors, chemical irritation of the nerve has also been proposed as a possible pathogenesis of TN associated with dermoid or epidermoid tumors [2].

Tumor Size and Occurrence of TN

There have been few reports on the relationship between the tumor size and the occurrence of TN. Jamjoom et al. [2] reported in a review of 7 patients with CPA tumor-induced TN that the tumor size played no role in causing TN. However, because 4 of the 7 patients in that study had dermoid tumors, chemical irritation might have contributed to the occurrence of TN in those cases. Meanwhile, trigeminal symptoms correlated with the size of vestibular schwannomas [6]. Given the anatomical distance between the vestibulocochlear and trigeminal nerves, a small vestibular schwannoma with a cisternal diameter of less than 1 cm would not affect the trigeminal nerve.

We believe that the tumor location is more important than the size in the occurrence of meningioma-associated TN. As reported, 36% of tentorial notch meningiomas caused TN [7], and tumors located close to the trigeminal nerve root would more frequently cause TN. Nerve compression in or around Meckel's cave will occur more easily with small meningiomas. Nevertheless, minute meningiomas, which are not obvious on MR images, would rarely provoke intractable TN such as that observed in the present case. Anatomical factors also contributed to the occurrence of TN in the present case; the posterior fossa was relatively tight for the patient's age, and the cisternal portion of the trigeminal nerve was quite short.

Reportedly, in the side affected with TN, the CPA cisterns are smaller and the cisternal trigeminal nerves are shorter than those in the normal side [8]. We assume that these anatomical features would result in an increase in pressure on the trigeminal nerve root at the entrance of Meckel's cave, even in the case of small tumors.

Issues with Diagnosis and Treatment

An accurate preoperative determination of the causative pathology is essential for achieving sufficient surgical results after microvascular decompression for neurovascular compression syndrome. Conventional MR sequences are inadequate for precisely interpreting the complex neurovascular anatomy of the CPA [9]. High-resolution MR sequences such as FIESTA that produce heavy T2-weighted images have been used to delineate neurovascular relationships in the cistern by displaying a strong contrast between the cerebrospinal fluid and solid structures [10]. Despite its high spatial resolution, it is impossible to distinguish the anatomical details of solid structures such as cranial nerves and vessels. Therefore, a combination with 3D time-of-flight MR angiography has also been explored to better visualize vascular compression of the cranial nerves [10]. These modern imaging techniques also enable the detection of minute pathologies that can be overlooked on routine MR studies, as observed in the present case.

In this case, the dose of drugs for TN was low; 200 mg/day of carbamazepine and 75 mg/day of pregabalin were administered. An increase of drugs was considered but was not possible because of side effects. In such cases, surgical treatment would play an important role to improve symptoms as well as to obtain a pathological diagnosis.

Conclusion

We present a case of TN caused by a very small meningioma covering the suprameatal tubercle that exhibited hyperostosis at the entrance of Meckel's cave. Although TN caused by a tumor in the CPA is not rare, it is important to recognize that very small tumors would cause TN. Since such tumors can be overlooked on routine MR studies, high-resolution thin-sliced MR examinations and careful radiological interpretations are required for correct diagnosis and treatment.

Disclosure Statement

The authors declare that they have no conflict of interest. All authors, who are members of the Japan Neurosurgical Society (JNS), have registered online Self-reported COI Disclosure Statement Forms through the website for JNS members.

References

- 1 Barker FG 2nd, Jannetta PJ, Babu RP, Pomonis S, Bissonette DJ, Jho HD: Long-term outcome after operation for trigeminal neuralgia in patients with posterior fossa tumors. *J Neurosurg* 1996;84:818–825.
- 2 Jamjoom AB, Jamjoom ZA, al-Fehaily M, el-Watidy S, al-Moallem M, Nain Ur R: Trigeminal neuralgia related to cerebellopontine angle tumors. *Neurosurg Rev* 1996;19:237–241.
- 3 Nomura T, Ikezaki K, Matsushima T, Fukui M: Trigeminal neuralgia: differentiation between intracranial mass lesions and ordinary vascular compression as causative lesions. *Neurosurg Rev* 1994;17:51–57.
- 4 Shulev Y, Trashin A, Gordienko K: Secondary trigeminal neuralgia in cerebellopontine angle tumors. *Skull Base* 2011;21:287–294.

Ishi et al.: Case Report: Trigeminal Neuralgia Caused by a Minute Meningioma with Hyperostosed Suprameatal Tubercle

- 5 Hasegawa K, Kondo A, Kinuta Y, Tanabe H, Kawakami M, Matsuura N, Chin M, Saiki M: Studies concerning the pathogenesis of trigeminal neuralgia caused by cerebellopontine angle tumors (in Japanese). *No Shinkei Geka* 1995;23:315–320.
- 6 Matthies C, Samii M: Management of 1,000 vestibular schwannomas (acoustic neuromas): clinical presentation. *Neurosurgery* 1997;40:1–9; discussion 9–10.
- 7 Samii M, Carvalho GA, Tatagiba M, Matthies C, Vorkapic P: Meningiomas of the tentorial notch: surgical anatomy and management. *J Neurosurg* 1996;84:375–381.
- 8 Parise M, Acioly MA, Ribeiro CT, Vincent M, Gasparetto EL: The role of the cerebellopontine angle cistern area and trigeminal nerve length in the pathogenesis of trigeminal neuralgia: a prospective case-control study. *Acta Neurochir (Wien)* 2013;155:863–868.
- 9 Tash RR, Sze G, Leslie DR: Trigeminal neuralgia: MR imaging features. *Radiology* 1989;172:767–770.
- 10 Miller J, Acar F, Hamilton B, Burchiel K: Preoperative visualization of neurovascular anatomy in trigeminal neuralgia. *J Neurosurg* 2008;108:477–482.

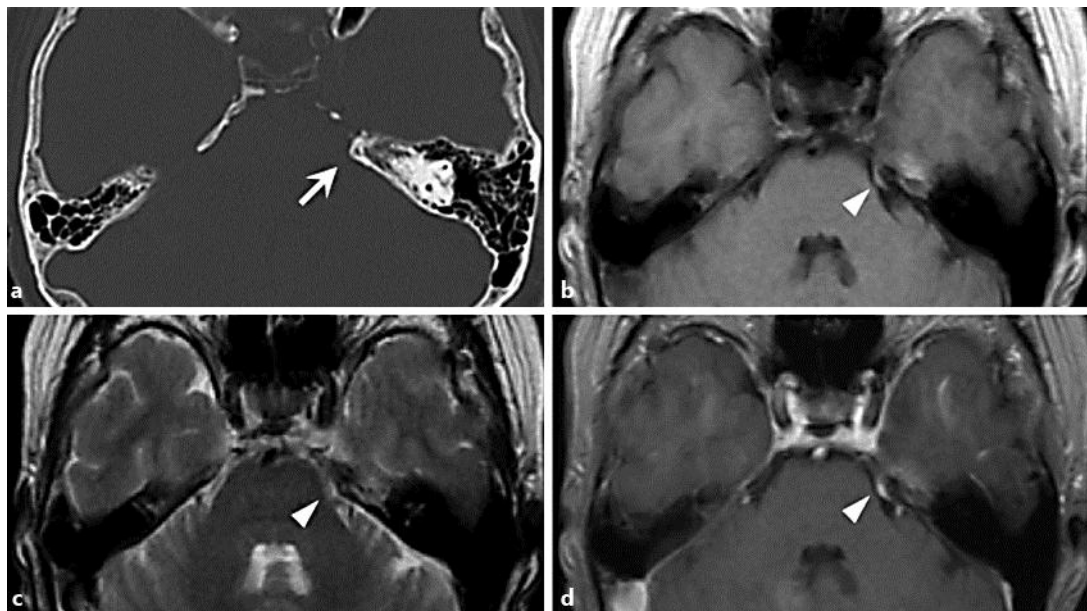


Fig. 1. **a** Preoperative bone-window CT showing the suprameatal tubercle with hyperostosis on the left side (arrow). **b** T1-weighted image showing an isointense lesion (arrowhead) covering the bony bulge. **c** T2-weighted image showing the hyperintense lesion (arrowhead). **d** Gadolinium-enhanced T1-weighted image showing a well-enhanced lesion (arrowhead) covering the bony bulge.

Ishi et al.: Case Report: Trigeminal Neuralgia Caused by a Minute Meningioma with Hyperostosed Suprameatal Tubercle

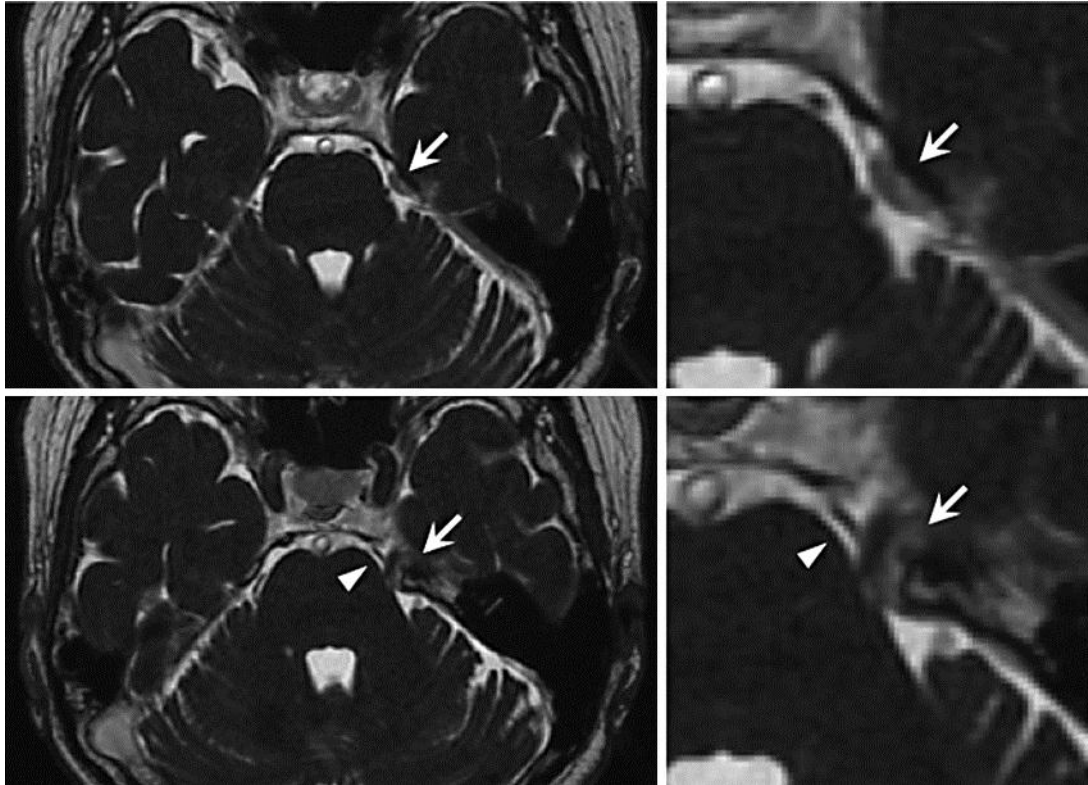


Fig. 2. Preoperative 3D FIESTA MR images showing an extra-axial tumor (arrow) at the entrance of Meckel's cave that medially compressed and distorted the trigeminal nerve root. The SCA (arrowhead) runs medially proximal to the trigeminal nerve.

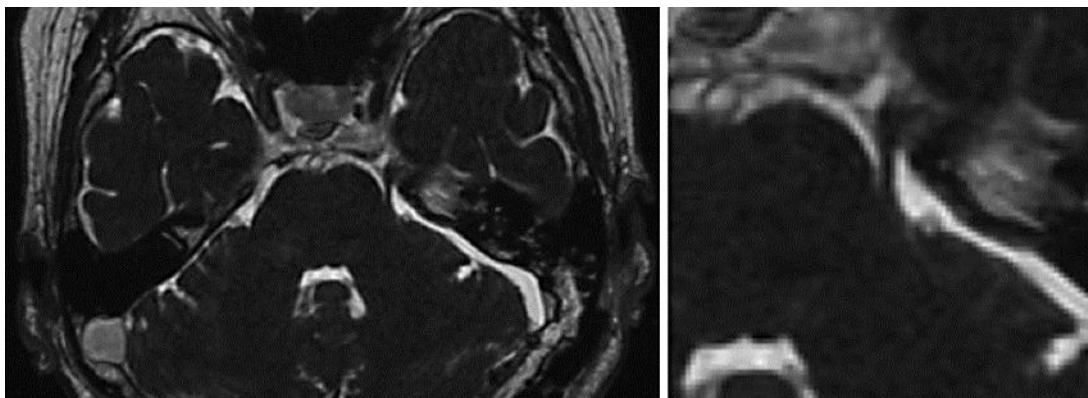


Fig. 3. Postoperative 3D FIESTA MR images showing the gross total removal of the tumor and the decompressed and straightened trigeminal nerve root.