

# Vascular Anomalies During Laparoscopic Renal Surgery: Incidence and Management of Left-Sided Inferior Vena Cava

Timothy K. Byler, Grant I.S. Disick, MD, Ihor S. Sawczuk, MD, Ravi Munver, MD

## ABSTRACT

**Background:** Left-sided inferior vena cava (IVC) is an unusual abnormality that may be clinically significant during renal surgery.

**Methods:** We report the unique case of a patient with a centrally located left renal mass who underwent laparoscopic radical nephrectomy. During the hilar dissection, unusual vascular anatomy was encountered. The patient was noted to have a left-sided inferior vena cava with multiple renal veins and anomalous tributaries. Laparoscopic radical nephrectomy was performed without complication.

**Discussion:** The embryology of a left-sided inferior vena cava is reviewed, and the safety and feasibility of a laparoscopic approach is discussed.

**Key Words:** Laparoscopy, Nephrectomy, Vascular, Inferior vena cava.

## INTRODUCTION

Laparoscopic renal surgery has become a standard urological procedure for a variety of indications. The most common intraoperative complication associated with laparoscopic nephrectomy is vascular injury.<sup>1</sup> As such, meticulous hilar dissection is of paramount importance. Unexpected vascular anomalies may increase the risk of hemorrhage and necessitate conversion to open nephrectomy. We report the case of a major inferior vena cava (IVC) anomaly encountered during laparoscopic nephrectomy and discuss its embryogenesis and management.

## CASE REPORT

A healthy 55-year-old female was referred for evaluation of microscopic hematuria. Computed tomography revealed a 4-cm enhancing lesion located centrally within the left kidney (**Figure 1**). Laparoscopic left radical nephrectomy was planned and upon hilar dissection, the IVC was encountered without visualization of the aorta, confirming its left-sided orientation. In addition, 3 renal veins were noted, as was a left gonadal vein that drained directly into the IVC (**Figure 2**). An aberrant vein was exposed that bridged the gonadal vein and the most caudal of the supernumerary renal veins. Prior to dissection of the renal artery, the caudal renal vein, gonadal vein, and bridging anomalous vein were ligated and transected. Further dissection was uneventful, and the kidney was removed successfully.

## DISCUSSION

The laparoscopic approach has become an accepted standard for extirpative renal surgery, with less postoperative pain, decreased hospital stay, and shorter convalescence compared with that of open surgery.<sup>2</sup> Colombo et al<sup>3</sup> reported that hemorrhage continues to be the most common intraoperative complication of laparoscopic surgery, occurring at a rate of 2.3% and requiring open conversion in 0.9% of cases. Preoperative knowledge of pertinent vascular anatomy is essential during laparoscopic renal surgery to avoid potential

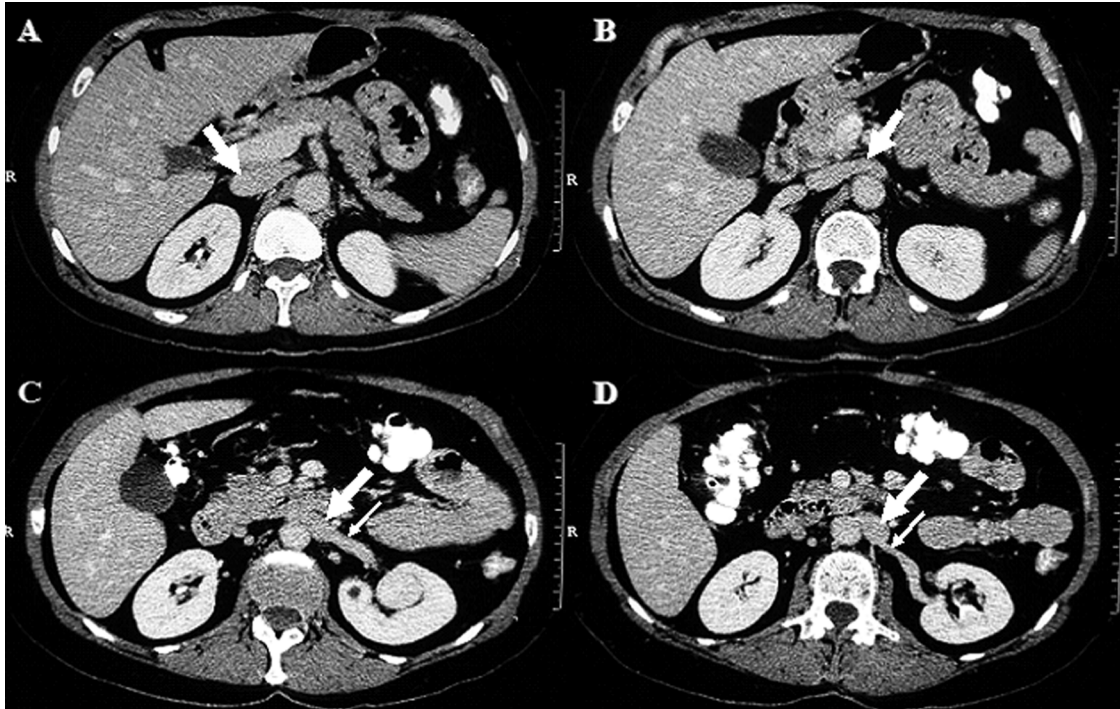
Hackensack University Medical Center, Hackensack, New Jersey, USA (Drs Disick, Sawczuk, Munver).

Touro University College of Medicine, Hackensack, New Jersey, USA (Drs Sawczuk, Munver).

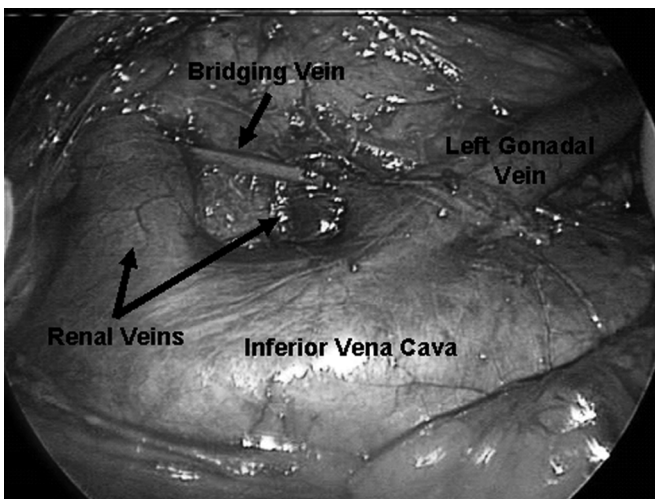
UMDNJ New Jersey Medical School, Newark, New Jersey, USA (Drs Byler, Munver).

Address correspondence to: Ravi Munver, MD, Vice Chairman, Department of Urology, Hackensack University Medical Center, 360 Essex Street, Suite 403, Hackensack, NJ 07601, USA. Telephone: 201 996-5459, Fax: 201 336 8221, E-mail: rmunver@hmed.com

© 2009 by JSLS, *Journal of the Society of Laparoendoscopic Surgeons*. Published by the Society of Laparoendoscopic Surgeons, Inc.



**Figure 1.** Abdominal CT scan illustrates the IVC as it courses from the normal anatomic position to the left-sided position: (A) IVC in right-sided anatomical position (thick arrow); (B) IVC crossing anterior to the aorta (thick arrow); (C) IVC crossing anterior to the aorta (thick arrow) and main left renal vein (thin arrow). Left renal mass is noted in a central location; (D) IVC in left-sided position (thick arrow) and second left renal vein (thin arrow).



**Figure 2.** Intraoperative image during left laparoscopic radical nephrectomy. View of cephalad (left) and caudad (right) aspect of IVC; kidney (out of frame) is located towards top of image. Left gonadal vein drains into the left-sided IVC. Two of the 3 left renal veins are noted. Bridging vein between the main renal vein and gonadal vein is noted.

complications. To our knowledge, this is among the initial reported cases of a left-sided inferior vena cava encountered during laparoscopic radical nephrectomy.

Left-sided IVC is an abnormality that occurs at a prevalence of 0.2% to 0.5% and is usually asymptomatic.<sup>4</sup> Although commonly an incidental finding, it becomes clinically significant when it is mistaken for paraaortic lymphadenopathy or the main renal vein. In such situations, it can be a source of iatrogenic hemorrhage.

The embryonic development of IVC involves the emergence and selective regression of 3 pairs of embryonic veins: the posterior cardinal, subcardinal, and supracardinal veins. Multiple anomalies have been described and classified based on the segment of IVC involved.<sup>5</sup> Anomalies of the postrenal segment of the IVC include retrocaval ureter, duplicated IVC, and left-sided IVC. A left-sided IVC is caused by persistence of the left supracardinal vein with regression of the right supracardinal vein. The left subrenal IVC then joins the left renal vein and crosses anterior to the aorta where it unites with the right renal vein. As a result, the suprarenal IVC remains right-sided in its normal anatomic orientation.

Our patient displayed an additional anomaly involving the presence of 3 left renal veins. Renal venous development results from anastomosis of the subcardinal and supracardinal veins.<sup>6</sup> During normal development, 2 veins are formed initially, the dorsal vein and ventral vein. The dorsal vein subsequently regresses with the result being a single renal vein. Multiple persisting renal veins is the most common anomaly of the venous developmental system with a prevalence ranging from 9% to 20%.<sup>4</sup> The main clinical significance of this finding is the risk of iatrogenic injury during renal surgery.

When a left-sided IVC is encountered, the surgeon must be suspicious of other anomalies. In our patient, 3 renal veins, a bridging vein, and a gonadal vein anomaly were encountered. Others have reported on a coexisting retrocaval ureter and IVC duplication.<sup>6–8</sup> Meticulous dissection and awareness of these potential variants may permit a successful laparoscopic approach.

Careful examination of preoperative radiographic imaging is mandatory in the diagnosis of a left-sided IVC. Case reports have described this phenomenon during laparoscopic live donor nephrectomy without adverse effects.<sup>7,8</sup> In our experience, this anomaly may be more readily apparent when evaluating patients with higher resolution imaging. In accordance with other reports, our case demonstrates that laparoscopic radical nephrectomy can be successfully performed without complications in the presence of a left-sided IVC.

**References:**

1. Simon SD, Castle EP, Ferrigni RG, et al. Complications of laparoscopic nephrectomy: the Mayo Clinic experience. *J Urol.* 2005;171:1447–1450.
2. Dunn MD, Portis AJ, Shalhav AL, et al. Laparoscopic versus open radical nephrectomy: a 9 year experience. *J Urol.* 2000;164:1153–1159.
3. Colombo JR, Haber GP, Jelovsek E, et al. Complications of laparoscopic surgery for urological cancer: a single institution analysis. *J Urol.* 2007;178:786–791.
4. Bass JE, Redwine MD, Kramer LA, et al. Spectrum of congenital anomalies of the inferior vena cava: cross-sectional imaging findings. *Radiographics.* 2000;20:639–652.
5. Chuang VP, Mena CE, Hoskins PA. Congenital anomalies of the inferior vena cava: review of embryogenesis and presentation of a simplified classification. *Br J Radiol.* 1974;47:206–213.
6. Mathews R, Smith PA, Fishman EK, et al. Anomalies of the inferior vena cava and renal veins: embryologic and surgical considerations. *Urology.* 1999;53(5):873–880.
7. Simforoosh N, Beigi FMA, Aminsharifi A, et al. Left-sided inferior vena cava found incidentally during laparoscopic donor nephrectomy: a report of three cases. *J Endourol.* 2007;21(5):542–544.
8. Radolinski B, Diner EK, Ghasemian SR. Left inferior vena cava in a living kidney donor. *J Urol.* 2005;174:2374.