

## Case Report

# Lower First Permanent Molar with an Additional Root Diagnosis and Management

**Abdullah Mahmoud Riyahi** 

*Department of Restorative Dental Science, Division of Endodontics, College of Dentistry, King Saud University, P.O. Box 60169, Riyadh 11545, Saudi Arabia*

Correspondence should be addressed to Abdullah Mahmoud Riyahi; ariyahi@ksu.edu.sa

Received 9 October 2019; Accepted 16 December 2019

Academic Editor: Daniel Torres-Lagares

Copyright © 2019 Abdullah Mahmoud Riyahi. This is an open access article distributed under the Creative Commons Attribution License, which permits unrestricted use, distribution, and reproduction in any medium, provided the original work is properly cited.

Three rooted lower first permanent molar represents one of the main anatomical variants which is a treatment challenge of clinicians. This study is aimed at presenting a case of a lower first molar with an additional root that was diagnosed and managed successfully using new techniques in endodontics. Tooth #46 was diagnosed as a necrotic pulp with symptomatic apical periodontitis. Different angle radiographs were obtained, and they clearly showed three roots. The procedure was completed under magnification and illumination using an operating microscope. The access cavity was modified to achieve straight line access for all the canals. Careful step-by-step instrumentation was performed using flexible NiTi rotary files. The canals were irrigated using 6% sodium hypochlorite. Afterwards, three-dimensional obturation was completed using warm vertical compaction. Knowledge of the anatomy and an early diagnosis are required to achieve high-quality root canal treatment.

## 1. Introduction

Complex root morphology and canal anatomy have been observed in the lower first molars [1–3]. The lower first molar usually has two roots, one located mesially and the other located distally. One major variant of this tooth morphology is the existence of a third root [4]. The additional root can be located distolingually (radix entomolaris) or mesiobuccally (radix paramolaris) [5, 6].

The occurrence of an additional root in the lower first molar varies across different populations. In the Chinese sub-population, it was found to be 29% [7]. However, it was found to be as low as 0.68% in the German population [8].

The distolingual (DL) root is typically small and conical in shape with an apex that swings buccally [9]. This anatomical variation can present a clinical challenge during endodontic treatment [10]. Therefore, knowledge of this root morphology, the correct diagnosis, and proper management are important to achieve high-quality treatment.

Due to the importance of the subject, the literature has many case reports addressing the diagnosis and manage-

ment of lower molar with an additional root. [11–13] With the current advances in endodontics, including operating microscopy, digital radiographs, cone beam computed tomography (CBCT), and heat-treated NiTi rotary file systems, such cases can be treated in a more predictable fashion.

This study aims to present a case of a lower first molar with a third root that was diagnosed and managed successfully using new techniques in endodontics.

## 2. Case

A 42-year-old male patient visited a dental clinic with the following chief complaint: “I have spontaneous pain in that tooth”. He pointed at tooth #46. The pain had started one month ago and was progressive. The patient had a noncontributory medical history with no known allergies. He had multiple restorations in the upper and lower arches with no history of LA complications.

An extraoral examination showed a symmetrical face, no head and neck lymphadenopathy, no TMJ clicking, and limited mouth opening. Tooth #46 responded negatively to the

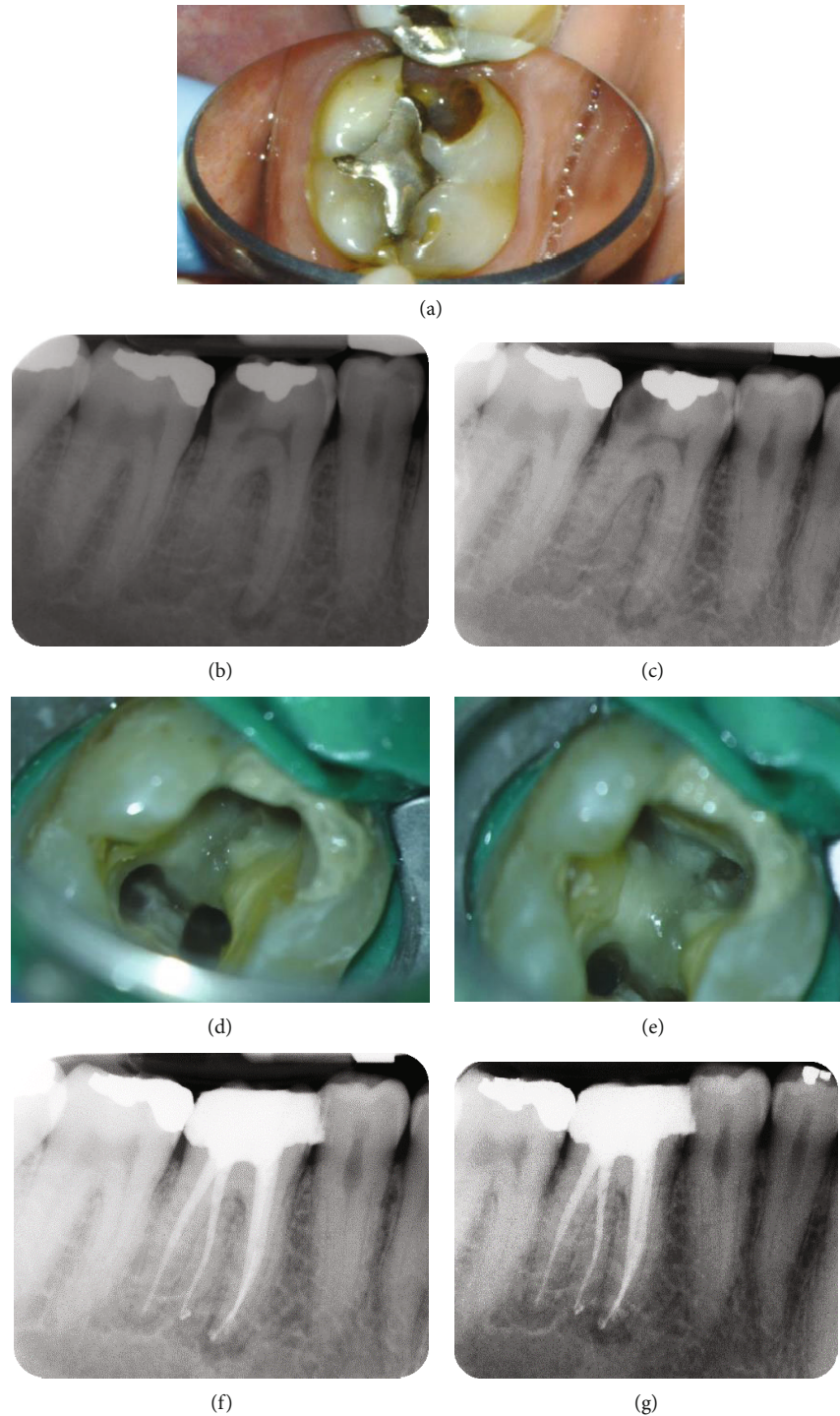


FIGURE 1: (a) Intraoral photo of tooth #46 showing a large carious lesion and defective amalgam restoration. (b, c) Periapical radiographs of different angles showing the additional root. (d, e) Access cavity preparation with four root canals located. (f, g) Final periapical radiographs from different angles.

cold test and electric pulp test. However, there was tenderness upon percussion and palpation. The probing depth was within 3 mm, and there was no mobility in this tooth.

Different angles of periapical radiographs for tooth #46 showed occlusal amalgam restoration, mesial and distal caries, periapical radiolucencies, and an additional root

(Figure 1). The case was diagnosed as a necrotic pulp with symptomatic apical periodontitis.

Endodontic treatment was performed in two visits. In the first visit, under local anesthesia and rubber dam isolation, a modified access cavity was prepared. Four canals were located under operating microscope magnification. The apex

locator was used to determine the working length. After the initial instrumentation was completed, calcium hydroxide was applied, and the access was closed with a cotton pellet and Cavit.

In the second visit, under local anesthesia and rubber dam isolation, the instrumentation was completed using ProTaper and Hyflex CM rotary file (Coltene Whaledent, Altstätten, Switzerland). The canals were irrigated using 6% sodium hypochlorite. Then, paper points were used to dry the canals. The canals were obturated using warm vertical compaction (Figure 1) with Gutta-percha and AH Plus sealer (Maillefer Dentsply, Ballaigues, Switzerland). Then, the access cavity was restored with Cavit. After two weeks, the clinical symptoms disappeared. The patient was referred for final restoration.

### 3. Discussion

Cases with complex canal anatomy, including lower molars with an additional root, require careful clinical and radiographic evaluations, magnification, and identification of all the canals through straight-line access, meticulous cleaning and shaping, copious irrigation, and three-dimensional obturation.

Since the permanent lower first molar can be three-rooted, the diagnosis of such morphology is essential at an early stage. This requires performing periodontal probing, which can enable the identification of the additional root. Furthermore, preoperative periapical radiographs obtained from different angles are needed to explore the existence of a third root [6].

The evaluation of case complexity is important before starting endodontic treatment. Once lower first molars with an additional root are identified, the difficulty of the case should be carefully assessed, and referral to an endodontist is usually required to manage such cases.

In general, different studies have evaluated finishing root canal treatment in a one visit or more. The clinicians can complete the treatment in one or multiple visits [14]. There is no evidence suggesting that it is better to complete the root canal treatment in a single visit or in multiple visits [15].

Due to the unusual location of the additional canal, the access cavity preparation should be modified accordingly to obtain straight-line access, which is necessary to enable proper chemomechanical instrumentation and three-dimensional obturation. Access modification has been reported for lower molars with additional roots [16].

Irrespective of the instrumentation technique to be used in these canals, initial canal negotiation is usually started with K-files of a small size. The small files made of stainless steel are distorted in a curve canal to estimate the curvature and anatomy present [10].

Irrigation is critical for the success of endodontic treatment. Sodium hypochlorite irrigant has a desired antimicrobial effect. Irrigation could be the only method to reach areas that are unreached through the mechanical action alone [17].

Furthermore, a severe curvature also requires special care to prevent instrument separation. Because of the possible presence of a severe canal curvature, the use of files

that are more resistant to fracture by fatigue can be recommended. Therefore, heat-treated files can provide an expected advantage for cleaning and shaping such canals. Superior resistance to fracture by fatigue has been reported for heat-treated files [18].

Moreover, the magnification and illumination using an operating microscope are helpful for enhancing endodontic treatment quality. Furthermore, those features play an important role in difficult cases [19]. Modern endodontic treatment is more effective because of operating microscope usage [20]. In the management of lower molars with additional roots, the operating microscope is useful for locating the canals.

Finally, due to the difficulty of these cases, recent advances in endodontics should be utilized to facilitate high-quality root canal treatment.

### 4. Conclusion

Clinicians' knowledge about root canal anatomy variants in the lower first molars is of critical importance. The identification of lower molars with an additional root should start at an early stage. Proper clinical and radiographic examinations are required. Once the difficulty of the case is determined, referral to an endodontist may be the proper course of action for management.

### Conflicts of Interest

The author declares that he has no conflicts of interest.

### References

- [1] Y. Kimura and K. Matsumoto, "Mandibular first molar with three distal root canals," *International endodontic journal*, vol. 33, no. 5, pp. 468–470, 2000.
- [2] J. L. Bond, G. R. Hartwell, J. C. Donnelly, and F. R. Portell, "Clinical management of middle mesial root canals in mandibular molars," *Journal of Endodontics*, vol. 14, no. 6, pp. 312–314, 1988.
- [3] L. E. Souza-Flamini, G. B. Leoni, J. F. Chaves et al., "The Radix Entomolaris and Paramolaris: A Micro-Computed Tomographic Study of 3-rooted Mandibular First Molars," *Journal of Endodontics*, vol. 40, no. 10, pp. 1616–1621, 2014.
- [4] G. Carabelli, *Systematisches Handbuch der Zahnheilkunde*, Braumuller and Seidel, Vienna, Austria, 2nd edition, 1844.
- [5] L. Bolk, "Bemerkungen über Wurzelvariationen am menschlichen unteren Molaren," *Zeitschrift für Morphologie und Anthropologie*, vol. 17, pp. 605–610, 1915.
- [6] F. L. Calberson, R. J. De Moor, and C. A. Deroose, "The radix entomolaris and paramolaris: clinical approach in endodontics," *Journal of Endodontics*, vol. 33, no. 1, pp. 58–63, 2007.
- [7] R. Zhang, H. Wang, Y. Y. Tian, X. Yu, T. Hu, and P. M. Dummer, "Use of cone-beam computed tomography to evaluate root and canal morphology of mandibular molars in Chinese individuals," *International Endodontic Journal*, vol. 44, no. 11, pp. 990–999, 2011.

- [8] E. Schafer, D. Breuer, and S. Janzen, "The prevalence of three-rooted mandibular permanent first molars in a German population," *Journal of Endodontics*, vol. 35, no. 2, pp. 202–205, 2009.
- [9] C. E. Jerome and J. R. Hanlon, "Dental anatomical anomalies in Asians and Pacific Islanders," *Journal of the California Dental Association*, vol. 35, no. 9, pp. 631–636, 2007.
- [10] F. Abella, S. Patel, F. Duran-Sindreu, M. Mercade, and M. Roig, "Mandibular first molars with disto-lingual roots: review and clinical management," *International Endodontic Journal*, vol. 45, no. 11, pp. 963–978, 2012.
- [11] I. Štampfelj, "Endodontic management of the three-rooted mandibular first permanent molar: a case report," *Acta stomatologica Croatica*, vol. 48, no. 3, pp. 216–223, 2014.
- [12] B. J. Thomas, A. Nishad, B. Paulaian, and J. E. Sam, "Case reports and clinical guidelines for managing radix entomolaris," *Journal of Pharmacy & Bioallied Sciences*, vol. 8, Supplement 1, pp. S160–S163, 2016.
- [13] T. Hitij, L. Hocevar, and I. Štampfelj, "Bilateral presence of radix entomolaris in first and second permanent mandibular molars identified in a Caucasian woman," *BMJ case reports*, vol. 2017, article bcr2016218425, 2017.
- [14] F. Schwendicke and G. Gostemeyer, "Single-visit or multiple-visit root canal treatment: systematic review, meta-analysis and trial sequential analysis," *BMJ Open*, vol. 7, no. 2, article e013115, 2017.
- [15] M. Manfredi, L. Figini, M. Gagliani, and G. Lodi, "Single versus multiple visits for endodontic treatment of permanent teeth," *Cochrane Database of Systematic Reviews*, vol. 12, 2016.
- [16] R. J. De Moor, C. A. Deroose, and F. L. Calberson, "The radix entomolaris in mandibular first molars: an endodontic challenge," *International Endodontic Journal*, vol. 37, no. 11, pp. 789–799, 2004.
- [17] M. Haapasalo, Y. Shen, Z. Wang, and Y. Gao, "Irrigation in endodontics," *British dental journal*, vol. 216, no. 6, pp. 299–303, 2014.
- [18] Y. J. Yang, B. X. Hou, and X. M. Hou, "Metallurgic behavior and mechanical property of nickel-titanium endodontic files made by 3 heat treatment techniques," *Chinese journal of stomatology*, vol. 53, no. 8, pp. 539–545, 2018.
- [19] B. X. Hou, "Role of the operating microscope in diagnosis and treatment of endodontic diseases," *Zhonghua kou qiang yi xue za zhi= Zhonghua kouqiang yixue zazhi= Chinese journal of stomatology*, vol. 53, no. 6, pp. 386–391, 2018.
- [20] The Dental Operating Microscope in Endodontics, *END-ODONTICS: Colleagues for Excellence*, newsletter, Winter, 2016.