



Received: 2014.11.16  
Accepted: 2014.12.17  
Published: 2015.03.25

**Authors' Contribution:**

- A** Study Design
- B** Data Collection
- C** Statistical Analysis
- D** Data Interpretation
- E** Manuscript Preparation
- F** Literature Search
- G** Funds Collection

## Internal Carotid Artery Blister-Like Aneurysm Caused by *Aspergillus* – Case Report

Masaki Ogawa<sup>1DEF</sup>, Keita Sakurai<sup>1BDEF</sup>, Takatsune Kawaguchi<sup>2BDEF</sup>, Aya Naiki-Ito<sup>3D</sup>, Motoo Nakagawa<sup>1DF</sup>, Kenji Okita<sup>4BD</sup>, Noriyuki Matsukawa<sup>4D</sup>, Yuta Shibamoto<sup>1DF</sup>

<sup>1</sup> Department of Radiology, Nagoya City University Graduate School of Medical Sciences, Nagoya, Japan

<sup>2</sup> Department of Radiology, Toyota-kai Medical Corporation Kariya Toyota General Hospital, Nagoya, Japan

<sup>3</sup> Department of Experimental Pathology and Tumor Biology, Nagoya City University Graduate School of Medical Sciences, Nagoya, Japan

<sup>4</sup> Department of Neurology and Neuroscience, Nagoya City University Graduate School of Medical Sciences, Nagoya, Japan

**Author's address:** Masaki Ogawa, Department of Radiology, Nagoya City University Graduate School of Medical Sciences, 1 Kawasumi, Mizuho-cho, Mizuho-ku, Nagoya 467-8601, Japan, e-mail: eternal@fj9.so-net.ne.jp

### Summary

**Background:**

Blister-like aneurysm of the supraclinoid internal carotid artery (ICA) is a well-documented cause of subarachnoid hemorrhage. Generally, this type of aneurysm is associated with various conditions such as hypertension, arteriosclerosis, and ICA dissection. Although *Aspergillus* is the most common organism causing intracranial fungal aneurysmal formation, there is no report of a blister-like aneurysm caused by *Aspergillus* infection.

**Case Report:**

An 83-year-old man received corticosteroid pulse therapy followed by oral steroid therapy for an inflammatory pseudotumor of the clivus. Two months later, the patient was transported to an emergency department due to the diffuse subarachnoid hemorrhage, classified as Fisher group 4. Subsequent 3D computed tomography angiogram revealed a blister-like aneurysm at the superior wall of the left ICA. Six days later, the patient died of subarachnoid hemorrhage caused by the left ICA aneurysm rerupture. Autopsy revealed proliferation of *Aspergillus* hyphae in the wall of the aneurysm. Notably, that change was present more densely in the inner membrane than in the outer one. Thus, it was considered that *Aspergillus* hyphae caused infectious aneurysm formation in the left ICA via hematogenous seeding rather than direct invasion.

**Conclusions:**

The blister-like aneurysm is a rare but important cause of subarachnoid hemorrhage. This case report documents another cause of blister-like aneurysms, that is an infectious aneurysm associated with *Aspergillus* infection.

**MeSH Keywords:**

**Aspergillus • Blister • Carotid Artery, Internal • Mycoses**

**PDF file:**

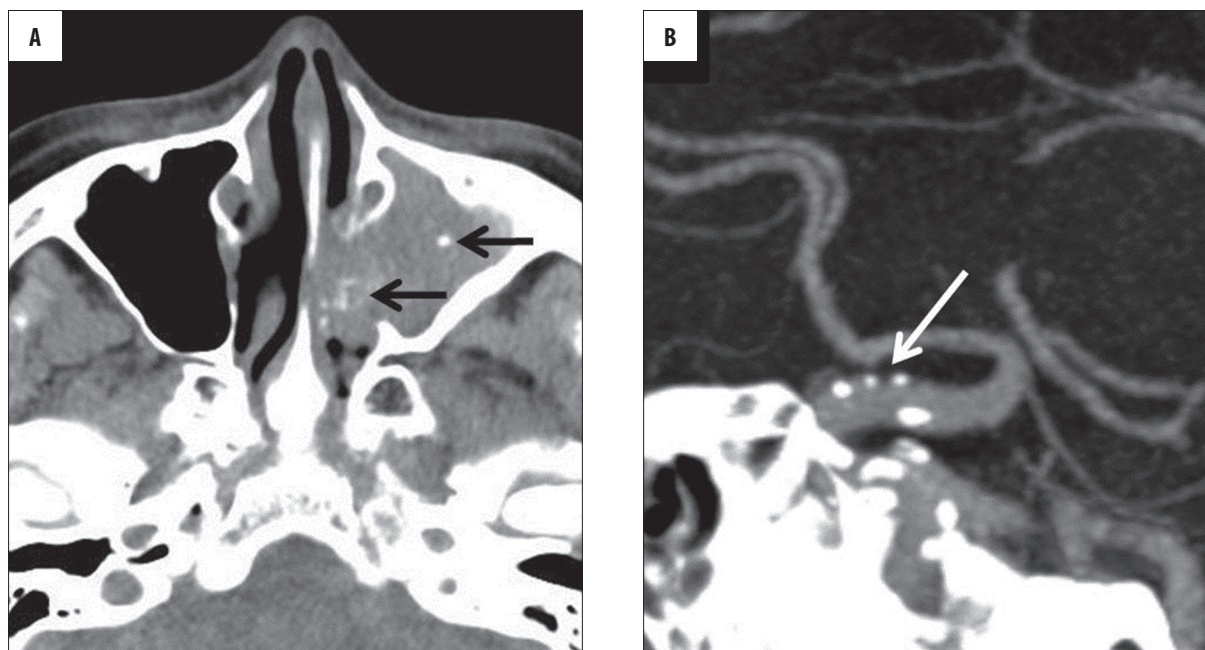
<http://www.polradiol.com/abstract/index/idArt/893050>

### Background

Blister-like aneurysms of the supraclinoid internal carotid artery (ICA), which were initially reported by Sundt and Murphey, represent a rare but well-documented cause of subarachnoid hemorrhage [1,2]. A blood blister-like aneurysm refers to a small hemispherical bulge from the arterial wall, and has been reported to arise at non-branching sites mainly from the dorsomedial wall of ICA [1,3–6]. Frequently, these lesions are associated with hypertension [3,5], arteriosclerosis [5,6], and ICA dissection [4,5]. These

aneurysms are difficult to detect, and their surgical treatment is challenging, with high morbidity and mortality rates [4,7,8].

Mycotic aneurysms involving ICA are also rare. Infectious aneurysms involving the cerebral vasculature represent only 2% to 5% of all intracranial aneurysms [9]. Most infection-associated carotid aneurysms are caused by bacterial pathogens related to infectious endocarditis in contrast to the rare occurrence of fungus-related carotid aneurysms [9,10].



**Figure 1.** CT scan of the paranasal sinuses revealed left maxillary sinusitis with a calcified mass (arrows) and slight bone destruction, suggestive of maxillary sinus aspergilloma (A). Oblique sagittal thin-slab maximum intensity projection image revealed only a mild atherosclerotic change including calcifications and mild arterial wall irregularities without aneurysm formation (arrow; B).

In this article, we reported a case of a blister-like aneurysm in the superior wall of the left ICA caused by infectious vasculitis due to Aspergillosis in a patient treated with steroid therapy.

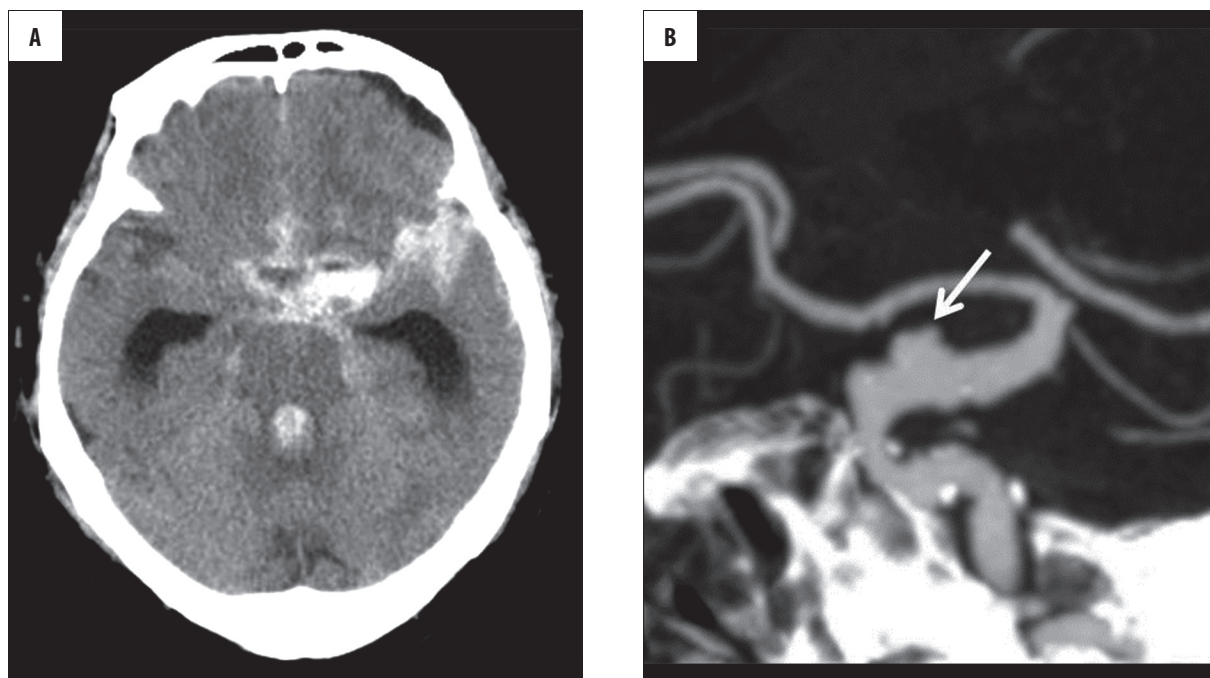
### Case Report

An 83-year-old man presented with headache, facial diplegia and right retrobulbar neuritis. Initial computed tomography (CT) scan of the paranasal sinuses (Figure 1A) revealed left maxillary sinusitis with a calcified mass and slight bone destruction, suggestive of a maxillary sinus aspergilloma. On contrast-enhanced CT (Figure 1B), only a mild atherosclerotic change including calcifications and mild arterial wall irregularities without aneurysm formation was found in his intracranial arteries. In addition to these findings, magnetic resonance imaging (MRI) of the head revealed diffuse abnormal signal intensity and enhancement involving the clivus and surrounding soft tissue including muscles and subcutaneous fat without bone destruction. Blood tests showed mild anemia (hemoglobin, 10.1 g/dL) and an elevated level of C-reactive protein (5.5 mg/dL; normal range <0.3 mg/dL), serum Aspergillus antigens were positive. White blood cell count and other biochemical tests including  $\beta$ -D-glucan were almost normal. In addition to endoscopic open surgery of the left maxillary sinus, a transnasal-transsphenoidal endoscopic biopsy of the clivus was performed with the suspicion of central skull base osteomyelitis. However, histological examinations of the clivus bone tissue specimen, including Grocott's methenamine silver staining and Gram staining, revealed no microorganisms. In the absence of any pathological and biochemical evidence suggestive of infectious disease, he was diagnosed with a non-infectious inflammatory pseudotumor of the clivus. As a result, he received a single course of corticosteroid pulse therapy (500 mg

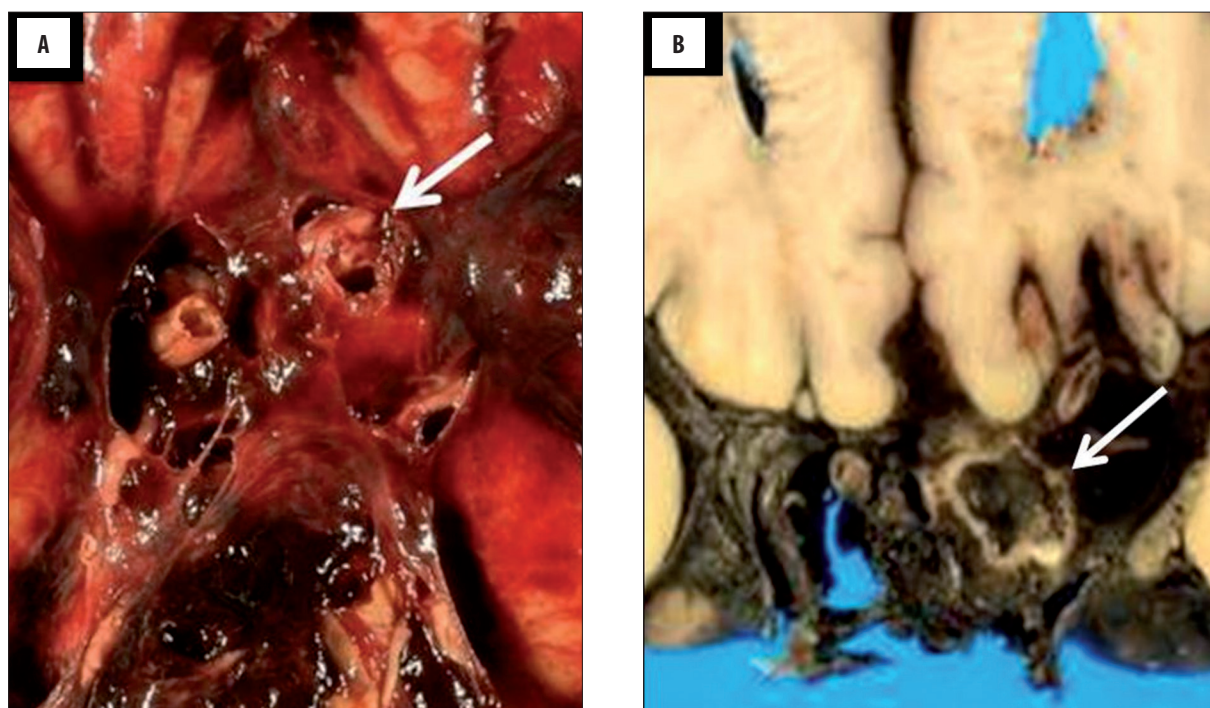
methylprednisolone) followed by oral steroid therapy (50 mg prednisolone). After the medication, the patient was discharged with partial remission of his symptoms and abnormal MRI findings.

Two months later, the patient was transported to an emergency department due to sudden onset of symptoms, including a severe headache and consciousness disturbance, corresponding to Hunt-Hess grade 4. Initial CT images (Figure 2A) revealed diffuse subarachnoid hemorrhage, classified as Fisher group 4, and subsequent 3D-CTA (Figure 2B) revealed a blister-like aneurysm in the superior wall of the left ICA. Aneurysms were depicted as wide-necked shallow outpouchings of the superior and lateral walls of the supraclinoid left ICA. In addition to aneurysmal formation, stenosis of the C4 portion of the left ICA was visualized. No other aneurysms were depicted in his intracranial arteries. Considering his advanced age and neurological condition, conservative instead of radical treatment (including surgical and endovascular treatment) was decided as the therapeutic strategy. Six days later, the patient died of subarachnoid hemorrhage due to the left ICA aneurysm rupture.

The brain, lung, heart and abdominal organs such as the liver, spleen, and kidney were examined at autopsy, whereas paranasal sinuses were not observed in detail. A rupture of the aneurysm in the superior wall of the left ICA was confirmed macroscopically (Figure 3A, 3B), and atherosclerosis was found in the left ICA microscopically. Microscopic findings of the aneurysm were pathologically characterized by destruction of the internal elastic lamina and media, and numerous infiltrating inflammatory cells in the aneurysmal wall. Grocott's staining revealed septate hyphae with acute-angle branching, morphologically consistent with aspergillus species, located in the inflamed



**Figure 2.** CT scan revealed diffuse subarachnoid hemorrhage mainly in the suprasellar cistern, left dominant bilateral Sylvian fissure and ambient cistern with intraventricular hemorrhage (A). Oblique sagittal thin-slab maximum intensity projection image revealed a wide-necked, shallow outpouching aneurysm in the superior wall of the left ICA (arrow; B).



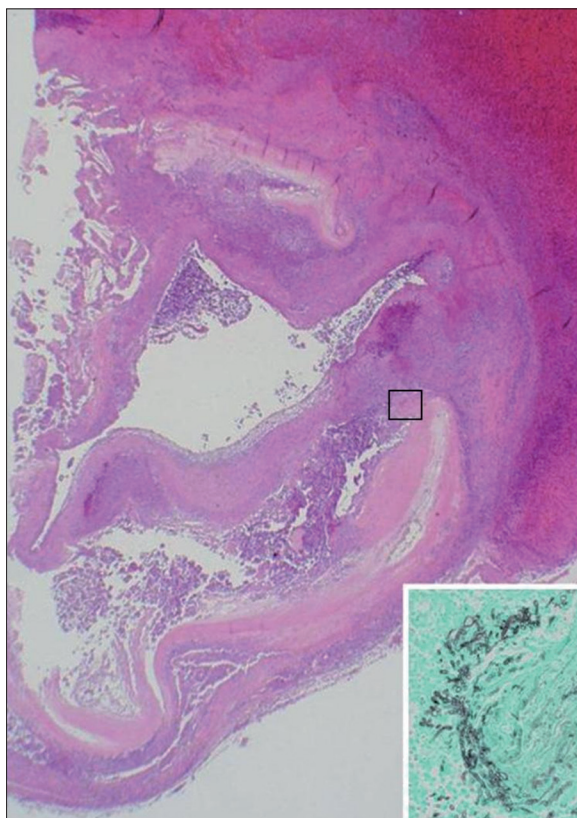
**Figure 3.** At autopsy, a ruptured aneurysm (arrow) was found in the left ICA (A, B).

areas of the arterial and aneurysmal walls (Figure 4). Additionally, the serum *Aspergillus* antigens were positive in the previous days, the final pathological diagnosis was aneurysm caused by *Aspergillus* infection. Notably, Hyphae of *Aspergillus* existed more densely in the inner membrane than in the outer one. Considering the distribution of inflammatory changes and *Aspergillus* hyphae, it was reasonable to suppose that hematogeneous seeding rather than

direct local invasion caused infectious aneurysm formation in the left ICA. However, evidence of *Aspergillus* infection was not found in any organs other than the left ICA.

### Discussion

We reported a rare case of blister-like aneurysm caused by *Aspergillus* infection in a patient treated with steroid



**Figure 4.** Hematoxylin and eosin stain revealed destruction of the elastica interna and media, and numerous infiltrating inflammatory cells in the aneurysmal wall. Destruction of the wall structures was more severe in the inner membrane than in the outer one. Grocott's stain revealed *Aspergillus* hyphae in the inflamed areas of the arterial wall (inset).

therapy. Blister-like aneurysms are thin-walled, broad-based aneurysms which lack identifiable necks and are known to be one of the most difficult lesions to treat [1,3–5,7,8]. Ruptured blister-like aneurysms of the supraclinoid ICA present with subarachnoid hemorrhage and are estimated to represent 0.9–9.4% of ruptured intracranial aneurysms [4,8]. The most frequent location for blister-like aneurysms is the anteromedial wall [5,8]. Compared with saccular aneurysms, these lesions tend to have a more precipitous course, with rapid enlargement and frequent rebleeding [1,4–7]. The imaging appearance of supraclinoid ICA blister-like aneurysms has been described in detail elsewhere [1,4–6,8,11]. Morphologically, they appear as wide-necked, shallow outpouchings of non-branching sites of the supraclinoid ICA. Because of their broad-based, shallow profiles, these aneurysms often represent a diagnostic challenge on both 3D-CTA and conventional angiogram. In addition to comprehension of the morphology and distribution of these lesions, both a meticulous angiographic technique and a high index of suspicion are often required to make the precise diagnosis.

Pathologically, these lesions have been reported to reveal focal wall defects covered with thin fibrous tissue and adventitia, lacking the usual collagen layer, suggestive of pseudoaneurysm formation [5,7,8]. Dissection of the ICA has been proposed as a major causative factor for blood

blister-like aneurysms [4,5,7,8]. Traditionally, the arterial dissection is regarded as a disorder between the internal elastica and media [12]. Interestingly, a recent study has reported that dissections of the cervical internal carotid and vertebral artery affect primarily the outer arterial layers [13]. However, the pathological findings including destruction of the internal elastic lamina and media, and hyphae in the inflamed areas of the aneurysmal wall in the present case were different from those of arterial dissections. These findings were consistent with infectious vasculitis rather than a dissection. Moreover, we found atherosclerosis in the left ICA, but did not find other evidence that a dissection of intracranial vessels was present before *Aspergillus* infections.

Although it has already been reported that various causal factors, including hemodynamic stress and atherosclerosis other than dissections, are also important in the formation of a blister-like aneurysm [3], to our knowledge, there is no report of a blister-like aneurysm caused by *Aspergillus* infection. Infectious aneurysms involving the cerebral vasculature are uncommon lesions, believed to represent only 2% to 5% of all intracranial aneurysms [9]. Intracranial fungal aneurysms are estimated to represent 14% of all carotid infectious aneurysms [14]. Although less common, fungal aneurysms currently occur with increasing frequency with the widespread use of immunosuppressive agents and steroids [9,14]. *Aspergillus* is a ubiquitous fungus that commonly causes diseases in debilitated or immunocompromised patients, and is the most common organism causing intracranial fungal aneurysmal formation [14]. In addition to immune deficiency, the general risk factors are wider administration of antibiotics, corticosteroids and immunosuppressants [10]. Inhalation of airborne spores is a usual mechanism of infection and allows the organism to enter the bronchopulmonary system or paranasal sinuses. The routes of entry into the central nervous system have been reported to be: 1) circulatory propagation from other organs such as the lung; 2) direct invasion from adjacent skull regions such as the middle ear cavity, paranasal sinus, and orbit; and 3) brain surgery, lumbar puncture, and blood transfusion [9,15].

It is well known that *Aspergillus* infection causes infectious vasculitis [15]. The previous report mentioned that infectious vasculitis follows three courses: 1) formation of thrombus, causing hemorrhagic infarction and brain abscess; 2) sudden massive hemorrhage; and 3) formation of an aneurysm [15]. The tendency of *Aspergillus* hyphae to intramural growth results in a configuration and location of fungal aneurysms different from those of the more common bacterial infectious aneurysms [9]. Fungal aneurysms tend to be fusiform in shape and involve longer, more proximal segments of the intracranial vessels, whereas bacterial infectious lesions tend to be distally-located multiple spherical aneurysms with relatively small diameters (ranging from 2 to 5 mm) [9,14,16]. These morphologic differences could enable precise diagnosis.

Intracranial arterial dissections reveal various imaging appearances including arterial stenosis, intramural hematoma and aneurysmal formation [17]. Clinicians do not have difficulty in diagnosing arterial dissections with typical

imaging appearance such as hyperintense intramural hematoma and intimal flap. However, in contrast to these findings, it can be difficult to differentiate between infectious vasculitis and arterial dissection in case of small pseudoaneurysm formation. Particularly, the anatomical characteristic of the superior wall of ICA C2 portion, where hemodynamic stress is high due to superior and lateral directions of its curve, enables various pathological conditions to form pseudoaneurysms similar to the "blister-like aneurysm" [5]. Thus, we recommend clinicians to raise the possibility of infectious vasculitis in the diagnosis of blister-like aneurysms if the patient has risk factors such as previous fungal infection and steroid therapy like in our case.

## Conclusions

We could not find out where the *Aspergillus* hyphae originated from. Autopsy did not reveal aspergillosis in any other organs. Fungal infection of the sinus cavity might therefore have been present and we may have noticed a

small infection if we had examined paranasal sinuses under a microscope at autopsy. However, we did not consider the possibility of infectious aneurysm at the time of autopsy because the maxillary sinus aspergilloma had already been removed at the onset of subarachnoid hemorrhage. Thus, the paranasal sinus was not adequately evaluated at autopsy. The 3D-CTA revealed no aneurysm in patient's intracranial arteries before steroid pulse therapy. The immunosuppressive effects of steroid therapy are considered to have facilitated the propagation of *Aspergillus* infection and caused hematogenous spread to the superior wall of left ICA (in this portion fungal infectious aneurysms tend to occur and fragility due to atherosclerosis might help in destruction of the arterial wall).

## Conflicts of interest disclosure

The authors have no personal financial or institutional interest in any of the drugs, materials, or devices in the article.

## References:

1. Sim SY, Shin YS, Cho KG et al: Blood blister-like aneurysms at nonbranching sites of the internal carotid artery. *J Neurosurg*, 2006; 105: 400-5
2. Sundt TM Jr, Murphey F: Clip-grafts for aneurysm and small vessel surgery. 3. Clinical experience in intracranial internal carotid artery aneurysms. *J Neurosurg*, 1969; 31: 59-71
3. Andaluz N, Zuccarello M: Blister-like aneurysms of the anterior communicating artery: a retrospective review of diagnosis and treatment in five patients. *Neurosurgery*, 2008; 62: 807-11
4. Kamijo K, Matsui T: Acute extracranial-intracranial bypass using a radial artery graft along with trapping of a ruptured blood blister-like aneurysm of the internal carotid artery. *Clinical article. J Neurosurg*, 2010; 113: 781-85
5. Ogawa A, Suzuki M, Ogasawara K: Aneurysms at nonbranching sites in the supraclinoid portion of the internal carotid artery: internal carotid artery trunk aneurysms. *Neurosurgery*, 2000; 47: 578-83
6. Silva JC, Faquini IV, Kitamura MA, Azevedo-Filho HR: Internal carotid artery blood blister-like aneurysm. *Arq Neuropsiquiatr*, 2008; 66: 563-65
7. Lee BH, Kim BM, Park MS et al: Reconstructive endovascular treatment of ruptured blood blister-like aneurysms of the internal carotid artery. *J Neurosurg*, 2009; 110: 431-36
8. Meling TR, Sorteberg A, Bakke SJ et al: Blood blister-like aneurysms of the internal carotid artery trunk causing subarachnoid hemorrhage: treatment and outcome. *J Neurosurg*, 2008; 108: 662-71
9. Hurst RW, Judkins A, Bolger W et al: Mycotic aneurysm and cerebral infarction resulting from fungal sinusitis: imaging and pathologic correlation. *Am J Neuroradiol*, 2001; 22: 858-63
10. Komatsu Y, Narushima K, Kobayashi E et al: *Aspergillus* mycotic aneurysm-case report. *Neurol Med Chir (Tokyo)*, 1991; 31: 346-50
11. Horie N, Morikawa M, Fukuda S et al: Detection of blood blister-like aneurysm and intramural hematoma with high-resolution magnetic resonance imaging. *J Neurosurg*, 2011; 115: 1206-9
12. Friedman AH, Drake CG: Subarachnoid hemorrhage from intracranial dissecting aneurysm. *J Neurosurg*, 1984; 60: 325-34
13. Völker W, Dittrich R, Grewe S et al: The outer arterial wall layers are primarily affected in spontaneous cervical artery dissection. *Neurology*, 2011; 76: 1463-71
14. Hot A, Mazighi M, Lecuit M et al: Fungal internal carotid artery aneurysms: successful embolization of an *Aspergillus*-associated case and review. *Clin Infect Dis*, 2007; 45: e156-61
15. Iihara K, Makita Y, Nabeshima S et al: Aspergillosis of the central nervous system causing subarachnoid hemorrhage from mycotic aneurysm of the basilar artery-case report. *Neurol Med Chir (Tokyo)*, 1990; 30: 618-23
16. Jaworska K, Dołowy J, Kuśmierska M et al: Multiple fusiform cerebral aneurysms – case report. *Pol J Radiol*, 2012; 77(1): 50-53
17. Sakurai K, Miura T, Sagisaka T et al: Evaluation of luminal and vessel wall abnormalities in subacute and other stages of intracranial vertebrobasilar artery dissections using the volume isotropic turbo-spin-echo acquisition (VISTA) sequence: a preliminary study. *J Neuroradiol*, 2013; 40: 19-28