

Published online: 21/08/2014
Published print: 08/2014

doi: 10.5455/aim.2014.22.237-240

ACTA INFORM MED. 2014 AUG 22(4): 237-240
Received: 11 May 2014 • Accepted: 22 June 2014
© AVICENA 2014

ORIGINAL PAPER

Predictive Values of Optical Coherence Tomography (OCT) Parameters in Assessment of Glaucoma progression

Sanja Sefic Kasumovic¹, Aida Kasumovic¹, Suzana Pavljasevic², Emir Cabric³, Milka Mavija⁴, Irena Sesar⁵, Sabina Dacić-Lepara⁶, Mirko Jankov⁷

Eye Policlinic „Dr. Sefić“, Sarajevo, Bosnia and Herzegovina¹

Public Health Centre, Tuzla, Bosnia and Herzegovina²

“Public Health Care Institution Doboju-Jug, Matuzići“, Bosnia and Herzegovina³

University Clinical Center, Banjaluka, Bosnia and Herzegovina

University Clinical Hospital, Mostar

Faculty of Electrical engineering, Sarajevo, Bosnia and Herzegovina

Laser Fokus Centre for Eye Microsurgery, Beograd, Serbia

Corresponding author: Asist.Prof. Sanja Sefić Kasumović, MD, PhD. Eye Policlinic „Dr. Sefić“, Ferhadija 5, 71 000 Sarajevo, B&H.
Email: sefic1@bih.net.ba

SUMMARY

Goal: the purpose of the current study was to estimate the predictive values of optical coherence tomography parameters in early, developed perimetric and terminal glaucoma. **Methods:** 180 eyes of 120 consecutive patients were evaluated in this retrospective cross sectional pilot study. Copernicus Spectral –domain optical coherence tomography with resolution of 3 mm obtained through the optic nerve head were included. All examined eyes were divided to four groups (healthy, early, developed perimetric glaucoma and terminal glaucoma). The values of the thickness of the retinal nerve fibre layer, the size of the disk, the volume of the cup, the E/D parameter and the size of the RIM were compared in four study groups. **Results:** The sensitivity of RNFL was 90,0%, specificity 82,0 %, positive predictability 83,3 % and negative predictability was 89,1 %. The total accuracy was 86,0 % and area under curve (AUC) was 0,878 for RNFL indeks comparing early to developed glaucoma. The sensitivity for CUP was 78%, the specificity was 80,8 %, the positive predictability 81,2% and the negative predictability was 77,5 %. The total accuracy was 79,3 % and area under curve (AUC) was 0,86 comparing early to developed glaucoma. The sensitivity for E/D was 82,0%, the specificity was 82,9 % the positive predictability 83,7 % and the negative predictability was 81,3 %. The total accuracy was 82,5 % and area under curve (AUC) for E/D was 0,89 comparing early to developed glaucoma. The sensitivity for RIM was 78,0%, the specificity was 76,6 %, the positive predictability was 84,7 and the negative predictability was 67,7 %. The total accuracy was 77,5 % and area under curve (AUC) for the RIM comparing the developed to terminal glaucoma was 0,792. The sensitivity of RNFL was 88,0 %, the specificity was 66,7 %, the positive predictability was 81,5% and the negative predictability was 76,9%. The total accuracy was 80,0% and the area under curve (AUC) for RNFL comparing developed to terminal glaucoma was 0,815. The increasing 0,1 unit RNFL decreases the risk of developing glaucoma from early to another developed stage of glaucoma for 6,95%. The increasing of E/D for only one unit increases the risk to develop another stage of glaucoma for 18,75 times. The increasing of RNFL for only one unit decreases the risk of performing developed glaucoma from initial stage for 7,8%. The increasing for only one unit of CUP increases the risk to develop terminal glaucoma for 8,47 times and increasing for 0,1 unit of the value of RIM decreases the risk developing terminal glaucoma for 9,27%. The increasing for 0,01 unit of the E/D index increases the risk for terminal glaucoma for 23,23 times. The increasing for one unit of RNFL decreasing the risk developing terminal glaucoma for 5,7%.

Key words: glaucoma, progression, optical coherence tomography, optic disc morphology.

1. INTRODUCTION

The progressive glaucomatous optic disc atrophy is characterized by the optic disc changes, including enlargement of the optic disc cup and the loss of the neuroretinal rim. Morphologic changes may precede loss of function as the tests of the visual field (1, 2). Optical coherence tomography (OCT) was introduced approximately 20 years ago and has achieved an important role in present clinical diagnostics (3, 4).

With aim to diagnosed glaucoma it is fundamental to identify glaucoma progression in order to intensify the treatment before nerve fiber loss proceeds. In terminal glaucoma the deterioration can be identified by

the changes in the visual field testing and the thinning of the nerve fibre layer (5).

Few data exist about long term course of OCT measurements and its relevance for detection of glaucoma progression. Wollstein et al.(6) found a loss of average RNFL thickness of 11,7 microns within 4,7 years in glaucoma patients.

2. AIM OF THE STUDY

The aim of the study is to emphasise which index of OCT testing shows the most important predictor values to identify the glaucoma progression.

3.3. METHODS

Total number of 180 eyes of 120 consecutive patients were evaluated in this retrospective cross sectional pilot study. Copernicus SD-OCT with resolution of 3 mm obtained through the optic nerve head (ONH) were included. All examined eyes were divided to four groups. The size of the disc (size), the volume of cup (cup), cup/disc ratio (E/D), size of the rim (rim) and the thickness of the retinal nerve fibre layer (RNFL) were observed in 50 healthy eyes, 50 eyes with the signs of initial open angle, preperimetric glaucoma, 50 eyes with developed simplex glaucoma and 30 eyes with terminal glaucoma signs (final glaucomatous atrophy). Exclusion criteria were ocular hypertension, other optic nerve neuropathies causing optic nerve atrophy and angle closure glaucoma. The diagnosis of glaucoma was made if one or more of the following morphological criteria were present : thinning or notching of the neuroretinal rim, loss of peripapillary RNFL, unfulfilled inferior-superior, nasal-temporal rule. Pathologic visual field test results associated with a pathologic optic disc configuration confirmed the diagnosis but were not necessary for the inclusion to the study.

These results were incorporated in the final statistical conclusion.

All statistical analyses were performed in SPSS for Windows v17.0 (SPSS Inc., Chicago, IL, USA). The specificity and sensitivity OCT parameters as potential markers progression of disease was investigated by ROC curve. Binary logistic regression was performed to show how changing variables can influence progression of the disease. All the tests were performed with the significance level of 0.05.

4. RESULTS

Results are presented in Tables 1-3 and Figures 1-2-

An increasing of the RIM for 1 unit decreases the risk to develop manifest glaucoma for 69,5%. The increasing of the E/D relation for 0,01 unit increases the risk developing manifest glaucoma for 17,75%. The enlargement of the RNLF index for one unit decreases the risk developing manifest glaucoma from initial stage of the disease for 7,8% (Table 1).

The increasing of the CUP for 0,1 unit increases the risk developing absolute glaucoma for 74,7 %. The increasing of the RIM-a for 1 unit decreases the risk to develop terminal glaucoma for 92,7 %. The enlargement of the E/D relation for 0,001 unit increases the risk developing absolute glaucoma for 22,27 %. The increasing of the RNLF for only one unit decreases the risk of terminal glaucoma for 5,7% (Table 2).

The sensitivity for the CUP was 78,0%, the speci-

Variables	B	S.E	Wald	df	p=	OR	95,0% CI	
							lower	upper
RIM	-1,181	0,571	4,331	1	0,037	0,305	0,100	0,933
E/D	2,932	1,397	4,403	1	0,036	18,757	1,213	289,958
RNFL	-0,081	0,17	22,436	1	0,000002	0,922	0,891	0,953

Table 1. Independent predictors of progression glaucoma from initial to developed stage (binar logistic regression)

Variables	B	S.E	Wald	df	p=	OR	95,0% IC	
							lower	upper
CUP	2,137	0,748	8,168	1	0,004	8,478	1,957	36,717
RIM	-2,618	0,696	14,165	1	0,0001	0,073	0,019	0,285
E/D	7,751	1,807	18,389	1	0,00001	2323,792	67,246	80301,870
RNFL	-0,058	0,015	15,824	1	0,00006	0,943	0,917	0,971

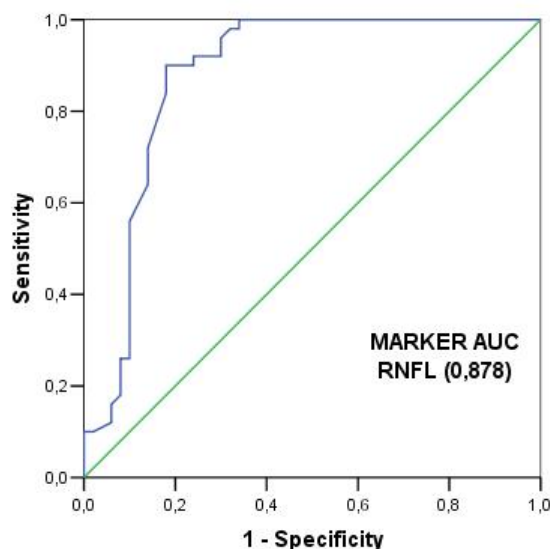
Table 2. The independent predictors of progression terminal, absolute glaucoma from developing stage of the disease (binar logistic regression)

marker	Sensitivity (%)	Specificity (%)	PP (%)	NP (%)	AUC	CI	p<
CUP cut off (0,56)	78,0	80,8	81,2	77,5	0,866	0,794-0,938	0,005
E/D cut off (0,305)	82,0	82,9	83,7	81,3	0,899	0,838-0,959	0,005

Table 3. The sensitivity and specificity OCT parameters in assesment of early stages glaucoma (incipient vs. control eyes). PP –positive predictive value. NP –negative predictive value. CI – confidence interval. AUC- area under curve

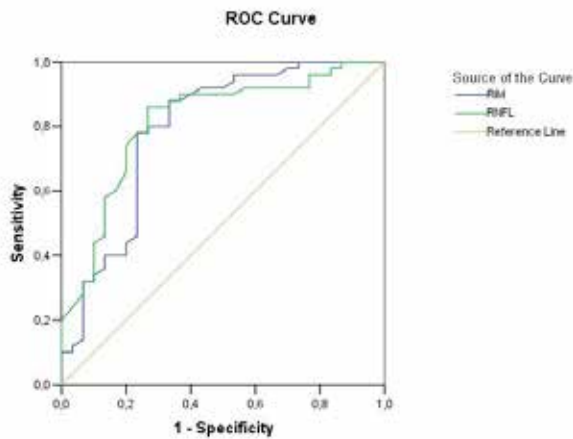
city 80,8%, the positive predictability 81,2%, negative predictability 77,5%. The total or final accuracy was 79,3%. AUC for CUP was 0,866 (Table 3).

The sensitivity for the E/D was 82,0%, the specificity 82,9%, the positive predictability 83,7%, negative predictability was 81,3%. The final accuracy was



marker	Sensitivity (%)	Specificity (%)	PP (%)	NP (%)	AUC	CI	p<
RNFL cut off (99,50)	90,0	82,0	83,3	89,1	0,878	0,803-0,954	0,005

Figure 1. The sensitivity and the specificity of the OCT parameters in an assessment the initial to developing glaucoma (initial vs. developed perimetric glaucoma) PP –positive predictive value, NP –negative predictive value, CI – confidence interval, AUC- area under curve



marker	Sensitivity (%)	Specificity (%)	PP (%)	NP (%)	AUC	CI	p <
RIM cut off (0,56)	78,0	76,6	84,7	67,6	0,792	0,681-0,903	0,005
RNFL cut off (63,5)	88,0	66,7	81,5	76,9	0,815	0,715-0,914	0,005

Figure 2. The sensitivity and the specificity of OCT parameters in assesment terminal glaucoma compering to developed glaucoma (developed vs. terminal glaucoma). PP –positive predictive value, NP –negative predictive value, CI – confidence interval, AUC–area under curve

82,5%. AUC for the E/D was 0,899. The sensitivity for the RNFL was 90,0%, the specificity was 82,0%, the positive predictability was 83,3%, the negative predictability was 89,1%. The final accuracy was 86,0%. AUC for the RNFL was 0,878 (Figure 1).

The sensitivity of the RIM was 78,0%, the specificity was 76,6%, the positive predictability was 84,7%, negative predictability was 67,6%. The final accuracy was 77,5%. The AUC for RIM was 0,792.

The sensitivity for the RNFL was 88,0%, the specificity was 66,7%, the positive predictability 81,5%, negative predictability was 76,9%. The total accuracy was 80,0%. The AUC for RNFL was 0,815 (Figure 2).

5. DISCUSSION

Our opinion is that the detection of progression is crucial for prognosis in glaucoma. The morphologic changes in adults are incurable. Reduction of the intraocular pressure is the main therapeutic strategy to predict and avoid progression of the disease (7).

Lee et al. (8) performed a trend-based analysis using Stratus OCT. The rate of progression of -1,58 microns per year in progressors and of -0,34 microns per year in nonprogressors. The rate of change found by Medeiros et al. (9) in the trend based analysis was lower with a rate of change of -0,72 microns per year in progressors.

Krupa et al. (10) showed that E/D parameter had the highest sensitivity and speciticity as well as high positive likelihood ratio and near-zero negative likelihood ratio. The NFI and MD parameters showed lower likelihood ratios and their applicability for the diagnosis of primary open-angle glaucoma is limited. These results are according to our study results.

Wang et al.(11) identified several structural features that were significantly different between healthy and glaucomatous eyes. Axonal loss as well as remodeling would contribute to smaller lamina cribrosa pores creating in beam thickness to pore diametar ratio with disease. They observed a significant increase in pore diameter in glaucomatous eyes. It may represent focal damage in glaucoma causing some pores to drastically lose diameter thus increasing the the variabiliy in the structure in optic nerve head.

DARC (Detection of apoptotic retinal cells) is going to be the new technique which utilizes the unique optical properties of the eye to directly visualize retinal ganglion cell death. It gives glaucoma physicians the opportunity to detect glaucoma earlier and monitor the response to treatment in a visual and quantifiable manner (12,13).

Werkmeister et al. (14) emphasised that imaging in glaucoma patients focuses on ONH, the RNFL and te RGC layer. Among these options, the imaging of RGCs is the most promising approach because the loss of RGCs is directly associated with the characteristic glaucomatous visual field loss. The understanding of the structure-functional relationship in glaucoma has also significantly increased (15, 16).

6. CONCLUSION

In conclusion, we demonstrated the importance of the structural changes of optic nerve head with aim to asses the management and treatment of progressive glaucoma eye in spite of good funcional results and no thinning of RNFL. Glaucomatous eyes typically had thinner RNFL but the statistically different structural ratios inside the optic nerve head. Therefore it is important to consider the changes inside the optic disc under the regular clinical glaucoma follow up.

It is an exciting time for physicians and over the next decade will certainly see advances in early detection (RNFL) and efficacious treatments and neuro-protection (structural changes of ONH).

CONFLICT OF INTEREST: NONE DECLARED.

REFERENCES

1. Chauhan BC, Nicolela MT, Artes PL. Incidence and rates of visual field progression after longitudinally measured optic disc change in glaucoma. *Ophthalmology*. 2009; 116: 2110-2118.
2. Huang D, Swanson FA, Lin CP. et al. Optical coherence tomography. *Science*. 1991; 254: 1178-1181.
3. Puliafito CA, Hee MB, Lin CP. et al. Imaging of macular disases with optical coherence tomography. *Ophthalmology*. 1995; 102: 217-229.
4. Schuman JS, Hee MB, Lin CP. et al. Quantification of nerve fibre layer thickness in normal and glaucomatous eyes using optical coherence tomography. *Arch Ophthalmol*. 1995; 113: 586-596.
5. Nukada M, Hangai M, Mori S. et al. Detection of local-

ised retinal nerve fibre layer defects in glaucoma using enhanced spectral-domain optical coherence tomography. *Ophthalmology*. 2011;118:1038-1048.

6. Wollstein G, Schuman JS, Price I. et al. Optical coherence tomography longitudinal evaluation of retinal nerve fibre layer thickness in glaucoma. *Arch Ophthalmol*. 2005; 123: 1038-1048.
7. Wessel JM, Horn FK, Tornow RP, Schmid M, Mardin CY, Kruse FE, Juenemann AG, Laemmer R. Longitudinal analysis of progression in glaucoma using spectral domain optical coherence tomography. *Invest Ophthalmol Vis Sci*. 2013; 54: 3613-3620.
8. Lee FL, Kim TW, Weinreb RN. Trend based analysis of retinal nerve fiber layer thickness measured by optical coherence tomography in eyes with localised nerve fibre layer defects. *Invest Ophthalmol Vis Sci*. 2011; 52: 1183-1144.
9. Medeiros FA, Zangwill LM, Alencar LM. et al. Detection of glaucoma progressin with stratus OCT retinal nerve fibre layer optic nerve head and macular thickness measurements. *Invest Ophthalmol Vis Sci*. 2009; 50: 5741-5757.
10. Polaczek-Krupa B, Grabska-Liberek I. Applicability of standard parameters in diagnostics of primary open-angle gtlaucoma. *Med Sci Monit*. 2013;19: 657-660.
11. Wang B, Nevins JE, Nadler Z, Wollstein G, Ishikawa H, Bilonick RA, Kagemann I, Sigal IA, Grulkowski I, Liu JJ, Kraus M, Lu CD, Hornegger J, Fujimoto Jg, Schuman JS. In vivo lamina cribrosa microarchitecture in healthy and glaucomatous eyes as assessed by optical coherence tomography. *Invest Ophthalmol Vis Sci*. 2013; 54: 8270-8274.
12. Guo L, Cordeiro MF. Assessment of neuroprotection in the retina with DARC. *Prog Brain Res*. 2008; 173: 437-450.
13. Kersey T, Clement CI, Bloom P, Cordeiro MF. New trends in glaucoma risk, diagnosis and management. *Indian Journal of Medical Research* 2013; 137: 659-668.
14. Werkmeister RM, Popa Cherecheanu A, Garhofer G, Schmidl D, Schmetterer. Imaging of retinal ganglion cells in glaucoma : pitfalls and challenges. *Cell Tissue Res*. 2013; 353(2): 261-268.
15. Malik R, Swanson WH, Ggarway-Heath DF. „Structure- function relationship“ in glaucoma: past thinking and current concepts. *Clin Exp Ophthalmol*. 2012; 40: 369-380.
16. Medeiros FA, Lisboa R, Weinreb RN, Girkin Ca, Liebmann JM, Zangwill LM. A combined index of structure and function for staging glaucomatous damage. *Arch Ophthalmol*. 2012; 130: 1107-1116.