



Since January 2020 Elsevier has created a COVID-19 resource centre with free information in English and Mandarin on the novel coronavirus COVID-19. The COVID-19 resource centre is hosted on Elsevier Connect, the company's public news and information website.

Elsevier hereby grants permission to make all its COVID-19-related research that is available on the COVID-19 resource centre - including this research content - immediately available in PubMed Central and other publicly funded repositories, such as the WHO COVID database with rights for unrestricted research re-use and analyses in any form or by any means with acknowledgement of the original source. These permissions are granted for free by Elsevier for as long as the COVID-19 resource centre remains active.



Research Article

Temporal changes of lung computed tomography findings pulmonary COVID-19 infection

Bitā Abbasi^a, Masoud Pezeshki-Rad^a, Hourieh Soleimani^{a,*}, Mahnaz Mozdourian^b, Reza Akhavan^c
and Mona Maftouh^a

^a Department of Radiology, Faculty of Medicine, Mashhad University of Medical Sciences, Mashhad, Iran

^b Lung Disease Research Center, Faculty of Medicine, Mashhad University of Medical Sciences, Mashhad, Iran

^c Department of Emergency Medicine, Faculty of Medicine, Mashhad University of Medical Sciences, Mashhad, Iran

Available online xxx

ABSTRACT

Objectives: COVID-19 infection demonstrates characteristic findings in chest CT. The optimal timing of repeated CT scans still needs to be clarified, and the optimal time to assess imaging clearance in COVID-19 is still unknown. It is crucial to have a roadmap of the imaging course of COVID-19 pneumonia to develop guidelines for prompt diagnosis of pulmonary complications, especially fibrosis, at the earliest stage.

Purpose: To assess the temporal changes of chest CT findings in patients with COVID-19 pneumonia and evaluate the rate of a complete resolution and determine the patients are at excessive risk for residual parenchymal abnormalities.

Materials and Methods: This retrospective observational study included 48 patients with real-time polymerase chain reaction-confirmed COVID-19 who were admitted to three academic hospitals. These patients underwent at least one initial chest CT before or after admission and at least one follow-up CT scan four weeks or more after the onset of the symptoms. All chest CTs were categorized according to time of performance into four groups, including the first week, second week, third-fourth week, and more than 28 days. Lung involvement was categorized as predominantly alveolar (ground-glass opacity and consolidation), organizing pneumonia, and reticular patterns. The severity of involvement was also evaluated by the reader.

Results: Forty-eight patients and a total of 130 chest CT scans were evaluated. The alveolar pattern showed a gradual decrease in frequency from 91% in the first week to 9% after the fourth week of the disease but the organizing pneumonia pattern gradually increased with disease progression and the frequency of reticular pattern increased significantly after third week. Complete resolution of CT findings was seen in 17 patients (13.1%) and was significantly more prevalent in patients of younger age (p value < 0.001) and with lower initial CT severity scores (p value = 0.048). CT severity scores in the second week were significantly higher in ICU admitted patients (p value = 0.003).

Conclusion: There are temporal patterns of lung abnormalities in patients with COVID-19 pneumonia. The predominant CT pattern was alveolar infiltrate in the first and second weeks of the disease, replaced with an organizing pneumonia pattern in the third and fourth weeks. Progression of lung involvement was correlated with ICU admission due to the highest CT severity score in the second and third weeks of presentation but not in the first week in patients who were admitted at ICU. Complete CT resolution was significantly more common in patients of younger age and lower initial CT severity scores.

RÉSUMÉ

Objectifs: L'infection à COVID-19 présente des résultats caractéristiques au scanner thoracique. Le moment optimal pour répéter les

Contributors: All authors contributed to the conception or design of the work, the acquisition, analysis, or interpretation of the data. All authors were involved in drafting and commenting on the paper and have approved the final version.

Funding: This study did not receive any specific grant from funding agencies in the public, commercial, or not-for-profit sectors.

Competing interests: The authors declare no conflict of interest.

Ethical Approval: The Ethics committee of the Mashhad University of Medical Science, Iran, approved this retrospective observational study and the review board waived informed consent due to the observational nature of the research and the epidemic of COVID-19 as an emergency public health event.

* Corresponding author at: Radiology Department, Imam Reza hospital, Razi Sq., Mashhad, Iran

E-mail address: SoleimaniH971@mums.ac.ir (H. Soleimani).

tomographies doit encore être clarifié, et le moment optimal pour évaluer l'intervalle d'imagerie dans le cas de la COVID-19 est encore inconnu. Il est crucial d'avoir une feuille de route de l'évolution de l'imagerie de la pneumonie à COVID-19 afin de développer des directives pour un diagnostic rapide des complications pulmonaires, en particulier la fibrose, au stade le plus précoce.

But: Évaluer les changements temporels des résultats du scanner thoracique chez les patients atteints de pneumonie à COVID-19, évaluer le taux de résolution complète et déterminer les patients présentant un risque excessif d'anomalies parenchymateuses résiduelles.

Matériel et méthodologie: Cette étude observationnelle rétrospective a inclus 48 patients dont la réaction en chaîne par polymérase en temps réel a confirmé la présence de COVID-19 et qui ont été admis dans trois hôpitaux universitaires. Ces patients ont subi au moins un scanner thoracique initial avant ou après leur admission et au moins un scanner de suivi quatre semaines ou plus après l'apparition des symptômes. Toutes les tomographies thoraciques ont été classées selon le moment de leur réalisation en quatre groupes, à savoir la première semaine, la deuxième semaine, la troisième-quatrième semaine et plus de 28 jours. L'atteinte pulmonaire a été classée en trois catégories: alvéolaire prédominante (opacité en verre dépoli et consolidation), pneumonie organisée et schémas réticulaires. La gravité de l'atteinte a également été évaluée par le lecteur.

Résultats: Quarante-huit patients et un total de 130 tomographies thoraciques ont été évalués. Le schéma alvéolaire a montré une diminu-

Keywords: COVID-19; pneumonia; CT; temporal changes; Chest

Introduction

COVID-19 infection demonstrates characteristic findings in chest CT. The imaging findings change during the disease, and physicians need to be familiar with various imaging patterns. The hallmark of COVID-19 is the presence of bilateral patchy ground-glass opacities (GGOs) that may coalesce into dense consolidation in the course of the disease [1]. As the disease progresses, new lesions may occur in the previously unaffected areas of the lung. The density and number of lesions may also change over time. These findings represent foci of edema, organizing pneumonia, and diffuse alveolar damage [2]. The lesions are typically gradually absorbed over two weeks [3], but in some patients, inflammation matures to form residual fibrosis [2].

Repeated CT scans can help identify the early and long-term complications of COVID-19 pneumonia, although at the cost of extra ionizing doses. The optimal timing of repeated CT scans still needs to be clarified, and the optimal time to assess imaging clearance in COVID-19 is still unknown. The general recommendation is to repeat chest radiograph (CXR) six weeks after community-acquired pneumonia to exclude primary bronchial neoplasms [4]. However, the patchy ground-glass opacity in COVID-19 pneumonia is less probable of harboring underlying malignancy, particularly in the context of the pandemic [2]. Although the data are still limited for COVID-19 pulmonary sequela, there may be essential parallels from the severe acute respiratory syndrome (SARS) outbreak of 2002–2003 caused by SARS-CoV and the Middle East respiratory

syndrome (MERS) first identified in 2012 [2]. Air-space opacification and reticulation are the most commonly reported residual imaging findings in SARS/MERS patients [5,6], found 3–6 months after the initial diagnosis. It is crucial to have a roadmap of the imaging course of COVID-19 pneumonia to develop guidelines for prompt diagnosis of pulmonary complications, especially fibrosis, at the earliest stage.

This study aimed to evaluate the temporal changes of chest CT findings in patients with COVID-19 pneumonia.

Conclusion: Il existe des schémas temporels d'anomalies pulmonaires chez les patients atteints de pneumonie à COVID-19. Le modèle TDM prédominant était un infiltrat alvéolaire au cours des première et deuxième semaines de la maladie, remplacé par un modèle de pneumonie organisée au cours des troisième et quatrième semaines. La progression de l'atteinte pulmonaire était corrélée à l'admission en soins intensifs, le score de gravité tomодensitométrique étant le plus élevé au cours des deuxième et troisième semaines de présentation, mais pas au cours de la première semaine chez les patients admis en soins intensifs. La résolution complète de l'atteinte pulmonaire par tomодensitométrie était significativement plus fréquente chez les patients plus jeunes et présentant des scores de gravité tomодensitométrique initiaux plus faibles.

Methods and materials

Patient selection

The Ethics committee of the Mashhad University of Medical Science, Iran, approved this retrospective observational study and the review board waived informed consent due to the observational nature of the research and the epidemic of COVID-19 as an emergency public health event.

Patients with confirmed COVID-19 pneumonia who were admitted to the isolation wards of three academic hospitals from January 16, 2020, to March 17, 2020, were evaluated using the following inclusion criteria; at least one positive real-time reverse transcriptase-polymerase chain reaction (RT-PCR) result for severe acute respiratory syndrome coronavirus 2 (SARS-CoV-2) in oropharyngeal swabs was obtained

before or after admission, at least one CT scan with lung abnormalities before or after admission, available electronic records, and at least one follow-up CT scan performed four weeks or more after the onset of the symptoms. No specific exclusion criteria were applied.

CT protocol

All chest CT exams were performed in a caudocranial direction using a commercially available 16-slice CT scanner (NeuViz 16 Essence, Neusoft Medical Systems, China). All the scans were done in the supine position with arms extended over the head.

Image Interpretation

The images were retrieved from PACS, anonymized, and transferred into a dedicated workstation and analyzed using OSIRIX MD™ (version 10.0.1) software and a medical monitor. A radiologist with ten years of experience (BA) reviewed all the images. CT images were assessed in line with the descriptors defined by the Fleischner Society [7,8] regarding the presence of alveolar pattern characterized as ground-glass opacity (GGO) (increased parenchymal attenuation without the obstruction of underlying vasculature), consolidation (increased parenchymal attenuation with obstruction of underlying vasculature), or a combination of consolidation and GGO. The presence of rounded GGO/consolidation, halo sign, architectural distortion, or parenchymal lines was also evaluated. The laterality and distribution of parenchymal abnormalities in the transverse (central, peripheral, and diffuse) were assessed. The outer third of the lung was defined as peripheral, and the inner two-thirds were defined as central. The reading radiologist was asked to categorize each CT scan according to the dominant parenchymal finding into one of the following categories; Alveolar infiltrates pattern (mostly ground-glass opacity and/or consolidation), organizing pneumonia pattern (mostly consolidations associated with parenchymal distortions), fibrotic pattern (mostly reticulations and linear stripes), or normal.

For all scans, the extent of involvement on thin-slice CT images was evaluated by the radiologist. We used the method previously applied by Wang et al. [8]. This method uses lung opacification as a criterion for the extent of the disease in the lungs. Each lung was divided into three zones: the upper zone (above the carina), the middle zone (from the carina to the inferior pulmonary vein), and the lower zone (below the inferior pulmonary vein). The degree of involvement in each zone was scored as follows: a score of 0 denoted no involvement; one, < 25% involvement; two, 25% to less than 50% involvement; three, 50% to less than 75% involvement; and four, \geq 75% involvement. The total score ranged from 0 to 24.

The CT studies were categorized according to the time interval between symptom initiation and CT acquisition (in weeks), into the acute (first week), early subacute (second week), late subacute (weeks three and four), and chronic phase (after the fourth week).

Statistical analysis

Data analysis was performed using SPSS software (version 23.0, SPSS Inc., Chicago, Ill).

We summarized continuous variables using mean \pm SD or median and interquartile range (IQR) when appropriate. Categorical variables are presented as n (%). In all statistical analyses, $p < 0.05$ was considered statistically significant. As most variables were non-parametric, we used Mann-Whitney test to compare quantitative variables between two groups, and Kruskal-Wallis test to compare them between more than two groups.

Results

Patient characteristics

A total of 130 computed tomographic examinations related to 48 patients were evaluated. At least one follow-up chest CT scan with a minimum time interval of four weeks from the initial CT examination was performed for each patient. Each patient underwent a mean of 2 (SD 1.06) CT scans. The median time interval between symptom onset and initial CT scan was 8 (5-11 IQR) days. The median time interval between symptom onset and follow-up CT scan was 39 (23.75-89 IQR) days. The median time interval between the initial and follow-up CTs was 31 (16-84 IQR) days. The demographic and laboratory data are summarized in Table 1.

Temporal changes of CT findings

The predominant pattern of abnormality was alveolar in the first two weeks and organizing pneumonia in the third and fourth weeks. The alveolar pattern saw a gradual decrease in frequency from 91% in the first week to 9% after the fourth week of the disease. On the contrary, the organizing pneumonia pattern gradually increased with disease progression. We had one case of a complete resolution and one case of reticular pattern in the third-fourth week. Still, all other instances of reticulation and complete resolution were seen after the fourth week of symptom initiation (Figures 1-4).

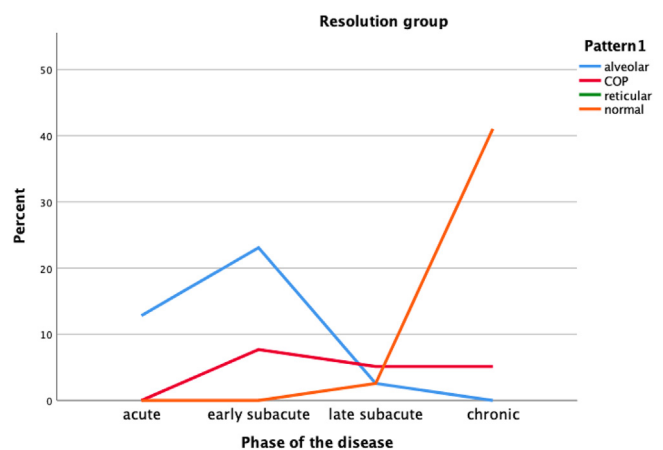


Figure 1. The frequency of CT pattern distribution in the resolution group.

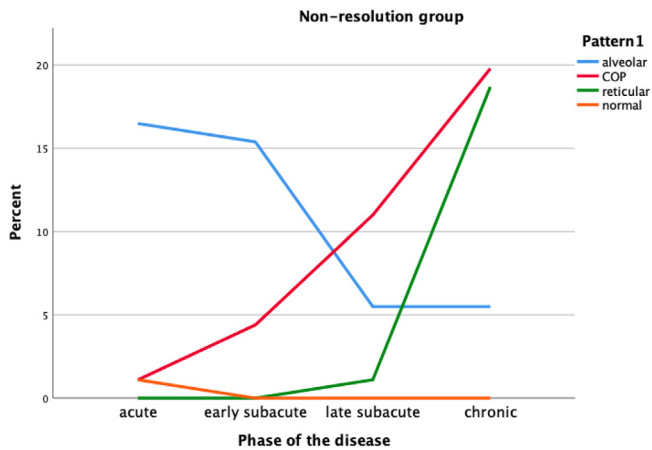


Figure 2. The frequency of CT pattern distribution in the non-resolution group.

We investigated the temporal changes of the CT severity score which showed a marked increase in the second week (Figure 5), and were significantly different in the various phases

of the disease (Kruskal Wallis test, $p: 0.000$). A comparison of the CT severity scores at different phases of the disease between the two groups is summarized in Figure 5. The alveolar pattern of involvement is seen in 39 (42.9%) patients without and 15 (38.5%) patients with complete resolution. The organizing pneumonia pattern is seen in 33 (36.3%) patients without and 7 (17.9%) patients with complete resolution. The reticular pattern is seen in 18 (19.8%) patients without and 0 (0%) patients with complete resolution (chi square, $p: 0.000$).

Only one patient had a normal CT scan at the time of admission. CT findings were completely resolved in 17 (36%) patients. There was a significant difference in the initial CT severity score ($p: 0.048$) and age ($p: <0.001$) between the patients with and without complete CT resolution. No significant difference was seen in the two groups regarding the prevalence of hypertension ($p: 0.65$), diabetes mellitus ($p: 0.62$), coronary artery disease ($p: 0.2$), and COPD ($p: 0.4$) (Table 2).

Among the 48 studied patients, 18 were admitted to the ICU at some point during their hospitalization. We compared the CT severity scores between patients admitted in the ICU and those not (Figure 6). Only 4 (8.3%) mortality cases were in

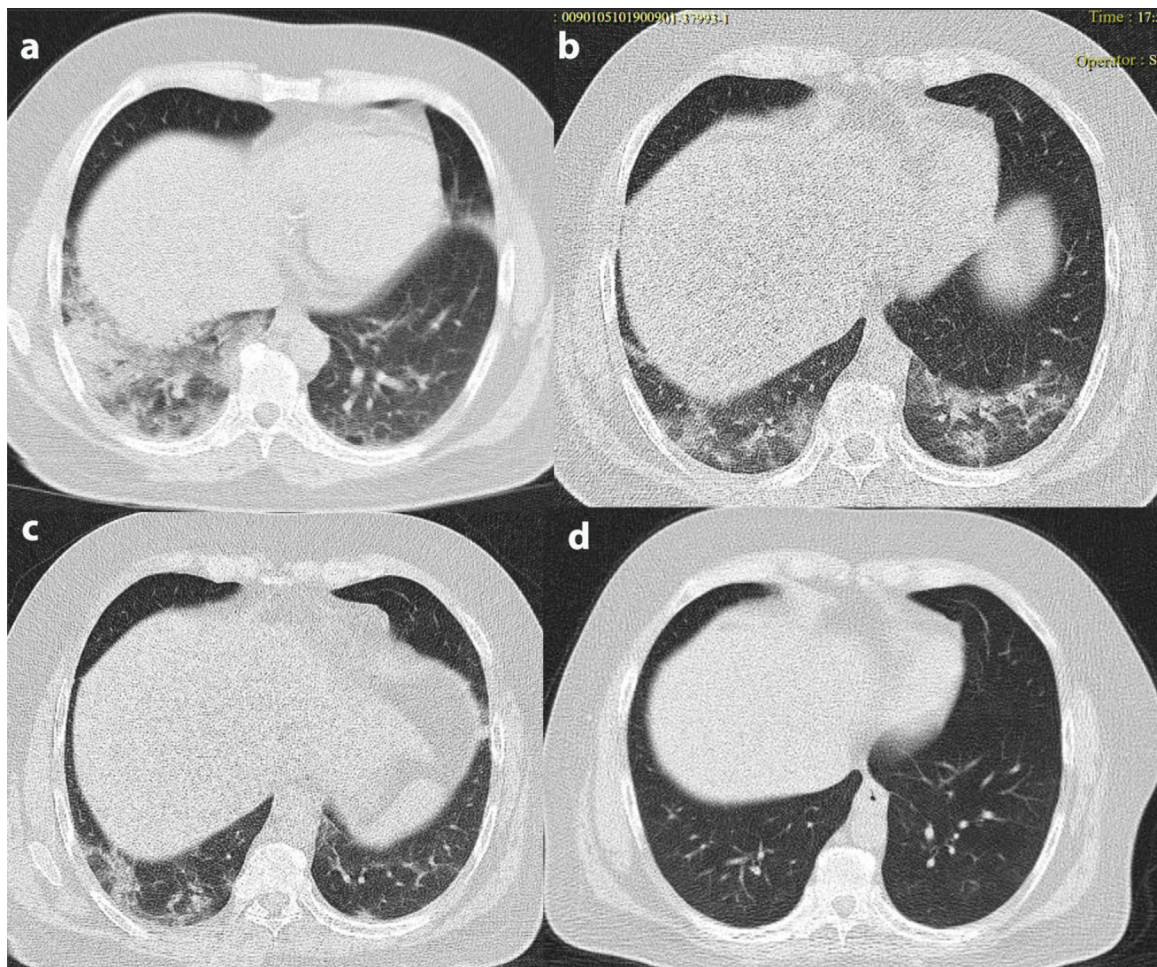


Figure 3. Example of a patient from our cohort. A 42 y/o man, presented with fever and cough. (a) The first CT scan obtained on the 11th day shows an alveolar pattern with mixed GGO and consolidation. (b) On the 18th day, partial resolution of lesions and ground-glass opacities with superimposed architectural distortion produces an OP pattern. (c) On the 42nd day, the lesions have progressed into architectural distortions and bands, forming a reticular pattern. (d) on the 496th day, the lesions are completely resolved.

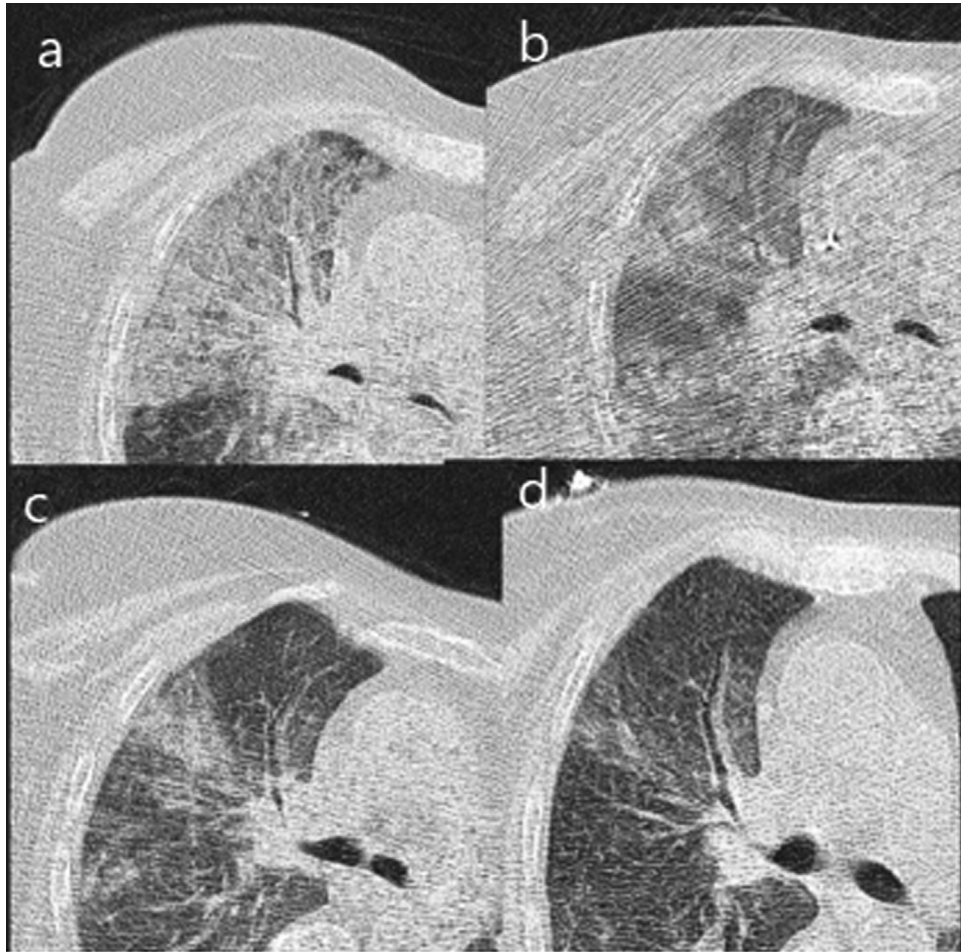


Figure 4. A 77-year-old woman presented with fever and dyspnea. (a) Axial lung CT scan obtained on the 10th-day after symptom onset shows an alveolar pattern with consolidation and air-bronchogram. (b) on the 17th day, the lesions have decreased attenuation, forming an alveolar pattern with mixed GGOs and consolidations. (c) On the 31st day, parenchymal retraction and parenchymal bands are added to the picture. (d) on the 44th day, there are some remaining parenchyma distortions and bronchial dilatations.

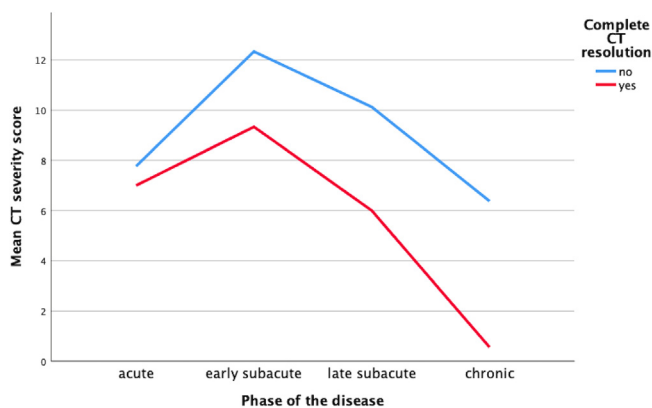


Figure 5. CT severity in patients with and without complete CT resolution in the course of the COVID-19 disease.

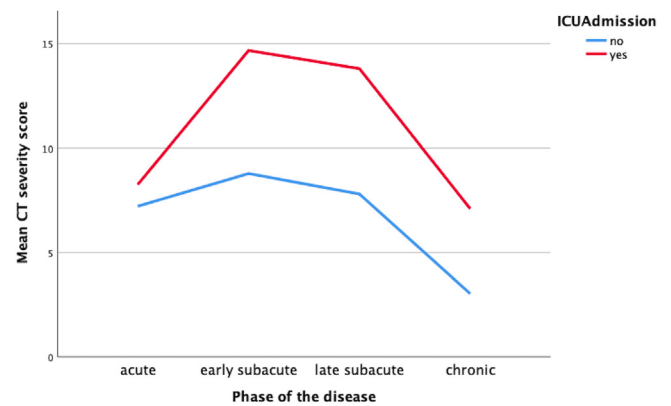


Figure 6. CT severity in patients with and without ICU admission in the course of the COVID-19 disease.

the evaluated group, so we did not extend our statistical analysis to this factor. There was a significant difference in CT severity score after the first week between the patients with and without ICU admission. This was not the case for the CT severity score

in the first week. The CT severity score being roughly the same in the first week between the two groups, increased dramatically in the second and third weeks in patients who eventually needed ICU admission (Figure 6).

Table 1
Patient demographics, comorbidities, symptoms at admission and laboratory findings at admission.

Variables	patients(n= 48)
Age (years), median (IQR)	57 (46-71)
Gender, n (%)	
Male	28 (58.3)
Female	20 (41.7)
Comorbidities, n (%)	
Diabetes	13 (27.1)
Hypertension	10 (20.8)
Coronary artery disease	12 (25)
Chronic obstructive pulmonary disease	6 (12.5)
Malignancy	2 (4.2)
Immunosuppression	8 (16.7)
Symptoms, n (%)	
Fever	22 (45.8)
Cough	19 (39.6)
Dyspnea	33 (68.8)
Myalgia	8 (16.7)
Weakness	8 (16.7)
Gastrointestinal upset	5 (10.4)
Altered mental status	7 (14.6)
Chest pain	1 (2.1)
Hemoptysis	2 (4.2)
ICU admission, n (%)	18 (37.5)
Hypoxia at admission, n (%)	14 (29.2)
Laboratory data	
WBC (*10 ⁹ /L), median (IQR)	8 (6.2-10.1)
LYM%	14.4 (10-21)
Lymphocyte count (*10 ⁹ /L), median (IQR)	1.16 (.77-1.43)
LDH (U/L), median (IQR)	649 (452.2-841.4)
CRP (mg/L), median (IQR)	111 (25.4-186.8)
AST (U/L), median (IQR)	28.5 (19.5-67.75)
ALT (U/L), median (IQR)	43.5 (18.5-83.5)

IQR: Interquartile range, WBC: White blood count, LDH: Lactate dehydrogenase, CRP: C reactive protein, ESR: erythrocyte sedimentation rate, AST: Aspartate aminotransferase, ALT: alanine aminotransferase, BUN: blood urea nitrogen, Cr: Serum creatinine, Hb: hemoglobin, LYM%: lymphocyte percentage

Discussion

This study evaluated the longitudinal changes in imaging abnormalities on thin-section thoracic CT scans of patients

with COVID-19 pneumonia. The CT findings reflect a typical lung injury in viral pneumonia, previously described in the severe acute respiratory syndrome (SARS) and Middle East respiratory syndrome (MERS) [9]. In our patients, the extent of parenchymal abnormalities increased markedly between the first and second weeks after the onset of symptoms. The peak levels of lung involvement were reached in the second week. This was followed by a decline in scores in the following weeks. This pattern was seen in patients with and without eventual complete resolution of CT findings, and in patients with and without subsequent ICU admission. The findings are in line with several other studies [10–13] and may suggest the second week of the disease as the most critical time in the natural course, in which the lung injury reaches the peak level on imaging. We showed that the CT severity score in the second week was significantly higher in patients who needed ICU admission; however, the CT severity score in the first week was not statistically different in the two groups. This suggests that the CT severity score in the second week can be a predictor of the patient's subsequent need for intensive care.

Although CT severity scores decreased after the third week, the frequency of reticular patterns and fibrous-like changes significantly increased in this period.

The most common CT pattern in the first two weeks of the disease was the alveolar pattern (ground-glass opacities and/or consolidations), which was quickly replaced with an organizing pneumonia pattern in the third and fourth weeks. Secondary organizing pneumonia from viral infections is a known entity previously reported in SARS, MERS, and influenza infection [14,15]. The frequency of reticular patterns and fibrous-like changes significantly increased after the fourth week. This finding is noteworthy, as it has been shown that organizing pneumonia has the potential to progress to fibrosis. A follow-up CT scan might be needed for the early identification of patients suspected of having organizing pneumonia in COVID-19 [8].

Table 2
Factors associated with complete resolution of CT findings in COVID-19 patients

Factor	Final CT outcome			p value
	Complete resolution group	Non-resolution group	Total	
Demographics				
Gender, n (%) of males	9 (52.9)	20 (64.5)	29 (60.4)	0.32**
Age (years), median (IQR)	46 (37.5-56)	68 (55-78)	57 (66.2-71.5)	<0.001***
Comorbidity factors				
Hypertension, n (%)	3 (17.6)	7 (22.6)	10 (22.9)	0.49**
Diabetes, n (%)	4 (23.5)	9 (29)	13 (27.1)	0.48**
Coronary artery disease, n (%)	3 (17.6)	9 (29)	12 (25)	0.31**
COPD, n (%)	1 (5.9)	5 (16.1)	6 (12.5)	0.29**
Laboratory findings				
Serum CRP level (mg/L), Median (IQR)	125 (15.8-201.3)	111 (25.4-178.9)	111 (25.4-186.8)	0.84***
Serum LDH level (U/L), median (IQR)	670 (459-916)	623 (431.5-808.5)	649 (452.2-841.4)	0.57***
Lymphopenia, n (%)	5 (29.4)	14 (45.2)	19 (39.6)	0.22**
Initial CT severity score (SD)	7.9 (4.0)	10 (5.9)	9.2 (5.4)	0.048*
Time interval between final CT and symptom onset in days, mean (SD)	116.1 (109.1)	73.8 (87.7)	87.6 (96.2)	0.15

* T test

** Chi square test

*** Mann Whitney test

GGOs are a typical pattern in viral pneumonia but not specific to the COVID-19 infection [16,13]. Various factors can contribute to the GGO formation, including the partial collapse of alveoli, filling of airspaces with fluid, pus, blood, etc., septal thickening, or combinations of them [7]. The most common parenchymal abnormality was a combination of GGO and consolidations. Pure GGOs were seen in 36.4% of patients in the first week of the presentation. The proportion of pure GGO dropped significantly in the later stages of the disease. On the contrary, pure consolidation was seen in only one patient (4.5%) in the first week, but its prevalence increased to 20% in the second week.

The addition of architectural distortions, parenchymal stripes, and retractions to the image creates the organizing pneumonia pattern in the later stages. This may progress to parenchymal bands and fibrosis or show complete resolution in later stages. In this study, full resolution of CT findings was seen in 17 CT scans and was significantly more prevalent in patients of younger age and with lower initial CT severity scores.

Complete resolution of CT findings was seen in one patient (0.8%) in the third-fourth week after the presentation and in 16 (12.3%) patients in the later times. In the previous similar studies, a higher percentage of patients showed complete resolution of CT findings and this could be due to the fact that only hospitalized patients were followed up in our study and patients with milder forms of disease were not included [17,18]

The single most significant contributing factor in the complete resolution of CT findings was the age of the patient, which was significantly lower in patients with complete resolution. The initial CT severity score also was significantly higher in patients in whom residual parenchymal changes (fibrosis, parenchymal bands, etc.) remained in the chronic phase. The findings are in line with several other studies; However, in some previous studies, more other factors such as ICU admission, duration of hospitalization and level of leukocytosis have also been mentioned as the risk factors which could be related to complete resolution [18,19].

There are several limitations to our study. First, we had a relatively small number of patients included. Second, we only included hospitalized patients in our research, and the results may not apply to milder forms of the disease in outpatients. Third, since lung biopsy was not performed on our studied cohort, the imaging-histopathological correlation could not be performed in our study. Fourth, only one radiologist interpreted the images in our study. Finally, although we followed up with the patients as long as possible, the long-term follow-up CT scan was not acquired in some patients, and we could not follow them to a later point.

Conclusion

In conclusion, there are temporal patterns of lung abnormalities. The predominant CT pattern was alveolar infiltrate in the

first and second weeks of the disease, replaced with an organizing pneumonia pattern in the third and fourth weeks. The CT severity score was the highest in the second and third weeks of presentation when severity correlated significantly with the risk of ICU admission. Complete CT resolution was also more common in patients with lower initial CT severity scores and younger ages.

References

- [1] Zarifan A, et al. Chest CT findings of coronavirus disease 2019 (COVID-19): a comprehensive meta-analysis of 9907 confirmed patients. *Clin Imaging*. 2020;70:101–110.
- [2] George PM, et al. Respiratory follow-up of patients with COVID-19 pneumonia. *Thorax*. 2020;75(11):1009–1016.
- [3] Raptis CA, et al. Chest CT and Coronavirus Disease (COVID-19): A Critical Review of the Literature to Date. *AJR Am J Roentgenol*. 2020;215(4):839–842.
- [4] Kooraki S, et al. COVID-19 pandemic revisited: lessons the radiology community has learned a year later. *Emerg Radiol*. 2021;28(6):1083–1086.
- [5] Das KM, et al. Follow-up chest radiographic findings in patients with MERS-CoV after recovery. *Indian J Radiol Imaging*. 2017;27(3):342–349.
- [6] Hui DS, et al. Impact of severe acute respiratory syndrome (SARS) on pulmonary function, functional capacity and quality of life in a cohort of survivors. *Thorax*. 2005;60(5):401–409.
- [7] Hansell DM, et al. Fleischner Society: glossary of terms for thoracic imaging. *Radiology*. 2008;246(3):697–722.
- [8] Wang Y, et al. Temporal changes of CT findings in 90 patients with COVID-19 pneumonia: a longitudinal study. *Radiology*. 2020:200843.
- [9] Ooi GC, et al. Severe acute respiratory syndrome: temporal lung changes at thin-section CT in 30 patients. *Radiology*. 2004;230(3):836–844.
- [10] Bernheim A, et al. Chest CT Findings in Coronavirus Disease-19 (COVID-19): Relationship to Duration of Infection. *Radiology*. 2020:200463.
- [11] Pan F, et al. Time Course of Lung Changes at Chest CT during Recovery from Coronavirus Disease 2019 (COVID-19). *Radiology*. 2020;295(3):715–721.
- [12] Shi H, et al. Radiological findings from 81 patients with COVID-19 pneumonia in Wuhan, China: a descriptive study. *Lancet Infect Dis*. 2020;20(4):425–434.
- [13] Zhang Z, et al. Publisher Correction: Temporal lung changes on thin-section CT in patients with COVID-19 pneumonia. *Sci Rep*. 2021;11(1):4892.
- [14] Ajlan AM, et al. Middle East respiratory syndrome coronavirus (MERS-CoV) infection: chest CT findings. *AJR Am J Roentgenol*. 2014;203(4):782–787.
- [15] Lai RQ, et al. [Pathological changes of lungs in patients with severity acute respiratory syndrome]. *Zhonghua Bing Li Xue Za Zhi*. 2004;33(4):354–357.
- [16] Kim EA, et al. Viral pneumonias in adults: radiologic and pathologic findings. *Radiographics*. 2002 **22 Spec No**: S137–149.
- [17] Liu D, et al. The pulmonary sequelae in discharged patients with COVID-19: a short-term observational study. *Respirat Res*. 2020;21(1):1–7.
- [18] Tabatabaei SMH, et al. Chest CT in COVID-19 pneumonia: what are the findings in mid-term follow-up? *Emergency Radiol*. 2020;27(6):711–719.
- [19] Yasin R, et al. Predicting lung fibrosis in post-COVID-19 patients after discharge with follow-up chest CT findings. *Egyptian J Radiol Nucl Med*. 2021;52(1):1–13.