

## INSTRUCTIVE CASE

**SARS-CoV-2 associated with death in an infant with congenital chylothorax**Handan Bezirganoglu <sup>1,2</sup> and Nilufer Okur<sup>1,2</sup><sup>1</sup>Department of Pediatrics, and <sup>2</sup>Division of Neonatology, Gazi Yasargil Training and Research Hospital, Diyarbakır, Turkey

Severe acute respiratory syndrome coronavirus 2 (SARS-CoV-2) infection in infants and children is thought to cause milder symptoms than other common viral respiratory pathogens.<sup>1</sup> However, our knowledge of the severity and course of the COVID-19 infection in an immunocompromised infant is still scarce.

Congenital chylothorax (CC) is a rare condition which, apart from the electrolyte, fluid imbalance and loss of blood cells, lymphocytes and immunoglobulins, may cause impaired lung development.<sup>2</sup>

Here, we report one of the rare fatal SARS-CoV-2 cases in the infantile age group. An infant with CC developed severe acute respiratory distress syndrome complicated with pulmonary hypertension after infection with SARS-CoV-2 and died of pulmonary complications. To our knowledge, this is the first case reported in an infant with CC.

**Case Report****CC diagnosis and initial management**

A female infant delivered by emergency caesarean section because of breech presentation at 37 weeks gestational age and birthweight of 2900 g was diagnosed prenatally with bilateral pleural effusions. Bilateral chest tubes were placed after admission to the neonatal intensive care unit on the first day of life. The fluid of transude appearance started to drain at 110–130 mL/kg/day. Nevertheless, as the enteral feeding increased, chylous fluid started to accumulate. Despite total parenteral nutrition infusion and enteral nutrition with a meagre amount of long chain fatty acid (LCF)-free formula, the chylous fluid

amount was >20 mL/kg/day. Octreotide treatment was started and titrated to a dose of 8 mcg/kg/h on the 17th day. Repeat echocardiogram demonstrated no signs of congenital pathology and pulmonary hypertension until the 35th day. At follow-up, thoracal ultrasound demonstrated significant bilateral effusions despite ongoing medical treatment for more than 4 weeks. Therefore, a decision was taken to proceed to surgery, and the infant was transferred to another hospital for bilateral pleurodesis.

**SARS-CoV-2 infection and disease course**

On the post-natal 45th day, the patient re-transferred to our neonatal intensive care unit. At admission, she was febrile. Real-time polymerase chain reaction (RT-PCR) was performed, and nasopharyngeal swab test was positive for SARS-CoV-2. During the course of the disease, the infant's respiratory status worsened and oxygen saturation was diminished to 75%, despite high-frequency ventilation and positive end-expiratory pressure (PEEP) level as high as 10 cmH<sub>2</sub>O with an oxygen level of 100%. Both tracheal aspirate culture and blood cultures were negative. Repeated doses of surfactant were administered, and broad-spectrum antibiotics were started. Adrenalin infusion was initiated for borderline hypotension. Also, as the echocardiogram revealed severe pulmonary hypertension, inhaled nitric oxide and sildenafil treatment were started. The patient's immunoglobulin G, A and M levels were way below the laboratory's lower threshold. The results of laboratory tests revealed severe lymphopenia and hypoalbuminaemia. The lymphocyte count remained extremely low throughout the disease, reaching a nadir on the 49th day. She was found to have elevated C-reactive protein, procalcitonin, lactate dehydrogenase and ferritin levels. Liver function tests were slightly elevated. She had a positive D-dimer with a peak level of 8648 ng/mL on day 49. She was given prophylactic enoxaparin at a dose of 1 mg/kg/day and received intravenous immunoglobulin (IVIG) infusion four times during the course. After consultation with a paediatric infectious diseases specialist, first lopinavir/ritonavir and high-dose vitamin D, then high-dose corticosteroid infusion and remdesivir were started to control the pro-inflammatory cytokine storm. Ten days after the diagnosis, the SARS-CoV-2-infected infant's respiratory status gradually improved to a saturation of 93%, but not enough to significantly lower mean airway pressure and PEEP levels on mechanical ventilation. Despite protective ventilatory strategies, her later radiographs were consistent with pulmonary interstitial emphysema (Fig. 1). The infant died on the post-natal 69th day after a pulmonary hypertensive crisis and

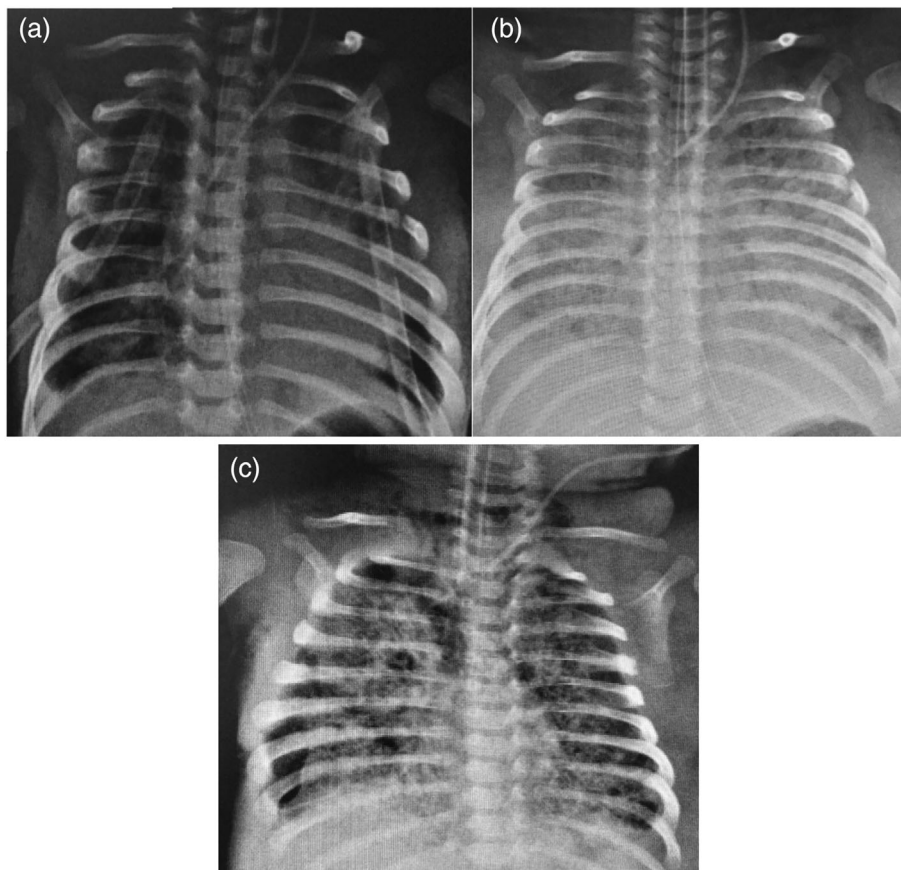
**Key Points**

- 1 Congenital chylothorax is a significant risk factor for severe COVID-19 infection because it impairs adaptive and innate immunity and also lung development.
- 2 Specific treatment guidelines for severe COVID-19 cases in infants are lacking.
- 3 The infant's clinical status benefited the most from corticosteroid treatment in this case.

**Correspondence:** Dr Handan Bezirganoglu, Department of Pediatrics, Gazi Yasargil Training and Research Hospital, Talaytepe Street, Baglar, Diyarbakır 21090, Turkey. Fax: +90 41225 80060; email: bezirganoglu@hacettepe.edu.tr

Conflict of interest: None declared.

Accepted for publication 10 May 2021.



**Fig. 1** Chest radiographs: (a) At the time of readmission. (b) Four days after the diagnosis of SARS-CoV-2 infection. (c) Twenty days after the diagnosis of SARS-CoV-2 infection.

developing severe respiratory failure unresponsive to treatment. The patient remained positive for SARS-CoV-2 by RT-PCR on both nasopharyngeal swabs and tracheal aspirates until her death. The family did not permit an autopsy.

## Discussion

In comparison to her age, the SARS-CoV-2 infection followed an atypical course in our patient. Clinical cohort studies showed that the majority of neonates infected with SARS-CoV-2 were asymptomatic or had mild symptoms, with a generally favourable prognosis.<sup>3</sup> Also, studies in immunocompromised children demonstrated that the immune system dysfunction did not significantly increase the risk of severe COVID-19 infection.<sup>4</sup>

Our patient had risk factors prior to the SARS-CoV-2 infection. She was intubated for 37 days due to an intra-uterine diagnosed pleural effusion that likely compromised lung development. Furthermore, persistent chylous effusion and prolonged intubation further contributed to chronic lung pathology. Although we did not study lymphocyte subsets of the patient, a study of eight patients revealed loss of CD4 T cells and relative retention of natural killer (NK) cells in chylothorax patients' peripheral blood.<sup>5</sup> Because our patient's lymphocyte count remained persistently extremely low ( $<800$  cells/mm<sup>3</sup>), it is reasonable to assume that a possible absence of NK cells was also present. As shown in previous studies, even if the number of NK cells increases relatively, loss of T and B cells negatively affects antiviral immunity.<sup>6</sup>

Therefore, we think that the loss of lymphocytes through chylous fluid affected interferon production and cellular response, which paved the way for a more severe course of COVID-19 infection in this case. Our patient remained positive for SARS-CoV-2 by RT-PCR on both nasopharyngeal swabs until her death, through 25 days. The partial absence of NK cells might cause prolonged viral shedding.

Due to the extremely low incidence of severe COVID-19 cases in infants reported in the literature, specific treatment guidelines for severe cases do not exist. As a result, we attempted to choose treatment options with the fewest possible side effects. First, lopinavir/ritonavir was started, but as the infant's respiratory status dramatically worsened, methylprednisolone treatment was initiated. Our observation is that the infant's cardiopulmonary physiology got the most benefit from corticosteroid treatment as inotropic support was discontinued, and the oxygenation index was significantly decreased after 72 h of steroid initiation. Remdesivir had no additional beneficial effect on clinical status. This could be due to the fact that it was administered at a later stage of the disease.

Hypogammaglobulinaemia may have contributed to the patient's insufficient response to SARS-CoV-2 infection. Although some studies suggest serial measurement of serum immunoglobulin levels and prophylactic IVIG treatment in CC patients, a study found that IVIG administration did not lead to discernible protection from infectious complications in these population.<sup>7</sup> A Cochrane systematic review revealed conflicting findings

regarding the efficacy of convalescent plasma treatment in reducing COVID-19 mortality.<sup>8</sup> As the risk–benefit ratio is unknown in infants, we decide not to give convalescent plasma.

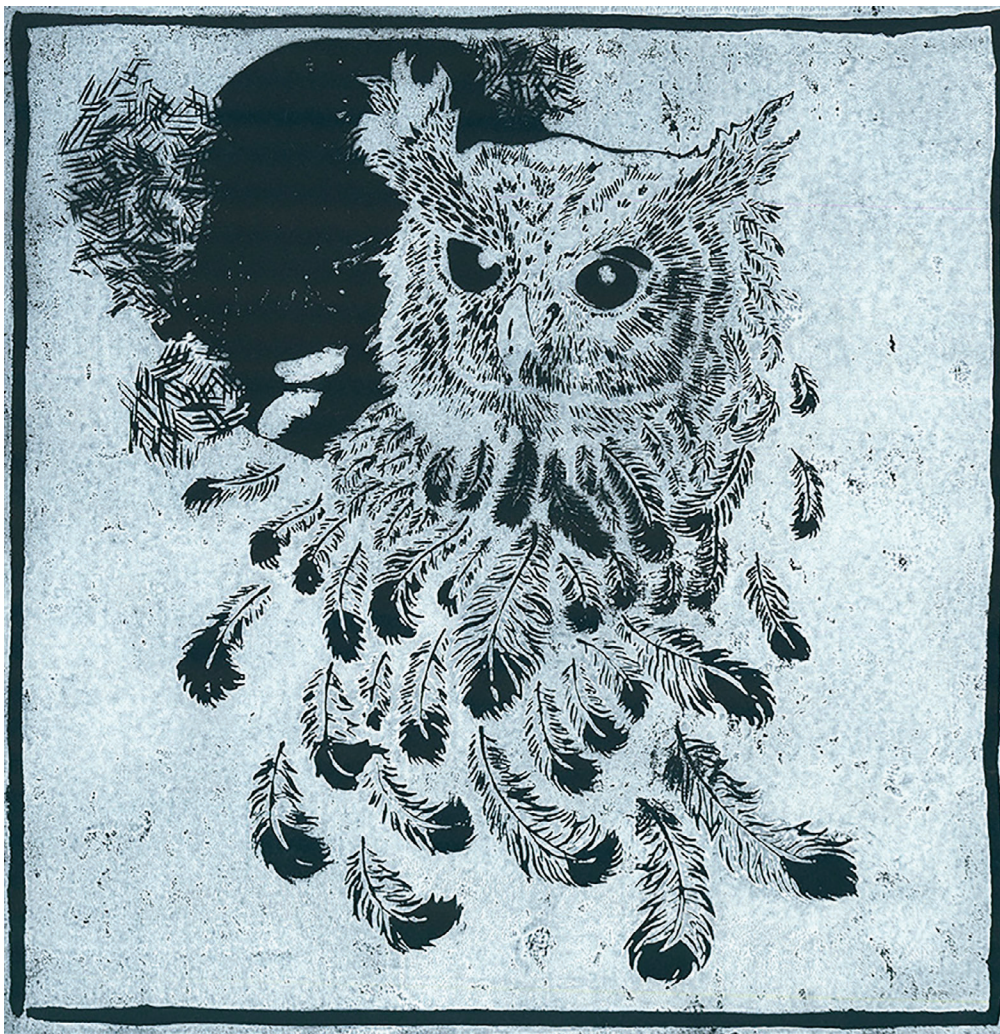
We report a case of severe pulmonary involvement and one of the youngest death because of novel COVID-19 infection in an infant with chronic lung pathology and compromised adaptive and innate immunity due to CC. This report may contribute to determining high-risk infants for COVID-19 infection.

## Acknowledgement

We thank the patient's family for their consent for publication.

## References

- Zimmermann P, Curtis N. Why is COVID-19 less severe in children? A review of the proposed mechanisms underlying the age-related difference in severity of SARS-CoV-2 infections. *Arch. Dis. Child.* 2021; **106**: 429–39.
- Tutor JD. Chylothorax in infants and children. *Pediatrics* 2014; **133**: 722–33.
- Gale C, Quigley MA, Placzek A *et al.* Characteristics and outcomes of neonatal SARS-CoV-2 infection in the UK: A prospective national cohort study using active surveillance. *Lancet Child Adolesc. Health* 2021; **5**: 113–21.
- Castano-Jaramillo LM, Yamazaki-Nakashimada MA, Scheffler Mendoza SC, Bustamante-Ogando JC, Espinosa-Padilla SE, Lugo Reyes SO. A male infant with COVID-19 in the context of ARPC1B deficiency. *Pediatr. Allergy Immunol.* 2021; **32**: 199–201.
- Orange JS, Geha RS, Bonilla FA. Acute chylothorax in children: Selective retention of memory T cells and natural killer cells. *J. Pediatr.* 2003; **143**: 243–9.
- Cook KD, Waggoner SN, Whitmire JK. NK cells and their ability to modulate T cells during virus infections. *Crit. Rev. Immunol.* 2014; **34**: 359–88.
- Wasmuth-Pietzuch A, Hansmann M, Bartmann P, Heep A. Congenital chylothorax: Lymphopenia and high risk of neonatal infections. *Acta Paediatr.* 2004; **93**: 220–4.
- Piechotta V, Chai KL, Valk SJ *et al.* Convalescent plasma or hyperimmune immunoglobulin for people with COVID-19: A living systematic review. *Cochrane Database Syst. Rev.* 2020; **7**: CD013600.



Feathers at Dusk by Cisem Kolac (age 15) from Operation Art 2021