







# Percutaneous Fixation without Bone Graft for Scaphoid Nonunion\*

## *Fixação percutânea sem enxerto ósseo para pseudartrose do escafoide*

João Carlos Belloti<sup>1,2</sup>  Klebson Bruno Lopes Vasconcelos<sup>1</sup>  Jorge Raduan Neto<sup>1,2</sup>   
 Aldo Okamura<sup>1,2</sup>  Marcela Fernandes<sup>1,2</sup>  Vinícius Ynoe de Moraes<sup>1,2</sup> 

<sup>1</sup> Hand Surgery Service, Hospital Alvorada, United Health, São Paulo, SP, Brazil

<sup>2</sup> Department of Orthopedics and Traumatology, Escola Paulista de Medicina, Universidade Federal de São Paulo (EPM-Unifesp), São Paulo, SP, Brazil

Address for correspondence Vinícius Ynoe de Moraes, PhD, Departamento de Ortopedia e Traumatologia, Escola Paulista de Medicina, Universidade Federal de São Paulo (EPMUnifesp), R. Borges Lagoa, 778, Vila Clementino, São Paulo, SP, 04038-030, Brazil (e-mail: vymoraes@gmail.com).

Rev Bras Ortop 2020;55(6):759–763.

### Abstract

**Objective** To describe the clinical and radiographic outcomes of patients submitted to percutaneous fixation without bone graft for scaphoid nonunion, with a minimum follow-up of six months.

**Methods** A case series study of a convenience sample of hand surgeons with prospective evaluation. Patients with scaphoid (waist or proximal pole) nonunion and the following features were included: more than six months of history; X-rays showing sclerosis of the edges of the nonunion, with resorption of the nonunion focus measuring less than 4 mm (Slade & Gleissler I, II, III and IV) and no angular deformity; and no proximal pole necrosis on magnetic resonance imaging (MRI).

**Results** After six months of follow-up, all nonunion were consolidated, with no major complications. The functional outcomes revealed good scores on the disabilities of the arm, shoulder and hand (DASH;  $n = 12$ ; mean: 6.9; standard deviation [SD]: 2.1) and patient-rated wrist evaluation (PRWE;  $n = 12$ ; mean: 7.97, SD: 1.5) questionnaires. The results of the visual analog scale (VAS) showed little residual pain ( $n = 12$ ; mean: 0.71; SD: 0.2). Slight decreases in flexion (69 versus 59.1;  $p = 0.007$ ), extension (62.4 versus 48.7;  $p = 0.001$ ) and radial deviation (29.6 versus 24.6;  $p = 0.014$ ) were detected in comparison to the contralateral side.

**Conclusions** All cases in the series presented consolidation and good functional scores at the six-month evaluation. This is a promising option (with lower technical demand and morbidity) for the treatment of scaphoid nonunion. Comparative studies are required to assess the effectiveness of this technique in comparison with other options.

### Keywords

- ▶ fractures, bone
- ▶ scaphoid bone
- ▶ pseudarthrosis

\* Study developed at the Hand Surgery Service, Hospital Alvorada, United Health, São Paulo, SP, Brazil.

**Resumo**

**Objetivo** Descrever os resultados (clínico-radiográficos) de pacientes tratados por meio de fixação percutânea sem enxerto ósseo para pseudartrose do escafoide, com seguimento mínimo de seis meses.

**Materiais e Métodos** Série de casos de uma amostra de conveniência de grupo de cirurgiões de mão com avaliação prospectiva.. Foram incluídos pacientes com diagnóstico de pseudartrose do escafoide (cintura ou polo proximal) com as seguintes características: mais de seis meses de histórico; radiografias demonstrando esclerose das bordas da pseudartrose, com reabsorção do foco de pseudartrose menor do que 4 mm (Slade & Gleissler I, II, III e IV), sem deformidade angular; e sem necrose do polo proximal pela ressonância magnética (RM).

**Resultados** Na avaliação com mais de seis meses, todas as pseudartroses estavam consolidadas e sem maiores complicações. Os resultados funcionais demonstraram boas pontuações nos questionários de disfunções do braço, ombro e mão (*disabilities of the arm, shoulder and hand*, DASH; n = 12; média: 6,9; desvio padrão [DP]: 2,1) e de avaliação do pulso pelo paciente (*patient-rated wrist evaluation*, PRWE; n = 12; média: 7,97; DP: 1,5). Observou-se pouca dor residual de acordo com a escala visual analógica (EVA; n = 12; média: 0,71; DP: 0,2). Houve discreta diminuição da flexão (69 versus 59,1; p = 0,007), da extensão (62,4 versus 48,7; p = 0,001) e do desvio radial (29,6 versus 24,6; p = 0,014) em comparação ao lado contralateral.

**Conclusões** Nesta série, todos os casos estavam consolidados ao sexto mês de avaliação, com boas pontuações funcionais. Trata-se de uma opção promissora (menor demanda técnica e morbidade) para o tratamento da pseudartrose do escafoide. Estudos comparativos serão úteis para avaliar a efetividade da técnica com relação a outras opções.

**Palavras-chave**

- ▶ fraturas ósseas
- ▶ osso escafoide
- ▶ pseudartrose

**Introduction**

The treatment for scaphoid nonunion is quite controversial and heterogeneous. There are numerous surgical techniques described in the literature, ranging from microsurgical vascularized bone grafts to shock waves.<sup>1-3</sup> The indication of one technique over another is due to many factors, including viability of the proximal pole of the nonunion, scaphoid flexion deformity, carpal collapse, and the degree of resorption at the fracture site.<sup>1</sup>

However, there are a substantial number of cases of nonunion with no radiographic evidence of proximal pole necrosis, absence of angular deformities and little resorption. Some authors<sup>4,5</sup> believe that the use of an open route and grafting in such cases increase morbidity without adding benefits.

In this scenario, the use of a percutaneous screw without a graft may be a good option because of the following: lower degree of technical difficulty; lower degree of morbidity at the site of the nonunion and the area of the autologous graft donor; shorter recovery time; and better functional outcome associated with the percutaneous technique.<sup>4,5</sup> In this technique, a headless self-compressing screw is positioned in line along the scaphoid axis percutaneously, with a guidewire, under radioscopy.<sup>6-8</sup>

The present study hypothesizes that the treatment of scaphoid nonunion with percutaneous fixation of a self-compressing screw is a viable option with high rates of

consolidation and low morbidity. The aim of the present study is to evaluate the effectiveness and safety of such technique using clinical (self-reported function, goniometry) and radiographic (bone consolidation) outcomes.

**Materials and Methods****Study Type**

The present is a case series with prospective clinical evaluation using questionnaires and physical examination of patients undergoing scaphoid nonunion treatment with percutaneous screw fixation from January 2015 to January 2018 at the Hand Surgery and Microsurgery Service of Hospital Alvorada, in the city of São Paulo, Brazil. The patients were followed-up for a minimum period of six months after surgery.

**Participants****Inclusion Criteria**

1) Male and female patients, aged 18 to 60 years, with more than 6 months of history of scaphoid nonunion, undergoing percutaneous screw fixation; 2) radiographic evidence of sclerosis of the edges of the nonunion, with no major resorption (Slade & Gleissler I, II, III, IV)<sup>8</sup> and lack of angular deformity; 3) absence of proximal pole necrosis on magnetic resonance imaging (MRI).

**Exclusion Criteria**

1) Patients who did not want to adhere to the treatment; 2) those with hand and wrist inflammatory diseases; 3) those with nerve damage that may hinder the evaluation of the hand and wrist; 4) patients who had another episode of trauma to the ipsilateral wrist and hand; 5) those with radiocarpal or midcarpal arthrosis; and 6) patients who did not agree with the terms of the informed consent form.

**Surgical Technique**

Percutaneous scaphoid fixation was performed according to the usual technique.<sup>1</sup> The waist nonunion was fixed using a retrograde volar approach, whereas the proximal-pole nonunion was fixed via an anterograde dorsal route. Both techniques employed a mini-track device for the protection of the soft tissues and a guidewire for the self-compressing screw (2.4-mm and 3.0-mm headless compression screws, Depuy Synthes, Raynham, MA, US). The position of the implant was checked using radioscopy, in order to determine that the guidewire was close to the scaphoid axis. The largest possible screw was chosen for each case.

**Evaluated Outcomes**

After the sixth month, pre- and postoperative routine radiographs, wrist and forearm range of motion at goniometry, and the disabilities of the arm, shoulder and hand (DASH),<sup>9</sup> the patient-rated wrist evaluation (PRWE)<sup>10,11</sup> and the pain visual analog scale (VAS) questionnaire results were evaluated.<sup>12</sup> Consolidation was verified using radiographs taken in

three views (front, side and semi-pronated) during the outpatient follow-up.

**Statistical Analysis**

The results were expressed as descriptive statistics (proportions, mean, median, standard deviation and interquartile range values) with inferential statistics (Student *t* test) for the comparison with the contralateral side. Values of *p* < 0.05 were considered statistically significant.

**Results**

In total, 12 patients were included in the study. All cases (100%) presented bone healing. The sample consisted mainly of right-handed (75%) men (75%) with a median age of 30 years old (interquartile range: 27-40 years old). Nonunion was predominantly at the scaphoid waist (75%), with the remaining cases affecting the proximal pole. The DASH and PRWE scores showed little dysfunction at the six-month follow-up. In addition, according to the VAS, the pain was minimal during the postoperative follow-up (►Table 1). ►Table 2 shows the results of the objective functional assessment, in which a small deficit in flexion-extension and radial deviation was observed in comparison to the non-operated wrist. ►Figures 1, 2 and 3 show examples of clinical and radiographic outcomes.

**Discussion**

Scaphoid fractures are difficult to treat due to their unique anatomy and vascular supply.<sup>1,13,14</sup> Fibrous union of

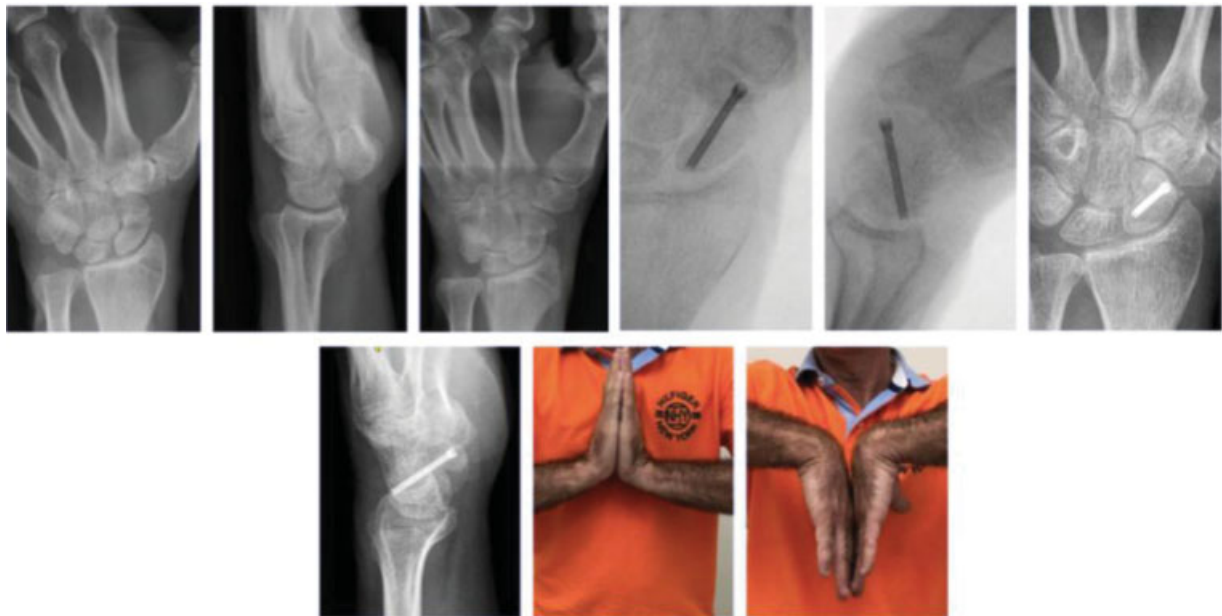**Table 1** Assessment of patient-reported outcomes at least 6 months after the surgical procedure

Outcome	N	Mean	Median	Standard deviation	IQR
Questionnaire: DASH	12	6.99	2.1	14.27	0-5.3
Questionnaire: PWRE	12	7.97	1.5	15.87	0.1-6.1
Pain: VAS	12	0.71	0.2	1.43	0.1-0.6

Abbreviations: DASH, disabilities of the arm, shoulder and hand; IQR, interquartile range; PRWE, patient-rated wrist evaluation; VAS, visual analog scale.

**Table 2** Goniometry: operated and control (non-operated) sides

Goniometry		N	Mean	Median	Standard deviation	p-value
Elbow: pronation	Operated	12	83.9	84	11.4	0.058
	Control	12	86.5	87	13.0	
Elbow: supination	Operated	12	90.1	90	4.2	0.179
	Control	12	88.2	90	4.3	
Wrist: extension	Operated	12	48.7	51	11.8	0.001
	Control	12	62.4	62.5	12.3	
Wrist: flexion	Operated	12	59.1	61.5	8.7	0.007
	Control	12	69.0	70	6.9	
Wrist: radial deviation	Operated	12	24.6	25.5	5.0	0.014
	Control	12	29.6	30	5.3	
Wrist: ulnar deviation	Operated	12	37.8	38	6.3	0.111
	Control	12	40.5	41.5	7.4	



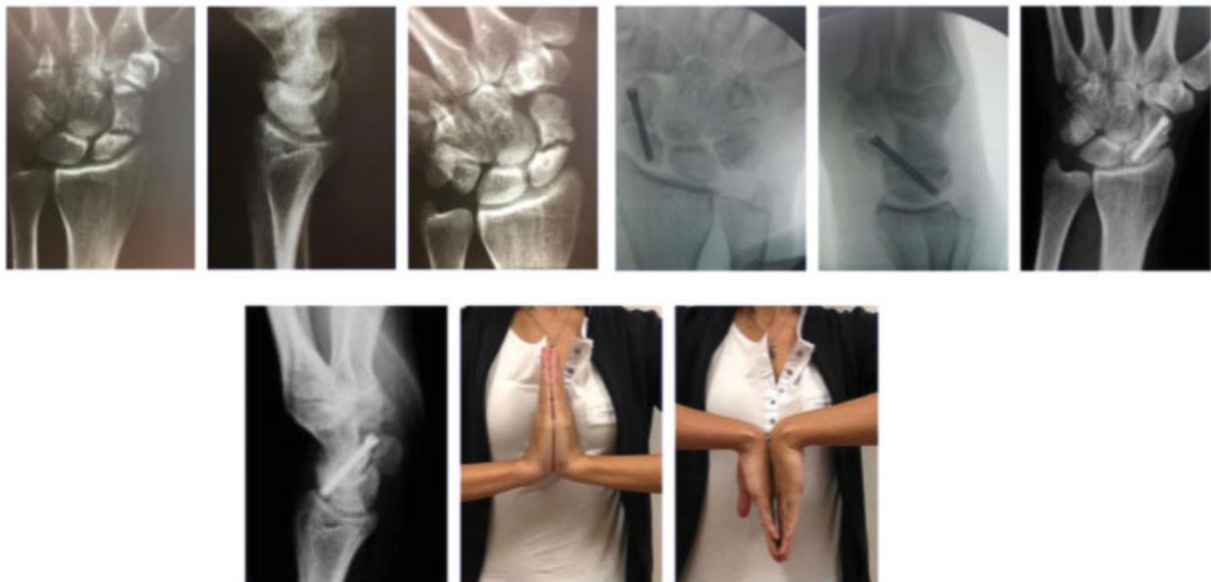
**Fig. 1** Male patient, 53 years old. Pseudarthrosis of the scaphoid waist.

scaphoid fractures occurs because the healing process is interrupted in its early stages. It is suggested that this is due to focal micromovement and lack of adequate mechanical stabilization. The outcomes from this case series seem to partially refute the notion that incremental grafting is required for consolidation.

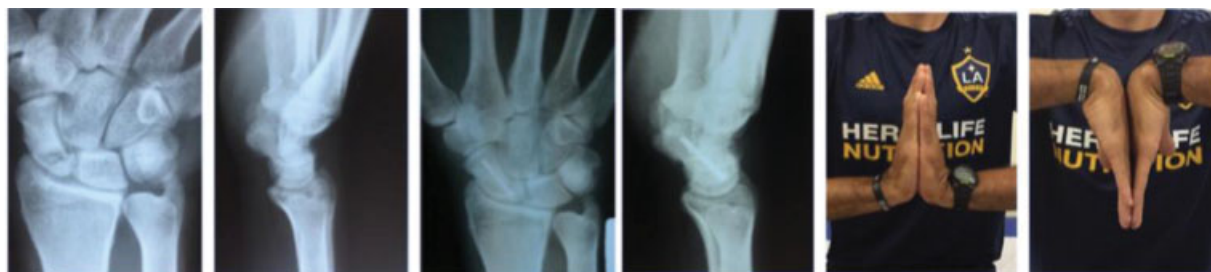Pseudarthroses with minimal sclerosis are similar to fibrous unions, requiring only compression and rigid fixation for healing.<sup>6</sup> Our series is consistent with that of Kim et al.,<sup>4</sup> who published cases of nonunion with mild resorption at the fracture site from 12 patients with late scaphoid waist union treated with the percutaneous fixation method. Similarly, Hegazy,<sup>15</sup> in a series with 21 patients, reported a similar

outcome, with 100% of consolidation and an average DASH score of 6.9; these findings are very similar to our own. Vanhees et al.,<sup>16</sup> in a retrospective series with 16 patients, reported a 94% consolidation rate. The literature has series with small samples, reflecting the difficulty in recruiting such patients. As such, conducting comparative studies seems more difficult and, somehow, creates an opportunity to conduct collaborative (multicenter) studies.<sup>17</sup>

There are no clearly reported data on the extent of bone resorption at the nonunion site and its effect on the need for bone graft. One study<sup>16</sup> showed that, regardless of the gap size, non-deviated fractures can heal without bone graft as long as mechanical stabilization is achieved and carpal alignment is



**Fig. 2** Female patient, 27 years old. Pseudarthrosis of the scaphoid waist.



**Fig. 3** Male patient, 37 years old. Pseudarthrosis of the proximal pole of the scaphoid.

sustained,<sup>18</sup> as observed in the present cohort of patients. In addition, a considerable advantage of this technique is the potential maintenance of a better range of motion (since there is less aggression to the wrist capsule) and the lack of morbidity in the graft donor area.<sup>19</sup> That said, if this technique offers consolidation rates similar to the grafting technique, it will bring greater benefits to patients due to the lower morbidity. The main limitations of the present study are our relatively small sample size and the lack of a control group.

## Conclusion

All cases were consolidated at the six-month evaluation, with good functional scores. This is a promising option for the treatment of scaphoid nonunion, with lower technical demand and morbidity. Comparative studies are required to assess the effectiveness of this technique in comparison with other options.

### Conflict of Interests

The authors have none conflict of interests to declare.

## References

- Lee SK. Fractures of the carpal bones. In: Green D, Hotchkiss R, Pederson W, Wolfe S editors. *Green's operative hand surgery*. 7th ed. Philadelphia: Churchill Livingstone; 2016
- Pinder RM, Brkljac M, Rix L, Muir L, Brewster M. Treatment of Scaphoid Nonunion: A Systematic Review of the Existing Evidence. *J Hand Surg Am* 2015;40(09):1797–1805.e3
- Quadlbauer S, Pezzeri C, Beer T, et al. Treatment of scaphoid waist nonunion by one, two headless compression screws or plate with or without additional extracorporeal shockwave therapy. *Arch Orthop Trauma Surg* 2019;139(02):281–293
- Kim JK, Kim JO, Lee SY. Volar percutaneous screw fixation for scaphoid waist delayed union. *Clin Orthop Relat Res* 2010;468(04):1066–1071
- Capo JT, Shamian B, Rizzo M. Percutaneous screw fixation without bone grafting of scaphoid non-union. *Isr Med Assoc J* 2012;14(12):729–732
- Haddad FS, Goddard NJ. Acute percutaneous scaphoid fixation. A pilot study. *J Bone Joint Surg Br* 1998;80(01):95–99
- Slade JF III, Jaskwlich D. Percutaneous fixation of scaphoid fractures. *Hand Clin* 2001;17(04):553–574
- Geissler WB. Arthroscopic management of scaphoid fractures in athletes. *Hand Clin* 2009;25(03):359–369
- Orfale AG, Araújo PM, Ferraz MB, Natour J. Translation into Brazilian Portuguese, cultural adaptation and evaluation of the reliability of the Disabilities of the Arm, Shoulder and Hand Questionnaire. *Braz J Med Biol Res* 2005;38(02):293–302
- Goldhahn J, Shisha T, Macdermid JC, Goldhahn S. Multilingual cross-cultural adaptation of the patient-rated wrist evaluation (PRWE) into Czech, French, Hungarian, Italian, Portuguese (Brazil), Russian and Ukrainian. *Arch Orthop Trauma Surg* 2013;133(05):589–593
- Paranaíba VF, Santos JBGD, Raduan Neto J, Moraes VY, Belloti JC, Faloppa F. PRWE application in distal radius fracture: comparison and correlation with established outcomes. *Rev Bras Ortop* 2017; 52(03):278–283
- Revill SI, Robinson JO, Rosen M, Hogg MI. The reliability of a linear analogue for evaluating pain. *Anaesthesia* 1976;31(09): 1191–1198
- Barton NJ. Experience with scaphoid grafting. *J Hand Surg Br* 1997;22(02):153–160
- Schuidt F, Haentjens P, Van Innis F, Vander Maren C, Garcia-Elias M, Sennwald G. Prognostic factors in the treatment of carpal scaphoid nonunions. *J Hand Surg Am* 1999;24(04):761–776
- Hegazy G. Percutaneous Screw Fixation of Scaphoid Waist Fracture Non-Union Without Bone Grafting. *J Hand Microsurg* 2015;7(02):250–255
- Vanhees M, van Riet RRP, van Haver A, Kebrle R, Meermans G, Verstreken F. Percutaneous, Transtrapezial Fixation without Bone Graft Leads to Consolidation in Selected Cases of Delayed Union of the Scaphoid Waist. *J Wrist Surg* 2017;6(03):183–187
- Geoghegan JM, Woodruff MJ, Bhatia R, et al. Undisplaced scaphoid waist fractures: is 4 weeks' immobilisation in a below-elbow cast sufficient if a week 4 CT scan suggests fracture union? *J Hand Surg Eur Vol* 2009;34(05):631–637
- de Moraes VY, Ferrari PM, Gracitelli GC, Faloppa F, Belloti JC. Outcomes in orthopedics and traumatology: translating research into practice. *Acta Ortop Bras* 2014;22(06):330–333
- Slade JF 3rd, Gillon T. Retrospective review of 234 scaphoid fractures and nonunions treated with arthroscopy for union and complications. *Scand J Surg* 2008;97(04):280–289