

# Anaphylactoid hypersensitivity reaction from intra-arterial cetuximab: Clinical considerations and management

SAGE Open Medical Case Reports  
Volume 7: 1–4  
© The Author(s) 2019  
Article reuse guidelines:  
sagepub.com/journals-permissions  
DOI: 10.1177/2050313X18823447  
journals.sagepub.com/home/sco



Yonatan Bardash<sup>1,2</sup> , Tristan Tham<sup>1</sup>, Caitlin Olson<sup>1</sup>,  
Julian Khaymovich<sup>1</sup> and Peter Costantino<sup>1,2</sup>

## Abstract

Intra-arterial infusion of drugs shows promising results in terms of safety and efficacy. Intra-arterial cetuximab, a monoclonal antibody treatment, is currently being tested for its use in head and neck cancers. We present the case of a 45-year-old Asian male who developed an anaphylactoid hypersensitivity reaction, manifesting itself in the form of bronchospasm, tachycardia, and hypotension, during intra-arterial infusion of cetuximab. The symptoms were quickly diagnosed, and the patient was treated accordingly. Despite the safety profile of cetuximab and the decreased risk of systemic effects with intra-arterial infusion versus intravenous infusion, severe hypersensitivity reactions are still a risk in intra-arterial cetuximab infusions. Consequently, proper planning and care must be taken to prophylactically prevent and in the case of a reaction, treat the reaction accordingly. The case presented herein is, to the best of our knowledge, the first recorded moderate-to-severe infusion reaction in a patient receiving intra-arterial cetuximab treatment for head and neck cancer.

## Keywords

Intra-arterial infusion, hypersensitivity reaction, head and neck cancer, cetuximab, management, case report

Date received 26 April 2018; accepted: 14 December 2018

## Introduction

Intra-arterial (IA) infusion is a unique modality of drug administration. Clinically, the main utility of this technique is seen in chemotherapy administration, in which IA infusion of the chemotherapy agent allows for high doses of drugs to be targeted directly to the cancerous tissue, while reducing exposure of healthy tissues to the effect of the drugs. In the literature, IA infusions are noted for having lower risk of systemic effects.<sup>1,2</sup> The current explanation for this is based on two working assumptions, one direct and one indirect: the direct effect is by targeting the cancer tissue, reducing healthy tissue exposure to chemotherapy agents, and the indirect effect of the reduction in overall dosing needed to treat, whereby the patient is exposed to an appreciable reduction in the overall amount of chemotherapy agent throughout treatment.

Cetuximab is a monoclonal antibody agent that has been established as a first-line treatment for recurrent head and neck cancer.<sup>3</sup> Monoclonal antibodies, such as cetuximab, have proven to be quite effective chemotherapeutic agents but they have also been associated with hypersensitivity

infusion reactions (IR).<sup>4</sup> With respect to intravenous infusions of cetuximab, mild to moderate reactions (grades 1 and 2 IRs), including flushing, rash, fever, chills, dyspnea, and mild hypotension, occur in 16%–19% of patients after the first infusion.<sup>5</sup> Severe reactions (grades 3 and 4 IRs), such as bronchospasms and anaphylaxis, are much less common and occur roughly 3% of the time. Despite previous reports to the safety and the decreased risk of systemic side effects associated with IA, we present the first reported case of a patient who developed a hypersensitivity reaction to IA cetuximab.

<sup>1</sup>New York Head & Neck Institute and Lenox Hill Hospital, Northwell Health System, New York, NY, USA

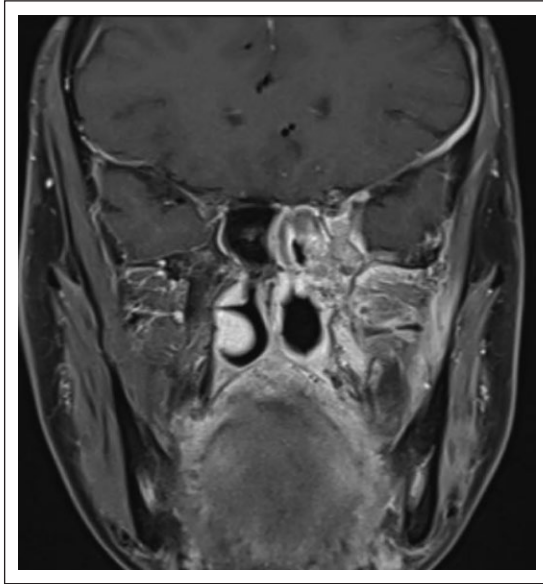
<sup>2</sup>Donald and Barbara Zucker School of Medicine at Hofstra/Northwell, New York, NY, USA

### Corresponding Author:

Yonatan Bardash, New York Head & Neck Institute and Lenox Hill Hospital, Northwell Health System, 130 East 77th Street, 10th Floor, New York, NY 10075, USA.

Email: Ybardash1@pride.hofstra.edu





**Figure 1.** Coronal MRI.

## Case

A 45-year-old Asian male with a history of nasopharyngeal carcinoma (NPC) was referred to our clinic in the spring of 2016 after he was found to have NPC recurrence. His past medical history was insignificant except for a four pack-year smoking history (2006–2010). He had no personal or family history of allergies, asthma, chronic obstructive pulmonary disease (COPD), or atopy. The patient was diagnosed via fine needle aspiration of a cervical lymph node in 2013 and underwent definitive chemoradiation therapy (CRT) from late 2013 to early 2014 (cisplatin and conventional radiation therapy (XRT) with a total dose of 56 Gy over 28 fractions). However, 9 months after completion of CRT, a positron emission tomography (PET) scan was suspicious for recurrence. Nasal biopsy was performed, but was found to be negative. Roughly 19 months after completion of his CRT, the patient's surveillance PET scan was again suggestive of recurrence. In January 2016, the patient underwent an endoscopic left maxillary antrostomy, left total ethmoidectomy, and sphenoidotomy with biopsies at another institution. Pathology confirmed recurrence of poorly differentiated NPC. At that time, the patient's disease was determined to be endoscopically unresectable so he was referred to our institution for consideration for open resection. Upon referral, a magnetic resonance imaging (MRI) was obtained, which demonstrated extensive left skull base recurrence of the primary NPC with cavernous sinus, Meckel's cave, and perineural involvement along V3 to the left mandible (Figure 1). There was also involvement of the orbital apex and temporal lobe dura. Symptomatically, the patient reported numbness along the left side of his face and decreased taste along the left hemi-tongue. He denied any difficulty swallowing, vision loss, hearing loss, or weakness. After presenting the

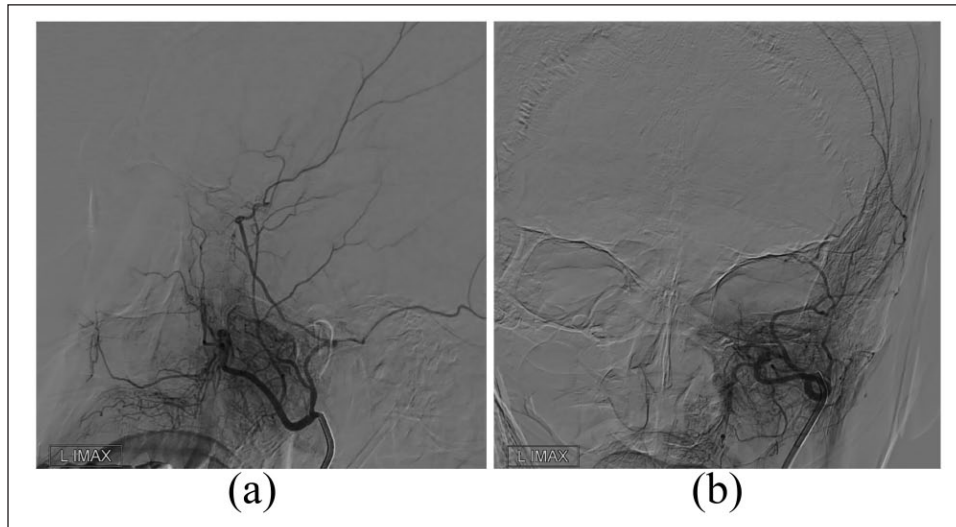
patient at our tumor board, it was decided that the patient's volume of disease was unresectable, but his excellent performance status and minimal symptoms made him an appropriate candidate for our phase I IA cetuximab clinical trial with concurrent re-irradiation.<sup>6</sup>

In April 2016, the patient was enrolled and underwent the first dose of his two scheduled IA cetuximab doses of 100 mg/m<sup>2</sup> in a Phase I dose-escalation clinical trial (NCT02438995). The morning of the infusion the patient's vitals were stable (T: 99, heart rate (HR): 78 bpm, blood pressure (BP): 119/65, respiratory rate (RR): 14, SaO<sub>2</sub>: 98%) and consistent with patient's baseline vitals. As per the study protocol, the patient was prophylactically treated with 50 mg of diphenhydramine 1 hour prior to the start of the IA cetuximab infusion. After groin puncture and demonstrating a safe intravascular positioning of the microcatheter for IA infusion, a total of 81.5 mL of cetuximab was infused over 12 min (Figure 2(a) and b). After infusion of the first 50 mL, the patient developed a cough with concurrent elevation of his HR up to 110 bpm. He was treated with 100 mg intravenous hydrocortisone sodium succinate and his symptoms resolved, allowing for the remainder of the infusion to be given to completion without adverse effects. The patient did not experience any severe vascular pain or vascular spasms as a result of the procedure. The catheter and femoral sheath were removed and hemostasis was achieved with a perclose device. Subsequently, while still in the cath lab, the patient's HR and RR suddenly increased to 110 bpm and over 20, respectively. His BP dropped to 50/30, his oxygen saturation dropped to 90, and he experienced bronchospasms. The anesthesiologist treated the patient with 20 mg of epinephrine, 180 mcg of phenylephrine, and 4 mg of Zofran, along with positive ventilation and a total of 900cc of Lactated Ringers. After intervention, the patient's vitals stabilized (HR: 91 bpm, BP: 111/66, RR: 16, SaO<sub>2</sub>: 99), and he was transferred to the holding area for observation and recovery. The patient never demonstrated signs of flushing, rash, fever, chills, and dyspnea and his vitals remained continuously stable for the following 24 h of observation. The patient was then discharged home and reported feeling well with no complaints during a follow-up phone call 3 days post infusion.

Per protocol, the patient was removed from the IA cetuximab trial due to severe IR, so he never received the second scheduled dose. However, he proceeded to receive intensity-modulated radiation therapy (IMRT) to his left nasopharynx, skull base, cavernous sinus, and Meckel's cave. He received a total of 7000 cGy over 35 fractions with some minor overlapping of his prior radiation site; 16 months out from completion of his one dose of cetuximab and re-irradiation, the patient's surveillance imaging still shows no evidence of disease.

## Discussion

Due to IA cetuximab's purported specificity and safety, it is viewed as a potential preferred method of administration for



**Figure 2.** Selected angiographic images: (a) Digital subtraction angiography (DSA) examination in lateral view of the left internal maxillary artery at the site of SSIA cetuximab injection and (b) DSA examination in anterior-posterior (AP) view of the left internal maxillary artery at the site of the SSIA cetuximab.

the treatment of head and neck cancer. IA infusion has shown to be associated with fewer complications and side effects compared to intravenous (IV) infusion.<sup>1</sup> However, based on the case we have reported, IA cetuximab still maintains a risk of inducing adverse reactions, albeit at presumably lower rates than IV infusion. The patient experienced an anaphylactoid hypersensitivity reaction, despite prophylactically being treated with diphenhydramine, an H<sub>1</sub> antagonist recommended for the purpose of preventing IRs with cetuximab. During the infusion, the patient experienced a cough and elevated HR, requiring hydrocortisone sodium succinate. Furthermore, within 30 min after the infusion, the patient displayed unstable vitals, including decreased BP, increased RR and HR, decreased SaO<sub>2</sub>, and the development of bronchospasms. The patient was immediately treated for the IR accordingly and his vitals normalized. Epinephrine, a sympathomimetic catecholamine often used in IRs, was used to stabilize the patient. Epinephrine functions as an  $\alpha$  and  $\beta$ -adrenergic agonist, reversing peripheral vasodilation, alleviating hypotension, reducing erythema and angioedema, and resulting in bronchodilation and increased myocardial output and contractility.<sup>7</sup>

Although the exact reason for why our patient experienced an IR is unknown, there are several theories as for why adverse reactions may occur. Monoclonal antibodies, such as cetuximab, have been postulated to elicit a response from human anti-chimeric antibodies (HACAs) and human anti-human antibodies (HAHAs).<sup>8</sup> Other theories include IgE-mediated responses as leading contributors to IRs, and in particular, anaphylaxis.<sup>9,10</sup> Geographic differences result in different natural exposures to galactose- $\alpha$ -1,3-galactose which has been implicated in the production of IgE antibodies. Cetuximab contains galactose- $\alpha$ -1,3-galactose, or alpha-gal and therefore puts those with increased IgE production at

risk for IRs. Although information on our patient's IgE sensitization to alpha-gal was unavailable, we suggest using an enzyme-linked immunosorbent assay (ELISA) assay to screen for anti-cetuximab IgE antibodies prior to infusion, as this appears to be a highly specific and sensitive method of determining whether a severe IR may occur.<sup>9-11</sup> In order to properly monitor for such reactions, vitals must be carefully recorded before, during, and after infusion, and although IRs normally occur within the first hour after infusion, delayed reactions may still occur.<sup>5,12</sup> Among patients who experience IRs, 90% experience adverse reactions after the first infusion. A “crash cart” with epinephrine, ephedrine, aerosolized bronchodilator, and other equipment, such as an oxygen tank, should be available as a preventive measure. Even with pre-medication, up to 19% of patients treated with cetuximab report an IR. Hence, diphenhydramine may not be enough to prevent reactions.<sup>5</sup> Literature suggests that the administration of albuterol, famotidine, and corticosteroids, along with diphenhydramine, may significantly decrease the risk of severe reactions and should be considered in future prevention of IRs.<sup>13</sup> There is also literature that suggests that patients who have developed a mild–moderate IR due to cetuximab can be successfully re-challenged, but with a reduced infusion rate.<sup>5,9</sup> However, re-challenging is not suggested in patients with severe IR. Due to the protocol of the study, our patient was removed from the clinical trial due to the allergic reaction and was not re-challenged.<sup>6</sup>

## Conclusion

To our knowledge, this is the first report of an IR arising from IA cetuximab for head and neck cancer. It is important to note that even with evidence of increased safety using IA infusion, our patient experienced a severe IR despite diphenhydramine

prophylaxis. Prompt intervention and cognizance of this potentially life-threatening complication is vital during the administration of IA cetuximab.

### Acknowledgements

We would like to acknowledge Dr John Seitz (Anesthesiology), Dr Keith Haller (Anesthesiology), and Guillermo Restrepo (Interventional Neurosurgery) for their contributions to the case report by providing firsthand accounts of the adverse events and for helping to review and clarify the electronic medical record notes.

### Declaration of conflicting interests

The author(s) declared no potential conflicts of interest with respect to the research, authorship, and/or publication of this article.

### Ethical approval

Our institution does not require ethical approval for reporting individual cases or case series.

### Funding

The author(s) received no financial support for the research, authorship, and/or publication of this article.

### Informed consent

Written informed consent was obtained from the patient for their anonymized information to be published in this article.

### ORCID iD

Yonatan Bardash  <https://orcid.org/0000-0002-0079-4619>

### References

1. Liu F, Tang Y, Sun J, et al. Regional intra-arterial vs. systemic chemotherapy for advanced pancreatic cancer: a systematic review and meta-analysis of randomized controlled trials. *Plos One* 2012; 7(7): e40847.
2. Eckman WW, Patlak CS and Fenstermacher JD. A critical evaluation of the principles governing the advantages of intra-arterial infusions. *J Pharmacokinet Biopharm* 1974; 2(3): 257–285.
3. Tham T, White TG, Chakraborty S, et al. Intra-arterial cetuximab for the treatment of recurrent unresectable head and neck squamous cell carcinoma. *J Exp Ther Oncol* 2016; 11: 293–301.
4. Bonner JA, Harari PM, Giralt J, et al. Radiotherapy plus cetuximab for squamous-cell carcinoma of the head and neck. *N Engl J Med* 2006; 354(6): 567–578.
5. Lenz HJ. Management and preparedness for infusion and hypersensitivity reactions. *Oncologist* 2007; 12(5): 601–609.
6. Boockvar J, Costantino P and Kraus D. Super-selective intra-arterial infusion of cetuximab (erbitux) with or without radiation therapy for the treatment of unresectable recurrent squamous cell carcinoma of the head and neck. *US National Library of Medicine*, <https://clinicaltrials.gov/ct2/show/NCT02438995>
7. Kemp SF, Lockey RF and Simons FER. Epinephrine: the drug of choice for anaphylaxis—a statement of the world allergy organization. *World Allergy Organ J* 2008; 1(7Suppl. 1): S18–S26.
8. Lenz HJ. Anti-EGFR mechanism of action: antitumor effect and underlying cause of adverse events. *Oncology (Williston Park)* 2006; 20(5Suppl. 2): 5–13.
9. Chung CH, Mirakhur B, Chan E, et al. Cetuximab-induced anaphylaxis and IgE specific for galactose-alpha-1,3-galactose. *N Engl J Med* 2008; 358: 1109–1117.
10. Ohshita N, Ichimaru Y, Gamoh S, et al. Management of infusion reactions associated with cetuximab treatment: a case report. *Mol Clin Oncol* 2017; 6(6): 853–855.
11. Dupont B, Mariotte D, Moldovan C, et al. Case report about fatal or near-fatal hypersensitivity reactions to cetuximab: anticetuximab IgE as a valuable screening test. *Clin Med Insights Oncol* 2014; 8: 91–94.
12. Yamaguchi K, Watanabe T, Satoh T, et al. Severe infusion reactions to cetuximab occur within 1 h in patients with metastatic colorectal cancer: results of a nationwide, multicenter, prospective registry study of 2126 patients in Japan. *Jpn J Clin Oncol* 2014; 44(6): 541–546.
13. Touma W, Koro SS, Ley J, et al. Risk factors for and pre-mediations to prevent cetuximab-induced infusion reactions in patients with squamous cell carcinoma of the head and neck. *Oral Oncol* 2014; 50(9): 895–900.