

Updates on the Treatment of Erythrodermic Psoriasis

Yang Lo¹
Tsen-Fang Tsai²

¹Department of Dermatology, Cathay General Hospital, Taipei, Taiwan;

²Department of Dermatology, National Taiwan University Hospital and National Taiwan University College of Medicine, Taipei, Taiwan

Abstract: Erythrodermic psoriasis (EP) is a rare variant of psoriasis, which is potentially life threatening and often resistant to conventional therapy. Biologics have revolutionized the treatment of plaque-type psoriasis, and shown promise in EP. However, due to the lack of head-to-head studies and the rarity of EP, no high level evidence-based treatment guidelines for EP have been established, and the evidence of treatment of EP is limited to case reports or small case series. Here, we present a narrative review focusing on the up-to-date information for the treatment of EP.

Keywords: erythrodermic psoriasis, treatment

Erythrodermic psoriasis (EP), a rare variant of psoriasis vulgaris, accounts for 1–2% patients with psoriasis.^{1,2} A higher prevalence of EP in Asians was found in China and Taiwan study.^{3,4} EP is clinically defined as prominent erythema and scaling affecting at least 75–90% of the body surface area (BSA).^{1,5} Due to the extensive cutaneous involvement, EP patients can present with systemic symptoms, such as pruritus, fever, chills, dehydration, arthralgia, asthenia and lymphadenopathy.^{1,5} Several triggers for causing EP can be identified, including infection, administration of systemic corticosteroids, withdrawal of medication, severe emotional stress and preceding illness.^{2,6} Many biomarkers are possibly related to the pathogenesis of EP, including higher IL-4 and IL-10 levels,⁷ elevation of serum IgE,⁸ increased Th2 response,^{7,9} and the presence of circulating adhesion molecules.¹⁰ There may be overlap between the EP and atopic dermatitis immune phenotypes.¹¹ Recently, a study from China revealed the possible role of the cytokine tumor necrosis factor-related weak inducer of apoptosis (TWEAK) in the pathogenesis of EP and psoriasis vulgaris (PV).¹² Furthermore, according to a recent study from China, a higher prevalence of thyroid dysfunction was found in EP patients.¹³ Several human leukocyte antigens (HLA), such as HLA-Cw6 and HLA-DR7 have been linked with psoriasis vulgaris,^{14,15} and the same genetic constitution was also related to guttate psoriasis.¹⁶ In Chinese patients with erythrodermic psoriasis, HLA-C*01:02 was reported to be the most frequent HLA-C allele (34.4%) compared to plaque psoriasis (21.9%) and healthy controls (21.2%).⁶ Recently, one case reported mutations of the CARD14 gene with EP related to requiring higher doses of ustekinumab.¹⁷ Due to the lack of head-to-head studies and the rarity of EP, no high-level evidence-based treatment guidelines for EP have been established.¹ This review article aims to provide up-to-date information for the treatment of EP (Tables 1–5).

Correspondence: Tsen-Fang Tsai
Tel +886-2-2312-3456 #65734
Email tftsai@yahoo.com

Table 1 Studies of Conventional Oral Immunosuppressive Agents in EP Patients

Treatment	Author (Year)	Number of Subjects	Study Design	Results	Adverse Events
MTX	Collins et al ¹⁸ (1991)	7	R	4 (57.1%) Patients with excellent response, 2 (28.6%) patients with good response, 1 patient failed.	NR
MTX	Kumar et al ²¹ (1994)	5	R	2 (40%) Patients achieved disease-free interval for 14 weeks. All patients relapse within 14 weeks.	Nausea, vomiting
CsA	Giannotti et al ²⁶ (1993)	33	Case series	22 (67%) Patients achieved complete remission in a median time of 2–4 months after 6 months of treatment.	Hypertension, cerebrovascular disorder
CsA	Bruzzese et al ²⁷ (2009)	1	Case report	Under CsA 3 mg/kg, complete remission was seen within 3 months.	NR
CsA + etretinate	Kokelj et al ³³ (1998)	3	Case series	After treatment for 11–18 days, remission was seen.	Xerosis, cheilitis, GI upset
CsA + UVB	Franchi et al ³⁵ (2004)	7	Case series	After 9 weeks, PASI score Reduction by 57.6, compared with placebo. points	None
Acitretin CsA	Charbit et al ³⁶ (2016)	2 2	R	After 3 months of treatment, 2 patients treated with acitretin failed to achieve greater than 50% clearance. 1 patient treated with CsA had “good” response (>75%).	NR
Etretinate	Kim et al ³⁹ (1991)	12	Case series	Averaged 19.9 days for complete disappearance of scales. After 2–11 months of treatment, 10 (83.3%) patients had satisfactory results.	Cheilitis, elevated lipid profiles level
Etretinate	Rosińska et al ⁴⁰ (1988)	5	Case series	2 (40%) Patients with clinical improvement.	Focal osteoporosis
MMF	Geilen et al ⁴⁷ (1998)	2	Case series	After treatment for 6 weeks, both patients reported with 70% skin improvement.	None

Abbreviations: CsA, cyclosporine; EP, erythrodermic psoriasis; GI, gastrointestinal; MTX, methotrexate; MMF, mycophenolate mofetil; NR, not reported; PASI, Psoriasis Area and Severity Index; R, retrospective; UVB, ultraviolet B.

Methods

The electronic databases of PubMed, Embase and Google Scholar were searched for relevant studies from 1985 to March 1, 2021, using the index words, “erythrodermic psoriasis” and the co-indexing terms “treatment”, “management”, “biologic”, “methotrexate”, “cyclosporine”, “acitretin”, “etanercept”, “infliximab”, “adalimumab”, “ustekinumab”, “secukinumab”, “ixekizumab”, “brodalumab”, “guselkumab”, “tildrakizumab”, “risankizumab” and “apremilast”.

Conventional Oral Immunosuppressive Agents

Methotrexate

Methotrexate (MTX) is one of the most commonly used immunosuppressive drugs for EP.^{18–24} The treatment dosing is variable for the initial dose; the administration of 7.5

to 15mg per week for maintenance was reported based on previous retrospective studies.^{18–21,23} Dosing of 7.5 to 40mg weekly for the treatment of EP has been reported.¹ Most of the patients in previous studies reported good response to MTX,^{18–20} and Haustein et al reported the treatment response to MTX was observed within 1 to 4 weeks,²⁰ and 28 (77.8%) patients had good outcomes.²⁰ Inconsistent results were seen for child patients based on one retrospective study; among three child patients with EP under MTX, one patient did not achieve a disease-free status, but the others had approximately 14 weeks of disease-free interval.²¹ Aydin et al reported good responses for two patients treated with a combination of cyclosporine and MTX,²² and MTX was administered with 10mg intramuscular injection weekly and combined with cyclosporine 3.5mg/kg/day in divided doses. However, the time to

Table 2 Studies of Tumor Necrosis Factor Antagonist in EP Patients

Biologic Agent	Characteristics				
Etanercept	Fully humanized, soluble, recombinant fusion protein				
Infliximab	Mouse–human chimeric monoclonal antibody, IgG1				
Adalimumab	Fully humanized, monoclonal antibody, IgG1				
Golimumab	Fully humanized, monoclonal antibody, IgG1 κ				
Treatment	Author (Year)	Number of Subjects	Study design	Results	Adverse Events
Infliximab + acitretin	Takahashi et al ⁴³ (2007)	7	Case series	After third infusion of infliximab, all patients reported 90% improvement.	None
Etanercept	Esposito et al ⁴⁸ (2006)	10	Case series	At week 12, 5/10 (50%) patients achieved PASI 75. At week 24, 6/10 (60%) patients achieved or maintained PASI 75, 2/10 patients (20%) maintained improvement between PASI 50 and PASI 75.	UTI pruritus
Etanercept	Piqué-Duran et al ⁴⁹ (2007)	1	Case report	Achieved PASI 100 at week 9	NR
Infliximab Etanercept	Romero-Maté et al ⁵⁰ (2010)	1	Case report	At week 20, achieved PASI 100 with infliximab. Maintained etanercept therapy for 34 months	NR
Infliximab (n=24) Adalimumab (n=7) Etanercept (n=6) Ustekinumab (n=3) Efalizumab (n=2)	Viguier et al ⁵¹ (2011)	28	R	At week 12–14, 48% achieved PASI 75 with infliximab, 50% with adalimumab, 40% with etanercept.	Bacterial infection in 7/12 serious adverse event. Adalimumab: lymphoma. Ustekinumab: sudden death. Infliximab: immunoallergic reaction, suicide attempt.
Etanercept Infliximab	Sahel et al ⁵² 2016	2	Case report	At week 12, one case with etanercept from PASI 32.8 to 7. The other one improved to PASI 4.8 with infliximab	NR
Etanercept + MTX	Fraga et al ⁵³ (2011)	1	Case report	After 3 months of treatment, erythroderma resolved.	None
Infliximab	Poulalhon et al ⁵⁴ (2006)	5	Case series	After 14 weeks, 2 (40%) patients achieved PASI 90, and 3 patients achieved PASI 75.	Arthralgia, delayed infusion reaction, pneumonia.
Infliximab + MTX	Lisby et al ⁵⁵ (2004)	3	Case series	All patients with total clearance after first dose of infliximab.	None
Infliximab + MTX	Heikkilä et al ⁵⁶ (2005)	4	Case series	All patients reported rapidly improvement after 2 or 3 infusions of infliximab.	None

(Continued)

Table 2 (Continued).

Biologic Agent	Characteristics				
Infliximab	Torii et al ⁵⁹ (2011)	8	UCT	At week 50, 4 (50%) with reduction of >5 in DLQI.	Nasopharyngitis
Golimumab	Lee et al ⁷⁰ (2015)	1	Case report	82% Reduction in PASI score after the third injection.	None

Abbreviations: CsA, cyclosporine; DLQI, Dermatology Life Quality Index; EP, erythrodermic psoriasis; MTX, methotrexate; NR, not reported; PASI, Psoriasis Area and Severity Index; R, retrospective; TNF, tumor necrosis factor; UCT, uncontrolled clinical trial; UTI, urinary tract infection.

Table 3 Studies of IL-12/23, IL-23 Antagonist in EP Patients

Biologic Agent	Targets	Characteristics			
Ustekinumab	p40 Subunit of IL-12 and -23	Fully humanized, monoclonal antibody, IgG1κ			
Guselkumab	p40 Subunit of IL -23	Fully humanized, monoclonal antibody, IgG1			
Risankizumab	p40 Subunit of IL -23	Fully humanized, monoclonal antibody, IgG1			
Treatment	Author (Year)	Number of Subjects	Study Design	Results	Adverse Events
Ustekinumab	Pescitelli et al ⁷⁴ (2015)	22	R	At week 16, 70% of patients achieved PASI 75. More than 80% at week 28.	None
Ustekinumab	Santos-Juanes et al ⁷⁵ (2010)	2	Case series	At week 4, PASI score improvement: 81% and 94%, respectively. At week 12, PASI score improvement: 94% and 97%, respectively.	NR
Ustekinumab	Wang et al ⁷⁶ (2011)	8	Case series	At week 12 and 28, 50% of patients achieved PASI75. 12.5% achieved PASI 90 at 12 weeks, and 37.5% achieved PASI 90 at 28 weeks.	NR
Ustekinumab	Saraceno et al ⁸⁰ (2013)	2	Case series	Both of patients achieved PASI at week 12. One case maintained PASI 75 for 12 months. One case maintained PASI 90 for 64 weeks.	NR
Guselkumab	Sano et al ⁸⁶ (2018)	11	Case series	At week 16, 10 (90.9%) with treatment success.	4 (36.4%) Patients with nasopharyngitis.
Guselkumab	Megna et al ⁸⁷ (2020)	1	Case report	After 20 weeks of treatment, patient achieved PASI 100, and maintaining to week 48.	NR
Guselkumab	Chiang et al ⁸⁸ (2021)	13	Case series	PASI 75 rate: At weeks 4, 12, 20, and 28 was 15.4%, 38.5%, 53.9%, and 46.2%.	None
Risankizumab	Suleiman et al ⁸⁹ (2020)	4	Phase 3 open-label clinical trial	At week 16, all patients achieved PASI 90.	NR

Abbreviations: EP, erythrodermic psoriasis; IL, interleukin; NR, not reported; PASI, Psoriasis Area and Severity Index.

Table 4 Studies of IL-17 Antagonist in EP Patients

Biologic Agent	Targets	Characteristics			
Secukinumab	Anti-IL-17A	Fully humanized, monoclonal antibody, IgG1κ			
Ixekizumab	Anti-IL-17A	Humanized, monoclonal antibody, IgG4			
Brodalumab	Anti-IL-17R	Fully humanized, monoclonal antibody, IgG2			
Treatment	Author (Year)	Number of Subjects	Study Design	Results	Adverse Events
Secukinumab	Weng et al ⁹⁰ (2018)	10	Case series	At week 16, 4 (40%) achieved PASI 90, (70%) of patients achieved PASI 75. At week 24, 30% achieved PASI 90 and 60% achieved PASI 75.	None
Secukinumab	Mugheddu et al ⁹¹ (2017)	2	Case series	2 (100%) Patients achieved PASI 75 at week 4. Maintained efficacy were seen at 12–24 week follow-up.	None
Secukinumab	Mateu-Puchades et al ⁹² (2018)	5	Case series	3 (60%) Patients achieved PASI 75 at week 4. All patients achieved PASI 90 at week 16 and 80% had PASI 100.	NR
Secukinumab	Galluzzo et al ⁹³ (2018)	1	Case report	At week 12, the patients achieved PASI 75.	None
Secukinumab	Rongioletti et al ⁹⁴ (2018)	1	Case report	At week 12, the patients achieved PASI 100.	None
Secukinumab	Pizzatti et al ⁹⁹ (2020)	1	Case report	7 days after injection, PASI score improved from 31.5 to 17.6.	None
Ixekizumab	Saeki et al ¹⁰¹ (2017)	8	Case series	At week 52, 8 (100%) patients achieved PASI75, 6 (75%) achieved PASI90, and 1 patient achieved PASI 100.	Allergic reaction, infection, injection site reaction, hepatic disorder
Ixekizumab	Megna et al ¹⁰³ (2019)	1	Case report	After 6 weeks, patient achieved PASI 100, and maintaining to week 24.	None
Ixekizumab + acitretin, Secukinumab	Pangilinan et al ¹⁰⁵ (2020)	1	Case series	After two weeks of ixekizumab injection, PASI score improved from 36 to 5. The other one achieved PASI 100 after 4 doses of secukinumab.	None
Ixekizumab	Lo et al ¹⁰⁶ (2019)	9	Case series	4 (44%) Patients achieved PASI 75 at week 12.	4 (44.4%) Patients with injection site reaction.
Ixekizumab	Lo et al ¹⁰⁷ (2021)	14	Case series	After 52 weeks, three (21.4%) patients achieved PASI 75.	5 (35.7%) Patients with injection site reaction. 1 patient with vulvovaginal candidiasis.
Brodalumab	Yamasaki et al ¹⁰⁸ (2017)	18	Case series	After week 12, 14 (77.8%) patients achieved PASI 75, 9 (50%) patients achieved PASI 90, and 3 (16.7%) patients achieved PASI 100. At week 52, 88.9%, 88.9%, and 61.1% achieved PASI 75, PASI 90, and PASI 100.	Nasopharyngitis

(Continued)

Table 4 (Continued).

Biologic Agent	Targets	Characteristics			
Brodalumab	Bernardini et al ¹⁰⁹ (2020)	1	Case report	At week 4, PASI score decreased from 42 to 22.	None
Brodalumab	Megna et al ¹¹⁰ (2020)	2	Case series	One case achieved PASI 90 at week 3. One case achieved PASI 90 at week 12.	None

Abbreviations: EP, erythrodermic psoriasis; IL, interleukin; IL-17R, interleukin-17 receptor; NR, not reported; PASI, Psoriasis Area and Severity Index.

Table 5 Other Treatment in EP Patients

Treatment	Author (Year)	Number of Subjects	Study Design	Results	Adverse Events
Apremilast	Papadavid et al ¹¹¹ (2017)	1	Case report	Achieved PASI 100 at 20 days. Relapse after week 12.	None
Apremilast	Krishnamoorthy et al ¹¹² (2019)	1	Case report	Achieved PASI 100 at week 10. Remained free of psoriasis for 1 year.	None
Apremilast	Arcilla et al ¹¹³ (2016)	1	Case report	NR	Atrial fibrillation
Apremilast	Mugheddu et al ¹¹⁴ (2020)	1	Case report	NR	None
Naltrexone	Beltran Monasterio et al ¹¹⁵ (2019)	1	Case report	Achieved complete remission after 3 months of treatment.	None
Panitumumab	Nishizawa et al ¹¹⁶ (2012)	1	Case report	Erythrodermic status improved after 10 days of treatment.	None
Coenzyme Q10 + vitamin E +selenium	Kharaeva et al ¹¹⁷ (2009)	7 7 (placebo group)	RCT	After treatment for 30 days, PASI scores for the supplement group were 19 ± 4 compared to 30 ± 5 in the placebo group ($p < 0.05$)	None

Abbreviations: EP, erythrodermic psoriasis; NR, not reported; PASI, Psoriasis Area and Severity Index; RCT, randomized controlled trial.

response was also not documented. Patients with EP usually tolerated MTX well,^{18,20–22,24} and nausea and vomiting were the most commonly reported adverse events; however, hepatotoxicity, hematologic and metabolic complications should be monitored.^{24,25}

Cyclosporine

Cyclosporine is an immunosuppressive medication that blocks IL-2 transcription and results to inhibiting the growth of T-cell and proliferation.²⁶ Several case reports and studies revealed the efficacy of cyclosporine for EP.^{22,27–37} The reported dosing of cyclosporine ranged from 1.5 to 5mg/kg/

day.^{27–29,34} The largest study is one open-label, single-center study from Italy which had 22 (66.7%) patients in complete remission, with the initial mean dose of 4.2mg/kg/day, and tapered by 0.5mg/kg every 2 weeks.²⁷ Ninety-four percent of the patients responded to the treatment according to the study,²⁷ and approximately 2–4 months were needed to achieve the treatment outcome. A faster treatment response seen within 1 month was reported for a combination treatment of cyclosporine and etretinate.^{33–35} Combination therapies with other treatment modalities were also reported, including MTX,²² alefacept,³² etretinate^{33–35} and phototherapy.³⁶ One case series reported three cases with

rapid response under cyclosporine and etretinate, achieving complete remission after combination treatment for 11–18 days, and with no signs of relapse during 1 year of follow-up.³⁴ However, one case series reported failure to control in three patients with acitretin and cyclosporine.³⁸ Cyclosporine is usually well-tolerated, though side effects including gastrointestinal upset,³⁷ hypertension³⁷ and acute kidney injury were reported.³⁹ Clinicians should avoid using cyclosporine in elderly patients with hypertension or impaired renal function.¹ Cyclosporine is considered a first-line therapy for acute and unstable cases according to the published consensus of the US National Psoriasis Foundation in 2010.¹

Acitretin/Etretinate

Both etretinate and its active metabolite acitretin are often used for the treatment of EP,^{33–35,37,40–45,47} but the results have been inconsistent. Kim et al reported satisfactory outcomes for 12 patients with a monotherapy of acitretin,⁴⁰ 10 (83.3%) patients reported remission under the initial dose of 20–60 mg daily. The average time to complete clearing of erythematous scales was 19.9 days, and the duration of clearing of erythema ranged from 2 to 11 months. However, Charbit et al reported two patients who failed to achieve greater than 50% clearance after 3 months of treatment,³⁷ and in the report by Rosińska et al, only two of five children showed favorable results after treatment of one to 4 months of etretinate.⁴¹ Combination therapies with other immunosuppressive medication were common, including cyclosporine,³⁷ acitretin with azathioprine,⁴³ or infliximab,⁴⁴ and etretinate with cyclosporine^{33–35} or MTX.⁴² One patient with EP coexisting with bullous pemphigoid was treated successfully with acitretin and azathioprine.⁴³ Acitretin and MTX are considered more suitable for stable cases, compared to infliximab and cyclosporine,¹ but due to the possible hepatotoxicity, this combination should be used cautiously. However, a case of EP caused by acitretin was reported.⁴⁵ The use of a lower initial dose of acitretin reduced the risk of worsening erythrodermic status compared to higher dose.⁴⁶ Cheilitis is the most common side effect under acitretin or etretinate.^{34,40} Gastrointestinal upset and elevated lipid profile levels⁴² should also be monitored. In addition, bone density should be checked as focal osteoporosis has been reported.⁴¹

Mycophenolate Mofetil (MMF)

Limited evidence exists for successfully using MMF for treating EP. Only one case reported two patients treated with MMF,⁴⁸ and both of them experienced 70% skin improvement after 6 weeks of treatment. No adverse effects were observed during the treatment course, and the disease did not relapse after drug discontinuation.

Tumor Necrosis Factor (TNF) Antagonist Etanercept

Etanercept, a recombinant human fusion protein, has demonstrated efficacy in treating EP.^{49–54} Esposito et al reported that with 25 mg twice weekly, a treatment response could be observed between week 12–24.⁴⁹ At week 12, five of ten (50%) patients achieved PASI 75, and at week 24, six of ten (60%) patients achieved or maintained PASI 75, and two of ten patients (20%) maintained improvement between PASI 50 and PASI 75. Piqué-Duran et al reported one case who achieved PASI 100 as early as week 9.⁵⁰ Romero-Marte et al reported one case with stable condition under etanercept for 34 months after suboptimal response to infliximab.⁵¹ In a retrospective study, 50 mg dosing twice weekly for 12 weeks, then 50 mg weekly thereafter, 40% patients achieved PASI 50 at week 24–28.⁵² Infection is the most common side effect, with pneumonia, and *Staphylococcus aureus* septicemia and urinary infection being reported.^{49,52}

Infliximab

Infliximab, a chimeric monoclonal antibody, is considered to be a first-line biologic for EP due to its rapid onset.^{1,44,52,53,55–70} In one multicenter study that included 24 patients,⁵² one-third of the patients achieved PASI 75 at week 4 with infliximab treatment. But long-term efficacy is not so promising, as at the same study that only 48% of patients achieved PASI 75 at week 14,⁵² and one case reported no further improvement after the sixth infusion of infliximab; the subject's condition was then controlled by administration of etanercept.⁵¹ The occurrence of the anti-infliximab antibody was considered to be the reason.⁵⁵ Poulalhon et al reported the prevalence of positive detection of anti-nuclear antibodies (ANA) increased from 12% to 72% at week 22.⁵⁵ Thus, the use of infliximab as long-term controlling medication for EP should be evaluated. Concurrent administration with immunosuppressive medication would induce rapid clearing of erythrodermic status,^{44,56,57} and MTX and acitretin are often used.

Lisby et al and Heikkila et al reported rapid treatment responses with a combination treatment with MTX.^{56,57} Heikkila et al reported four (100%) patients with excellent responses after the second or third infusion of infliximab combined with MTX,⁵⁶ and Lisby et al reported three (100%) patients that almost clearance within a week after the first infusion of infliximab.⁵⁷ The dosing of infliximab ranged from 2.7 to 4.4 mg per kg and MTX with 5 to 7.5 mg per week.⁵⁷ Infection is the most common side effect, such as staphylococcus aureus septicemia,^{52,57} nasopharyngitis,⁶⁰ and erysipelas.^{52,57} Moreover, delayed infusion reactions,⁵⁵ myocardial infarction, suicide attempts and immunoallergic shock have also been reported after administration of infliximab.⁵² Furthermore, one case reported CD30+ T-cell lymphoma under the treatment of cyclosporine and infliximab,⁵⁸ and the lesion regressed after discontinuation of these agents.

Golimumab

Golimumab, another anti-TNF, is a fully human γ -1 immunoglobulin- κ monoclonal antibody. The evidence of golimumab for treating EP is limited with only one report.⁷¹ After three sessions of golimumab 50 mg injections every 4 weeks, the patient achieved PASI 75 without any side effects.

Adalimumab

Adalimumab is another fully human monoclonal antibody against TNF. There have been only nine patients receiving adalimumab for treatment, including one multicenter, retrospective study with seven patients,⁵² and two case reports.^{72,73} Most data are from the retrospective study which revealed that 67% of the patients achieved PASI75 at week 10 to 14, and at week 22 to 24, 50% of the patients achieved PASI75 or 75% improvement in BSA, compared to 25% of the patients treated with etanercept and 30% of the patients treated with infliximab in that study.⁵² Richetta et al reported one case involving a hepatitis C virus (HCV) flare-up after treatment with pegylated interferon alpha-2a and ribavirin. The symptoms were controlled by adalimumab at week 3, and no adverse effects were observed during the 5 weeks of treatment.⁷³ One patient was diagnosed with nodal T-cell lymphoma 3 months later after administration of adalimumab.⁵² Paradoxically, there are also reports regarding adalimumab as a trigger of EP.⁷⁴

IL-12/23, IL-23 Antagonist

Ustekinumab

Ustekinumab, a monoclonal p40 IL-12/23 antagonist, has been reported for treatment of EP in several articles.^{75–85} The largest study was from Italy,⁷⁵ which include 22 patients. As early as week 4, most of the patients had improved clinical condition, 15 (68.2%) patients achieved PASI 90 at week 28, and sustained effects were seen at week 60. Additionally, Wang et al reported suboptimal treatment effects: at week 28, only 3 (37.5%) patients achieved PASI 90.⁷⁷ Ustekinumab has also been reported as effective for cases of prior failure with anti-TNF agents,^{76,82–84} and one case reported sustained maintained PASI 90 at week 114 of treatment.⁸⁴ However, Viguier et al reported three cases under the treatment of ustekinumab, in which only one (33.3%) had treatment response,⁵² with the other two patients experiencing inadequate response to prior anti-TNF agents. Ustekinumab is also considered as a first-line treatment for acute and severe cases of EP.⁷⁰ Although ustekinumab is considered to have a relative low risk of infection compared to anti-TNF agents, a case of latent TB reactivation induced by ustekinumab has been reported.⁸⁶ One adverse event of sudden death was reported after 9 months of treatment of ustekinumab.⁵² Furunculosis and widespread *Staphylococcus* infection have been observed.⁵²

Guselkumab

Guselkumab, an interleukin 23 inhibitor that targets the p19 subunit, was reported as effective for EP in 24 cases. In an open-label, multicenter, Phase 3 study⁸⁷ (50mg at weeks 0, 4 and every 8 weeks thereafter until week 52), 10 (90.9%) patients achieved treatment success, while 5 (45.5%) patients achieved “very much improved” under Clinical Global Impression of Improvement (CGI). At week 52, 10 (90.9%) patients achieved a mean absolute PASI of 3.9 (SD = 4.27) with a median improvement of 94.1%. Megna et al reported one patient achieved PASI 100 after 20 weeks of therapy, and the effect remained until week 48.⁸⁸ Chiang et al reported 13 patients with follow-up for 28 weeks,⁸⁹ in which 8 (61.5%) patients achieved PASI 50 response at week 12, and sustained effects were observed for these PASI 50 responders. The treatment efficacy at week 12 could be seen as one predictor for patient response for guselkumab.⁸⁹ The most common adverse event was nasopharyngitis.⁸⁷

Risankizumab

Risankizumab is another IL-23 antagonist that targets the p19 subunit. One phase 3 open-label clinical trial has been completed in Japanese patients with pustular psoriasis or EP,⁹⁰ dosing with 75 mg at week 0, week 4, and every 12 weeks. At week 16, the clinical response was 100%, and all of the patients achieved PASI 90.

IL-17 Antagonist

Secukinumab

Secukinumab, a fully human monoclonal IL-17A antibody, is administered at a dose of 300 mg weekly for the first 5 weeks and every 4 weeks thereafter for the treatment of EP.^{91–101} The efficacy of secukinumab can be seen as early as week 2 to week 6.^{92–94} Mateu-Puchades et al reported 5 (100%) patients achieved PASI 90 at week 16 to week 20.⁹³ Furthermore, long-term remission was observed for patients with EP under secukinumab.^{96,97,100,101} One multicenter, retrospective study reported 10 of 13 (76.9%) patients had a treatment response.⁹⁸ At week 52, 5 (38.5%) patients achieved PASI 90 and 5 patients achieved PASI 100, and the median time to clearance was 3 weeks.⁹⁸ No recurrences were seen during the 52 weeks follow-up.⁹⁸ However, Weng et al reported that only 6/10 patients (60%) achieved PASI 75 response at week 24 possibly because most of the patients had failed with multiple biologics previously.⁹¹ No major events were observed during treatment course.^{91–93}

Ixekizumab

Ixekizumab, another IL-17A blocker, demonstrated a sustained effect for EP according to a study from Japan.^{102,103} In an open-label, phase 3 study, eight patients were enrolled (dosed 160 mg at week 0, 80 mg every 2 weeks through week 12, and 80 mg every 4 weeks until to week 244).^{102,103} Eight (100%) patients achieved PASI 75 after 12 weeks of treatment, all patients maintained PASI 75 at week 24 and week 52, and 6 (75%) patients achieved PASI 90.¹⁰² The results revealed that the effects were sustained to week 244, the mean PASI score was 42.8 at baseline, 3.0 at week 52, and 5.0 at week 244. There are also several case reports regarding the efficacy of ixekizumab for EP,^{104–106} including one case with human immunodeficiency virus (HIV) infection.¹⁰⁶ For patients with prior failure with secukinumab, ixekizumab still demonstrated a rapid response as early as week 4.¹⁰⁷ Suboptimal responses were reported in only four (44%) patients, who achieved PASI 75 at week 12 according to a previous

study. In addition, the response was even poorer after prolonged use.¹⁰⁸ After week 52, the discontinuation rate increased, only three (21.4%) patients achieved PASI 75, and one (7.1%) patient achieved PASI 90. Infection was a common side effect,¹⁰³ including upper respiratory tract infection and gastroenteritis. Injection-site swelling was also observed in about 30% of the cases.^{107,108}

Brodalumab

Brodalumab, an anti-IL-17-receptor antibody, also demonstrated efficacy for EP.

There is one open-label study and two case reports discussing the treatment of brodalumab.^{109–111} During a 52-week, phase 3, multicenter, open-label study,¹⁰⁹ with brodalumab 140mg twice weekly subcutaneous administration initially (week 0, week 1, week 2), 5 (27.8%) patients were shifted to receive 210 mg based on the investigators' decision. Eighteen (100%) patients showed clinical improvement, under the definition of achieving CGI classified as "improved" or "remission" at week 12 and week 52. Sustainable effects were observed through week 52, PASI 75 and PASI 90 achievement rates were both 88.9%, while the PASI 100 response was 61.1%. Bernardini et al reported one case with EP and polycythemia,¹¹⁰ and the PASI score improved from 42 to 22 within 4 weeks of treatment with brodalumab. Megna et al reported two cases successfully treated with EP, one achieved PASI 90 at week 3 and reached PASI 100 at week 12, and the other one achieved PASI 90 at week 12.¹¹¹ Patients usually tolerated brodalumab well without major adverse events,^{110,112} The most common adverse event was nasopharyngitis.¹⁰⁹

Others

Apremilast

Apremilast, a phosphodiesterase 4 (PDE4) inhibitor, has been used for EP in four case reports.^{112–115} Papadavid et al reported one case of a previous failure with MTX, cyclosporine and adalimumab, who achieved PASI 100 after apremilast 30 mg twice daily for 20 days.¹¹² Krishnamoorthy et al reported one case with the total resolution of the lesions after 10 weeks of treatment without relapse for 1 year.¹¹³ Another case was infected with coronavirus 2019 (COVID-19) and was treated successfully with apremilast for EP.¹¹⁵ Apremilast may also be effective for elderly EP patient, according to one retrospective study.¹¹⁶ Papadavid et al reported gradual deterioration of the absolute PASI score after 4 months of treatment.¹¹² Infection is still one of the common side

effects as one case experienced two episodes of upper respiratory infection during the treatment with apremilast.¹¹³ Furthermore, one major adverse event was atrial fibrillation induced by apremilast.¹¹⁴

Naltrexone

Naltrexone, which affects the opioid growth factor-opioid growth factor receptor, also plays a role in the immune system. Beltran Monasterio et al reported after oral low-dose naltrexone with a daily dose of 4.5 mg for 3 months, the patient remained complete remission after 6 months of treatment.¹¹⁷

Panitumumab

Panitumumab is a human monoclonal antibody against EGFR, and was reported to have some clinical effect for psoriasis in one patient with rectal cancer.¹¹⁸ The patient had improved clinical condition within 10 days of treatment with panitumumab, although no PASI score was reported.

Antioxidants

In one randomized controlled trial, coenzyme Q10, vitamin E, and selenium supplementation were beneficial for EP.¹¹⁹ Clinical conditions improved with supplementation of antioxidants. After treatment for 30 days, PASI score was 19 ± 4 for the supplement group and 30 ± 5 for the placebo group ($p < 0.05$). Due to a lack of further studies, the evidence for using antioxidants for EP has been called into question.

Systemic Steroid

Systemic steroid is not recommended according to the published consensus of the US National Psoriasis Foundation in 2010.¹ However, the use of systemic steroid for treatment of psoriasis may be more common than expected in real world but is highly controversial. Exacerbation of erythrodermic status after withdrawal or reduction of systemic corticosteroid has been well documented,² but it may be uncommon as reported in some recent studies.^{120,121} Anecdotal reports showed improvement of EP following systemic steroid.^{86,122} Short course systemic steroid, combined with conventional immunosuppressive agents, can be considered for acute cases¹²² who are not accessible or contraindicated to biologics or cyclosporine.

Phototherapy

Phototherapy is not suggested for acute EP, due to the photosensitization can increase the risk of Koebnerization.^{1,2} But phototherapy can still be

considered as one of the treatment options for long-term, stable EP cases.¹ Some case reported phototherapy as adjunctive therapy for EP.^{123,124} Pang et al reported one case with phototherapy as adjunctive therapy who was refractory to acitretin.¹²³

Discussion

EP is a variant of psoriasis that is more resistant to conventional treatment. Biologics have revolutionized the treatment of plaque-type psoriasis, and shown promise in EP.^{70,125,126} Anti-TNF agents, such as infliximab and etanercept can be combined with traditional immunosuppressive agents for better efficacy,¹²⁵ while anti-IL12/23 agents and anti-IL17 agents are usually given as monotherapy for EP due to their superior efficacy, and are therefore used as first-line treatments for EP, including ustekinumab, secukinumab, ixekizumab, guselkumab and brodalumab.^{70,125,126} In particular, anti-IL17 agents can control the symptoms of EP within weeks,^{92–94,107,109–111} which may be considered in patients who need rapid control. Furthermore, an ongoing trial for risankizumab revealed promising results for 16 weeks,⁹⁰ but the longer-duration efficacy remains to be published.

However, there is evidence supporting the efficacy of biologics for treating EP in case reports and case-series, albeit they often lack long-term follow up data. In pivotal trials of biologics for psoriasis, current or even prior EP have been excluded for the study.¹²⁷ Even in countries that issue indications for use of biologics for EP, such as Japan, the number of patients in the trials have been severely limited, 8 for infliximab,⁶⁰ 8 for ixekizumab,¹⁰² 11 for guselkumab,⁸⁷ and 18 for brodalumab.¹⁰⁹ Moreover, none of the trials were randomized active or placebo controlled trials. Among the biologics, fewer major adverse events were reported for anti-IL12/23 agents and anti-IL17 agents than anti-TNF agents, and infection remains the most common side effect which should be monitored. Interestingly, according to a previous study,¹²⁸ in biologic-naïve patients with psoriasis or psoriatic arthritis, anti-IL12/23 agents were associated with a reduced risk of infection compared to anti-TNF and anti-IL-17 agents. However, there is no difference in infection risk in either of these agents in patients with prior biologic use. Whether the result can be applied to EP patients awaits further studies. In addition, it is also important to consider the comorbidities during the treatment of EP.² Several articles reported EP triggered by infection, such as HCV and HIV infection.^{47,73,106} Although biologics are considered safer

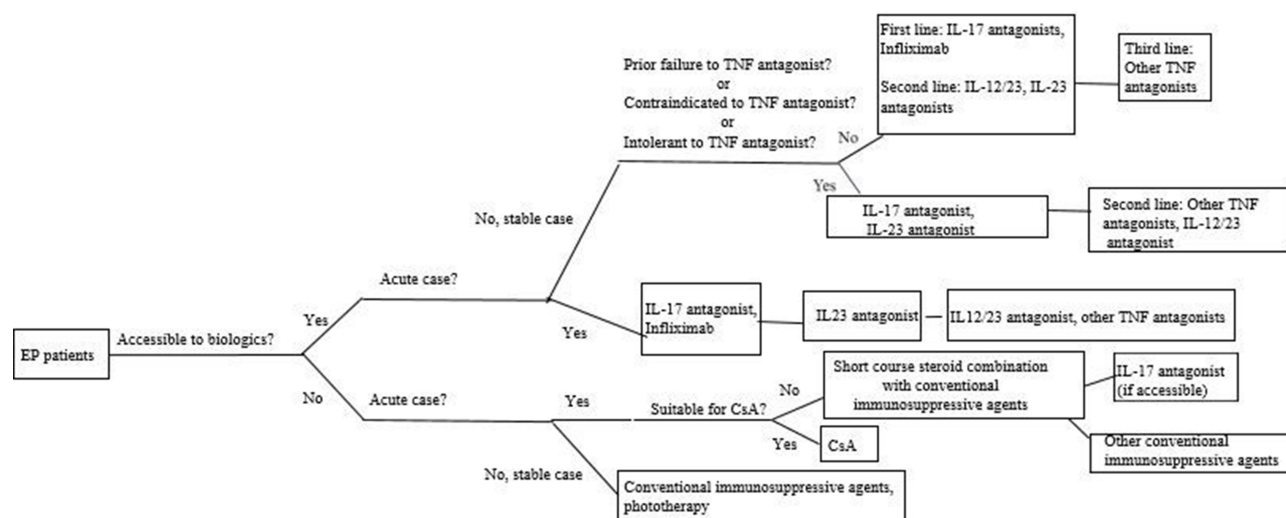


Figure 1 Treatment algorithm of EP, suggested by the author.

Abbreviations: CsA, cyclosporine; EP, erythrodermic psoriasis; IL, interleukin; TNF, tumor necrosis factor.

agents compared to conventional oral agents, their use in patients with viral hepatitis and HIV remains limited.

Drug survival is impaired in EP compared to plaque-type psoriasis in post-marketing studies. Thus, patients with EP treated with biologics tend to have multiple experiences of prior biologics failure, which will also compromise subsequent treatment efficacy.¹²⁹ In general, patients achieved better efficacy after switching to IL-23 and IL-17 antagonists after previous poor response to anti-TNF agents and ustekinumab.¹³⁰ However, in patients with prior inadequate response to secukinumab,^{107,108} the results were poorer than the open-label, phase 3 study after the switch to ixekizumab.¹⁰³ Interestingly, although the efficacy of small oral molecules is less satisfactory compared to biologics in the treatment of psoriasis, two promising results of using apremilast were reported in EP^{112,113}; however, the case numbers were small. Likewise, tofacitinib has been reported to be effective in patients with moderate to severe psoriasis who had inadequate responses to prior biologics.¹³¹ However, its role in EP remains unknown. Further head-to-head controlled studies are needed for more evidence-based treatment guidelines.

For patients who have no access to biologics, conventional immunosuppressive agents are suggested. Cyclosporine is suggested for acute cases, and others for stable cases.¹ Short course systemic corticosteroid should be reserved for EP patients during severe acute flare who do not have access to biologics and are contraindicated to cyclosporine due to uncontrolled hypertension or renal insufficiency or malignancy. Even in these patients, adequate hydration

and aggressive control of hypertension should be attempted to enable the use of cyclosporine. However, the optimal dose and duration of systemic corticosteroid use is unknown. Transition and/or overlap to a non-systemic corticosteroid regimen should be initiated once the acute flare is controlled. Preferably, a fast onset biologic such as IL-17 inhibitor should be given to prevent the rebound/flare of psoriasis after corticosteroid withdrawal. However, gradual corticosteroid taper may be needed if conventional oral agents or phototherapy are used. We propose the algorithm for treatment of EP after literature review (Figure 1).

Conclusion

Despite the rapid progress in the development of biologics for psoriasis, data supporting the efficacy in EP remain limited. Also, the remission duration and risk of rebound upon discontinuation are poorly studied. In addition, it is important to understand the drug survival time, optimal dosing, and pharmacokinetics of biologics for EP.

Funding

There is no funding to report.

Disclosure

Dr Tsen-Fang Tsai has conducted clinical trials and/or received honoraria for serving as a consultant for AbbVie, Boehringer Ingelheim, Bristol Myers Squibb, Celgene, Eli Lilly, Galderma, GSK-Stiefel, Janssen-Cilag, LeoPharma, Merck Sharp & Dohme, Novartis, Pfizer and Serono International SA (now Merck Serono

International). Dr Yang Lo has no conflicts of interest to declare.

References

- Rosenbach M, Hsu S, Korman NJ, et al. Treatment of erythrodermic psoriasis: from the medical board of the National Psoriasis Foundation. *J Am Acad Dermatol*. 2010;62(4):655–662. doi:10.1016/j.jaad.2009.05.048
- Boyd AS, Menter A. Erythrodermic psoriasis. Precipitating factors, course, and prognosis in 50 patients. *J Am Acad Dermatol*. 1989;21(5 Pt 1):985–991. doi:10.1016/S0190-9622(89)70287-5
- Yan D, Afifi L, Jeon C, Cordoro KM, Liao W. A cross-sectional study of the distribution of psoriasis subtypes in different ethno-racial groups. *Dermatol Online J*. 2018;24(7):13030/qt5z21q4k2.
- Chen HS, Tseng MP, Tsai TF. An epidemiologic study of Taiwanese psoriatic patients in a single clinic. *Dermatol Sinica*. 2003;21(3):216–224.
- Stinco G, Errichetti E. Erythrodermic psoriasis: current and future role of biologicals. *BioDrugs*. 2015;29(2):91–101. doi:10.1007/s40259-015-0119-4
- Lo Y, Chiu HY, Tsai TF. Clinical Features and Genetic Polymorphism in Chinese Patients with Erythrodermic Psoriasis in a Single Dermatologic Clinic. *Mol Diagn Ther*. 2020;24(1):85–93. doi:10.1007/s40291-019-00441-x
- Zhang P, Chen H, Duan Y, et al. Analysis of Th1/Th2 response pattern for erythrodermic psoriasis. *J Huazhong Univ Sci Tech Med Sci*. 2014;34(4):596–601. doi:10.1007/s11596-014-1322-0
- Li L-F, Sujana SA, Yang H, Wang W-H. Serum immunoglobulins in psoriatic erythroderma. *Clin Exp Dermatol*. 2005;30(2):125–127. doi:10.1111/j.1365-2230.2004.01717.x
- Deeva I, Mariani S, De Luca C, et al. Wide-spectrum profile of inflammatory mediators in the plasma and scales of patients with psoriatic disease. *Cytokine*. 2010;49(2):163–170. doi:10.1016/j.cyto.2009.09.014
- Groves RW, Kapahi P, Barker JN, Haskard DO, MacDonald DM. Detection of circulating adhesion molecules in erythrodermic skin disease. *J Am Acad Dermatol*. 1995;32(1):32–36.
- Moy AP, Murali M, Kroshinsky D, Duncan LM, Nazarian RM. Immunologic Overlap of Helper T-Cell Subtypes 17 and 22 in Erythrodermic Psoriasis and Atopic Dermatitis. *JAMA Dermatol*. 2015;151(7):753–760. doi:10.1001/jamadermatol.2015.2
- Wang H, Wang S, Li L, et al. Involvement of the cytokine TWEAK in the pathogenesis of psoriasis vulgaris, pustular psoriasis, and erythrodermic psoriasis. *Cytokine*. 2020;138:155391. doi:10.1016/j.cyto.2020.155391
- Zheng J, Gao Y, Liu N, et al. Higher prevalence of thyroid dysfunction in patients with erythrodermic psoriasis. *J Dermatol*. 2020;47(9):1007–1012. doi:10.1111/1346-8138.15427
- Chen L, Tsai TF. HLA-Cw6 and psoriasis. *Br J Dermatol*. 2018;178(4):854–862. doi:10.1111/bjd.16083
- Henseler T, Koch F, Westphal E. Presence of HLA-DR7 in type I psoriasis. *J Invest Dermatol*. 1992;98(4):607.
- Mallon E, Bunce M, Savoie H, et al. HLA-C and guttate psoriasis. *Br J Dermatol*. 2000;143(6):1177–1182. doi:10.1046/j.1365-2133.2000.03885.x
- Signa S, Campione E, Rusmini M, et al. Whole exome sequencing approach to childhood onset familial erythrodermic psoriasis unravels a novel mutation of CARD14 requiring unusual high doses of ustekinumab. *Pediatr Rheumatol Online J*. 2019;17(1):38. doi:10.1186/s12969-019-0336-3
- Collins P, Rogers S. The efficacy of methotrexate in psoriasis—a review of 40 cases. *Clin Exp Dermatol*. 1992;17(4):257–260. doi:10.1111/j.1365-2230.1992.tb02161.x
- Van Dooren-greebe RJ, Kuijpers AL, Mulder J, De Boo T. Methotrexate revisited: effects of long-term treatment in psoriasis. *Br J Dermatol*. 1994;130(2):204–210. doi:10.1111/j.1365-2133.1994.tb02901.x
- Haustein UF, Rytter M. Methotrexate in psoriasis: 26 years' experience with low-dose long-term treatment. *J Eur Acad Dermatol Venereol*. 2000;14(5):382–388. doi:10.1046/j.1468-3083.2000.00058.x
- Kumar B, Dhar S, Handa S, Kaur I. Methotrexate in childhood psoriasis. *Pediatr Dermatol*. 1994;11(3):271–273. doi:10.1111/j.1525-1470.1994.tb00602.x
- Aydin F, Canturk T, Senturk N, Turanlı AY. Methotrexate and ciclosporin combination for the treatment of severe psoriasis. *Clin Exp Dermatol*. 2006;31(4):520–524. doi:10.1111/j.1365-2230.2006.02153.x
- Khaled A, Ben Hamida M, Zeglaoui F, Kharfi M, Ezzine N, Faza'a B. Traitement du psoriasis par méthotrexate à l'ère des biothérapies: étude chez 21 patients tunisiens [Treatment of psoriasis by methotrexate in the era of biotherapies: a study in 21 Tunisian patients]. *Thérapie*. 2012;67(1):49–52. doi:10.2515/therapie/2012004
- Hawilo A, Zaraq I, Benmously R, et al. Erythrodermic psoriasis: epidemiological clinical and therapeutic features about 60 cases. *Tunis Med*. 2011;89(11):841–847.
- Mahmood T, Zaghi D, Menter A. Emerging oral drugs for psoriasis. *Expert Opin Emerg Drugs*. 2015;20(2):209–220. doi:10.1517/14728214.2015.1010509
- Lim KK, Su WP, Schroeter AL, Sabers CJ, Abraham RT, Pittelkow MR. Cyclosporine in the treatment of dermatologic disease: an update. *Mayo Clin Proc*. 1996;71(12):1182–1191. doi:10.4065/71.12.1182
- Studio Italiano Multicentrico nella Psoriasi (SIMPSO). Management of erythrodermic psoriasis with low-dose cyclosporine. *Dermatology*. 1993;187(Suppl 1):30–37. doi:10.1159/000247289
- Bruzzese V, Pepe J. Efficacy of cyclosporine in the treatment of a case of infliximab-induced erythrodermic psoriasis. *Int J Immunopathol Pharmacol*. 2009;22(1):235–238. doi:10.1177/039463200902200126
- Ahdout J, Mandel H, Chiu M. Erythroderma in a patient taking acitretin for plaque psoriasis. *J Drugs Dermatol*. 2008;7(4):391–394.
- Sprecher E, Bergman R, Friedman-Birnbaum R. Cyclosporine treatment of psoriatic erythroderma complicated by bacterial sepsis. *J Eur Acad Dermatol Venereol*. 1999;12(2):197–198. doi:10.1111/j.1468-3083.1999.tb01027.x
- Borghini A, Corazza M, Mantovani L, Bertoldi AM, Giari S, Virgili A. Prolonged cyclosporine treatment of severe or recalcitrant psoriasis: descriptive study in a series of 20 patients. *Int J Dermatol*. 2012;51(12):1512–1516. doi:10.1111/j.1365-4632.2012.05571.x
- Prossick TA, Belsito DV. Alefacept in the treatment of recalcitrant palmoplantar and erythrodermic psoriasis. *Cutis*. 2006;78(3):178–180.
- Brechtel B, Wellenreuther U, Toppe E, Czarnetski BM. Combination of etretinate with cyclosporine in the treatment of severe recalcitrant psoriasis. *J Am Acad Dermatol*. 1994;30(6):1023–1024. doi:10.1016/S0190-9622(09)80147-3
- Kokelj F, Plozzer C, Torsello P, Trevisan G. Efficacy of cyclosporine plus etretinate in the treatment of erythrodermic psoriasis (three case reports). *J Eur Acad Dermatol Venereol*. 1998;11(2):177–179.

35. Korstanje MJ, Bessems PJ. Combination therapy ciclosporin-etretinate effective in erythrodermic psoriasis. *Dermatologica*. 1989;179(2):94. doi:10.1159/000248324
36. Franchi C, Cainelli G, Frigerio E, Garutti C, Altomare GF. Association of cyclosporine and 311 nM UVB in the treatment of moderate to severe forms of psoriasis: a new strategic approach. *Int J Immunopathol Pharmacol*. 2004;17(3):401–406. doi:10.1177/039463200401700321
37. Charbit L, Mahé E, Phan A, et al. Systemic treatments in childhood psoriasis: a French multicentre study on 154 children. *Br J Dermatol*. 2016;174(5):1118–1121. doi:10.1111/bjd.14326
38. Kuijpers ALA, van Dooren-greebe RJ. Failure of combination therapy with acitretin and cyclosporine A in 3 patients with erythrodermic psoriasis. *Dermatology*. 1997;194(1):88–90. doi:10.1159/000246070
39. Rao S, Bernshteyn M, Sohal R, Proumen R, Goodman A, Shepherd Z. The Management of Erythrodermic Psoriasis Complicated by Cyclosporine. *Case Rep Dermatol Med*. 2020;2020:5215478. doi:10.1155/2020/5215478
40. Kim BS, Shin KS, Youn JI, Lee YS. Treatment of erythrodermic psoriasis with etretinate. *Ann Dermatol*. 1991;3(2):107–111. doi:10.5021/ad.1991.3.2.107
41. Rosińska D, Wolska H, Jablonska S, Konca I. Etretinate in severe psoriasis of children. *Pediatr Dermatol*. 1988;5(4):266. doi:10.1111/j.1525-1470.1988.tb00902.x
42. Tuyp E, MacKie RM. Combination therapy for psoriasis with methotrexate and etretinate. *J Am Acad Dermatol*. 1986;14(1):70–73. doi:10.1016/S0190-9622(86)70009-1
43. Roeder C. Psoriatic erythroderma and bullous pemphigoid treated successfully with acitretin and azathioprine. *Eur J Dermatol*. 1999;9(7):537–539.
44. Takahashi MDF, Castro LG, Romiti R. Infliximab, as sole or combined therapy, induces rapid clearing of erythrodermic psoriasis. *Br J Dermatol*. 2007;157(4):828–831. doi:10.1111/j.1365-2133.2007.08111.x
45. Ahdout J, Mandel H, Chiu M. Erythroderma in a patient taking acitretin for plaque psoriasis. *J Drugs Dermatol*. 2008;7:391.
46. Ling MR. Acitretin: optimal dosing strategies. *J Am Acad Dermatol*. 1999;41(3 Pt 2):S13–17. doi:10.1016/S0190-9622(99)70360-9
47. Valenzuela F, Fernández J, Sánchez M, Zamudio A. Erythrodermic psoriasis and human immunodeficiency virus: association and therapeutic challenges. *An Bras Dermatol*. 2018;93(3):438–440. doi:10.1590/abd1806-4841.20187387
48. Geilen CC, Tebbe B, Garcia Bartels C, Krenzel S, Orfanos CE. Successful treatment of erythrodermic psoriasis with mycophenolate mofetil. *Br J Dermatol*. 1998;138(6):1101–1102. doi:10.1046/j.1365-2133.1998.02296.x
49. Esposito M, Mazzotta A, de Felice C, Papoutsaki M, Chimenti S. Treatment of erythrodermic psoriasis with etanercept. *Br J Dermatol*. 2006;155(1):156–159. doi:10.1111/j.1365-2133.2006.07217.x
50. Pique-Duran E, Perez-Cejudo JA. Psoriatic erythroderma treated with etanercept. *Actas Dermosifiliogr*. 2007;98(7):508–510.
51. Romero-Maté A, García-Donoso C, Martínez-Morán C, Hernández-Núñez A, Borbujo J. Long-term management of erythrodermic psoriasis with anti-TNF agents. *Dermatol Online J*. 2010;16(6):15.
52. Viguier M, Pagès C, Aubin F, et al. Efficacy and safety of biologics in erythrodermic psoriasis: a multicentre, retrospective study. *Br J Dermatol*. 2012;167(2):417–423. doi:10.1111/j.1365-2133.2012.10940.x
53. Sahel H, Bouadjar B. Treatment of Erythrodermic Psoriasis with Infliximab and Etanercept in Two Cases. *J Clin Exp Cosme Derma*. 2017;1:002.
54. Fraga NA, Paim Mde F, Follador I, Ramos AN, Rêgo VR. Refractory erythrodermic psoriasis in a child with an excellent outcome by using etanercept. *An Bras Dermatol*. 2011;86(4 suppl 1):S144–S147. doi:10.1590/S0365-05962011000700038
55. Poulalhon N, Begon E, Lebbe C, et al. A follow-up study in 28 patients treated with infliximab for severe recalcitrant psoriasis: evidence for efficacy and high incidence of biological autoimmunity. *Br J Dermatol*. 2007;156(2):329–336. doi:10.1111/j.1365-2133.2006.07639.x
56. Lisby S, Gniadecki R. Infliximab (Remicade) for acute, severe pustular and erythrodermic psoriasis. *Acta Derm Venereol*. 2004;84(3):247–248.
57. Heikkilä H, Ranki A, Cajanus S, Karvonen SL. Infliximab combined with methotrexate as long-term treatment for erythrodermic psoriasis. *Arch Dermatol*. 2005;141(12):1607–1610. doi:10.1001/archderm.141.12.1607
58. Mahé E, Descamps V, Grossin M, Fraitag S, Crickx B. CD30+ T-cell lymphoma in a patient with psoriasis treated with cyclosporin and infliximab. *Br J Dermatol*. 2003;149(1):170–173. doi:10.1046/j.1365-2133.2003.05384.x
59. Rongioletti F, Borenstein M, Kirsner R, Kerdel F. Erythrodermic, recalcitrant psoriasis: clinical resolution with infliximab. *J Dermatol Treat*. 2003;14(4):222–225. doi:10.1080/09546630310010895
60. Torii H, Nakagawa H, Japanese Infliximab Study Investigators. Long-term study of infliximab in Japanese patients with plaque psoriasis, psoriatic arthritis, pustular psoriasis and psoriatic erythroderma. *J Dermatol*. 2011;38(4):321–334. doi:10.1111/j.1346-8138.2010.00971.x
61. Lewis TG, Tuchinda C, Lim HW, Wong HK. Life-threatening pustular and erythrodermic psoriasis responding to infliximab. *J Drugs Dermatol*. 2006;5(6):546–548.
62. O'Quinn RP, Miller JL. The effectiveness of tumor necrosis factor alpha antibody (infliximab) in treating recalcitrant psoriasis: a report of 2 cases. *Arch Dermatol*. 2002;138(5):644–648. doi:10.1001/archderm.138.5.644
63. Fiehn C, Andrassy K. Case number 29: hitting three with one strike: rapid improvement of psoriatic arthritis, psoriatic erythroderma, and secondary renal amyloidosis by treatment with infliximab (Remicade). *Ann Rheum Dis*. 2004;63(3):232. doi:10.1136/ard.2003.014191
64. Yip L, Harrison S, Foley P. From biologic to biologic to biologic: lessons to learn for erythrodermic and recalcitrant chronic plaque psoriasis. *Australas J Dermatol*. 2008;49(3):152–155. doi:10.1111/j.1440-0960.2008.00463.x
65. Tridico LA, Antonio JR, Mathias CE, Pozzetti EMO. Effectiveness and safety of infliximab for 11 years in a patient with erythrodermic psoriasis and psoriatic arthritis. *An Bras Dermatol*. 2017;92(5):743–745. doi:10.1590/abd1806-4841.20176565
66. Valdés A, Mdel P, Schroeder HF, Roizen GV, Honeyman MJ, Sánchez ML. Efficacy of infliximab in patients with moderate and severe psoriasis treated with infliximab (Remicade). *Rev Med Chil*. 2006;134(3):326–331. doi:10.4067/s0034-988720060003000009
67. Kurokawa R, Hagiwara A, Nijima Y, Kojima K. Computed tomography imaging findings in erythrodermic psoriasis treated with infliximab: a case report. *Radiol Case Rep*. 2018;13(2):460–463. doi:10.1016/j.radcr.2018.02.005
68. Belinchon I, Lucas A, Ballester I, Betlloch I, Pérez-Crespo M. Successful treatment of life threatening erythrodermic psoriasis with infliximab. *J Am Acad Dermatol*. 2009;60(3):AB171.
69. Suárez Pedreira I, Santos Juanes J, Caminal Montero L, Trapiella L. Infliximab: an alternative in refractory erythrodermic psoriasis. *Piel*. 2006;21(6):317–318. doi:10.1016/S0213-9251(06)72498-4

70. Carrasquillo OY, Pabón-Cartagena G, Falto-Aizpurua LA, et al. Treatment of erythrodermic psoriasis with biologics: a systematic review. *J Am Acad Dermatol*. 2020;83(1):151–158. doi:10.1016/j.jaad.2020.03.073
71. Lee WK, Kim GW, Cho HH, et al. Erythrodermic psoriasis treated with golimumab: a case report. *Ann Dermatol*. 2015;27(4):446–449. doi:10.5021/ad.2015.27.4.446
72. Mumoli N, Vitale J, Gambaccini L, Sabatini S, Brondi B, Cei M. Erythrodermic psoriasis. *QJM*. 2014;107(4):315. doi:10.1093/qjmed/hct139
73. Richetta AG, Maiani E, Carlomagno V, et al. Treatment of erythrodermic psoriasis in HCV+patient with adalimumab. *Dermatol Ther*. 2009;22(Suppl 1):S16–18. doi:10.1111/j.1529-8019.2009.01266.x
74. Nowshheen S, Kohorst JJ, El-Azhary RA. Adalimumab-induced erythrodermic reactions. *Int J Dermatol*. 2019;58(10):e204–e206. doi:10.1111/ijd.14503
75. Pescitelli L, Dini V, Gisoni P, et al. Erythrodermic psoriasis treated with ustekinumab: an Italian multicenter retrospective analysis. *J Dermatol Sci*. 2015;78(2):149–151. doi:10.1016/j.jdermsci.2015.01.005
76. Santos-Juanes J, Coto-Segura P, Mas-Vidal A, Galache Osuna C. Ustekinumab induces rapid clearing of erythrodermic psoriasis after failure of antitumour necrosis factor therapies. *Br J Dermatol*. 2010;162(5):1144–1146. doi:10.1111/j.1365-2133.2010.09669.x
77. Wang TS, Tsai TF. Clinical experience of ustekinumab in the treatment of erythrodermic psoriasis: a case series. *J Dermatol*. 2011;38(11):1096–1099. doi:10.1111/j.1346-8138.2011.01224.x
78. Kim YS, Kim HJ, Lee S, Park YL. Erythrodermic psoriasis improved by ustekinumab: a report of two cases. *Ann Dermatol*. 2016;28(1):121–122. doi:10.5021/ad.2016.28.1.121
79. Koutsoukou XA, Papadavid E, Theodoropoulos K, Rigopoulos D. Ustekinumab in severe complicated erythrodermic psoriasis: rapid clearing, safety, and sustained remission. *Dermatol Ther*. 2014;27(5):257–259. doi:10.1111/dth.12131
80. Stinco G, Piccirillo A, Errichetti E, Bergamo S, Patrone P. Treatment of recalcitrant erythrodermic psoriasis with ustekinumab. *Eur J Dermatol*. 2014;24(3):387–390. doi:10.1684/ejd.2014.2325
81. Saraceno R, Talamonti M, Galluzzo M, Chiricozzi A, Costanzo A, Chimenti S. Ustekinumab treatment of erythrodermic psoriasis occurring after physical stress: a report of two cases. *Case Rep Dermatol*. 2013;5(3):254–259. doi:10.1159/000348645
82. Castineiras I, Fernandez-Diaz L, Juárez Y, Lueiro M. Sustained efficacy of ustekinumab in refractory erythrodermic psoriasis after failure of antitumor necrosis factor therapies. *J Dermatol*. 2012;39(8):730–731. doi:10.1111/j.1346-8138.2011.01499.x
83. Buggiani G, D'Erme AM, Krysenka A, Pescitelli L, Lotti T, Prignano F. Efficacy of ustekinumab in sub-erythrodermic psoriasis: when TNF-blockers fail. *Dermatol Ther*. 2012;25(3):283–285. doi:10.1111/j.1529-8019.2012.01465.x
84. Castiñeiras I, Fernández-Díaz L, Juárez Y, Lueiro M. Sustained efficacy of ustekinumab in refractory erythrodermic psoriasis after failure of antitumor necrosis factor therapies. *J Dermatol*. 2012;39(8):730–731.
85. Concha-Garzón MJ, Godoy-Traperó A, Daudén E, et al. Short- and long-term treatment of erythrodermic psoriasis with ustekinumab: a national and multicenter case series. *J Am Acad Dermatol*. 2014;70(5):AB189.
86. Errichetti E, Piccirillo A. Latent tuberculosis reactivation in a patient with erythrodermic psoriasis under treatment with ustekinumab and a low dose steroid, despite isoniazid chemoprophylaxis. *Eur J Dermatol*. 2014;24(4):508–509. doi:10.1684/ejd.2014.2386
87. Sano S, Kubo H, Morishima H, Goto R, Zheng R, Nakagawa H. Guselkumab, a human interleukin-23 monoclonal antibody in Japanese patients with generalized pustular psoriasis and erythrodermic psoriasis: efficacy and safety analyses of a 52-week, phase 3, multicenter, open-label study. *J Dermatol*. 2018;45(5):529–539. doi:10.1111/1346-8138.14294
88. Megna M, Ruggiero A, Camela E, Fabbrocini G, Marasca C. A case of erythrodermic psoriasis successfully treated with guselkumab. *Dermatol Ther*. 2020;33(2):e13238.
89. Chiang CY, Tsai TF. Treatment Response of Patients with Erythrodermic Psoriasis after Switching to Guselkumab. *Dermatol Ther (Heidelb)*. 2021;11(1):301–306. doi:10.1007/s13555-020-00480-x
90. Sleiman AA, Khatri A, Oberoi RK, Othman AA. Exposure-Response Relationships for the Efficacy and Safety of Risankizumab in Japanese Subjects with Psoriasis. *Clin Pharmacokinet*. 2020;59(5):575–589. doi:10.1007/s40262-019-00829-2
91. Weng HJ, Wang TS, Tsai TF. Clinical experience of secukinumab in the treatment of erythrodermic psoriasis: a case series. *Br J Dermatol*. 2018;178(6):1439–1440. doi:10.1111/bjd.16252
92. Mugheddu C, Atzori L, Lappi A, Pau M, Murgia S, Rongioletti F. Successful Secukinumab treatment of generalized pustular psoriasis and erythrodermic psoriasis. *J Eur Acad Dermatol Venereol*. 2017;31(9):e420–e421.
93. Mateu-Puchades A, Santos-Alarcón S, Martorell-Calatayud A, Pujol-Marco C, Sánchez-Carazo JL. Erythrodermic psoriasis and secukinumab: our clinical experience. *Dermatol Ther*. 2018;31(4):e12607. doi:10.1111/dth.12607
94. Galluzzo M, D'Adamo S, Campione E, Mazzilli S, Bianchi L, Talamonti M. A clinical case of severe disease burden: an erythrodermic psoriatic patient treated with secukinumab. *J Dermatolog Treat*. 2018;29(sup1):1–11. doi:10.1080/09546634.2018.1524818
95. Rongioletti F, Mugheddu C, Murgia S. Repigmentation and new growth of hairs after anti-interleukin-17 therapy with secukinumab for psoriasis. *JAAD Case Rep*. 2018;4(5):486–488. doi:10.1016/j.jcdr.2018.01.006
96. Dogra S, Bishnoi A, Narang T, Handa S. Long-term remission induced by secukinumab in a 13-year-old boy having recalcitrant chronic erythrodermic psoriasis. *Dermatol Ther*. 2018;31(4):e12611. doi:10.1111/dth.12611
97. Tichy M. Arthropathic psoriasis complicated by a paradoxical reaction in the form of erythrodermic psoriasis following adalimumab and by an allergic reaction following infliximab which was successfully managed with secukinumab. *Postepy Dermatol Alergol*. 2019;36(4):495–497. doi:10.5114/ada.2019.87454
98. Damiani G, Pacifico A, Russo F, et al. Use of secukinumab in a cohort of erythrodermic psoriatic patients: a pilot study. *J Clin Med*. 2019;8(6):770. doi:10.3390/jcm8060770
99. Shibata T, Muto J, Takama H, Yanagishita T, Ito T, Watanabe D. Case of psoriatic erythroderma induced by the discontinuation of the chronic use of topical steroid after dialysis initiation and successfully treated with secukinumab. *J Dermatol*. 2019;46(4):e119–20. doi:10.1111/1346-8138.14649
100. Pizzatti L, Mugheddu C, Sanna S, Atzori L, Rongioletti F. Erythrodermic psoriasis in a dialyzed patient successfully treated with Secukinumab. *Dermatol Ther*. 2020;33(3):e13348. doi:10.1111/dth.13348
101. Liu LC, Jin XH, Sun C, Xia JX. Two cases of refractory erythrodermic psoriasis effectively treated with secukinumab and a review of the literature. *Dermatol Ther*. 2021;34:e14825. doi:10.1111/dth.14825
102. Japanese Ixekizumab Study Group, Saeki H, Nakagawa H, Nakajo K, et al. Efficacy and safety of ixekizumab treatment for Japanese patients with moderate to severe plaque psoriasis, erythrodermic psoriasis and generalized pustular psoriasis: results from a 52-week, open-label, phase 3 study (UNCOVER-J). *J Dermatol*. 2017;44(4):355–362. doi:10.1111/1346-8138.13622

103. Okubo Y, Mabuchi T, Iwatsuki K, et al. Long-term efficacy and safety of ixekizumab in Japanese patients with erythrodermic or generalized pustular psoriasis: subgroup analyses of an open-label, phase 3 study (UNCOVER-J). *J Eur Acad Dermatol Venereol*. 2019;33(2):325–332. doi:10.1111/jdv.15287
104. Megna M, Gallo L, Balato N, Balato A. A case of erythrodermic psoriasis successfully treated with ixekizumab. *Dermatol Ther*. 2019;32(2):e12825. doi:10.1111/dth.12825
105. Trovato E, Orsini C, Russo F, Cortonesi G, Rubegni P. Ixekizumab as treatment of erythrodermic psoriasis. *Dermatol Ther*. 2021;34:e14868. doi:10.1111/dth.14868
106. Pangilinan MCG, Sermswan P, Asawanonda P. Use of Anti-IL-17 Monoclonal Antibodies in HIV Patients with Erythrodermic Psoriasis. *Case Rep Dermatol*. 2020;12(2):132–137. doi:10.1159/000508781
107. Lo Y, Tsai TF. Clinical experience of ixekizumab in the treatment of patients with history of chronic erythrodermic psoriasis who failed secukinumab: a case series. *Br J Dermatol*. 2019;181(5):1106–1107. doi:10.1111/bjd.18174
108. Lo Y, Huang YH, Tsai TF. Long-term effectiveness and safety of ixekizumab in the treatment of 14 patients with history of chronic erythrodermic psoriasis who failed prior secukinumab: a bicentric retrospective study. *Dermatol Sinica*. 2021.
109. Yamasaki K, Nakagawa H, Kubo Y, Ootaki K. Efficacy and safety of brodalumab in patients with generalized pustular psoriasis and psoriatic erythroderma: results from a 52-week, open-label study. *Br J Dermatol*. 2017;176(3):741–751. doi:10.1111/bjd.14702
110. Bernardini N, Skroza N, Tolino E, et al. Recurrent erythrodermic psoriasis and polycythemia successfully treated with brodalumab. *Dermatol Ther*. 2020;33(6):e14338. doi:10.1111/dth.14338
111. Megna M, Fabbrocini G, Ferrillo M, Cinelli E. Erythrodermic psoriasis successfully and rapidly treated with brodalumab: report of two cases. *Dermatol Ther*. 2020;33(6):e14351. doi:10.1111/dth.14351
112. Papadavid E, Kokkalis G, Polyderas G, Theodoropoulos K, Rigopoulos D. Rapid clearance of erythrodermic psoriasis with apremilast. *J Dermatol Case Rep*. 2017;11(2):29–31. doi:10.3315/jdcr.2017.1246
113. Krishnamoorthy G, Kotecha A, Pimentel J. Complete resolution of erythrodermic psoriasis with first-line apremilast monotherapy. *BMJ Case Rep*. 2019;12(1):e226959. doi:10.1136/bcr-2018-226959
114. Arcilla J, Joe D, Kim J, Kim Y, Truong VN, Jaipaul N. Erythrodermic psoriasis treated with apremilast. *Dermatol Rep*. 2016;8(1):6599. doi:10.4081/dr.2016.6599
115. Mugheddu C, Pizzatti L, Sanna S, Atzori L, Rongioletti F. COVID-19 pulmonary infection in erythrodermic psoriatic patient with oligodendroglioma: safety and compatibility of apremilast with critical intensive care management. *J Eur Acad Dermatol Venereol*. 2020;34(8):e376–e378. doi:10.1111/jdv.16625
116. Megna M, Fabbrocini G, Camela E, Cinelli E. Apremilast efficacy and safety in elderly psoriasis patients over a 48-week period. *J Eur Acad Dermatol Venereol*. 2020;34(11):e705–e707. doi:10.1111/jdv.16443
117. Beltran Monasterio EP. Low-dose Naltrexone: an Alternative Treatment for Erythrodermic Psoriasis. *Cureus*. 2019;11(1):e3943. doi:10.7759/cureus.3943
118. Nishizawa A, Satoh T, Yokozeki H. Erythrodermic psoriasis improved by panitumumab, but not bevacizumab. *Acta Derm Venereol*. 2012;92(4):360–361. doi:10.2340/00015555-1348
119. Kharaeva Z, Gostova E, De Luca C, Raskovic D, Korkina L. Clinical and biochemical effects of coenzyme Q10, vitamin E, and selenium supplementation to psoriasis patients. *Nutrition*. 2009;25(3):295–302. doi:10.1016/j.nut.2008.08.015
120. Gregoire ARF, DeRuyter BK, Stratman EJ. Psoriasis Flares Following Systemic Glucocorticoid Exposure in Patients With a History of Psoriasis. *JAMA Dermatol*. 2021;157(2):198–201. doi:10.1001/jamadermatol.2020.4219
121. Mrowietz U, Domm S. Systemic steroids in the treatment of psoriasis: what is fact, what is fiction? *J Eur Acad Dermatol Venereol*. 2013;27(8):1022–1025. doi:10.1111/j.1468-3083.2012.04656.x
122. Cretu S, Salavastru CM, Tiplica GS. Treatment of psoriatic erythroderma using systemic corticosteroids: a timeless option? *Dermatol Ther*. 2020;33(6):e14222. doi:10.1111/dth.14222
123. Pang ML, Murase JE, Koo J. An updated review of acitretin—a systemic retinoid for the treatment of psoriasis. *Expert Opin Drug Metab Toxicol*. 2008;4(7):953–964. doi:10.1517/17425255.4.7.953
124. van der Vleuten CJ, Gerritsen MJ, Steijlen PM, de Jong EM. A therapeutic approach to erythrodermic psoriasis: report of a case and a discussion of therapeutic options. *Acta Derm Venereol*. 1996;76(1):65–67. doi:10.2340/00015555766567
125. Reynolds KA, Pithadia DJ, Lee EB, Liao W, Wu JJ. A systematic review of treatment strategies for erythrodermic psoriasis. *J Dermatolog Treat*. 2021;32(1):49–55. doi:10.1080/09546634.2019.1689228
126. Shao S, Wang G, Maverakis E, Gudjonsson JE. Targeted Treatment for Erythrodermic Psoriasis: rationale and Recent Advances. *Drugs*. 2020;80(6):525–534. doi:10.1007/s40265-020-01283-2
127. Hsu SH, Tsai TF. Evolution of the inclusion/exclusion criteria and primary endpoints in pivotal trials of biologics and small oral molecules for the treatment of psoriasis. *Expert Rev Clin Pharmacol*. 2020;13(3):211–232. doi:10.1080/17512433.2020.1743175
128. Li X, Andersen KM, Chang HY, Curtis JR, Alexander GC. Comparative risk of serious infections among real-world users of biologics for psoriasis or psoriatic arthritis. *Ann Rheum Dis*. 2020;79(2):285–291. doi:10.1136/annrheumdis-2019-216102
129. Ger TY, Huang YH, Hui RC, Tsai TF, Chiu HY. Effectiveness and safety of secukinumab for psoriasis in real-world practice: analysis of subgroups stratified by prior biologic failure or reimbursement. *Ther Adv Chronic Dis*. 2019;10:2040622319843756. doi:10.1177/2040622319843756
130. Tsai YC, Tsai TF. Switching biologics in psoriasis - practical guidance and evidence to support. *Expert Rev Clin Pharmacol*. 2020;13(5):493–503. doi:10.1080/17512433.2020.1767590
131. Huang YW, Tsai TF. Efficacy of tofacitinib in patients with moderate-to-severe psoriasis who had inadequate responses to prior biologics. *Dermatol Sinica*. 2019;37(4):205–208.

Psoriasis: Targets and Therapy

Publish your work in this journal

Psoriasis: Targets and Therapy is international, peer-reviewed, open access journal focusing on psoriasis, nail psoriasis, psoriatic arthritis and related conditions, identification of therapeutic targets and the

Submit your manuscript here: <http://www.dovepress.com/psoriasis-targets-and-therapy-journal>

optimal use of integrated treatment interventions to achieve improved outcomes and quality of life. Visit <http://www.dovepress.com/testimonials.php> to read real quotes from published authors.

Dovepress