

# [<sup>18</sup>F]Fluoro-2-Deoxy-D-Glucose Positron Emission Tomography/Computed Tomography Imaging in Oncology: Initial Staging and Evaluation of Cancer Therapy

Ernest K.J. Pauwels<sup>a, b</sup> Annette W. Coumou<sup>c</sup> Magdalena Kostkiewicz<sup>d</sup>  
Kalevi Kairemo<sup>e</sup>

<sup>a</sup>University Medical School Pisa, Pisa, Italy; <sup>b</sup>Leiden University Medical Center, Leiden, and

<sup>c</sup>Amsterdam University Medical Center, Amsterdam, The Netherlands; <sup>d</sup>Jagiellonian University, Cracow, Poland;

<sup>e</sup>International Comprehensive Cancer Center Docrates, Helsinki, Finland

## Key Words

[<sup>18</sup>F]fluoro-2-deoxy-D-glucose-positron emission tomography/computed tomography · Cancer staging · Interim scanning · Posttreatment evaluation

## Abstract

Positron emission tomography (PET) with [<sup>18</sup>F]fluoro-2-deoxy-D-glucose (FDG) has proven to be a valuable diagnostic modality in various diseases. Its accuracy has been improved with the hybrid PET/computed tomography (CT) technique because of precise anatomic location of areas of abnormal FDG accumulation. This integrated PET/CT modality has been widely adopted, particularly in oncology. This paper reviews the role of FDG-PET/CT imaging in breast cancer, non-small-cell lung cancer, colorectal cancer, head and neck cancer as well as lymphoma on the basis of recent key articles. Special attention is paid to preoperative diagnostic workup, evaluation of treatment response and survival prognosis. Experience from specialized centers indicates that there is strong evidence for the clinical effectiveness of FDG-PET/CT in staging, restaging and the prediction of response to therapy in the above-mentioned malignancies. It is con-

cluded that this imaging modality contributes considerably to improved patient management and paves the way to personalize cancer treatment in a cost-effective way.

Copyright © 2013 S. Karger AG, Basel

## Introduction

Positron emission tomography (PET) has become an important component of cancer imaging and an integral part of the management of cancer patients. The widespread availability of the primary PET agent [<sup>18</sup>F]fluoro-2-deoxy-D-glucose (FDG) has allowed a variety of applications in cancer medicine and has awakened public awareness of this valuable imaging technique. After intravenous application, FDG is transported into cells as an analog of glucose. However, after the first rate-limiting step of phosphorylation by hexokinase, FDG-6-phosphate is not further metabolized. Due to its negative charge, it remains trapped within cells and its accumulation is proportional to the cellular glycolytic rate. Thus, FDG accumulation in tissue reflects cellular glucose transport and hexokinase activity. Subsequently, the

phosphorylated  $^{18}\text{F}$ -labeled metabolite can be detected by PET,  $^{18}\text{F}$  being a positron-emitting radionuclide. Typically, physiologically increased FDG uptake is noted in the urinary tract, the intestinal tract, muscles, brain, and the heart. Especially, the intestinal activity may show unpredictable patterns, which can be confounding.

Well-documented observations demonstrate that malignant cells have an increase in membrane glucose transporter proteins (notably GLUT1 and GLUT3) and enzymes along the glycolytic pathway. These biochemical characteristics give rise to preferential FDG accumulation in cancer cells relative to normal cells. However, blood glucose competes with FDG after administration. Therefore, patient preparation is essential and fasting overnight helps to increase the FDG accumulation in abnormal tissues if imaging is performed the next morning. In case the examination takes place in the afternoon, a light breakfast and no lunch is advised. In general, a serum glucose level of less than 150 mg/dl at the time of FDG administration is preferred. At higher glucose levels, extensive liver and muscle uptake may take place, possibly obscuring osseous pathology and centrally located lymph node pathology. With regard to diabetic patients, the physician who treats the patient for diabetes should be consulted. Obviously, the amount of FDG accumulated in the tumor cell is also dependent on various parameters including the weight of the patient, the injected dose, and the interval between injection and PET scanning.

A wealth of clinical literature over the past decades has shown the efficacy of FDG-PET in a variety of tumors as recently reviewed by Czernin et al. [1]. Due to its increased spatial resolution, there is no doubt that the introduction of hybrid PET/computed tomography (CT) has added to the clear visualization of areas of increased FDG accumulation versus normal tissues. FDG-PET/CT offers the possibility to determine both the presence and the precise anatomic location of abnormal FDG uptake, although lesion characterization may depend on the application of contrast agent. Currently, this hybrid imaging technology has been widely adopted, particularly in oncology, a field in which its prominent role is reflected in the identification of neoplasms, the staging of disease, the monitoring of cancer therapy and the detection of recurrent disease [1].

This paper concentrates on the topics of staging and evaluation of the response to cancer therapy using FDG-PET/CT. A review across all cancers would be beyond the scope of this paper and, therefore, this review shall be limited to recent information, putting key peer-reviewed articles mostly dating from January 2006 to July 2012 into

the clinical context of common malignancies, including breast cancer, non-small-cell lung cancer, head and neck cancer, colorectal cancer and lymphoma. First, however, some methods of assessing FDG accumulation as obtained by PET imaging are considered.

## Methods to Evaluate FDG Uptake

Techniques of evaluation include visual assessment ('eyeballing'), semi-quantitative, and quantitative methods. The latter comprises mature kinetic analysis as non-linear regression and Patlak graphical analysis [2]. Both quantitative methods are too cumbersome and time-consuming for routine clinical use and will not be discussed in this paper.

### *Visual Assessment*

This is the most commonly used method and is based on the subjective observation of the contrast between the activity accumulation in the tumor and the adjacent tissues. It is most useful when the FDG accumulation in the tumor is reduced to zero or virtually zero, which is commonly interpreted as successful treatment. In other cases, however, the often subtle changes cannot be noted visually and the assessment of FDG tumor metabolism with PET needs the objective approaches briefly elucidated below.

### *Tumor-to-Normal Tissue Ratio*

The tumor-to-normal tissue ratio is similar to the visual assessment mentioned above. This semi-quantitative technique uses the ratio between tumor activity and activity in normal tissue(s). This ratio is fairly independent of the weight of the patient, the injected dose and blood glucose level. However, it may be difficult to select an appropriate reference site to measure the activity in normal tissue. Abdominal activity especially may show considerable variations over time. In follow-up studies, this reference site must be documented precisely in order to allow adequate therapy monitoring.

### *Standardized Uptake Value*

This quantitative measure is defined as the tissue uptake (usually from the pixel that demonstrates the highest lesion activity) divided by the injected dose normalized for the patient's body weight or body surface at a fixed time after tracer injection. As to the latter parameter, early imaging provides low standardized uptake values (SUVs) and, conversely, late imaging provides high SUVs.

This and other variables have been the subject of ample discussion [3]. Despite efforts to 'standardize' SUV measurements, interoperator variations are unavoidable and render general clinical use, easy interinstitutional data collection and comparison difficult.

In the late 1970s, the World Health Organization introduced tumor response criteria based on bidimensional measurement (summarized by Miller et al. [4]), which were replaced by a one-dimensional model by the name Response Evaluation Criteria for Solid Tumors (RESIST, versions 1.0 and 1.1; summarized by Eisenhauer et al. [5]). In addition to these guidelines, the European Organization for Research and Treatment of Cancer (EORTC) published recommendations for the assessment of tumor response using FDG scanning [6]. A decade after the publication of the EORTC recommendations, Wahl et al. [7] introduced PET Response Criteria in Solid Tumors (PERCIST). It is beyond the scope of this paper to go deeply into both the EORTC and the PERCIST criteria, but some details may be useful at this point. Both criteria use the complete resolution of FDG accumulation as an indication of complete metabolic response. Partial metabolic response is characterized by more than 25% and more than 30% reduction of FDG uptake in the EORTC and the PERCIST recommendations, respectively. According to the EORTC criteria, stable metabolic disease shows an increase in FDG uptake of less than 25% or a decrease of less than 15%, whereas an increase of more than 25 or 30% is attributed to progressive metabolic disease according to EORTC and PERCIST, respectively. According to PERCIST, the percent increase or decrease of FDG uptake beyond these numbers is attributed to stable metabolic disease.

### **Clinical FDG-PET/CT for Initial Staging and Response to Therapy**

The assessment of therapeutic efficacy with FDG-PET/CT can be clinically useful in a number of ways. First, FDG-PET/CT may be used as a tool for initial staging of newly diagnosed patients. For many types of neoplasms, correct initial staging is crucial in distinguishing operable from inoperable patients. Second, it may be helpful in identifying ineffective therapy at an early stage after the start of treatment (that is, between chemotherapy cycles, often called 'interim scanning'). This is important, as a negative response may be a reason to switch to another therapy. This way, the patient is no longer exposed to ineffective treatment. Thus, early recognition

may reduce morbidity and treatment costs. Third, the comparison between pre- and posttreatment scans provides an appropriate metabolic indicator of the final result of the treatment. The above-mentioned information is of significant clinical value, as changes in metabolic activity generally occur earlier than changes in tumor size, which is often used as a standard for the assessment of response [8]. Needless to say, the measurement in treatment response is important for drug development and drug approval as well as for clinical research.

#### *Breast Cancer*

The evaluation of breast masses is primarily performed by mammography because of its good performance and cost-effectiveness. Regarding the initial staging, FDG-PET/CT is significantly more accurate for detecting pathological axillary lymph nodes and distant metastases than conventional imaging, including plain chest radiography, bone scintigraphy and axillary and liver ultrasound together ( $p < 0.01$ ), as suggested by a retrospective study by Riegger et al. [9]. In this context, a recent article by Koolen et al. [10] advocates FDG-PET/CT in patients scheduled for neoadjuvant therapy in order to detect FDG-avid axillary lymph nodes. In these patients, FDG uptake renders sentinel lymph node biopsy unnecessary and enables axillary response monitoring during and after neoadjuvant chemotherapy.

Therapy response assessment in breast cancer patients is clinically relevant in cases with large and locally advanced tumors undergoing primary systemic therapy. A recent study on this issue comprising 104 patients was performed by Schwarz-Dose et al. [11]. The relative changes in SUV of FDG uptake were assessed to investigate its predictive value with respect to histopathological response. A threshold of 45% reduction in SUV identified 11 of 15 responders and the histopathological nonresponders were identified with a negative predictive value of 90% in the first cycle of chemotherapy. This information is of great importance for the stratification of individual treatment. Similar results have recently been published in studies by Martoni et al. [12] and Keam et al. [13] in patients undergoing neoadjuvant chemotherapy. A more recent study by Haug et al. [14] reported on 58 consecutive patients with hepatic metastases from breast cancer treated with Y-90 radioembolization. FDG-PET/CT was performed at baseline and at 3 months after selective internal radiation therapy. Changes in SUV of more than 30% reduction indicated therapy response on the basis of the Response Evaluation Criteria in Solid Tumors (RECIST). Follow-up studies in these patients demon-

strated that FDG-PET/CT was the only independent predictor of survival in these patients.

Taken together, recent studies indicate that FDG-PET/CT may help to individualize treatment in postsurgical patients. In presurgical patients FDG-PET/CT is useful in patients suspected of having local or distant tumor involvement.

#### *Non-Small-Cell Lung Cancer*

Various recent studies have demonstrated that FDG-PET/CT performs with superior accuracy in the preoperative staging of newly diagnosed patients with non-small-cell lung cancer. For instance, a randomized multicenter study reported on by Maziak et al. [15] provided evidence that preoperative staging with FDG-PET/CT identified more patients with mediastinal and extrathoracic disease than conventional staging. Disease was correctly upstaged in 23 of 167 PET/CT recipients and in 11 of 162 conventional staging recipients, thereby sparing those patients from surgery. Similar results have been achieved by Fisher et al. [16]. With regard to intrathoracic nodal staging, FDG-PET/CT appears to provide high specificity (around 90%), but low sensitivity (around 45%) [17]. As to mediastinal lymph node involvement, Perigaud et al. [18] regarded the positive predicted value of FDG-PET/CT high enough to skip invasive mediastinal lymph node staging in case of a negative study. However, due to the low negative predictive value, their prospective study in 51 patients suggests that FDG-avid lymph nodes need further characterization by invasive mediastinal staging.

As for the prediction of therapy response, a recent study in patients undergoing epidermal growth factor receptor inhibition therapy with the neoadjuvant erlotinib shows that FDG-PET/CT predicts histopathological response [19]. This investigation showed that in 70% of the metabolic responders tumor necrosis had occurred, whereas necrosis was observed in only 40% of the nonresponders at 1 week after therapy. Benz et al. [20] reported that 2 weeks after the start of the neoadjuvant erlotinib treatment, FDG-PET/CT allowed the prediction of response. By monitoring the treatment over this short period, these authors were able to show that progressive FDG uptake correlates well with shorter time to disease progression ( $p < 0.001$ ) and overall survival ( $p < 0.01$ ) vis-à-vis patients with stable or diminishing FDG uptake (47 vs. 119 days and 87 vs. 828 days, respectively). Similar outcomes in patients receiving this drug have been revealed by Mileschkin et al. [21], Kahraman et al. [22] and Zander et al. [23].

Taken together, recent FDG uptake studies show that preoperative staging is useful to select patients for invasive surgery. However, a negative thoracic FDG scan needs further confirmation. Furthermore, early treatment response predicts progression-free survival and overall survival in non-small-cell lung cancer patients. These findings help to select patients for expensive epidermal growth factor receptor therapy and prevent associated morbidity in patients in whom this therapy is likely to be less successful.

#### *Colorectal Cancer*

FDG-PET/CT does not add to the primary diagnosis and initial staging by colonoscopy and CT of colorectal cancer. However, Rosenberg et al. [24] demonstrated that FDG imaging is valuable for the prediction of histopathologic response as a result of neoadjuvant radiochemotherapy. These investigators found that in 30 patients with advanced rectal cancer, the positive predictive value for early (day 14) FDG response was 82 and 83% after completion of therapy. Similar results on FDG-PET/CT rectal cancer have been reported by others [25, 26]. Likewise, in a most recent prospective study, Janssen et al. [27] applied SUV reduction to differentiate responders from nonresponders in 51 rectal cancer patients. A cutoff value of 48% resulted in a specificity of 100% and a sensitivity of 64% regarding the correlation between metabolic and pathologic treatment response ( $n = 30$ ). Interestingly, a validation of this model was applied in the remaining 21 patients of this study group and a specificity and sensitivity of respectively 93 and 83% was found. These encouraging outcomes were obtained applying FDG-PET/CT before the start of chemotherapy and after 2 weeks of treatment.

Regarding the detection of local recurrence of rectal cancer, Bellomi et al. [28] reported that FDG-PET/CT revealed lesions with 100% sensitivity and 98% specificity based on histologic sampling and/or 2 years of follow-up in a retrospective study comprising 67 patients. Another retrospective study by Metser et al. [29] comprising 50 colorectal cancer patients showed that FDG-PET/CT had a higher sensitivity (98.1%) than contrast-enhanced CT (66.7%) on a tumor-site-based analysis. Moreover, it was found that in patients with an elevated carcinoembryonic antigen level, the identification of sites of recurrent or metastatic disease in chest and abdomen FDG-PET/CT appeared to be the imaging method of choice.

Taken together, prospective studies with FDG-PET/CT demonstrate that early monitoring of treatment response is a reliable imaging tool in patients with local rec-

tal cancer. Studies applying retrospective analysis suggest that this modality can detect local recurrence and distant metastases. For this application, however, the best time interval between the start of therapy and scanning as well as response criteria still need to be established in prospective studies.

#### *Hodgkin's and Non-Hodgkin's Lymphoma*

FDG-PET/CT is not the primary method for the initial diagnosis of lymphoma, but may locate the easiest node to resect to obtain a specimen by biopsy. Once the diagnosis has been established, FDG imaging plays a vital part in the staging procedure. Pelosi et al. [30] mention the correct staging of 61 cases in consecutive 65 patients and advocate the routine use of FDG-PET/CT in the initial evaluation of both Hodgkin's (HL) and non-Hodgkin's lymphoma (NHL). A previous study by Munker et al. [31] comprising 73 patients with newly diagnosed HL had obtained similar results by comparing FDG imaging with conventional methods. They observed that patients with early-stage disease as identified by conventional imaging have a significant risk of treatment failure. Indeed, in their most recent review, Shelly et al. [32] mention that FDG-PET/CT in aggressive NHL is more accurate for staging than both FDG-PET and CT alone. On the basis of previous research, they conclude that FDG-PET/CT has an impact on disease stage in 15–20% of patients with an influence on clinical management in 5–15%.

Apart from staging, the most valuable contribution of FDG-PET/CT in lymphoma is the use of early monitoring of treatment response. The differentiation between viable tumor tissue and fibrosis is a problem in lymphoma management that cannot be solved by morphological CT imaging alone. Gallium-67 has been used as a metabolic marker, but its low-resolution images have been replaced by high-resolution and site-specific FDG-PET/CT. Important outcomes of recent studies in HL and NHL are discussed below.

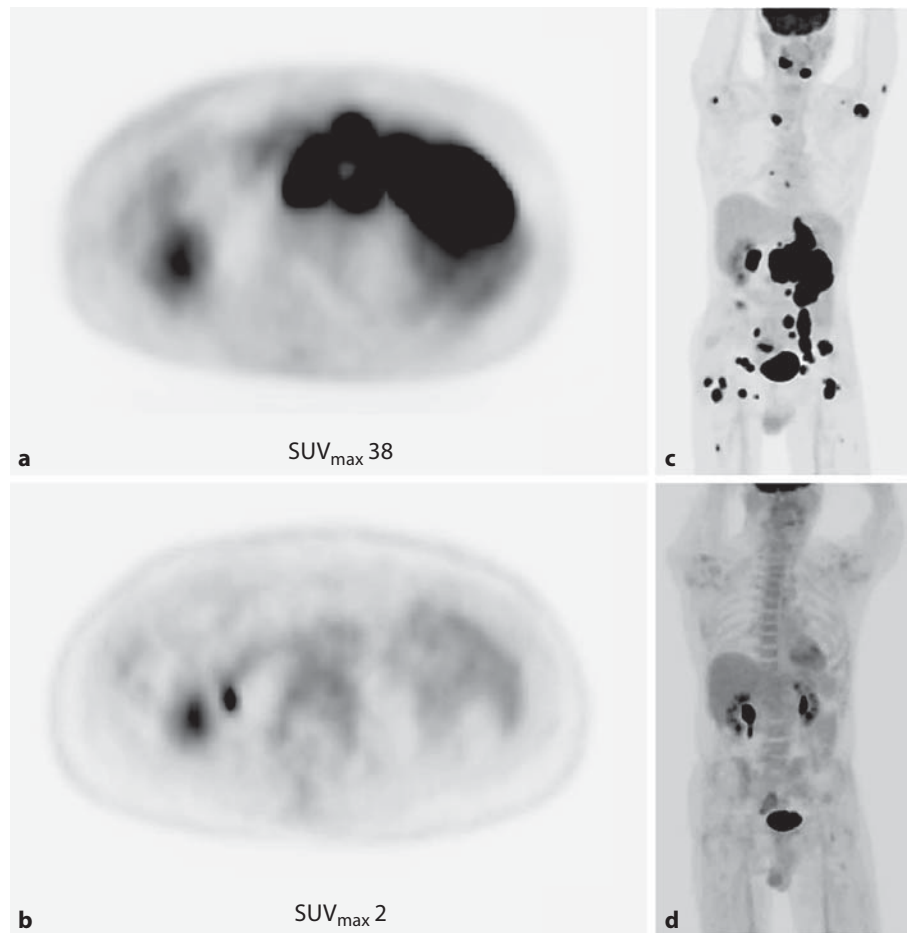
In HL patients, FDG-PET/CT results after 2 cycles of ABVD chemotherapy have been published by Cerci et al. [33] in a study comprising 104 patients. Their prognostic analysis at 3 years revealed an event-free survival of 53.2% of FDG-positive patients and 90.5% of FDG-negative patients. Avigdor et al. [34] investigated the potential benefit of FDG-PET/CT scanning as a guide to continuing therapy. These researchers followed 45 newly diagnosed advanced-stage HL patients who were treated with 2 cycles of escalated BEACOPP chemotherapy, followed by 4 cycles of ABVD. Imaging took place after the first 2 cycles.

They demonstrated that 4-year progression-free survival for FDG-negative patients ( $n = 31$ ) was 87%, whereas this number was 53% ( $n = 13$ ) in FDG-positive patients ( $p = 0.01$ ). A retrospective multicenter study, reported by Galamini et al. [35], analyzed data from 219 newly diagnosed HL patients. FDG imaging took place after 2 cycles of chemotherapy. The 2-year failure-free survival was 62% for FDG-positive patients and 95% for FDG-negative patients. Based on its prognostic value, these outcomes suggest that early FDG-PET/CT imaging may guide more individualized, risk-adapted therapeutic strategies [36].

With regard to NHL, the literature published so far evidences lower negative predictive values, likely due to the more aggressive nature of this disease compared to HL. Zhao et al. [37] made mention of the value of interim FDG-PET/CT imaging in a group of 61 consecutive NHL patients. Imaging took place prior to chemotherapy and after 3 cycles. The 2-year progression-free survival for FDG-negative patients was 72.2% and it was 23% for FDG-positive patients ( $p < 0.001$ ). Zinzani et al. [38] retrospectively analyzed the value of FDG imaging in 91 newly diagnosed patients with B-cell lymphoma. A midtreatment evaluation was compared with the results at the end of the chemoimmunotherapy regimen. A positive interim scan ( $n = 35$ ) resulted in a continuous complete response in only 6 (17%) patients, whereas 50 FDG-negative patients (89%) achieved a continuous complete response (event-free survival,  $p = 0.0001$ ; overall survival,  $p = 0.0001$ ).

The predictive role of FDG-PET/CT in the evaluation of therapeutic response in patients with autologous stem cell transplantation has been investigated by Qiao et al. [39]. In a study comprising 31 patients, FDG studies were performed prior to and after transplantation. Their findings show that progression-free survival at 1 year was strongly correlated with negative FDG findings prior to and after therapy ( $p < 0.0005$ ). As for pretherapy findings, the 1-year survival for FDG-negative patients and for FDG-positive patients was respectively 88.2 and 28.6%. For posttherapy findings, these numbers were found to be 88.9 and 23.1%, respectively.

The above-mentioned survey of recent reports on the widely utilized FDG-PET/CT imaging modality in lymphoma confirms earlier findings, which are reviewed by Juweid [40] and Zanoni et al. [41]. In particular, response assessment by imaging at a pretherapy stage (fig. 1), at certain intervals during therapy, and at completion of therapy appears to be an indispensable tool to evaluate the therapeutic regimen. A very important prognostic factor appears to be the interim FDG scan, which may be



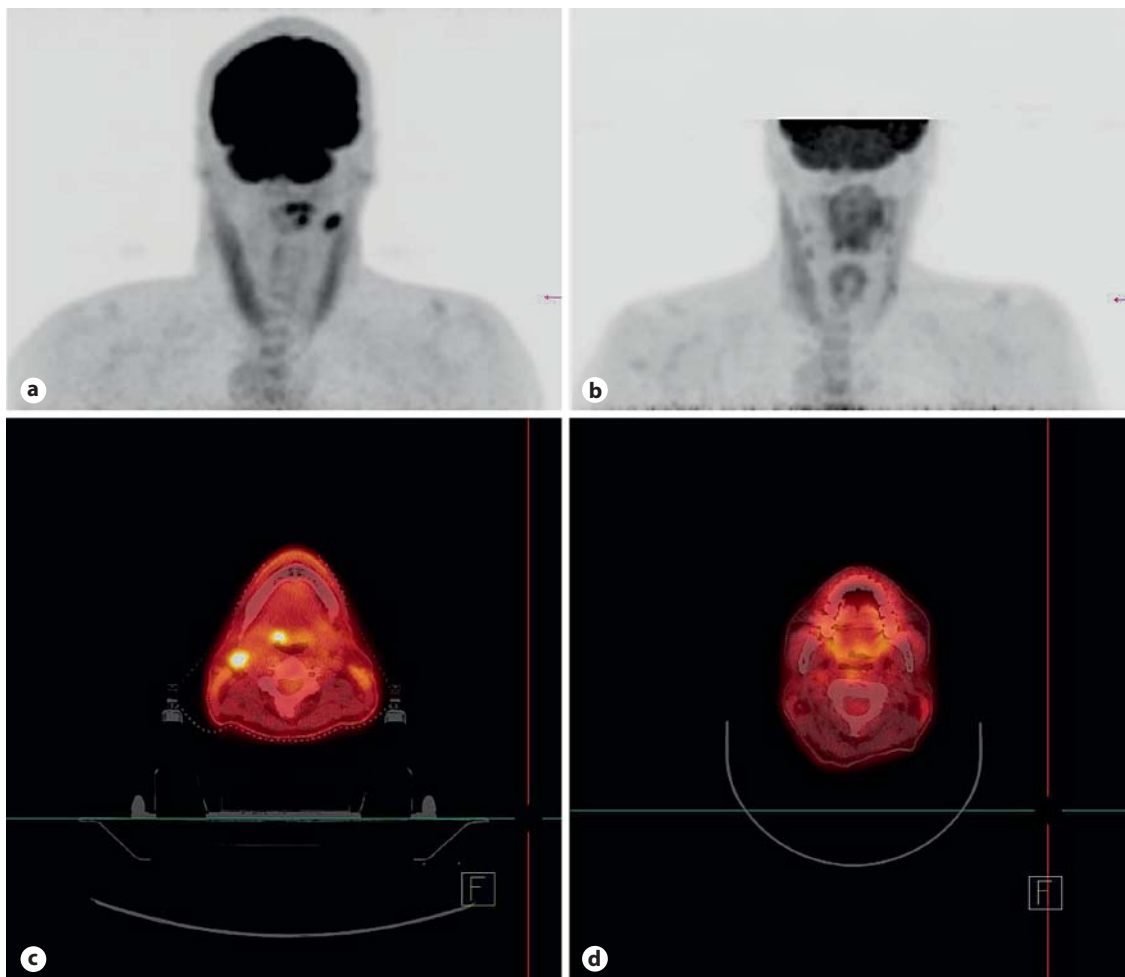
**Fig. 1.** FDG-PET/CT study in a 60-year-old male suffering from large B-cell lymphoma before and after 6 cycles of R-CHOP, and 2 cycles of HD-MTX. Complete metabolic response was observed 3 months after chemotherapy. The largest abdominal tumor burden ( $SUV_{max}$ : 38) shown transaxially (**a**) disappeared completely ( $SUV_{max}$ : 2) as shown in **b**. The whole-body images demonstrate an extensive intense disease (**c**), which disappears totally in all regions (**d**).

of considerable help in the clinical decision to continue with the same therapy or to change the therapy. These favorable characteristics have contributed to the fact that malignant lymphoma is the first disease for which FDG-PET and FDG-PET/CT was adopted as a tool for response assessment in the international standard criteria for the treatment of this disease [42].

#### *Head and Neck Cancer*

The preoperative staging of head and neck cancer (squamous cell carcinoma) includes physical examination and diagnostic imaging workup with CT and MRI. These techniques detect gross morphological invasions, but small tumors are far better detected with FDG-PET/CT. It is important to note that necrotic lesions hardly or do not accumulate FDG and diagnostic contrast-enhanced CT is necessary for correct staging [43] and that N0 necks cannot be confirmed by FDG-PET/CT and rely on physical/surgical examination [44]. The clinical im-

pact of FDG scanning has been described in a prospective investigation by Connell et al. [45], who performed 100 FDG-PET/CT studies in 76 patients. These studies altered the TNM classification in 12/35 patients and led to a change in radiotherapy planning technique and/or dose in 10/35 patients. Roh et al. [46] mentioned that both FDG-PET and FDG-PET/CT showed about 10% higher accuracy than CT/MRI for detection of primary tumors and cervical metastases (about 98 vs. 87%, respectively). A most recent retrospective study by Prestwich et al. [47] on 55 patients who underwent FDG-PET/CT prior to chemoradiotherapy showed that FDG scanning altered the TNM stage in 17/55 of patients, upstaging disease in 11 cases and downstaging in 6 cases. These and other studies [48, 49] consistently demonstrate that pretreatment FDG-PET/CT is superior to conventional imaging. It should be emphasized that initial staging with FDG-PET/CT not only allows the detection of the primary tumor and local disease, but also the detection of distant



**Fig. 2.** FDG-PET/CT study in a 54-year-old male patient with squamous cell cancer in the base of the tongue. FDG imaging (**a**) demonstrates metastatic disease to the upper jugular lymph nodes (level II). In a transaxial fusion image (**c**), these lesions can be confirmed on a CT overlay. In the images 1 month later, after external beam radiation therapy, both these lesions have disappeared (**b, d**).

metastases through whole-body imaging. However, more important is FDG scanning for the high coincidence with other primary tumors like lung, gastric and esophageal cancer [50].

The usefulness of interim FDG scanning (evaluation of induction therapy; fig. 2) in patients with head and neck cancer has been illustrated in a number of reports. A recent report by Yoon et al. [51] mentions FDG-PET in 21 patients with locally advanced tumors prior to and 2–4 weeks after induction chemotherapy. These authors found that a 65%  $SUV_{max}$  decrease from baseline value could predict clinical complete response ( $p = 0.003$ ). Knowing that CT fusion leads to a 15% increase in nodal staging compared to PET alone [52], it can be postulated

that FDG-PET/CT can only improve this prediction number.

The accuracy of FDG-PET/CT in the assessment of treatment response after definitive radiotherapy or chemoradiotherapy has been the subject of a number of recent clinical investigations. Ghanooni et al. [53] performed a prospective follow-up study in 32 patients with squamous cell carcinoma. FDG-PET/CT was performed before treatment and 2 weeks and 4 months after treatment. At 2 weeks after radiotherapy, residual malignant tissue was detected with a sensitivity and specificity of 86 and 85%, respectively. For relapse detection at 4 months, the sensitivity was reported to be 92%. The authors also report on simultaneously obtained MRI data and men-

tion that this modality is less sensitive (70%) at 4 months with regard to relapse detection.

On the same issue, Prestwich et al. [54] analyzed 44 consecutive patients who underwent FDG-PET/CT at baseline and at about 16 weeks after (chemo)radiotherapy. Thirty-one of the cases with locally advanced tumor showed a complete clinical response. The sensitivity and specificity for primary disease was 100 and 89%, respectively, and for nodal disease 100 and 92%, respectively. In 7 patients, FDG-negative lesions were detected with the unenhanced CT component of the hybrid scanner. After clinical observation of at least 8 months, these patients remained disease free. A similar investigation has been performed by Porceddu et al. [55]. These researchers enrolled 112 consecutive patients who achieved a complete response at the primary site. The patients underwent an FDG study and diagnostic CT for nodal response assessment at 12 weeks after the end of (chemo)radiotherapy. After a median follow-up of 28 months, the posttherapy assessment with CT showed residual nodal abnormalities in 50 patients, of which 41 were FDG-negative. The 9 patients with a positive FDG result underwent further treatment and in 6, residual disease could be confirmed. None of the 62 patients with negative FDG and CT results at 12 weeks after therapy showed isolated nodal failure during the follow-up period.

In combined prospective studies comprising stage III/Ib patients, Passero et al. [56] demonstrated that FDG-PET/CT but not clinical examination or CT using RECIST criteria correlated significantly with progression-free status ( $p < 0.0001$ ). The 2-year progression-free status for patients with complete remission and without complete remission by FDG scanning was 93 and 48%, respectively ( $p = 0.0002$ ). These recent findings confirm those of Ong et al. [57], published previously. The latter authors retrospectively evaluated 65 patients with locoregional advanced cancer after concurrent chemoradiotherapy. In these patients, the high negative predictive value of 97% (based on normal FDG-PET/CT at or 8 weeks after the end of therapy) virtually excluded locoregional disease.

In summary, in squamous cell head and neck cancer FDG-PET/CT offers the possibility to detect the primary tumor, locoregional involvement, distant metastatic disease as well as another primary malignancy. As such, this technique has proven to be a valuable diagnostic tool for staging, rather than physical examination, with or without CT or FDG-PET without CT [57]. In view of its ability to identify unrecognized lesions, FDG-PET/CT is useful for planning the most appropriate treatment (see for

**Table 1.** Usefulness of FDG-PET/CT in various malignancies

	Initial staging	Early evaluation therapy response	Evaluation at end of therapy
Breast	+(+)	++	++
Lung (NSCLC)	+(+)	++	s.d.a.
Colorectal	-	++	s.d.a.
HL	++	++	s.d.a.
NHL	++	++	++
Head and neck cancer	++	+	++

++ = Generally useful; + = useful in selected cases; - = not useful; s.d.a = scarce data available; NSCLC = non-small-cell lung cancer.

instance: <https://www.cancercare.on.ca/common/pages/UserFile.aspx?fileId=43127> for an in-depth overview).

Furthermore, a negative FDG-PET/CT examination is a powerful predictor of progression-free survival. Prospective studies are needed, however, to provide evidence that this modality is a decisive criterion in the management of these patients after therapy. At present, it can be advocated that patients who achieved complete therapy response on FDG-PET/CT can be followed up safely without invasive diagnostic methods [58]. In this context, it should be noted that FDG-PET/CT is helpful in differentiating persisting viable tumor masses from residual masses [59, 60].

## Discussion and Conclusion

In oncology, FDG-PET/CT offers the unique combination of functional PET and anatomic CT imaging, which facilitates the identification of primary and secondary tumors. In addition, this imaging modality is extremely well suited to assess therapy response in a clinical setting before morphological signs are evident (table 1). Indeed there is a lot of evidence that FDG-PET/CT changes the management of the patient and it is often used to decide initial and subsequent treatment strategy [61, 62]. In an era in which tailored targeted anticancer therapies are evolving, criteria which are only based on anatomic imaging are obsolete and carry the risk of underestimating therapeutic potential. Thus, multimodality imaging, including FDG-PET/CT, provides the best platform to assess therapy response of anticancer drugs and also for the drugs which are under investigation [63]. Undoubtedly FDG-PET/CT will become an integral part of the



World Health Organization, RECIST/PERCIST, EORTC and EANM (European Association of Nuclear Medicine) guidelines and recommendations that are currently used for the interpretation of drug activity and related solid tumor response [5–7, 64, 65]. This knowledge can help the clinician to identify (early) tumor-related symptoms. Nevertheless, the timing of response measurement is still a subject of debate. In their review, Storto et al. [66] advocate FDG scanning as late as possible after completion of therapy in order to avoid the effect of stunning on FDG uptake. On the other hand, it is stated that early response assessment by FDG-PET/CT can be advantageous in patient management and data from the literature endorse to consider 1–3 weeks after the initiation of the first chemotherapy cycle.

Despite its extraordinary clinical reach, one important limitation of FDG imaging is the fact that the agent is not specific for tumor tissue. False-positive results may be due to other processes with increased metabolic activity, including inflammatory and infectious states. It should also be mentioned that some low-grade tumors show a slow metabolic rate and, consequently, FDG accumulation is often not observed in these malignancies (primary tumors and metastases) including prostate cancer, differentiated thyroid cancer and neuroendocrine tumors, low-grade lymphoma and bronchoalveolar lung cancer [67].

One other aspect of hybrid PET/CT scanning should not be ignored and concerns the radiation dose delivered to the patient. The extra CT dose, including the scout scan, may make up a considerable part of the radiation burden. To overcome this problem, 'low-dose' CT has been implemented on many commercially available systems and may make up more than 25% (including the scout scan) of the total dose delivered to the patient by the imaging modality. Another effective way to reduce the radiation level and

the radiation dose to the patient is to optimize CT protocols. This may, unfortunately, cause loss of information necessary for adequate attenuation correction, quantification and diagnosis. In their extensive recent review on this issue, Leitha and Staudenherz [68] state that 'at present we lack sufficient data to quantify the diagnostic trade off between "low dose" and "diagnostic CT"'.

In the context of the early assessment of anticancer drug efficacy, FDG-PET/CT may be useful in the developmental process of new drugs. FDG-PET/CT is the method of choice for the objective and reproducible registration and measurement of metabolic and morphologic effect. This is a topical subject as important advances in molecular biology with respect to the proliferation of tumor cells have been made over the last decade. Harry et al. [69] stress that FDG scanning is an important early indicator with regard to drug efficacy and that may well serve as a surrogate biomarker of response.

Regarding economic considerations, an analysis of cost-effectiveness of FDG-PET/CT indicates that this imaging technique is superior to PET and CT alone in various tumors due to its greater accuracy [70, 71]. The potential financial savings associated with the use of FDG-PET/CT make additional imaging examinations or invasive procedures superfluous. Perhaps the most important aspect of this imaging technique comes from the patient's point of view: it reduces the time that is needed before appropriate evidence-based medical treatment is started, thereby diminishing anxiety and uncertainty.

## Acknowledgment

The authors are indebted to Jarkko Tiusanen for his assistance in formatting the figures.

## References

- 1 Czernin J, Benz MR, Allen-Auerbach MS: PET/CT imaging: the incremental value of assessing the glucose metabolic phenotype and the structure of cancers in a single examination. *Eur J Radiol* 2010;73:470–480.
- 2 Castell F, Cook GJ: Quantitative techniques in <sup>18</sup>F-FDG PET scanning in oncology. *Br J Cancer* 2008;98:1597–1601.
- 3 Keyes JW Jr: SUV: standard uptake or silly useless value? *J Nucl Med* 1995;36:1836–1839.
- 4 Miller AB, Hoogstraten B, Staquet M, et al: Reporting results of cancer treatment. *Cancer* 1981;47:207–214.
- 5 Eisenhauer EA, Therasse P, Bogaerts J, et al: New response evaluation criteria in solid tumours: revised RECIST guideline (version 1.1). *Eur J Cancer* 2009;45:228–247.
- 6 Young H, Baum R, Cremerius U, et al: Measurement of clinical and subclinical tumour response using [<sup>18</sup>F]-fluorodeoxyglucose and positron emission tomography: review and 1999 EORTC recommendations. European Organization for Research and Treatment of Cancer (EORTC) PET Study Group. *Eur J Cancer* 1999;35:1773–1782.
- 7 Wahl RL, Jacene H, Kasamon Y, et al: From RECIST to PERCIST: evolving considerations for PET response criteria in solid tumors. *J Nucl Med* 2009;50(suppl 1):122S–150S.
- 8 Avril N, Sassen S, Roylance R: Response to therapy in breast cancer. *J Nucl Med* 2009; 50(suppl 1):55S–63S.
- 9 Riegger C, Herrmann J, Nagarajah J, et al: Whole-body FDG PET/CT is more accurate than conventional imaging for staging primary breast cancer patients. *Eur J Nucl Med Mol Imaging* 2012;39:852–863.

- 10 Koolen BB, Valdés Olmos RA, Elkhuizen PH, et al: Locoregional lymph node involvement on <sup>18</sup>F-FDG PET/CT in breast cancer patients scheduled for neoadjuvant chemotherapy. *Breast Cancer Res Treat* 2012;135:231–240.
- 11 Schwarz-Dose J, Untch M, Tiling R, et al: Monitoring primary systemic therapy of large and locally advanced breast cancer by using sequential positron emission tomography imaging with [<sup>18</sup>F] fluorodeoxyglucose. *J Clin Oncol* 2009;27:535–541.
- 12 Martoni AA, Zamagni C, Quercia S, et al: Early (18)F-2-fluoro-2-deoxy-D-glucose positron emission tomography may identify a subset of patients with estrogen receptor-positive breast cancer who will not respond optimally to preoperative chemotherapy. *Cancer* 2010;116:805–813.
- 13 Keam B, Im SA, Koh Y, et al: Early metabolic response using FDG PET/CT and molecular phenotypes of breast cancer treated with neoadjuvant chemotherapy. *BMC Cancer* 2011;11:452.
- 14 Haug AR, Tiega Donfack BP, Trumm C, et al: <sup>18</sup>F-FDG PET/CT predicts survival after radioembolization of hepatic metastases from breast cancer. *J Nucl Med* 2012;53:371–377.
- 15 Maziak DE, Darling GE, Inculet RI, et al: Positron emission tomography in staging early lung cancer: a randomized trial. *Ann Intern Med* 2009;151:221–228, W-48.
- 16 Fischer B, Lassen U, Mortensen J, et al: Preoperative staging of lung cancer with combined PET-CT. *N Engl J Med* 2009;361:32–39.
- 17 Billé A, Pelosi E, Skanjeti A, et al: Preoperative intrathoracic lymph node staging in patients with non-small-cell lung cancer: accuracy of integrated positron emission tomography and computed tomography. *Eur J Cardiothorac Surg* 2009;36:440–445.
- 18 Perigaud C, Bridji B, Roussel JC, et al: Prospective preoperative mediastinal lymph node staging by integrated positron emission tomography-computerised tomography in patients with non-small-cell lung cancer. *Eur J Cardiothorac Surg* 2000;36:731–736.
- 19 Aukema TS, Kappers I, Olmos RA, et al, NEL Study Group: Is <sup>18</sup>F-FDG PET/CT useful for the early prediction of histopathologic response to neoadjuvant erlotinib in patients with non-small cell lung cancer? *J Nucl Med* 2010;51:1344–1348.
- 20 Benz MR, Herrmann K, Walter F, et al: (18)F-FDG PET/CT for monitoring treatment responses to the epidermal growth factor receptor inhibitor erlotinib. *J Nucl Med* 2011;52:1684–1689.
- 21 Mileshkin L, Hicks RJ, Hughes BG, et al: Changes in <sup>18</sup>F-fluorodeoxyglucose and <sup>18</sup>F-fluorodeoxythymidine positron emission tomography imaging in patients with non-small cell lung cancer treated with erlotinib. *Clin Cancer Res* 2011;17:3304–3315.
- 22 Kahraman D, Scheffler M, Zander T, et al: Quantitative analysis of response to treatment with erlotinib in advanced non-small cell lung cancer using <sup>18</sup>F-FDG and 3'-deoxy-3'-<sup>18</sup>F-fluorothymidine PET. *J Nucl Med* 2011;52:1871–1877.
- 23 Zander T, Scheffler M, Nogova L, et al: Early prediction of nonprogression in advanced non-small-cell lung cancer treated with erlotinib by using [(18)F]fluorodeoxyglucose and [(18)F]fluorothymidine positron emission tomography. *J Clin Oncol* 2011;29:1701–1708.
- 24 Rosenberg R, Herrmann K, Gertler R, et al: The predictive value of metabolic response to preoperative radiochemotherapy in locally advanced rectal cancer measured by PET/CT. *Int J Colorectal Dis* 2009;24:191–200.
- 25 Capirci C, Rampin L, Erba PA, et al: Sequential FDG-PET/CT reliably predicts response of locally advanced rectal cancer to neoadjuvant chemo-radiation therapy. *Eur J Nucl Med Mol Imaging* 2007;34:1583–1593.
- 26 Lambrecht M, Deroose C, Roels S, et al: The use of FDG-PET/CT and diffusion-weighted magnetic resonance imaging for response prediction before, during and after preoperative chemoradiotherapy for rectal cancer. *Acta Oncol* 2010;49:956–963.
- 27 Janssen MH, Öllers MC, van Stiphout RG, et al: PET-based treatment response evaluation in rectal cancer: prediction and validation. *Int J Radiat Oncol Biol Phys* 2012;82:871–876.
- 28 Bellomi M, Rizzo S, Travaini LL, et al: Role of multidetector CT and FDG-PET/CT in the diagnosis of local and distant recurrence of resected rectal cancer. *Radiol Med* 2007;112:681–690.
- 29 Metser U, You J, McSweeney S, et al: Assessment of tumor recurrence in patients with colorectal cancer and elevated carcinoembryonic antigen level: FDG PET/CT versus contrast-enhanced 64-MDCT of the chest and abdomen. *AJR Am J Roentgenol* 2010;194:766–771.
- 30 Pelosi E, Pregno P, Penna D, et al: Role of whole-body [<sup>18</sup>F] fluorodeoxyglucose positron emission tomography/computed tomography (FDG-PET/CT) and conventional techniques in the staging of patients with Hodgkin and aggressive non-Hodgkin lymphoma. *Radiol Med* 2008;113:578–590.
- 31 Munker R, Glass J, Griffeth LK, et al: Contribution of PET imaging to the initial staging and prognosis of patients with Hodgkin's disease. *Ann Oncol* 2004;15:1699–1704.
- 32 Shelly MJ, McDermott S, O'Connor OJ, et al: 18-Fluorodeoxyglucose positron emission tomography/computed tomography in the management of aggressive non-Hodgkin's B-cell lymphoma. *ISRN Hematol* 2012;2012:456706.
- 33 Cerci JJ, Pracchia LF, Linardi CC, et al: <sup>18</sup>F-FDG PET after 2 cycles of ABVD predicts event-free survival in early and advanced Hodgkin lymphoma. *J Nucl Med* 2010;51:1337–1443.
- 34 Avigdor A, Bulvik S, Levi I, et al: Two cycles of escalated BEACOPP followed by four cycles of ABVD utilizing early-interim PET/CT scan is an effective regimen for advanced high-risk Hodgkin's lymphoma. *Ann Oncol* 2010;21:126–132.
- 35 Gallamini A, Patti C, Viviani S, et al, Gruppo Italiano Terapie Innovative nei Linfomi (GITIL): Early chemotherapy intensification with BEACOPP in advanced-stage Hodgkin lymphoma patients with a interim-PET positive after two ABVD courses. *Br J Haematol* 2011;152:551–560.
- 36 Kasamon YL: Prognostication and risk-adapted therapy of Hodgkin's lymphoma using positron emission tomography. *Adv Hematol* 2011;2011:271595.
- 37 Zhao J, Qiao W, Wang C, et al: Therapeutic evaluation and prognostic value of interim hybrid PET/CT with (18)F-FDG after three to four cycles of chemotherapy in non-Hodgkin's lymphoma. *Hematology* 2007;12:423–430.
- 38 Zinzani PL, Gandolfi L, Broccoli A, et al: Midtreatment <sup>18</sup>F-fluorodeoxyglucose positron-emission tomography in aggressive non-Hodgkin lymphoma. *Cancer* 2011;117:1010–1018.
- 39 Qiao W, Zhao J, Wang C, et al: Predictive value of (18)F-FDG hybrid PET/CT for the clinical outcome in patients with non-Hodgkin's lymphoma prior to and after autologous stem cell transplantation. *Hematology* 2010;15:21–27.
- 40 Juweid ME: FDG-PET/CT in lymphoma. *Methods Mol Biol* 2011;727:1–19.
- 41 Zanoni L, Cerci JJ, Fanti S: Use of PET/CT to evaluate response to therapy in lymphoma. *Q J Nucl Med Mol Imaging* 2011;55:633–647.
- 42 Baba S, Abe K, Isoda T, et al: Impact of FDG-PET/CT in the management of lymphoma. *Ann Nucl Med* 2011;25:701–716.
- 43 Haerle SK, Strobel K, Ahmad N, et al: Contrast-enhanced <sup>18</sup>F-FDG-PET/CT for the assessment of necrotic lymph node metastases. *Head Neck* 2011;33:324–329.
- 44 Carlson ER, Schaefferkoetter J, Townsend D, et al: The use of multiple time point dynamic positron emission tomography/computed tomography in patients with oral/head and neck cancer does not predictably identify metastatic cervical lymph nodes. *J Oral Maxillofac Surg* 2013;71:162–77.
- 45 Connell CA, Corry J, Milner AD, et al: Clinical impact of, and prognostic stratification by, F-18 FDG PET/CT in head and neck mucosal squamous cell carcinoma. *Head Neck* 2007;29:986–995.
- 46 Roh JL, Yeo NK, Kim JS, et al: Utility of 2-[<sup>18</sup>F] fluoro-2-deoxy-D-glucose positron emission tomography and positron emission tomography/computed tomography imaging in the preoperative staging of head and neck squamous cell carcinoma. *Oral Oncol* 2007;43:887–893.

- 47 Prestwich RJ, Bhatnagar P, Chowdhury FU, et al: The impact of (18)F-FDG PET CT prior to chemoradiotherapy for stage III/IV head and neck squamous cell carcinoma. *ISRN Oncol* 2012;2012:636379.
- 48 Baek CH, Chung MK, Son YI, et al: Tumor volume assessment by <sup>18</sup>F-FDG PET/CT in patients with oral cavity cancer with dental artifacts on CT or MR images. *J Nucl Med* 2008; 49:1422–1428.
- 49 Tauzin M, Rabalais A, Hagan JL, et al: PET-CT staging of the neck in cancers of the oropharynx: patterns of regional and retropharyngeal nodal metastasis. *World J Surg Oncol* 2010;8:70.
- 50 Xu GZ, Guan DJ, He ZY: (18)FDG-PET/CT for detecting distant metastases and second primary cancers in patients with head and neck cancer. A meta-analysis. *Oral Oncol* 2011;47:560–565.
- 51 Yoon DH, Cho Y, Kim SY, et al: Usefulness of interim FDG-PET after induction chemotherapy in patients with locally advanced squamous cell carcinoma of the head and neck receiving sequential induction chemotherapy followed by concurrent chemoradiotherapy. *Int J Radiat Oncol Biol Phys* 2011;81: 118–125.
- 52 Jeong HS, Baek CH, Son YI, et al: Use of integrated <sup>18</sup>F-FDG PET/CT to improve the accuracy of initial cervical nodal evaluation in patients with head and neck squamous cell carcinoma. *Head Neck* 2007;29:203–210.
- 53 Ghanooni R, Delpierre I, Magremanne M, et al: FDG PET/CT and MRI in the follow-up of head and neck squamous cell carcinoma. *Contrast Media Mol Imaging* 2011;6:260–266.
- 54 Prestwich RJ, Subesinghe M, Gilbert A, et al: Delayed response assessment with FDG-PET-CT following (chemo)radiotherapy for locally advanced head and neck squamous cell carcinoma. *Clin Radiol* 2012;67:966–975.
- 55 Porceddu SV, Pryor DI, Burmeister E, et al: Results of a prospective study of positron emission tomography-directed management of residual nodal abnormalities in node-positive head and neck cancer after definitive radiotherapy with or without systemic therapy. *Head Neck* 2011;33:1675–1682.
- 56 Passero VA, Branstetter BF, Shuai Y, et al: Response assessment by combined PET-CT scan versus CT scan alone using RECIST in patients with locally advanced head and neck cancer treated with chemoradiotherapy. *Ann Oncol* 2010;21:2278–2283.
- 57 Ong SC, Schöder H, Lee NY, et al: Clinical utility of <sup>18</sup>F-FDG PET/CT in assessing the neck after concurrent chemoradiotherapy for locoregional advanced head and neck cancer. *J Nucl Med* 2008;49:532–540.
- 58 Freudenberg LS, Fischer M, Antoch G, et al: Dual modality of <sup>18</sup>F-fluorodeoxyglucose-positron emission tomography/computed tomography in patients with cervical carcinoma of unknown primary. *Med Princ Pract* 2005; 14:155–160.
- 59 Mak D, Corry J, Lau E, et al: Role of FDG-PET/CT in staging and follow-up of head and neck squamous cell carcinoma. *Q J Nucl Med Mol Imaging* 2011;55:487–499.
- 60 Allen-Auerbach M, Weber WA: Measuring response with FDG-PET: methodological aspects. *Oncologist* 2009;14:369–377.
- 61 Facey K, Bradbury I, Laking G, et al: Overview of the clinical effectiveness of positron emission tomography imaging in selected cancers. *Health Technol Assess* 2007;11:iii–iv, xi–267.
- 62 Fletcher JW, Djulbegovic B, Soares HP, et al: Recommendations on the use of <sup>18</sup>F-FDG PET in oncology. *J Nucl Med* 2008;49:480–508.
- 63 Milano A, Perri F, Ciarmiello A, et al: Targeted-therapy and imaging response: a new paradigm for clinical evaluation? *Rev Recent Clin Trials* 2011;6:259–265.
- 64 Boellaard R, O'Doherty MJ, Weber WA, et al: FDG PET and PET/CT: EANM procedure guidelines for tumour PET imaging: version 1.0. *Eur J Nucl Med Mol Imaging* 2010;37: 181–200.
- 65 Herrmann K, Benz MR, Krause BJ, et al: (18)F-FDG-PET/CT in evaluating response to therapy in solid tumors: where we are and where we can go. *Q J Nucl Med Mol Imaging* 2011;55:620–632.
- 66 Storto G, Nicolai E, Salvatore M: [<sup>18</sup>F]FDG-PET-CT for early monitoring of tumor response: when and why. *Q J Nucl Med Mol Imaging* 2009;53:167–180.
- 67 Long NM, Smith CS: Causes and imaging features of false positives and false negatives on F-PET/CT in oncologic imaging. *Insights Imaging* 2011;2:679–698.
- 68 Leitha T, Staudenherz A: Hybrid PET/CT and SPECT/CT imaging; in Saba L (ed): *Computed Tomography – Clinical Applications*. 2012. <http://www.intechopen.com/books/computed-tomography-clinical-applications/hybrid-pet-ct-and-spect-ct-imaging>.
- 69 Harry VN, Semple SI, Parkin DE, et al: Use of new imaging techniques to predict tumour response to therapy. *Lancet Oncol* 2010;11:92–102.
- 70 Langer A: A systematic review of PET and PET/CT in oncology: a way to personalize cancer treatment in a cost-effective manner? *BMC Health Serv Res* 2010;10:283.
- 71 Saif MW, Tzannou I, Makrilia N, et al: Role and cost effectiveness of PET/CT in management of patients with cancer. *Yale J Biol Med* 2010;83:53–65.