

Beta-Tricalcium Phosphate Block for Donor Site Morbidity of the Patella in Anterior Cruciate Ligament Reconstruction Using Bone-Patellar Tendon-Bone Graft

Yuki Kato, MD, PhD, Joverienne Chavez, MD, Shin Yamada, MD, Soichi Hattori, MD, Shuzo Takazawa, MD, and Hiroshi Ohuchi, MD, PhD

Department of Sports Medicine, Kameda Medical Center, Kamogawa, Japan

Purpose: This study aimed to investigate anterior knee symptoms in patients who underwent anterior cruciate ligament (ACL) reconstruction using bone-patellar tendon-bone (BPTB) graft followed by implantation of a beta-tricalcium phosphate (β -TCP) block as a bone void filler.

Materials and Methods: We retrospectively reviewed 84 cases of synthetic bone grafting using a β -TCP block for the patellar bone defect in ACL reconstruction with a BPTB autograft. Computed tomography of the operated knee was performed immediately after the surgery to evaluate whether the grafted β -TCP block protruded forward from the anterior surface of the patella. On the basis of the results, the cases were divided into a protrusion group (n=31) and a non-protrusion group (n=53). Anterior knee symptoms at 12 months postoperatively and absorption of the grafted β -TCP block were compared between the two groups.

Results: Except for patellofemoral crepitus, there was no significant difference in anterior knee symptoms between the two groups ($p>0.05$). The incidence of patellofemoral crepitus was significantly lower in the protrusion group than in the non-protrusion group ($p=0.027$). The groups showed no significant difference in β -TCP absorption.

Conclusions: The present study demonstrated that the protrusion of β -TCP that was used as a bone void filler had no adverse effects.

Keywords: Knee, Anterior cruciate ligament, Reconstruction, Bone-patellar tendon-bone grafts, Beta-tricalcium phosphate block, Donor site morbidity

Introduction

Bone-patellar tendon-bone (BPTB) autograft remains the common graft choice in anterior cruciate ligament (ACL) reconstructions^{1,2}, although the hamstring graft has been more commonly used recently. Due to the high initial tensile strength³, strong primary fixation, and early osseous integration of the bone plugs

in the tunnels, BPTB autograft is preferred for high-demand patients, such as athletes and laborers⁴. Despite its biomechanical advantages, use of BPTB autograft has been associated with donor site morbidity, presenting as anterior knee pain (AKP) and sensory disturbances. Additionally, BPTB autograft is often unsuitable in patients whose careers demand regular kneeling⁵⁻⁸. An untreated bone plug donor site with no bone formation causes severe tenderness, making it difficult for the patient to kneel. For prevention of such morbidity, autologous bone transplantation to the donor site is recommended⁹, although it is concerned that protrusion or deformity of the transplanted site might have an adverse effect. Although management of the BPTB donor site in ACL reconstruction remains debatable, bone substitutes, such as beta-tricalcium phosphate (β -TCP), may also be used as bone void fillers¹⁰ in order to eliminate the possibility of further donor site morbidity associated with autologous bone graft. The use of β -TCP block is advantageous because there are no reported complications at other bone donor sites and it can construct can-

Received July 31, 2018; Revised (1st) September 27, 2018; (2nd) December 16, 2018; Accepted February 18, 2019

Correspondence to: Yuki Kato, MD, PhD

Department of Sports Medicine, Kameda Medical Center, 929 Higashi-cho, Kamogawa 296-8602, Japan

Tel: +81-4-7092-2211, Fax: +81-4-7099-1191

E-mail: kato.yuki.0@kameda.jp

This is an Open Access article distributed under the terms of the Creative Commons Attribution Non-Commercial License (<http://creativecommons.org/licenses/by-nc/4.0/>) which permits unrestricted non-commercial use, distribution, and reproduction in any medium, provided the original work is properly cited.

cellous bone structure after its absorption and integration with surrounding bone structure with time. However, the integration speed and the size at the time of final bone structure construction cannot be predicted.

Therefore, in this study, we investigated the incidence of anterior knee symptoms and the speed of the graft integration after the use of β -TCP as a void filler in BPTB-ACL reconstruction according to the presence of initial protrusion of β -TCP block to determine whether those outcomes are affected by the initial graft protrusion. We hypothesized that BPTB donor site morbidity and adverse effects would increase when a large-size β -TCP block was used as a bone void filler.

Materials and Methods

1. Patients

A total of 140 reconstructions performed by the Y. K. were included in this study. OSferion[®] (Olympus Terumo Biomaterials Corp., Tokyo, Japan) β -TCP block with 75% porosity was used to fill the patellar defect following ACL reconstruction with BPTB autograft from February 2013 to September 2016 at Nihon University Hospital. Among them, 84 knees from 84 patients (53 male and 31 female patients) who could be followed up for at least 1 year postoperatively were studied retrospectively. Seventy-seven of the procedures were primary reconstructions, and seven were revisions due to synthetic graft failure. The mean age of the patients was 29.6 ± 11.8 years, ranging from 14 to 57 years. Patients excluded from the study were those with a past history or postoperative complications, such as patella fracture (n=2).

2. Intervention and Comparison

The graft harvest for all patients was performed using the following steps: The patient was positioned supine with a lateral post placed just proximal to the knee, at the level of a padded tourniquet, and a foot roll was used to prevent the hip from externally rotated and to maintain knee flexion at 90°. A pneumatic tourniquet was generally not used; it was applied when it was needed to be inflated intraoperatively. Longitudinal double incisions, approximately 25 mm each, were made over the inferior pole of the patella and over the area just medial to the tibial tubercle (Fig. 1). The incisions were performed layer by layer up to the patellar tendon. The paratenon was identified, incised longitudinally, and dissected both medially and laterally. A 10 mm graft was marked and incised from the central third of the patellar tendon. The patellar bone block was marked at a length of 12 mm from the inferior pole and a width of 10 mm. An osteotomy

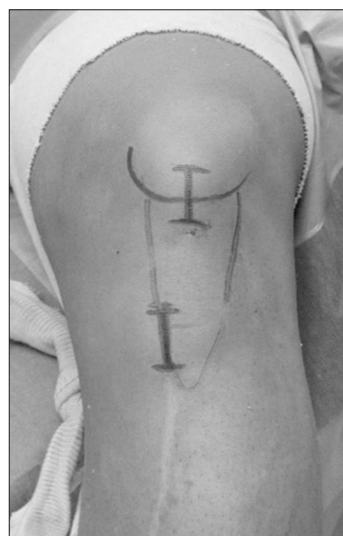

Fig. 1. Our incision approach. Longitudinal double incisions of approximately 25 mm each are made over the inferior pole of the patella and the area just medial to the tibial tubercle.

of the patellar bone block was performed using an oscillating saw at an angle of approximately 100° from the coronal plane to create a thickness of approximately 5 mm. The osteotomy was completed using a curved osteotome. The tibial bone block was harvested in a similar fashion distally from the most proximal portion of the tibial tubercle. The tibial bone block was marked at a length of 15 mm from the most proximal part of tibial insertion of the patella tendon and at a width of 10 mm. A β -TCP block, shaped like a baseball home plate with a length of 12 mm and a width of 10 mm was placed into the patellar donor site (Fig. 2). In all cases, the anterior protrusion height of the graft did not exceed 2 mm, and the inferior protrusion did not exceed the distal end of the original patella; the anterior graft protrusion was not intentional. After copious irrigation, the medial and lateral thirds of the patellar tendon were sutured together using a 3-0 polyglactin 910 (Vicryl[®]; Ethicon Inc., Somerville, NJ, USA) sutures. The paratenon was repaired using the same sutures.

The extent of protrusion of the graft used to fill the bone void was investigated. Computed tomography (CT) of the operated knee was performed 1 week postoperatively; multi-planar reconstruction of the CT images showed the position of the implanted β -TCP block relative to the patella. On the basis of the protrusion of the grafted β -TCP block from the anterior surface of the patella, the samples were classified into two groups: a protrusion group (n=31) (Fig. 3A) and a non-protrusion group (n=53) (Fig. 3B).

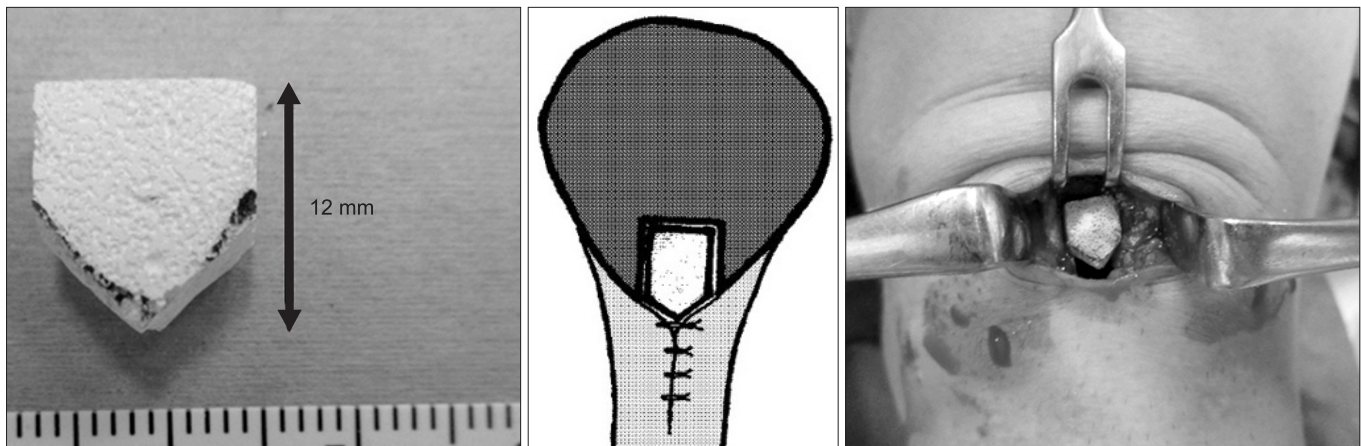


Fig. 2. The beta-tricalcium phosphate block is shaped like a baseball home plate and is placed into the patellar donor site.

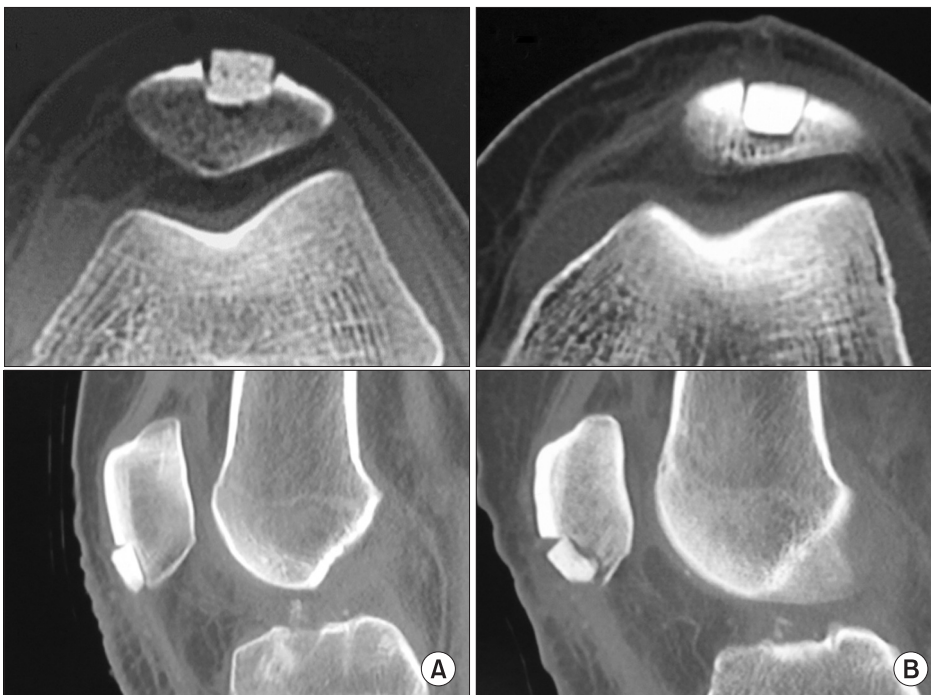

Fig. 3. Axial computed tomography of the knee showing protrusion of the graft (A) and the graft without protrusion (B). Based on this information, all cases were classified into two groups: a protrusion group (n=31) and a non-protrusion group (n=53).

3. Outcome Measures

Patients were followed up at 1, 3, 6, 9, and 12 months postoperatively. During each follow-up, radiographs were taken to assess the integration of the β -TCP block with the surrounding bone. The integration of the β -TCP block was defined as an unclear boundary between the β -TCP block and the surrounding cancellous bone due to absorption of the artificial bone. The following five subjective symptoms were also checked 12 months postoperatively: (1) AKP during activities of daily living; (2) AKP during sports activities; (3) sensory abnormality around a graft donor site; (4) kneeling pain; and (5) patellofemoral crepitus. The pa-

tients were asked to answer with a yes or a no for each symptom except for kneeling pain. A three-grade evaluation was made for assessing kneeling pain as follows: pain-free or almost pain-free was graded as “mild”; kneeling possible despite pain, as “moderate”; and kneeling impossible because of severe pain, as “severe”. Presence of an audible grinding noise and/or palpable vibrations around the patella¹¹⁾ was considered as patellofemoral crepitus.

4. Statistical Analysis

Pearson chi-square test was performed to compare the anterior knee symptoms and the time of β -TCP block absorption between

the two groups. Statistical significance was set at $p < 0.05$. All statistical data were calculated using the statistical software package SPSS ver. 17.0 (SPSS Inc., Chicago, IL, USA).

Results

AKP during activities of daily living was found in 5 out of 84 knees (6.0%); there was no significant difference in the incidence between the non-protrusion and protrusion groups (7.5% vs.

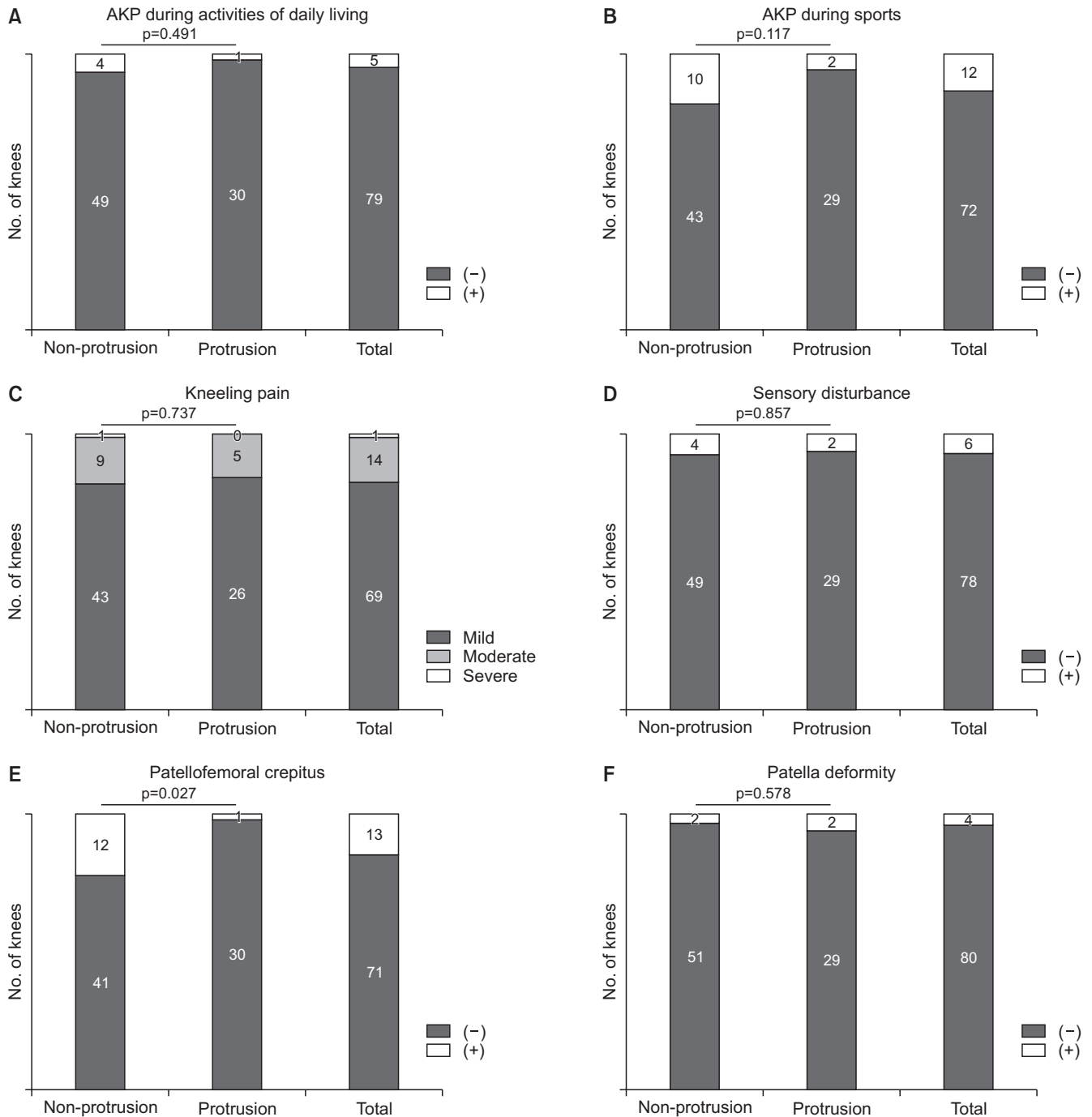


Fig. 4. Comparison of the incidences of anterior knee symptoms and patellar deformity after anterior cruciate ligament reconstruction between the non-protrusion group and the protrusion group. (A) Incidence of anterior knee pain (AKP) during activities of daily living. (B) Incidence of AKP during sports. (C) Incidence of kneeling pain. (D) Incidence of sensory disturbance. (E) Incidence of patellofemoral joint crepitus. (F) Incidence of patellar deformity.

3.2%; $p=0.491$) (Fig. 4A).

AKP during sports was found in 12 of 84 knees (14.3%); there was no significant difference in the incidence between the non-protrusion and protrusion groups (18.9% vs. 6.5%; $p=0.117$) (Fig. 4B).

Kneeling pain was found in 15 of 84 knees (severe: 1 knee, 1.2%; moderate: 14 knees, 16.7%). There was no significant difference in the incidence of kneeling pain between the non-protrusion group (severe: 1 knee, 1.9%; moderate: 9 knees, 17.0%) and the protrusion group (severe: 0 knee, 0%; moderate: 5 knees, 16.1%) ($p=0.857$) (Fig. 4C).

Sensory disturbance around the donor site was found in 6 of 84 knees (7.1%). No significant difference in the incidence of sensory disturbance was observed between the non-protrusion and protrusion groups (7.5% vs. 6.3%; $p=0.737$) (Fig. 4D).

Patellofemoral crepitus was found in 12 of 84 knees (14.3%); the incidence was significantly higher in the non-protrusion group (11 of 53 knees, 20.8%) than that in the protrusion group (1 of 31 knees, 3.2%) ($p=0.027$) (Fig. 4E).

Patellar deformity was found in 4 of 84 knees (4.8%). No significant difference in the incidence of patellar deformity was observed between the non-protrusion and protrusion groups (3.8% vs. 6.5%; $p=0.578$) (Fig. 4F).

The integration of the β -TCP block with the surrounding bone was found in 35 knees at 3 months, in 39 knees at 6 months, in 6 knees at 9 months, and in 1 knee at 12 months after the surgery. The non-protrusion group demonstrated β -TCP block integration in 21 knees at 3 months, 27 knees at 6 months, 3 knees at 9 months, and 1 knee at 12 months; the protrusion group demonstrated it in 14 knees at 3 months, 12 knees at 6 months, and 3 knees at 9 months. However, no significant difference in integration time was observed between the non-protrusion and protrusion groups ($p=0.619$).

Discussion

The present study compared the anterior knee conditions between the two groups classified by the presence of protrusion of β -TCP implanted into the patella bone plug donor site immediately after ACL reconstruction. The present study demonstrated that anterior knee symptoms were not adversely affected by protrusion of β -TCP that was used as a bone void filler. A previous study showed that untreated bone plug donor site adversely affected anterior knee symptoms⁹. Therefore, transplantation of autologous bone or artificial bone as bone void fillers into the donor site has been recommended. However, it has been suggested that protrusion of the transplanted artificial bone might have an

adverse effect.

The present study showed that except for patellofemoral crepitus, there were no significant differences in anterior knee complaints between the protrusion and non-protrusion groups. This may be because the protruded β -TCP integrated within several months. In this study, the absorption of most β -TCP blocks was observed within 6 months. We believe that integration of β -TCP block differs from that of autologous bone. It is considered that protrusion of a transplanted autologous bone might remain for a long period. Bone substitutes, such as β -TCP, have also been used as bone void fillers¹⁰ in order to eliminate further donor site morbidity associated with autologous bone grafts. In these cases, whether graft size contributes to a better clinical outcome remains unclear. The present study focused on this issue and investigated the difference in postoperative anterior knee complaints according to the presence of β -TCP block protrusion at the donor site.

A BPTB harvest may be responsible for postoperative knee pain in 12%–50% of patients¹²; it damages the infragenicular branches of the saphenous nerve, resulting in pain in the donor site as well as functional restriction⁶. After ACL reconstruction, 40%–60% of patients complain of residual pain at the donor site, sensory disturbance, and pain in the knee on bending^{6,8,13}. In the present study, <20% of all cases complained of anterior knee symptoms. The incidence of anterior knee complaints was lower than that in previous studies, which may be attributed to the β -TCP transplantation in the donor site.

Management of bone void after BPTB harvest remains unclear in the literature as reports about donor site management are conflicting. Based on a systematic review of four randomized trials^{13–15}, no statistically significant or clinically relevant differences were found in the outcomes between patients who had the patellar tendon defect closed and those who had it left open after ACL reconstruction with a BPTB autograft¹⁶. Likewise, a prospective randomized study by Brandsson et al.¹⁴ showed that suturing the patellar tendon defect and grafting bone at the site did not reduce AKP or donor site morbidity. However, some studies have reported that bone grafting of the patellar defect can reduce the incidence of these complications^{9,17}. In the present study, all the patients had the patellar tendon defect closed.

Of the subjective outcome measures that included AKP during activities of daily living, AKP in sports, kneeling pain, sensory disturbance, and patellofemoral crepitus, the incidence of patellofemoral crepitus was significantly lower in the protrusion group. Patellofemoral crepitus may be caused by increased fibrous synovial tissue around the patella^{18,19}, patella baja^{20,21}, patellar instabil-

ity^{22,23}), and osteoarthritis of the patellofemoral joint. Based on these results, we suggest that a large-sized bone void filler may help prevent patellofemoral crepitus by reducing friction in the inferior pole of the patella and prevent increased synovial proliferation.

Sensory nerve damage, specifically to the infrapatellar branch of the saphenous nerve, may depend on the incision approach to a large extent. Portland et al.²⁴ found that 59% cases had sensory loss after ACL reconstruction with a vertical incision for the BPTB harvest. In the present study, the incidence of sensory disturbance (7.1%) was relatively low, which can be attributed to the longitudinal double incision used in all cases. Gaudot et al.²⁵ reported that this approach significantly reduced the midterm incidence of AKP and the occurrence of sensory disorders after ACL reconstruction. However, the size of the block used as a bone void filler does not appear to influence this incidence as no significant difference was found between the two groups in the present study.

The primary limitation of the present study was the absence of a control group where no graft was applied at all at the donor site defect. This was because the effectiveness of β -TCP block transplantation as a bone void filler remains unclear, we conducted the study under the assumption that regardless of size, using a β -TCP block would be better than having no graft at all that has been shown to cause anterior knee symptoms^{9,10}. In this study, integration of β -TCP was evaluated by simple X-ray performed in the postoperative follow-up sessions. Following integration with surrounding bone tissue by absorption of β -TCP block margin after transplantation, osteogenesis of the artificial bone itself occurs. Therefore, there is possibility that the final residual bone defect in the protrusion group would be smaller than the non-protrusion group. However, we did not quantitatively evaluate the absorption of β -TCP. The study was also based on the assumption that the size of the defect would not affect the incidence of anterior knee symptoms, and all harvested grafts were the standard size as described in previous studies. Despite the possibility that many factors such as body mass index, muscle weakness, associated injury, and period from initial injury to surgery may affect postoperative subjective symptoms, the present study did not analyze those data. Weiss and Whatman²⁶ described that chronic instability after ACL injury may contribute to patellofemoral pain, which could improve after restoration of knee stability. In this study, we did not investigate possible causes of residual postoperative patellofemoral pain other than the donor site morbidity. However, all the patients in this study had no abnormalities of the patellofemoral joint preoperatively, such as patellofemoral

osteoarthritis and patella instability. We also assumed that in the seven revision cases included in the study, hamstring deficiency due to harvesting in the primary reconstruction did not have any effect on the knee extensor mechanism of those patients. Further investigation into the relation between knee stability and the subjective outcomes is crucial.

Conclusions

Except for patellofemoral crepitus, there was no significant difference in anterior knee complaints between the two groups divided according to the presence of protrusion of the β -TCP block transplanted immediately after ACL reconstruction. The incidence of patellofemoral crepitus was significantly lower in the protrusion group than that in the non-protrusion group.

Conflict of Interest

No potential conflict of interest relevant to this article was reported.

References

1. Patel JV, Church JS, Hall AJ. Central third bone-patellar tendon-bone anterior cruciate ligament reconstruction: a 5-year follow-up. *Arthroscopy*. 2000;16:67-70.
2. Podskubka A, Kasal T, Vaculík J, Krystlík Z. [Arthroscopic reconstruction of the anterior cruciate ligament using the transtibial technique and a graft from the patellar ligament—results after 5-6 years]. *Acta Chir Orthop Traumatol Cech*. 2002;69:169-74. Czech.
3. Noyes FR, Butler DL, Grood ES, Zernicke RF, Hefzy MS. Biomechanical analysis of human ligament grafts used in knee-ligament repairs and reconstructions. *J Bone Joint Surg Am*. 1984;66:344-52.
4. Duquin TR, Wind WM, Fineberg MS, Smolinski RJ, Buyea CM. Current trends in anterior cruciate ligament reconstruction. *J Knee Surg*. 2009;22:7-12.
5. Duri ZA, Aichroth PM, Wilkins R, Jones J. Patellar tendonitis and anterior knee pain. *Am J Knee Surg*. 1999;12:99-108.
6. Kartus J, Stener S, Lindahl S, Engström B, Eriksson BI, Karlsson J. Factors affecting donor-site morbidity after anterior cruciate ligament reconstruction using bone-patellar tendon-bone autografts. *Knee Surg Sports Traumatol Arthrosc*. 1997;5:222-8.
7. Kleipool AE, van Loon T, Marti RK. Pain after use of the

- central third of the patellar tendon for cruciate ligament reconstruction. 33 patients followed 2-3 years. *Acta Orthop Scand.* 1994;65:62-6.
8. Sachs RA, Daniel DM, Stone ML, Garfein RF. Patellofemoral problems after anterior cruciate ligament reconstruction. *Am J Sports Med.* 1989;17:760-5.
 9. Tsuda E, Okamura Y, Ishibashi Y, Otsuka H, Toh S. Techniques for reducing anterior knee symptoms after anterior cruciate ligament reconstruction using a bone-patellar tendon-bone autograft. *Am J Sports Med.* 2001;29:450-6.
 10. Epstein NE. Efficacy of posterior cervical fusions utilizing an artificial bone graft expander, beta tricalcium phosphate. *Surg Neurol Int.* 2011;2:15.
 11. Schiphof D, van Middelkoop M, de Klerk BM, Oei EH, Hofman A, Koes BW, Weinans H, Bierma-Zeinstra SM. Crepitus is a first indication of patellofemoral osteoarthritis (and not of tibiofemoral osteoarthritis). *Osteoarthritis Cartilage.* 2014;22:631-8.
 12. Hardin GT, Bach BR Jr, Bush-Joseph CA, Farr J. Endoscopic single-incision anterior cruciate ligament reconstruction using patellar tendon autograft: surgical technique. 1992 [classical article]. *J Knee Surg.* 2003;16:135-44; discussion 145-7.
 13. Kohn D, Sander-Beuermann A. Donor-site morbidity after harvest of a bone-tendon-bone patellar tendon autograft. *Knee Surg Sports Traumatol Arthrosc.* 1994;2:219-23.
 14. Brandsson S, Faxén E, Eriksson BI, Kålebo P, Swärd L, Lundin O, Karlsson J. Closing patellar tendon defects after anterior cruciate ligament reconstruction: absence of any benefit. *Knee Surg Sports Traumatol Arthrosc.* 1998;6:82-7.
 15. Cerullo G, Puddu G, Gianni E, Damiani A, Pigozzi F. Anterior cruciate ligament patellar tendon reconstruction: it is probably better to leave the tendon defect open! *Knee Surg Sports Traumatol Arthrosc.* 1995;3:14-7.
 16. Frank RM, Mascarenhas R, Haro M, Verma NN, Cole BJ, Bush-Joseph CA, Bach BR Jr. Closure of patellar tendon defect in anterior cruciate ligament reconstruction with bone-patellar tendon-bone autograft: systematic review of randomized controlled trials. *Arthroscopy.* 2015;31:329-38.
 17. Ferrari JD, Bach BR Jr. Bone graft procurement for patellar defect grafting in anterior cruciate ligament reconstruction. *Arthroscopy.* 1998;14:543-5.
 18. Dennis DA, Kim RH, Johnson DR, Springer BD, Fehring TK, Sharma A. The John Insall Award: control-matched evaluation of painful patellar Crepitus after total knee arthroplasty. *Clin Orthop Relat Res.* 2011;469:10-7.
 19. Ranawat AS, Ranawat CS, Slamin JE, Dennis DA. Patellar crepitation in the P.F.C. sigma total knee system. *Orthopedics.* 2006;29(9 Suppl):S68-70.
 20. Figgie HE 3rd, Goldberg VM, Heiple KG, Moller HS 3rd, Gordon NH. The influence of tibial-patellofemoral location on function of the knee in patients with the posterior stabilized condylar knee prosthesis. *J Bone Joint Surg Am.* 1986;68:1035-40.
 21. Yau WP, Wong JW, Chiu KY, Ng TP, Tang WM. Patellar clunk syndrome after posterior stabilized total knee arthroplasty. *J Arthroplasty.* 2003;18:1023-8.
 22. Brody DM. Running injuries. Prevention and management. *Clin Symp.* 1987;39:1-36.
 23. Witvrouw E, Werner S, Mikkelsen C, Van Tiggelen D, Vanden Berghe L, Cerulli G. Clinical classification of patellofemoral pain syndrome: guidelines for non-operative treatment. *Knee Surg Sports Traumatol Arthrosc.* 2005;13:122-30.
 24. Portland GH, Martin D, Keene G, Menz T. Injury to the infrapatellar branch of the saphenous nerve in anterior cruciate ligament reconstruction: comparison of horizontal versus vertical harvest site incisions. *Arthroscopy.* 2005;21:281-5.
 25. Gaudot F, Leymarie JB, Drain O, Boisrenoult P, Charrois O, Beaufils P. Double-incision mini-invasive technique for BTB harvesting: its superiority in reducing anterior knee pain following ACL reconstruction. *Orthop Traumatol Surg Res.* 2009;95:28-35.
 26. Weiss K, Whatman C. Biomechanics associated with patellofemoral pain and ACL injuries in sports. *Sports Med.* 2015;45:1325-37.