

[CASE REPORT]

Hyperplasia of Lymphoid Follicles and Lymphangiectasia in the Parietal Pleura in Bucillamine-induced Yellow Nail Syndrome

Isano Hase^{1,2}, Kazuhiro Kurasawa³, Hidenori Takizawa^{1,2}, Bunpei Yamaguchi^{1,2},
Hideo Sakuma⁴ and Yoshiki Ishii²

Abstract:

Yellow nail syndrome (YNS) pleurisy is often difficult to control, and pathological examinations have rarely been reported. We herein report a case of bucillamine-induced YNS in which histopathology of the parietal pleura revealed hyperplasia of the lymphoid follicles and lymphangiectasia. Even after the discontinuation of bucillamine, the pleurisy and lymphedema showed no change. Based on the histopathological findings showing similarity to rheumatoid pleurisy, we administered corticosteroid treatments, and both the pleurisy and lymphedema improved. The findings in the present case suggest that, in bucillamine-induced YNS, pleurisy may be related to inflammation caused by rheumatoid arthritis in addition to abnormalities in lymphatic vessels.

Key words: yellow nail syndrome, bucillamine, rheumatoid arthritis, pleurisy, lymphangiectasia, lymphoid hyperplasia

(Intern Med 57: 1887-1892, 2018)

(DOI: 10.2169/internalmedicine.9679-17)

Introduction

Yellow nail syndrome (YNS) is a rare disease that is characterized by thickened and slowly growing yellow nails, lymphedema, and chronic respiratory involvement, such as pleurisy. The etiology of YNS remains unclear. Functional abnormalities in the lymphatic vessels are considered a cause of YNS (1, 2), although dilated lymphatic vessels have been reported in YNS in a few articles (3, 4). Rheumatoid arthritis (RA) is a disease that has been associated with two types of YNS (spontaneous and therapy-related YNS) (5). Bucillamine, a disease-modifying anti-rheumatic drug, is a major causal drug of YNS. Interestingly, yellowish nails improve in 90.3% of patients after bucillamine is discontinued, but pulmonary manifestations and lymphedema improve in only 35% and 30.8% of these patients, respectively (6). This inconsistency in results suggests that different mechanisms

are responsible for the development of pulmonary lesions and nail abnormalities in YNS (6). Detailed pathological examinations of bucillamine-induced YNS have rarely been reported.

We herein report a case of bucillamine-induced YNS that was successfully treated using corticosteroids. The patient had a parietal pleura that presented as hyperplasia of the lymphoid follicles and lymphangiectasia.

Case Report

An 86-year-old Japanese woman was admitted to the hospital for dyspnea that had developed 1 week before her admission and subsequently worsened. She had a two-year history of RA that was treated with bucillamine. All of the patient's fingernails and toenails had become yellowish and thickened, and she had not needed to cut those nails for six months (Fig. 1).

¹Department of Respiratory Disease, Southern Tohoku General Hospital, Japan, ²Department of Pulmonary Medicine and Clinical Immunology, Dokkyo Medical University, Japan, ³Department of Rheumatology, Dokkyo Medical University, Japan and ⁴Department of Pathology, Southern Tohoku General Hospital, Japan

Received: June 18, 2017; Accepted: November 8, 2017; Advance Publication by J-STAGE: February 9, 2018

Correspondence to Dr. Isano Hase, isanotaki@gmail.com

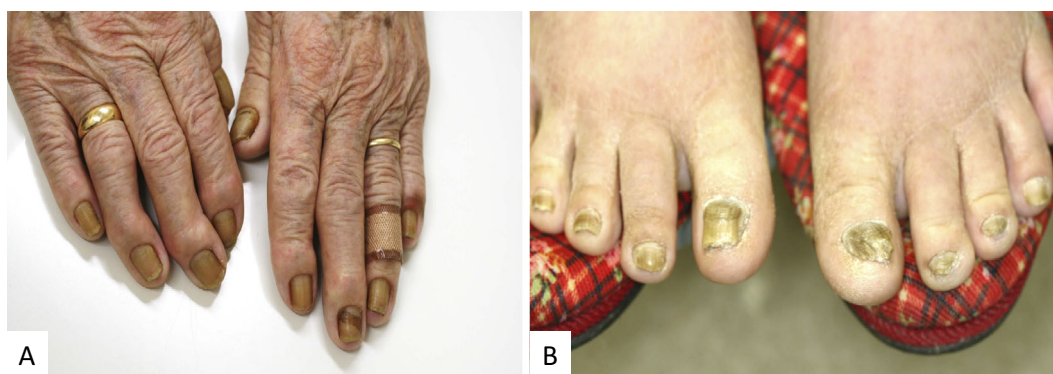

Figure 1. Photographs showing yellowish finger and toe nails.

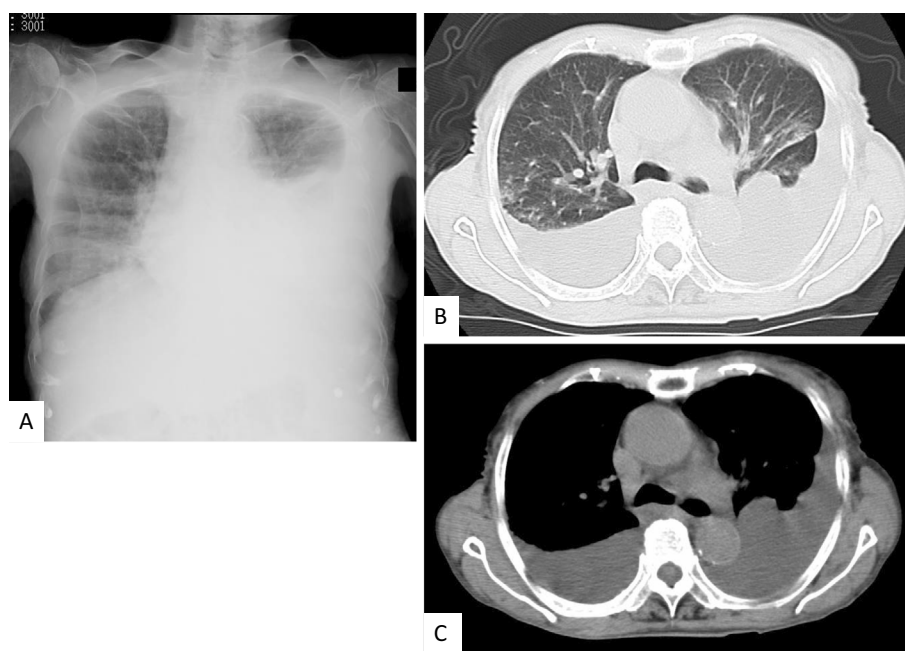


Figure 2. Chest radiography (A) and computed tomography (B, C) taken upon admission showing bilateral pleural effusion without apparent pulmonary lesions or thickened pleura.

The patient had never been a smoker. She presented with finger joint swelling with ulnar deviation, but the arthritis had been controlled for two years. She also presented with massive edema around her trunk and legs. Her body weight had increased from 36 kg to 43 kg over 7 months. Her peripheral oxygen saturation (SpO₂) was 94% on ambient air. Chest radiography and computed tomography showed bilateral pleural effusion without apparent pulmonary lesions or thickened pleura (Fig. 2). Radiography showed joint destruction and deformities in her hands, feet and knees. Laboratory data showed elevated C-reactive protein (2.5 mg/dL) and hypoalbuminemia (2.5 g/dL) levels with proteinuria (1.25 g/day). Her serum test was positive for rheumatoid factor and anti-cyclic citrullinated peptide antibodies but negative for anti-SS-A antibodies. Cardiac ultrasonography ruled out heart failure.

We performed thoracentesis once on each side. Bilateral pleural effusion comprised an exudate with lymphocytic predominance [86.3% (right) and 92.2% (left)] and no malign-

ant cells. The pleural effusion also showed normal levels of tumor markers, adenosine deaminase (ADA) [25.5 IU/L (right), 25.1 IU/L (left)], and glucose [122 mg/dL (right), 112 mg/dL (left)]. Cultures of the pleural effusion for bacteria or mycobacteria showed negative results.

We diagnosed the patient with bucillamine-induced YNS and discontinued bucillamine, instead administering salazosulfapyridine. One week after bucillamine was discontinued, the patient's nails began to gradually grow, but the pleural effusion and lymphedema did not change. Ten days after bucillamine was discontinued, medical thoracoscopy was performed and revealed multiple small, translucent nodules on the parietal pleura (Fig. 3). Large parietal pleura specimens were obtained with forceps using a peeling action. A pathological examination revealed hyperplastic lymphoid follicles with massive infiltration of plasma cells and lymphocytes but without granuloma (Fig. 4A-C). Immunohistochemical staining for CD3, 4, 8, and 20 showed that the lymphoid tissue in the pleura consisted of reactive hyperpla-

sia. The CD20-positive cells were surrounded by T cells (predominantly CD4-positive cells), consistent with a lymphoid follicular structure (data not shown). Immunohistochemical staining for IgG, IgA, κ , and λ showed polyclonality in the plasma cells, with a small percentage of the cells revealed to be IgG4-positive (data not shown). Immunohistochemistry performed using D2-40, a monoclonal antibody for lymphatic epithelium, revealed dilated lymphatic vessels in the subpleural area (Fig. 4D and E). Diseases other than RA that are frequently associated with hyperplasia of the lymphoid follicles were excluded.

Because RA-induced inflammation may have been a con-

tributing factor, we administered prednisolone (30 mg/day). After two weeks of this treatment, the patient needed no additional thoracentesis, and her lymphedema gradually improved. We began to taper the prednisolone after three weeks. After four weeks of prednisolone, she was discharged from our hospital. The corticosteroid dose was gradually tapered to 5 mg/day by her home doctor. One year later, she was re-admitted to our hospital because she was vomiting blood as a result of gastric cancer. At that time, she had not presented with any recurrence of pleural effusion, yellow nails, or lymphedema while on 5 mg/day of prednisolone (Fig. 5). She was transferred to a local hospital for palliative care and subsequently passed away.

Discussion

To our knowledge, this is the first report of bucillamine-induced YNS accompanied by hyperplastic lymphoid follicles and lymphangiectasia in the parietal pleura. Steroid treatment was effective in controlling pleural effusion in the present case. These findings suggest that inflammation due to RA can be related to bucillamine-induced YNS pleurisy.

Nakagomi et al. reported that the clinical manifestations of bucillamine-induced YNS include yellow nails (100% of 38 patients), lymphedema (37.1%), and pulmonary involvement (52.6%) (6). The chemical structure of bucillamine is similar to that of cysteine, a component of the keratin in nails, and this likely contributes to the mechanism underlying the development of yellow nails in these patients. Thus, bucillamine intake induces a yellow color in the nails, and

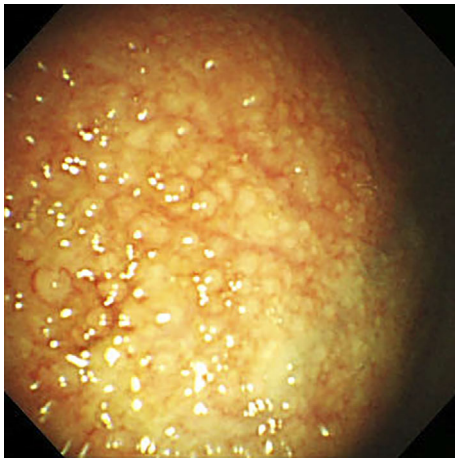


Figure 3. A medical thoracoscopic examination showing multiple small, translucent nodules on the parietal pleura.

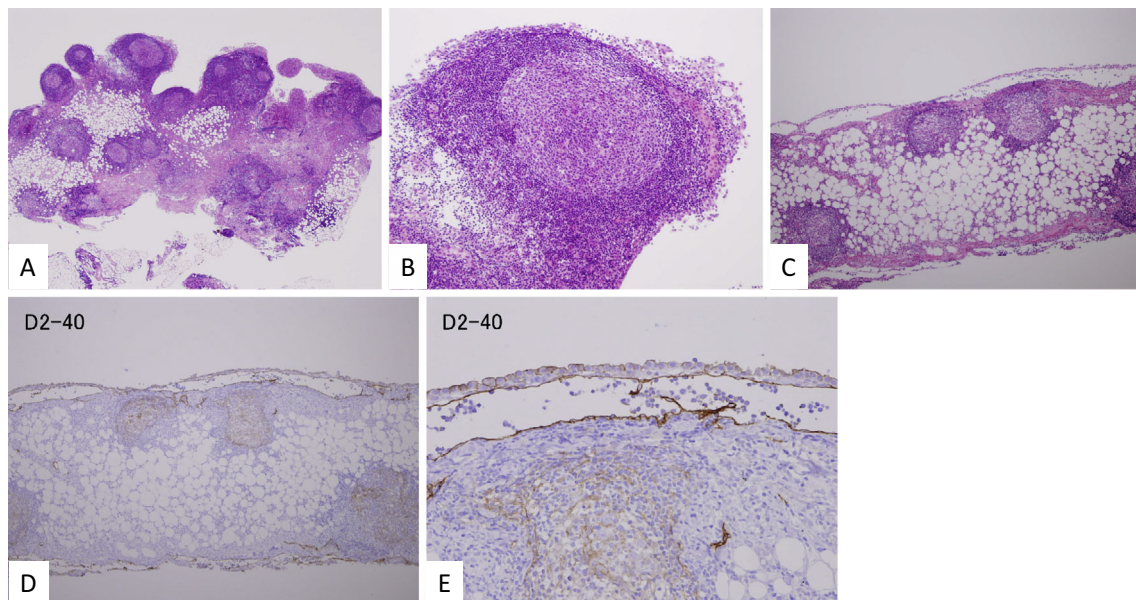


Figure 4. A histopathological examination of the parietal pleura demonstrating hyperplasia in lymphoid follicles exhibiting enlarged germinal centers and massive infiltration by plasmacytes and lymphocytes. The epithelioid cell layer was present as a membrane apart from the stroma (Hematoxylin and Eosin staining: A, ×10; B, ×100; C, ×20). Immunohistochemical staining for the lymphatic endothelial marker D2-40 showed that the lymphatic vessels in the subpleural area were dilated (D, ×20; E, ×100).

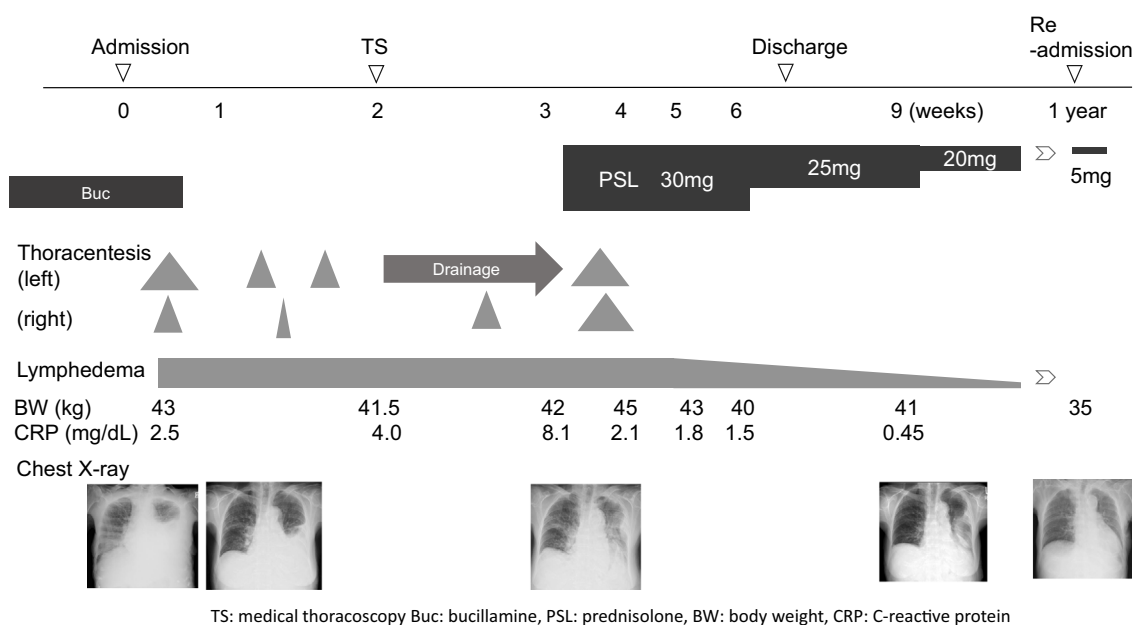


Figure 5. The clinical course of the case. The size of the gray triangle in the figure indicates the volume of pleural effusion.

discontinuing bucillamine should therefore return the yellowish nails to their normal color. Because pulmonary manifestations and lymphedema may not be treated by discontinuing bucillamine alone, other mechanisms have been suggested to explain the development of pleurisy (6).

Severe mononuclear cell infiltration with hyperplasia of the lymphoid follicles in the pleura was found in the present case, suggesting that RA-induced inflammation was involved in the development of the pleurisy. Lymphoid follicles in the pleura are ectopic lymphoid tissues and are induced by chronic inflammation, especially in cases of autoimmune disease, and chronic infection. In autoimmune diseases, ectopic well-formed lymphoid follicles are most commonly found in RA and Sjogren's syndrome, although ectopic lymphoid tissues, such as lymphoid aggregation, have been documented in other autoimmune diseases (7). In the present case, autoimmune diseases other than RA, chronic infection, and lymphoproliferative diseases were ruled out.

The results in our patient suggest that there were shared clinical and pathophysiological features between pleurisy and RA pleurisy based on the following three findings: first, the pathological findings in the pleura resembled those observed in RA-induced inflammation (e.g., mononuclear cell infiltration with lymphoid follicles); second, the pleurisy persisted after bucillamine was discontinued; and third, corticosteroids effectively treated the pleurisy. In addition, there was a previously reported case of YNS in a patient with RA in which no treatment was administered for RA that could have induced YNS, suggesting that there are shared mechanisms between YNS and RA (8). Furthermore, extra-articular inflammation often develops independent of arthritis activity (9). These data collectively suggest that bucillamine can cause inflammation with lymphoid follicles similar to those observed in RA and/or induce rheumatoid pleu-

risy itself.

The present case also showed marked lymphangiectasia in the pleura. Both YNS and RA are diseases with impaired lymphatic clearance (10). However, only a few studies of YNS patients have reported finding lymphangiectasia in pathological examinations of the visceral and parietal pleura (3) or the intestines (4), and no other pathological findings have been described (11). Because lymphangiectasia is induced by lymphoid follicles in Crohn's disease (12), we speculate that hyperplasia of the lymphoid follicles induces a downstream obstruction of the lymph flow, resulting in the dilatation of lymph vessels.

In our patient, corticosteroids effectively treated the pleural effusion in YNS, supporting the notion that RA-induced inflammation was involved in the development of pleurisy. There are no current treatment strategies for bucillamine-induced YNS. YNS pleurisy is often difficult to control, and many treatments have been applied with the aim of controlling pleural effusion. These include thoracentesis, pleuroperitoneal shunting, pleurovenous shunting, octreotide, vitamin E, and macrolides (13). Pleurodesis and decortication/pleurectomy appear to be the most effective treatments for YNS (14), but these invasive treatments have not been adequately adapted for use in elderly patients. We found no reports that explored the efficacy of corticosteroids for controlling idiopathic YNS. However, in cases of bucillamine-induced YNS, corticosteroid treatment may be an option when discontinuing bucillamine fails to improve the pleurisy.

We analyzed eight reported cases of bucillamine-induced YNS pleurisy, including the present one (Table) (6, 15-20). Rheumatoid pleurisy exhibits male dominance, even though there is female dominance in RA. Rheumatoid pleurisy patients also present with unilateral pleural effusion with exu-

Table. Reported Cases of Bucillamine-induced YNS Pleurisy.

No.	Age (y)	Sex	Pleural effusion					
			Bilateral or unilateral	Exdate/transdate	Glu (mg/dL)	ADA (IU/L)	RF (U/mL)	Lymphocyte (%)
1	46	F	Bilateral	Exdate	110	NA	39.7	NA
2	50	F	Unilateral	NA	NA	NA	NA	NA
3	71	F	Bilateral	Exdate	NA	NA	NA	NA
4	67	F	Unilateral	Exdate	105	24.8	<0.7	91
5	75	M	Bilateral	NA	NA	NA	NA	NA
6	81	M	Bilateral	Exdate	NA	NA	Low level	NA
7	80	F	Bilateral	Exdate	115	8.9	23.3	Lymphocyte dominant
8	86	F	Bilateral	Exdate	122/112*	25.5/25.1*	55/NA*	86.3/92.2*

Pathological examination of parietal pleura	Treatment before YNS	Duration of Buc (y)	Treatment for YNS		Efficacy of treatments		Reference
			Discontinuation of Buc	Other agents	Pleural effusion	Nail	
NA	Buc+MTX+PSL	6	Yes	Vit E	No	Improved	15
NA	Buc	1	Yes	SASP	Improved	Improved	16
NA	Buc	8	Yes	Vit E, Zn	No	Improved	17
NA	Buc	4	Yes	Vit E	No	No	18
NA	Buc	9	Yes	NA	No	Improved	6
Chronic inflammation	Buc	NA	NA	NA	NA	NA	19
Chronic fibrosing pleuritis	Buc+MTX	NA	No	CAM	Improved	Improved	20
Hyperplastic lymphoid follicles with massive infiltration of plasma cells and lymphocytes	Buc	2	Yes	PSL	Improved	Improved	Present case

*right/left. M: Male, F: Female, TP: total protein, ADA: adenocin deaminase, NA: not applicable, RF: rheumatoid factor, YNS: yellow nail syndrome, Buc: bucillamine, MTX: methotrexate, PSL: prednisolone, Vit E: vitamine E, SASP: salazosulfapyridine, Zn: zinc, CAM: clarithromycin

date, lymphocyte dominance, low glucose levels (21), and elevated levels of ADA (22) in the effusion. However, the eight cases of bucillamine-induced YNS we evaluated (Table) exhibited female dominance (6/8) and presented with bilateral pleural effusion (6/8), exudate with lymphocyte dominance (6/6), and normal glucose and ADA levels (3/3). The findings in the present case were consistent with those described in previous reports of bucillamine-induced YNS, regardless of the existence of lymphoid follicles in the pleura. While these findings suggest that there are clinical and histopathological similarities between bucillamine-induced YNS pleurisy and rheumatoid pleurisy, we also identified differences between these conditions in the clinical manifestations (laterality) and laboratory data associated with the pleural effusion (e.g., cell components and glucose and ADA levels).

In conclusion, our findings in the present case suggest that pleurisy in bucillamine-induced YNS may be associated with RA-induced inflammation in addition to abnormalities in lymphatic vessels. Hence, corticosteroids are a potential

treatment option for uncontrolled pleurisy associated with bucillamine-induced YNS.

The authors state that they have no Conflict of Interest (COI).

References

1. Bull RH, Fenton DA, Mortimer PS. Lymphatic function in the yellow nail syndrome. *Br J Dermatol* **134**: 307-312, 1996.
2. Bilen N, Bayramgurler D, Devge C, Basdas F, Yildiz F, Tore G. Lymphoscintigraphy in yellow nail syndrome. *Int J Dermatol* **37**: 444-446, 1998.
3. Solal-Celigny P, Cormier Y, Fournier M. The yellow nail syndrome. Light and electron microscopic aspects of the pleura. *Arch Pathol Lab Med* **107**: 183-185, 1983.
4. Duhra PM, Quigley EM, Marsh MN. Chylous ascites, intestinal lymphangiectasia and the 'yellow-nail' syndrome. *Gut* **26**: 1266-1269, 1985.
5. David-Vaudey E, Jamard B, Hermant C, Cantagrel A. Yellow nail syndrome in rheumatoid arthritis: a drug-induced disease? *Clin Rheumatol* **23**: 376-378, 2004.
6. Nakagomi D, Ikeda K, Hirotoishi K, Kobayashi Y, Suto A,

- Nakajima H. Bucillamine-induced yellow nail in Japanese patients with rheumatoid arthritis: two case reports and a review of 36 reported cases. *Rheumatol Int* **33**: 793-797, 2013.
7. Bombardieri M, Lewis M, Pitzalis C. Ectopic lymphoid neogenesis in rheumatic autoimmune diseases. *Nat Rev Rheumatol* **13**: 141-154, 2017.
 8. Mishra AK, George AA, George L. Yellow nail syndrome in rheumatoid arthritis: an aetiology beyond thiol drugs. *Oxf Med Case Reports* **2016**: 37-40, 2016.
 9. Okada H, Kurasawa K, Yamazaki R, et al. Clinical features of organizing pneumonia associated with rheumatoid arthritis. *Mod Rheumatol* **26**: 863-868, 2016.
 10. Jayson MI, Cavill I, Barks JS. Lymphatic clearance rates in rheumatoid arthritis. *Ann Rheum Dis* **30**: 638-639, 1971.
 11. Maldonado F, Tazelaar HD, Wang CW, Ryu JH. Yellow nail syndrome: analysis of 41 consecutive patients. *Chest* **134**: 375-381, 2008.
 12. Sura R, Colombel JF, Van Kruiningen HJ. Lymphatics, tertiary lymphoid organs and the granulomas of Crohn's disease: an immunohistochemical study. *Aliment Pharmacol Ther* **33**: 930-939, 2011.
 13. Kurin M, Wiesen J, Mehta AC. Yellow nail syndrome: a case report and review of treatment options. *Clin Respiratory J* **11**: 405-410, 2017.
 14. Valdes L, Huggins JT, Gude F, et al. Characteristics of patients with yellow nail syndrome and pleural effusion. *Respirology* **19**: 985-992, 2014.
 15. Nakatsue T, Cho D, Tanabe Y, Ito S, Nakano M, Gejo F. Yellow nail syndrome induced by bucillamine in a patient with pleural effusion, ascites, and elevation of tumor markers. *J Chubu Rheum Assoc* **32**: 46-47, 2001 (in Japanese).
 16. Iwahori Y, Honjo H, Honda K, et al. Two cases of yellow nail syndrome induced by bucillamine. *J Chubu Rheum Assoc* **32**: 44-45, 2001 (in Japanese).
 17. Chuujou S, Komura K, Kawara S. A case of yellow nail syndrome complicated with rheumatoid arthritis. *Hifuka No Rinsho* **46**: 907-909, 2004 (in Japanese).
 18. Isozaki T, Yajima N, Sato M, et al. A case of rheumatoid arthritis with bucillamine-induced yellow nail syndrome initially manifesting as pulmonary disease. *Clin Med Insights Case Rep* **3**: 63-68, 2010.
 19. Ariyoshi N, Nakamura A, Kashima M. Yellow nail syndrome. *Intern Med* **52**: 2833, 2013.
 20. Ro S, Ishii S, Hayashi Y, et al. Thoracoscopy under local anesthesia was useful for diagnosing yellow nail syndrome. *Intern Med* **55**: 975-980, 2016.
 21. Balbir-Gurman A, Yigla M, Nahir AM, Braun-Moscovici Y. Rheumatoid pleural effusion. *Semin Arthritis Rheum* **35**: 368-378, 2006.
 22. Ocana I, Ribera E, Martinez-Vazquez JM, et al. Adenosine deaminase activity in rheumatoid pleural effusion. *Ann Rheum Dis* **47**: 394-397, 1988.

The Internal Medicine is an Open Access article distributed under the Creative Commons Attribution-NonCommercial-NoDerivatives 4.0 International License. To view the details of this license, please visit (<https://creativecommons.org/licenses/by-nc-nd/4.0/>).