

## Bilateral Metachronous Breast Carcinoma: A Rare Case Report

### Abstract

The occurrence of bilateral breast cancer is rare. A second primary in the contralateral breast can either be synchronous or metachronous. Lobular carcinoma of the breast is known for its multicentricity and bilateral spread. The synchronous mixed pattern of carcinoma of the breast has also been reported in the same breast. The family history of breast carcinoma, estrogen receptor negativity, and human epidermal growth factor receptor-2 positivity are risk factors for the development of contralateral breast malignancy. In metachronous, bilateral breast cancer (MBBC) usually a single histological variant is seen at different time periods. However, we report a rare case of MBBC in a 66-year-old female patient with positive family history who had infiltrating lobular carcinoma (ILC) in the left breast followed by infiltrating ductal carcinoma in the right breast after a span of 2½ years, even after undergoing modified radical mastectomy with adjuvant chemotherapy followed by hormonal therapy for ILC of left breast.

**Keywords:** *Bilateral breast cancer, contralateral breast, infiltrating ductal carcinoma, infiltrating lobular carcinoma, metachronous, synchronous*

### Introduction

There has been an increase in incidence as well as the long-term survival of patients with breast cancer due to increase in life expectancy and improved management and prognosis. This has resulted in an increase in the incidence of patients with a second primary metachronous or synchronous breast cancer.<sup>[1]</sup> Of all the second primary malignancies in women, 30%–50% is represented by breast cancer. There is 2–6 times increase in the risk of developing a new primary cancer in the contralateral breast during the lifetime.<sup>[2]</sup>

In young patients, the relative risk of developing metachronous bilateral breast cancer (MBBC) is high. The risk of developing a contralateral primary breast cancer in patients with a history of previous breast cancer is about 5 times higher as compared to the occurrence of breast cancer in an unaffected individual.<sup>[3]</sup> The incidence of two separate primary breast cancer may be a result of a genetic predisposition, exposure to common environmental risk factors or an accumulation of two unrelated events.<sup>[4]</sup> We came across such a case where the patient after having been treated for infiltrating lobular carcinoma (ILC) and

infiltrating ductal carcinoma (IDC) with modified radical mastectomy (MRM), adjuvant chemotherapy, and still on hormonal therapy developed in the contralateral breast, that is, our patient developed histologically different carcinoma in the contralateral breast after treatment of the 1<sup>st</sup> primary breast carcinoma. Although there have been very few cases reported about synchronous bilateral breast carcinoma with different histopathological types,<sup>[5-7]</sup> we could not find even a single case about metachronous bilateral breast carcinoma with different histopathological type of breast cancer and that to after the patient had taken a 6 cycles of taxane-based adjuvant chemotherapy and was on hormonal therapy on presentation of second primary contralateral breast carcinoma. This is a very rare case report of its kind.

### Case Report

A 66-year-old female patient presented with a complaint of nonhealing ulcerative lesion over the left breast without any palpable lump. Fine-needle aspiration cytology done at a private laboratory reported chronic inflammation with abscess formation for which patient was referred to us. Excision biopsy was done which came out to be ILC of the left breast with estrogen receptor (ER) and progesterone

**Anand Singla,  
Navneet Kaur<sup>1</sup>,  
Darshanjeet Singh  
Walia,  
Deeksha Singla<sup>2</sup>**

*Departments of Surgery,  
<sup>1</sup>Pathology and <sup>2</sup>Pediatrics,  
GMC, Patiala, Punjab, India*

**Received:** 21 September, 2016.  
**Accepted:** 25 January, 2018.

*Address for correspondence:*  
*Dr. Anand Singla,*  
*Department of Surgery,*  
*GMC, Patiala, Punjab, India.*  
*E-mail: anand\_singla84@yahoo.*  
*co.in*

Access this article online

**Website:**  
www.ijabmr.org

**DOI:**  
10.4103/ijabmr.IJABMR\_384\_16

**Quick Response Code:**



**How to cite this article:** Singla A, Kaur N, Walia DS, Singla D. Bilateral metachronous breast carcinoma: A rare case report. *Int J App Basic Med Res* 2018;8:126-8.

This is an open access journal, and articles are distributed under the terms of the Creative Commons Attribution-NonCommercial-ShareAlike 4.0 License, which allows others to remix, tweak, and build upon the work non-commercially, as long as appropriate credit is given and the new creations are licensed under the identical terms.

**For reprints contact:** reprints@medknow.com

receptor (PR) weakly positive and human epidermal growth factor receptor 2 (HER 2)/neu negative. The patient was advised MRM which she refused and was put on the tablet Anastrozole.

After about a year, the patient again came to us with a complaint of a large breast lump. She was again advised surgery to which she agreed. Neoadjuvant radiotherapy was given to decrease the size of the tumor following which MRM with axillary clearance was done. Histopathology biopsy report came out to be ILC with axillary lymph node metastasis which was consistent with the earlier report of excision biopsy [Figure 1]. However, no distant metastases to the contralateral breast, liver, or lungs were present. The patient was treated with adjuvant chemotherapy on cyclophosphamide, doxorubicin, and fluorouracil regimen (6 cycles).

After a year and a half, the patient again presented with the complaint of a lump in the contralateral breast (right side) which was hard on palpation and fixed to the overlying skin. A provisional diagnosis of metastasis of invasive lobular carcinoma to the contralateral breast was made as ILC is known for its bilateral spread. MRM with axillary clearance was done. To our surprise, histopathology report came out to be IDC with axillary lymph node metastasis [Figure 2]. ER was strongly positive and PR was moderately positive, while HER 2/neu was negative. The patient is put on a taxane-based regimen of adjuvant chemotherapy consisting of intravenous docetaxel 75 mg/m<sup>2</sup>, doxorubicin 50 mg/m<sup>2</sup>, and cyclophosphamide 500 mg/m<sup>2</sup> every 21 days for 6 cycles. She is now doing well.

## Discussion

The chance that a patient with invasive breast carcinoma will develop a carcinoma in the contralateral breast is about 5 times that of the general population, and it is even higher if there is a family history of breast carcinoma. In case of lobular carcinoma, this figure can be as high as 25–30%.

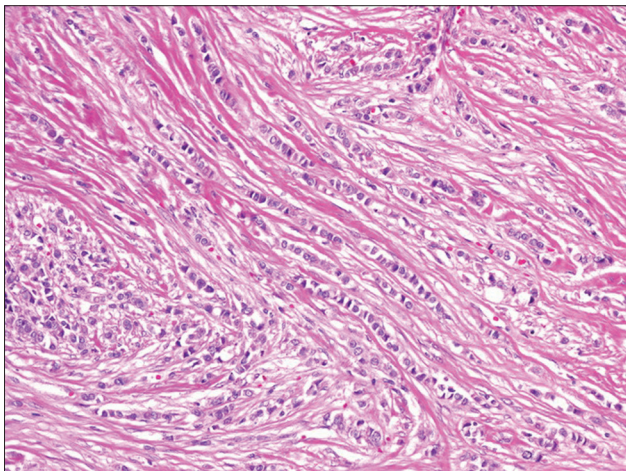


Figure 1: Indian file pattern in infiltrating lobular carcinoma in patient's left breast postmodified radical mastectomy (H and E, ×10)

The use of adjuvant chemotherapy significantly decreases the risk of metachronous contralateral breast carcinoma.

Etiology of bilateral breast carcinomas is not well understood; however, it appears that familial link is more likely with metachronous bilateral breast carcinomas than with unilateral and with synchronous bilateral breast carcinomas. In our patient, family history of breast carcinoma was present.

IDC is the most common type of invasive breast cancer, accounting for 65%–80% of invasive breast lesions.<sup>[8]</sup> Its characteristics have been well described, including the average age of onset, its rate of hormone receptor and erbB2 positivity, the frequency of nodal involvement, rates of metastatic spread and overall survival.<sup>[9]</sup> ILC represented the second most common subtype of mammary neoplasia, accounting for about 5%–10% of the disease.<sup>[10]</sup> The clinical behavior of ILC has been known to be different since its recognition as a distinct clinico-pathological entity.<sup>[11]</sup> Infiltration typically does not destroy anatomic structures or incite a substantial connective tissue response. By virtue of their distinctive growth pattern and biology, lobular carcinomas often fail to form distinct masses that cannot be easily diagnosed by palpation or mammography. This makes early diagnosis challenging<sup>[12]</sup> and breast conservation approaches more difficult. As found in our patient where no mass was palpable in the left breast, and she was being treated for inflammatory pathology before presenting to us. Excision biopsy diagnosed the condition as ILC.

Lobular carcinoma is known for bilateral spread and multicentricity. Metastases to distinct sites such as the meninges, serosa, and retroperitoneum are also known in ILC.<sup>[13]</sup> In our patient, occurrence of both IDC and ILC was seen at different times, that is, there was present ILC in the left breast [Figure 1] and opposite to the usual finding of bilateral spread there was IDC in the right breast [Figure 2] after a gap of a year and a half. Our patient's bilateral breast

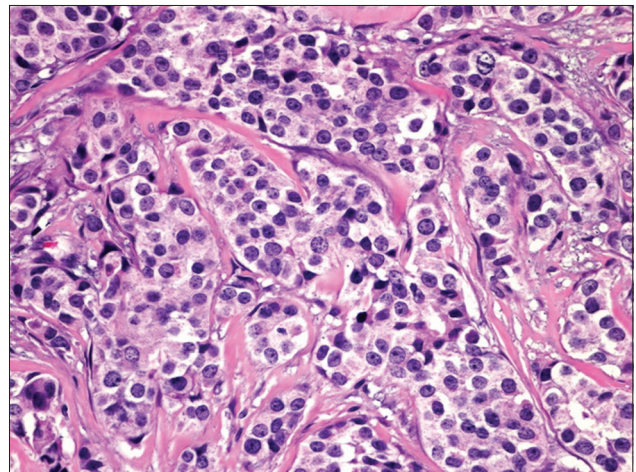


Figure 2: Large malignant ductal epithelial cells of infiltrating ductal carcinomas in patient's right breast postmodified radical mastectomy (H and E, ×40)

carcinoma was consistent with the definition of a MBBC, but with a separate histopathology. There are reports about the occurrence of mixed ductal and lobular carcinoma in the same breast, but in our case, there was the occurrence of IDC and ILC in contralateral breasts as a separate entity at different time periods. This is a rare case report of its kind.

#### Declaration of patient consent

The authors certify that they have obtained all appropriate patient consent forms. In the form the patient(s) has/have given his/her/their consent for his/her/their images and other clinical information to be reported in the journal. The patients understand that their names and initials will not be published and due efforts will be made to conceal their identity, but anonymity cannot be guaranteed.

#### Financial support and sponsorship

Nil.

#### Conflicts of interest

There are no conflicts of interest.

#### References

- Hartman M, Czene K, Reilly M, Adolfsson J, Bergh J, Adami HO, *et al.* Incidence and prognosis of synchronous and metachronous bilateral breast cancer. *J Clin Oncol* 2007;25:4210-6.
- Chaudary MA, Millis RR, Hoskins EO, Halder M, Bulbrook RD, Cuzick J, *et al.* Bilateral primary breast cancer: A prospective study of disease incidence. *Br J Surg* 1984;71:711-4.
- Vaitinen P, Hemminki K. Risk factors and age-incidence relationships for contralateral breast cancer. *Int J Cancer* 2000;88:998-1002.
- Dawson PJ, Maloney T, Gimotty P, Juneau P, Ownby H, Wolman SR, *et al.* Bilateral breast cancer: One disease or two? *Breast Cancer Res Treat* 1991;19:233-44.
- Dalal AK, Gupta A, Singal R, Dalal U, Attri AK, Jain P, *et al.* Bilateral breast carcinoma- a rare case report. *J Med Life* 2011;4:94-6.
- Kappikeri VK, Kriplani AM. Bilateral synchronous carcinoma breast- a rare case presentation. *Springerplus* 2015;4:193.
- Barvi G, Banerjee M, Mukherjee S, Das TK. An interesting case of primary Bilateral Synchronous breast carcinoma with mucinous carcinoma in one. *NJLM* 2016;5:7-9.
- Rosen PP. The pathological classification of human mammary carcinoma: Past, present and future. *Ann Clin Lab Sci* 1979;9:144-56.
- Wood WC, Muss HB, Solin LJ, Olopade OI. Malignant tumors of the breast. In: DeVita VT, Hellman S, Rosenberg S, editors. *Cancer: Principles and Practice of Oncology*. Ch. 33. Philadelphia: Lippincott, Williams and Wilkins; 2005. p. 1415-77.
- Sastre-Garau X, Jouve M, Asselain B, Vincent-Salomon A, Beuzeboc P, Dorval T, *et al.* Infiltrating lobular carcinoma of the breast. Clinicopathologic analysis of 975 cases with reference to data on conservative therapy and metastatic patterns. *Cancer* 1996;77:113-20.
- Dixon JM, Anderson TJ, Page DL, Lee D, Duffy SW. Infiltrating lobular carcinoma of the breast. *Histopathology* 1982;6:149-61.
- Kreke KN, Gissvold JJ. Invasive lobular carcinoma of the breast: Mammographic findings and extent of disease at diagnosis in 184 patients. *AJR Am J Roentgenol* 1993;161:957-60.
- Lesser ML, Rosen PP, Kinne DW. Multicentricity and bilaterality in invasive breast carcinoma. *Surgery* 1982;91:234-40.