

Difficulties in cerebrospinal fluid β hCG interpretation in a patient with an infundibular lesion

Alicia R Jones¹, Alan McNeil², Christopher Yates^{1,3}, Bala Krishnamurthy^{1,4} and Peter S Hamblin^{1,5}

¹Department of Endocrinology and Diabetes, Western Health, St Albans, Victoria, Australia, ²Dorevitch Pathology, Heidelberg, Victoria, Australia, ³Department of Medicine, The University of Melbourne (Royal Melbourne Hospital), Parkville, Victoria, Australia, ⁴Department of Medicine, The University of Melbourne (St. Vincent's Hospital), Fitzroy, Victoria, Australia, and ⁵Department of Medicine, The University of Melbourne (Western Campus), St Albans, Victoria, Australia

Correspondence
should be addressed
to A R Jones

Email
aliciarose86@gmail.com

Summary

A variety of neoplastic, inflammatory and congenital conditions can cause pituitary stalk thickening. Differentiating between these causes is important as targeted treatment may be offered. Diagnostic work-up consists of a thorough history, examination, biochemical analysis and imaging. We present the case of a 33-year-old male who presented with diabetes insipidus and had pituitary stalk thickening on magnetic resonance imaging. Further investigations revealed an elevated CSF β hCG, which raised the possibility of an intracranial germ cell tumor. However, when repeated on four different assays, the β hCG levels were discordant. On serial imaging, the pituitary stalk thickening reduced slightly, which would be unexpected for a germ cell tumor. This case raises the difficulties interpreting CSF β hCG, as not all immunoassays for β hCG have been validated for use in CSF. The Roche Diagnostics Elecsys and Siemens Centaur assays have been validated for CSF β hCG, and so we advocate using one of these methods. If unavailable or serum/CSF results are ambiguous, serial MRI is appropriate, with pituitary stalk biopsy considered if the stalk measures >6.5 mm or other imaging abnormalities are present.

Learning points:

- Most adult patients with central diabetes insipidus have imaging abnormalities on a pituitary MRI. The most common abnormalities are loss of the posterior pituitary bright spot and pituitary stalk thickening, both of which are non-specific.
- Causes of pituitary stalk thickening include neoplastic, inflammatory, infective and congenital lesions.
- Investigation of pituitary stalk thickening should encompass the many possible causes and include biochemical analyses as well as imaging of the chest, abdomen and pelvis. Further investigations should be guided by the clinical context, but may include testicular ultrasound, CSF analysis and pituitary stalk biopsy.
- Germ cell tumors involving the pituitary stalk may be suspected on clinical grounds, but in the absence of a tissue diagnosis (biopsy) confirmation may be difficult and relies on biochemical assessment of blood and possibly CSF as well as serial MRI imaging.
- CSF β hCG levels should be analyzed on an instrument validated for use in CSF or on multiple instruments, and the pitfalls of testing this marker (false negative in some germ cell tumors, false positives in other conditions, lack of internationally agreed reference ranges for diagnosing germ cell tumors) should be considered when interpreting the results.

Background

The majority of adult patients with central diabetes insipidus (DI) have abnormalities on pituitary magnetic resonance imaging (MRI), with loss of the posterior pituitary high-intensity signal and pituitary stalk thickening being most common (1). The differential diagnoses for infundibulum lesions is broad, and thorough investigations are required to identify a cause, which may be treated with targeted therapies. Cerebrospinal fluid (CSF) analysis of the tumor markers β -human chorionic gonadotrophin (β hCG) and alpha-fetoprotein (α FP) is indicated in certain circumstances; however, it is important to recognize that not all immunoassays have been validated for use in CSF.

Case presentation

A 33-year-old male originally from Brunei presented with acute onset of polydipsia and polyuria. He was consuming 10–12 liters of fluid daily and passing urine hourly overnight. There was no prodrome, no systemic symptoms and normal energy levels and libido. Past history included a left occipital meningioma removed at 17 years of age. He took no regular medications, was a non-smoker and consumed minimal alcohol. There was no personal or family history of connective tissue disorders or malignancy. He had migrated to Australia ten years previously, and immigration health examination, including tuberculosis testing, was normal. He lived with his wife, had no children and worked full-time as a chef.

On examination, he had an elevated body mass index of 30.7, minimal facial hair but Tanner Stage V pubic hair and genital development, a normal adult male voice and reduced testicular volume of 10 mL bilaterally with no palpable masses. Visual fields, cranial and peripheral neurological examinations, were normal. There were no cutaneous features to suggest sarcoidosis (erythema nodosum, cutaneous papules, nodules or plaques), and no enlarged lymph nodes or organomegaly.

Investigation

Initial investigations revealed an elevated serum sodium of 147 mmol/L (reference: 135–145), a raised serum osmolality of 307 mosmol/kg (reference: 278–298) and dilute urine (urine osmol 82 mosmol/kg). A water deprivation test was consistent with central DI. Biochemistry, renal and liver function and full blood examination were normal.

Table 1 Anterior pituitary function results.

	Result	Adult male reference range
FSH (IU/L)	<1	1–10
LH (IU/L)	<1	1–10
Testosterone (nmol/L)	1.3	10–35
Prolactin (IU/L)	182	45–375
Early morning cortisol (nmol/L)	335	145–619
ACTH (pmol/L)	4.2	<20
GH (IU/L)	<1	<7
IGF-1 (nmol/L)	13	11–32
TSH (IU/L)	1.12	0.5–4
T4 (pmol/L)	14.6	10–19

ACTH, adrenocorticotrophic hormone; FSH, follicular-stimulating hormone; GH, growth hormone; IGF-1, insulin-like growth factor 1; LH, luteinizing hormone; T4, thyroxine; TSH, thyroid-stimulating hormone.

Additional investigations revealed hypogonadotrophic hypogonadism with otherwise intact anterior pituitary function (Table 1). MRI of the pituitary demonstrated an enhancing, bulbous thickened pituitary stalk with a maximal diameter of 6.2 mm and minor indentation of the inferior optic chiasm (Fig. 1A and B). There was no leptomeningeal, dural or cranial nerve enhancement suggestive of CNS lymphoma, neurosarcoidosis or tuberculosis, and no

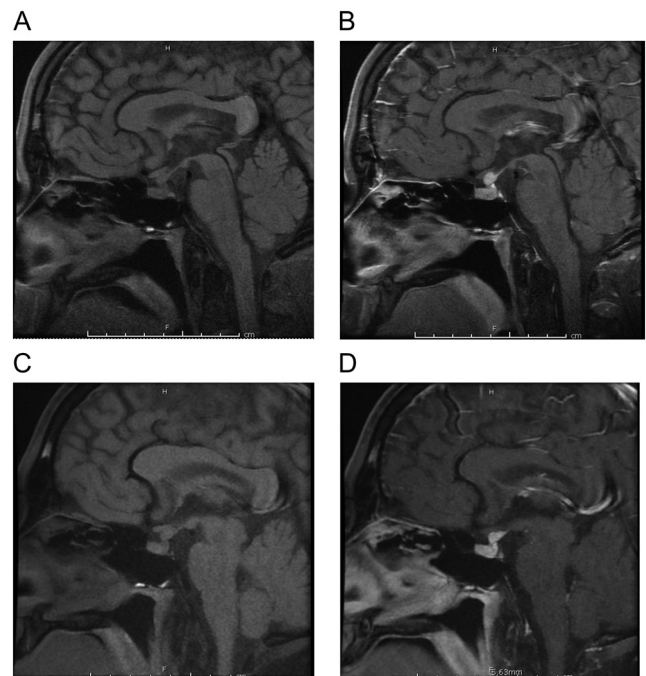


Figure 1 MRI brain. (A) Pre- and (B) post-contrast sagittal MRI brain at diagnosis showing thickened, bulbous enhancement of the pituitary stalk which measures 6.2 × 6.0 × 6.2 mm (AP, trans, SI), (C) pre- and (D) post-contrast sagittal MRI brain 6 months after diagnosis, showing reduction in size of the pituitary stalk, now measuring 4.4 × 4.9 × 5.5 mm.



Table 2 Specific investigations for the cause of pituitary stalk thickening.

	Result	Adult male reference range
Serum β hCG (IU/L)	<2	<2
Serum α -FP (μ g/L)	2	<10
PSA (μ g/L)	0.44	\leq 2.5
LD (U/L)	401	240–480
β -2 microglobulin (mg/L)	1.5	\leq 2
HIV antibody/antigen	Not detected	Not detected
IgG4 (g/L)	0.13	0.04–0.86
ACE (U/L)	28.0	20.0–70.0
Vitamin D (nmol/L)	60	>50
1,25-Dihydroxyvitamin D (pmol/L)	112	50–190
24-h urinary calcium	3.4 mmol/24 h	2.0–7.5
CRP (mg/L)	<1	\leq 10
ESR (mm/h)	5	<15
ANCA	Negative	Negative
Quantiferon Gold	Latent infection unlikely	
Chest X-ray	Normal	
Testicular ultrasound	Reduced testicular volume (8.3 on right and 8.5 mL on left) and vascularity, no lesions	
CT chest, abdomen, pelvis	Normal	

α -FP, alpha-fetoprotein; β hCG, human chorionic gonadotrophin; ACE, angiotensin converting enzyme; ANCA, antineutrophil cytoplasmic antibody; CRP, C-reactive protein; ESR, erythrocyte sedimentation rate; HIV, human immunodeficiency virus; IgG4, immunoglobulin G subtype 4; LD, lactate dehydrogenase; PSA, prostate specific antigen.

parenchymal lesion to suggest either these diagnoses or solid organ metastases. There was no osseous lesion suggestive of Langerhans cell histiocytosis (punched out lytic lesions or ‘geographic skull’ on CT, hypointense T1 or gadolinium enhancing lesions on MRI). There was no pineal calcification to suggest intracranial germ cell tumor (GCT); however, other features of GCT on MRI are not specific (2).

Initial investigations to establish the cause of pituitary stalk thickening, including a computed tomography of the chest, abdomen and pelvis, and testicular ultrasound, were unremarkable (Table 2). Serum tumors markers were normal, including β hCG <2IU/L (reference <2) and α FP 2 μ g/L (reference <10). Quantiferon Gold suggested latent tuberculosis was unlikely.

Given the bulbous appearance of the pituitary stalk on MRI, with no clear diagnosis, the decision was made to perform lumbar puncture for GCT markers (β hCG, α FP), tuberculosis and flow cytometry. This revealed an elevated β hCG level of 11.4IU/L (reference <10), with an undetectable α FP level. Gram stain, culture, protein, glucose, cytology, flow cytometry and tuberculosis testing of the CSF were all within normal parameters.

The results of the CSF β hCG raised the possibility of an intracranial GCT. However, the reference range for CSF β hCG has not been well defined. Given the implications of therapy for a GCT, a decision was made

to repeat the lumbar puncture prior to considering a pituitary stalk biopsy. Repeat CSF β hCG levels were then performed on various assay instruments and are displayed in Table 3.

Treatment

Our patient was treated with intranasal desmopressin 10 μ g BD with resolution of DI symptoms and was commenced on testosterone transdermal gel. Due to the discordant results of the CSF β hCG levels depending on the assay used, a decision was made to continue monitoring with serial MRI scans. Pituitary stalk biopsy was deferred until there was evidence of progressive stalk thickening.

Outcome and follow-up

Serial pituitary MRIs performed every two months over a period of six months showed mild reduction in size of the pituitary stalk, from the original size of 6.2 \times 6.0 \times 6.2 mm (AP, trans, SI) to 4.4 \times 4.9 \times 5.5 mm (Fig. 1C and D). An intracranial GCT was considered less likely based on this, and, based on the absence of features suggesting any alternative cause, a presumptive diagnosis of lymphocytic hypophysitis was made. His DI is persistent and anterior pituitary function remains unchanged.



Table 3 Levels of β hCG in CSF using various immunoassay platform and reference intervals for immunoassay.

Assay platform	First lumbar puncture β hCG (IU/L)	Second lumbar puncture β hCG (IU/L)	CSF reference interval (IU/L)
Siemens Centaur	11	10	<10
Roche Cobas	Not done	<0.01	<0.70
Beckman Access	Not done	0.52	None available
Abbott Architect	Not done	<1.2	None available

We plan to monitor his MRI pituitary, pituitary function tests and serum tumor markers every 6 months initially.

Discussion

Our patient presented with typical symptoms of DI and had classical findings on pituitary MRI. A thickened pituitary stalk can be due to neoplastic, inflammatory or congenital causes (Table 4). The prevalence of etiology differs considerably between reports (3).

Differentiating between causes requires thorough evaluation. Key features on history include personal and family history of malignancy, connective tissue and autoimmune conditions, constitutional symptoms, respiratory symptoms, travel history and recent

pregnancy. Examination should focus on signs of hypopituitarism, cranial nerve deficits, cutaneous changes consistent with sarcoidosis and lymphadenopathy or hepatosplenomegaly, which may suggest malignancy. Initial investigations should encompass the most common causes, with additional specific or invasive investigations based on the clinical picture (Table 4).

Investigations should also assess pituitary dysfunction, which may result from pituitary stalk thickening. The pituitary stalk transmits vasopressin and oxytocin between the hypothalamus and posterior pituitary, stimulatory hormones to the anterior pituitary and inhibitory factors for prolactin release. Interruption can therefore result in DI, hypopituitarism and hyperprolactinaemia. Studies have demonstrated that 28% of patients with infundibulum lesions have clinical DI, and 32% have at least one anterior pituitary hormone deficit, most commonly hypogonadotrophic hypogonadism, as in our case (2).

In this patient, initial investigations did not reveal a diagnosis, and there were no extra-cranial sites to biopsy. CSF analysis should be considered in these patients who are suspected to have, or with risk factors for, central nervous system (CNS) lymphoma, CNS tuberculosis, or intracranial GCT with normal serum α FP and β hCG and a normal testicular ultrasound (3).

Table 4 Causes of, and investigations for, the different causes of pituitary stalk thickening.

Category	Cause	Initial investigations	Additional investigations
Neoplastic	Germ cell tumor	Serum β hCG, α -FP	Testicular US, CSF β hCG and α -FP
	Solid organ metastases (breast, renal, lung, prostate)	CT Chest/abdomen/pelvis	CEA, Ca125, Ca19.9, PSA
	CNS lymphoma	LDH, β -2 microglobulin	HIV screening CSF cytology Bone marrow aspirate and trephine
Inflammatory/infective	Lymphocytic hypophysitis	IgG4	
	Neurosarcoidosis	Calcium, vitamin D, ACE, CXR, 1,25-dihydroxyvitamin D, 24 h urinary calcium	
	Langerhans cell histiocytosis		Whole body bone scan, skeletal survey
	Granulomatosis with polyangitis Tuberculosis	CRP, ESR, cANCA	Quantiferon Gold CSF acid fast bacilli CSF <i>Tropheryma whipplei</i>
Congenital	Whipple's disease		
	Pituitary hypoplasia Pituitary stalk interruption syndrome Septooptic dysplasia		

α -FP, alpha-fetoprotein; ACE, angiotensin-converting enzyme; ANCA, antineutrophil cytoplasmic antibody; Ca125, cancer antigen 125; Ca19.9, cancer antigen 19.9; CEA, carcinoembryonic antigen; CNS, central nervous system; CRP, C-reactive protein; CSF, cerebrospinal fluid; CT, computed tomography; CXR, chest X-ray; ESR, erythrocyte sedimentation rate; hCG, human chorionic gonadotrophin; HIV, human immunodeficiency virus; IgG4, immunoglobulin G version 4; LDH, lactate dehydrogenase; PSA, prostate specific antigen; US, ultrasound.

Non-germinomatous and mixed GCT secrete large amounts of α FP and β hCG; however, pure germinomas may be non-secretory or secrete only low levels of β hCG. The sensitivity and specificity for serum β hCG for diagnosis of GCT varies by cellular type, location (gonadal or extra-gonadal) and stage of disease, but is poor for isolated intracranial tumors (3, 4). Elevated serum levels occur in other malignancies, tumor lysis syndrome, primary hypogonadism and precocious puberty. Elevated CSF levels occur in pituitary adenomas, craniopharyngiomas, arachnoidal cysts and Langerhans cell histiocytosis (5).

Unfortunately, not all immunoassays for β hCG have been validated for use in CSF, which can make interpretation difficult. Validations of β hCG in CSF using the Roche Diagnostics Elecsys and Siemens Centaur assays have been published (6, 7). Other assays may give no reference range or use serum reference intervals as a guide. Given the marked differences between serum and CSF detection limits found on those assays that have been studied in CSF, this is inappropriate.

A validation should include a recovery experiment, reproducibility and the range of values found in healthy individuals as minimum. Ideally, it should also include patients with GCT and other pathologies, to calculate sensitivity and specificity, and a measure of stability and interfering factors. The Roche Diagnostics Elecsys assay for CSF β hCG is stable at any temperature for up to 7 days, and does not appear to be influenced by haemolysis or xanthochromia; however, similar studies of stability were not performed on the Centaur assay (6). Neither study included sufficient patients with GCT to calculate specificity or sensitivity.

The initial CSF β hCG result of 11.4IU/L in this patient was processed on the Siemens Centaur immunoassay. Mitsios and colleagues evaluated this method for CSF and reported a limit of blank (LoB) of 7.6IU/L, limit of detection (LoD) of 9.5IU/L and limit of quantitation (LoQ) of 10IU/L (7). This means that in a specimen containing no β hCG, the reported level may be up to 7.6IU/L, and the test is unable to reliably differentiate this value from 9.5IU/L. Standard laboratory practice is to only report values above the LoQ, lower values being reported as '<10IU/L'. Hu and colleagues attempted to calculate the sensitivity and specificity of CSF β hCG using the Centaur assay on 58 patients with pathologically confirmed intracranial GCT, 12 patients with Langerhans cell histiocytosis and 5 with other intracranial tumors. They demonstrated that a CSF β hCG of ≥ 8.2 IU/L had a sensitivity of 47% and

specificity of 100% for intracranial GCT (5). However, the authors report the LoD of the assay as 2IU/L, which is the serum not CSF LoD. The final value of 8.2IU/L is below the LoQ of the assay in CSF, and thus, cannot be reliably used in practice.

Guidelines on the management of intracranial GCT, produced by a panel of experts from the third International Intracranial Germ Cell Tumour symposium in 2013, state that GCT may be diagnosed on the basis of CSF β hCG alone, without histological confirmation, if levels are above nationally defined protocol thresholds (8). However, they acknowledge that thresholds for CSF β hCG differ worldwide (>25–100IU/L) and do not recommend any particular immunoassay or diagnostic cut-off. Marginal elevations are inadequate alone for diagnosis, and so a pituitary stalk biopsy would be required in our patient for definitive diagnosis.

Pituitary stalk biopsy is invasive and requires specialty neurosurgical expertise and should only be performed if there is no alternative site available for biopsy. It carries a risk of meningitis, CSF leak and permanent panhypopituitarism (3). Neurological complications are rare in lesions isolated to the pituitary stalk.

There is no consensus on the indications for pituitary stalk biopsy. Jian and coworkers reviewed 37 patients with DI and pituitary stalk thickening on imaging (9). Of idiopathic causes, no patients had pituitary stalk thickening of >6.5 mm, whereas all cases of GCT were either >6.5 mm or developed other abnormalities, and only one case of histiocytosis remained <6.5 mm, at the end of follow-up. A suggested approach therefore is to perform pituitary stalk biopsy if the stalk is above 6.5 mm in size initially or on serial imaging. The authors suggested monitoring for 2 years, as this was the median time for progression; however, a more conservative approach would be to monitor up to 4 years, the upper range for progression.

The majority of intracranial GCT present at 10–21 years of age, with a peak incidence around puberty and higher rates in males and Asian countries (4). One-third of patients with germinomas are asymptomatic for six months or more; however, non-germinomatous tumors have a shorter prodrome. They usually affect the midline (suprasellar cistern, pineal gland, fourth ventricle, basal ganglia), but may spread to the hypothalamus and third ventricle or metastasize to the spinal cord, lung or bone. Prognosis varies by cell type – germinomas are exquisitely radiosensitive and five-year survival rates are >90%, whereas non-germinomatous tumors have a poorer prognosis and require combination chemoradiotherapy (4).



Based on our initial CSF β hCG result, pituitary stalk biopsy was considered; however, the discordant results on repeat testing made us defer this. Serial imaging showed a slight reduction in size, which would be unexpected for a GCT, and so a presumptive diagnosis of lymphocytic hypophysitis was made. Lymphocytic hypophysitis is an inflammatory condition, with infiltration of the pituitary with lymphocytes, and eventual fibrosis. It is more common in females particularly during pregnancy or post-partum, is associated with autoimmune conditions and may be caused by immunotherapy (CTLA4 inhibitors, PD-1 inhibitors) (10). MRI shows uniform enhancement without other features (2). There are no consensus guidelines on management, and although glucocorticoids may be used, spontaneous resolution is also documented (10). Studies of glucocorticoids are limited by low numbers and short duration of follow-up. Given our patient had some reduction in the size of pituitary thickening without active treatment the decision was made not to use glucocorticoids.

Given we have been monitoring our patient for only six months, we cannot definitively exclude a GCT, as new changes may develop over years. However, it would be rare to see a reduction in the pituitary stalk size without treatment for GCT, and so we feel this is less likely. It is important to note that our patient avoided an invasive procedure after the CSF β hCG was repeated using different assays, and as such we would advocate testing CSF tumor markers using more than one analyzer, particularly in the absence of other clinical, biochemical or radiological signs of GCT.

In conclusion, pituitary stalk thickening has multiple causes and requires thorough investigation. In the absence of a diagnosis, and in the right clinical circumstances, CSF analysis should be performed; however, interpretation of results requires knowledge of the specific assays used and validated reference intervals for this. Pituitary stalk biopsy should be considered where the stalk measures >6.5 mm or other imaging abnormalities are present and sufficient neurosurgical expertise is available.

Declaration of interest

The authors declare that there is no conflict of interest that could be perceived as prejudicing the impartiality of the research reported.

Funding

This research did not receive any specific grant from any funding agency in the public, commercial or not-for-profit sector.

Patient consent

Written informed consent has been obtained from the patient for publication of this article and accompanying images.

Author contribution statement

All co-authors were involved in the care of the patient as an inpatient or outpatient. All authors were involved in writing up the case report.

References

- 1 Tien R, Kucharczyk J & Kucharczyk W. MR imaging of the brain in patients with diabetes insipidus. *American Journal of Neuroradiology* 1991 **12** 533–542.
- 2 Turcu AF, Erickson BJ, Lin E, Guadalix S, Schwartz K, Scheithauer BW, Atkinson JLD & Young WF. Pituitary stalk lesions: the Mayo Clinic experience. *Journal of Clinical Endocrinology and Metabolism* 2013 **5** 1812–1818. (<https://doi.org/10.1210/jc.2012-4171>)
- 3 Catford S, Wang YY & Wong R. Pituitary stalk lesions: systematic review and clinical guidance. *Clinical Endocrinology* 2016 **85** 507–521. (<https://doi.org/10.1111/cen.13058>)
- 4 Packer RJ, Cohen BH & Coney K. Intracranial germ cell tumours. *Oncologist* 2000 **5** 312–320.
- 5 Hu M, Guan H, Lau CC, Terashima K, Jin Z, Cui L, Wand Y, Li G, Yao Y, Guo Y, *et al.* An update on the clinical diagnostic value of β -hCG and α FP for intracranial germ cell tumours. *European Journal of Medical Research* 2016 **21** 10. (<https://doi.org/10.1186/s40001-016-0204-2>)
- 6 Shajani-Yi Z, Martin IW, Brunelle AA & Cervinski MA. Method validation of human chorionic gonadotrophin and α -fetoprotein in cerebrospinal fluid: aiding the diagnosis of intracranial germ cell tumours. *Journal of Applied Laboratory Medicine* 2017 **2** 65–75. (<https://doi.org/10.1373/jalm.2016.022822>)
- 7 Mitsios JV, McClellan A, Brown S & Gronowski AM. Human chorionic gonadotrophin and α -fetoprotein in cerebral spinal fluid: method validation and retrospective review. *Clinical Biochemistry* 2014 **47** 632–635. (<https://doi.org/10.1016/j.clinbiochem.2014.01.008>)
- 8 Murray MJ, Bartels U, Nishiwaka R, Fangusaro J, Matsutani M & Nicholson JC. Consensus on the management of intracranial germ-cell tumours. *Lancet Oncology* 2015 **16** e470–e477. ([https://doi.org/10.1016/S1470-2045\(15\)00244-2](https://doi.org/10.1016/S1470-2045(15)00244-2))
- 9 Jian F, Bian L, Sun S, Yang J, Chen X, Chen Y, Ma Q, Miao F, Wang W, Ning G, *et al.* Surgical biopsies in patients with central diabetes insipidus and thickened pituitary stalks. *Endocrine* 2014 **47** 325–335. (<https://doi.org/10.1007/s12020-014-0184-3>)
- 10 Faje A. Hypophysitis: evaluation and management. *Clinical Diabetes and Endocrinology* 2016 **2** 15. (<https://doi.org/10.1186/s40842-016-0034-8>)

Received in final form 15 January 2018

Accepted 1 February 2018