

A combined study of ^{18}F -FDG PET-CT and fMRI for assessing resting cerebral function in patients with major depressive disorder

CHANG FU¹, HONGJU ZHANG², ANG XUAN¹, YONGJU GAO¹, JUNLING XU¹ and DAPENG SHI³

Departments of ¹Nuclear Medicine, ²Neurology and ³Radiology, Zhengzhou University People's Hospital, Zhengzhou, Henan 450000, P.R. China

Received November 30, 2017; Accepted May 4, 2018

DOI: 10.3892/etm.2018.6434

Abstract. The present study investigated changes in the regional cerebral metabolic rates of glucose uptake (rCMRglc) using ^{18}F -fluorodeoxyglucose (^{18}F -FDG) positron emission tomography (PET) and regional homogeneity (ReHo), together with resting-state blood oxygen level-dependent (BOLD) functional magnetic resonance imaging (fMRI), in patients with major depressive disorder (MDD). In total, 18 patients with untreated MDD and 17 healthy control subjects underwent ^{18}F -FDG PET and BOLD-fMRI scanning. The MDD patients' cerebral changes, measured as rCMRglc and ReHo values, were mapped and statistically analyzed. Compared with the control group, the patients with MDD had a decreased rCMRglc in the bilateral superior, middle and inferior frontal gyrus, in the bilateral superior and middle temporal gyrus, in the bilateral anterior cingulate cortex, in the bilateral putamen and caudate, and in the left pallidum, but an increased rCMRglc in the bilateral hippocampus and left thalamus. The ReHo values in the patient group were decreased in the bilateral superior and middle frontal gyrus, left pallidum, bilateral putamen and left anterior cingulate cortex, but increased in the right hippocampus and thalamus. No statistically significant differences were identified between decreased metabolism and ReHo brain regions of MDD patients ($\chi^2=9.16$; $P=0.90$) and between increased metabolism and ReHo brain regions ($\chi^2=3.96$; $P=0.27$), when comparing activated brain regions of PET and MRI. The standardized uptake values (SUV) of the bilateral superior, middle and inferior frontal gyrus, bilateral superior and middle temporal gyrus, bilateral putamen, the

left caudate and pallidum, the left anterior cingulate cortex, and the bilateral hippocampus and thalamus were correlated with the ReHo ($r=0.51-0.83$; $P<0.05$). However, no correlation was detected between the SUV and ReHo in the right caudate and anterior cingulate cortex ($r=0.41$ and 0.37 , respectively; $P>0.05$). Taken together, these results demonstrated that patients with MDD displayed characteristic patterns regarding changes of brain glucose uptake and ReHo in the resting state. Furthermore, ^{18}F -FDG PET may be a more sensitive technique compared with BOLD-fMRI for the identification of brain lesions in patients with MDD.

Introduction

Depression is a mental disorder that poses a serious threat to the physical and mental health of affected patients. However, its etiology and pathogenesis remain to be fully elucidated (1). Based on previous research, certain hypotheses regarding the neurobiological mechanisms associated with depression have been proposed, including the central monoamine neurotransmitter dysfunction hypothesis, the neurotransmitter receptor hypothesis and the neurokinin hypothesis (2-4). The occurrence of clinical depression has been reported to be associated with neurobiological defects in affected patients (5-7). Certain aspects, including whether various cognitive impairment states may be caused by abnormalities in localized brain function, and whether these abnormalities differ between these states, are questions that may now be addressed using functional molecular imaging techniques.

^{18}F -fluorodeoxyglucose (^{18}F -FDG) positron emission tomography (PET) is a commonly used molecular imaging method for studying brain metabolism (8). ^{18}F -FDG may be transported into the human brain through the blood-brain barrier, and subsequently participates in the steps of glucose metabolism within brain cells (9). Therefore, ^{18}F -FDG PET imaging may be used to analyze the regional cerebral metabolic rate of glucose uptake (rCMRglc) to evaluate the activity of neurons (10,11). Blood oxygen level-dependent functional magnetic resonance imaging (BOLD-fMRI) has been used to study brain functional disease for several years (12). Resting-state BOLD-fMRI is a valuable means of analyzing human brain function (13). Methods for processing large

Correspondence to: Dr Dapeng Shi, Department of Radiology, Zhengzhou University People's Hospital, 7 Weiwu Road, Zhengzhou, Henan 450000, P.R. China
E-mail: episodede@sina.com

Key words: major depressive disorder, regional cerebral metabolic rate of glucose uptake, positron emission tomography, ^{18}F -fluorodeoxyglucose, functional magnetic resonance imaging, regional homogeneity

quantities of data obtained by BOLD-fMRI have arisen at an opportune moment (14). Two types, which are relatively simple and are used most frequently in clinical applications, are the regional activity characteristic analysis method and the linear correlation analysis method (15,16). The first of these methods is associated with regional homogeneity (ReHo) (16) and amplitude of low-frequency fluctuation (ALFF) (17), whereas the latter method is associated with functional connection (FC) (18). The present study focused on investigating the regional activity in the brains of patients with MDD. Since ALFF directly analyzes the oscillation amplitude of the BOLD signal, its advantage is that it uses all frequency domain information, but the disadvantage is that it only focuses on frequency domain information; at the same time, oscillations of cooperation between different areas in the human brain are always dependent on time synchronization. By contrast, ReHo reflects each individual voxel of the whole brain and its 26 neighboring individual time series of synchronicity, and thus represents a complete analysis of brain function activities. Therefore, the ReHo method was used to analyze BOLD data in the present study.

ReHo analysis is one way to analyze BOLD-fMRI data. It mainly evaluates the level of similarity in changes in the intensity of BOLD signals in the same time series and consequently, it indirectly reflects the temporal consistency of regional neuronal activities. Changes in the ReHo value in a cerebral region indicate that the regional neuronal activities are not synchronized with the surrounding cerebral regions in the same time series (16). Thus, abnormal ReHo values are associated with abnormality in cerebral regional neural activity, and ReHo analysis may detect such brain regions with abnormal activity. In recent years, rCMRglc and ReHo analyses have been applied with an increasing frequency in studies on various mental diseases, including MDD (19-21).

Previous studies on patients with depression using ^{18}F -FDG PET or BOLD-fMRI have indicated metabolic and ReHo abnormalities in certain specific cerebral regions, including the prefrontal, temporal, cingulate cortex, corpus striatum and hippocampus (22-24), and consequently, various aspects of the pathogenesis and neurobiological mechanisms of depression have been elucidated. A hypothesis that proposed limbic-cortical-striatal-pallidal-thalamic (LSCPT) neurological circuits of the brain has also been put forward to uncover the neuropathological mechanisms of depression (23,25,26). In previous PET or fMRI studies (27-29), although cerebral glucose hypometabolism in the prefrontal cortex has been generally considered to be an important change, the results remain conflicting concerning certain parts of the brain, including the anterior cingulate gyrus and the corpus striatum, which has hindered the attempts to interpret the results with the aim of providing neurobiological mechanism(s) of depression. Since the results of different studies may not be directly comparable due to differences in subjects, devices used and/or the research conditions, it is important to investigate the brain glucose metabolism and ReHo in the same group of patients with depression. Based on the abovementioned hypothesis, the present multimodal neuroimaging study was performed on a group of untreated patients with MDD using brain ^{18}F -FDG PET and resting-state BOLD-fMRI techniques to investigate changes in the cerebral

glucose uptake and ReHo values, and to determine whether any association existed between the two types of changes, with a group of healthy control subjects included as a reference. To the best of our knowledge, no similar studies have been reported previously.

Materials and methods

Participants. Imaging protocols were used to obtain ^{18}F -FDG PET and resting-state BOLD-fMRI scans with a maximum interval of 3 days between the two scans for 23 untreated patients with MDD and 18 age- and sex-matched healthy control subjects. A total of five MDD patients and one healthy subject were excluded due to excessive movement during BOLD-fMRI scanning; ultimately, ^{18}F -FDG-PET and resting-state BOLD-fMRI images from 18 patients with MDD and 17 controls were included in the quantitative analyses.

MDD patients were recruited from the Zhengzhou University People's Hospital (Zhengzhou, China) between November 2012 and December 2013. The healthy control subjects were recruited via advertisements and received reimbursements.

All patients were diagnosed according to the Diagnostic and Statistical Manual of Mental Disorders IV criteria (30) by two experienced psychiatrists with a specialization in MDD. The Hamilton Depression Rating Scale (HAM-D) (31) was used to rate the severity of depression and the Hamilton Anxiety Rating Scale (HAM-A) (32) was used to rate the severity of anxiety. All patients were diagnosed with MDD for the first time, and none of them had received any anti-depressant treatment prior to undergoing the imaging examinations. The participants were selected using the following criteria: i) Right-handedness; ii) aged between 18 and 50 years; iii) no history of neurological illnesses or other serious physical disease; iv) no history of alcohol or drug dependence; v) an ability and willingness to cooperate with the experimental procedures; and vi) written informed consent.

The clinical characteristics of the patients and of the healthy control subjects are presented in Table I.

Resting-state BOLD-fMRI. The resting state was defined as no performance of any prescribed cognitive task during the BOLD-fMRI scan (33). Participants were instructed to simply remain motionless, keep their eyes closed and not to think of anything in particular.

Image acquisition. MRIs were acquired with a GE Discovery MR 750 scanner (GE Healthcare, Little Chalfont, UK). A three-dimensional fast spoiled gradient-echo sequence was employed [repetition time (TR), 8.2 msec; echo time (TE), 3.2 msec; inversion time (TI), 450 msec; slice thickness, 1 mm; number of slices, 156; image matrix, 256x256; field of view (FOV), 24 x 24 cm] and a resting BOLD sequence (TR, 2,000 msec; TI, 450 msec; TE, 30 msec; slice thickness, 4 mm; number of slices, 32; image matrix, 64x64; FOV, 24x24 cm).

^{18}F -FDG PET images were obtained using a GE Discovery VCT PET-CT set (GE Healthcare). ^{18}F -FDG was performed using a GE MINI trace medical cyclotron (GE Healthcare) and an FDG automatic synthesis device. Subsequently, quality assurance tests were performed. Prior to the examination,

Table I. Clinical and demographic characteristics of MDD patients (n=18) and healthy controls (n=17).

Characteristic	MDD group	Healthy controls	P-value
Age (years)	32	33	0.57 ^a
Education (years)	17	18	0.53 ^a
Sex (male/female, n)	6/12	6/11	0.59 ^b
HAM-D	19	5	<0.05 ^a
HAM-A	13	3	<0.05 ^a

^aIndependent-sample t-test between MDD patients and healthy control; ^b χ^2 test. Values are expressed as the median. HAM-A, Hamilton Anxiety Rating Scale; HAM-D, Hamilton Depression Rating Scale; MDD, major depressive disorder.

all patients were required to fast for at least 6 h, and the fasting blood glucose levels of the patients were >6.1 mmol/l. ¹⁸F-FDG was injected in an intravenous bolus; the dose was 5.55 MBq/kg. Following the injection, each subject remained in a resting state in a quiet environment for a 50-min uptake period. The brain acquisition time of each patient was 40 min. Brain PET-CT scanning parameters were as follows: Voltage, 120 kV; current, 240 mA; and thickness, 5 mm. An acquisition counter using an iterative method was used to reconstruct the transverse, sagittal and coronal images.

Image pre-processing. Statistical Parametric Mapping (SPM8; Wellcome Department of Imaging Neuroscience, London, UK) was used to complete the image pre-processing. Due to the instability of the initial MRI signals, the first 10 volumes of each functional time series were rejected, leaving 200 volumes. The remaining fMRI images were converted into the Analyze7 format. Subsequently, the head motion and slice acquisition of the converted images were corrected. All images exhibited a maximum displacement of <2 mm in the x, y or z direction and <1° of angular motion during the whole fMRI scan. The fMRI images were subsequently normalized to the standard SPM8 template of echo planar imaging, and then spatially smoothed with a Gaussian kernel of 2x2x2 mm³ [full-width half maximum (FWHM)].

ReHo analysis. ReHo analysis (10) was performed by computing Kendall's coefficient of concordance (KCC) of the time series of a given voxel with those of its nearest neighbors (26 voxels) on a voxel-wise basis. The KCC was calculated according to the following formula: $W = \{\sum(R_i)^2 - n(R)^2\} / (1/12) K^2(n^3 - n)$ and $R = [(n+1)K] / 2$, with W as the KCC among given voxels, ranging from 0 to 1; R_i as the sum rank of the ith time-point; R as the mean of R_i values; K as the number of the time series within a measured cluster (K=27, one given voxel plus the number of its neighbors); and n as the number of ranks (n=200). The program for computing the KCC was coded in MATLAB 8.0 (MathWorks Inc., Natick, MA, USA).

PET data analysis. Brain PET images were converted into the Analyze7 format using SPM8 (5). Motion correction was applied to the converted images. Subsequently, the images were spatially normalized to standard anatomical space (again conforming to the standard Talairach template used in SPM8) to allow for inter-participant averaging and comparison.

Transformed images were then smoothed with a Gaussian kernel of 4x4x4 mm³ (FWHM) to eliminate the influence of physiological noise.

Statistical analysis. Two-sample t-test of voxel-based statistical analyses on the cerebral ¹⁸F-FDG PET images was performed for comparing between the patient and control group. The resulting statistical map was set at a combined threshold of corrected P<0.05 and a minimum cluster size of 10 voxels.

To explore the ReHo difference between MDD patients and controls, a second-level two-sample t-test was performed for the individual ReHo maps in a voxel-by-voxel manner comparing patients with MDD with the control group. The resulting statistical map was set at a combined threshold of a corrected P<0.05 and a minimum cluster size of 10 voxels (34).

The comparison of ReHo and FDG uptake was made using SPSS v18.0 (SPSS Inc., Chicago, IL, USA). Chi-square analysis was used to assess the association of activated brain regions in MDD patients determined by PET and fMRI. Pearson correlation analysis was applied to analyze the correlation between the standardized uptake value (SUV) and the ReHo of the abnormal regions of the patients with MDD. P<0.05 was considered to indicate a statistically significant difference.

Results

Result of HAM-D and HAM-A. The HAM-D and HAM-A scores of the 18 patients with MDD were all >17 and >7, respectively, while, at the same time, the two types of score were <7 in all of the control subjects (Table I). The inter-group differences in the HAM-D and HAM-A scores were statistically significant.

Result of ¹⁸F-FDG PET. Compared with the control subjects, the 18 MDD patients had a decreased glucose uptake on brain ¹⁸F-FDG PET (determined as rCMRglc values) in the bilateral superior, the middle and the inferior frontal gyrus, in the bilateral superior and middle temporal gyrus, in the bilateral anterior cingulate cortex, in the bilateral putamen and caudate, and in the left globus pallidus (Fig. 1; Table II), but an increased glucose uptake in the bilateral hippocampus and left thalamus (Fig. 2; Table II).

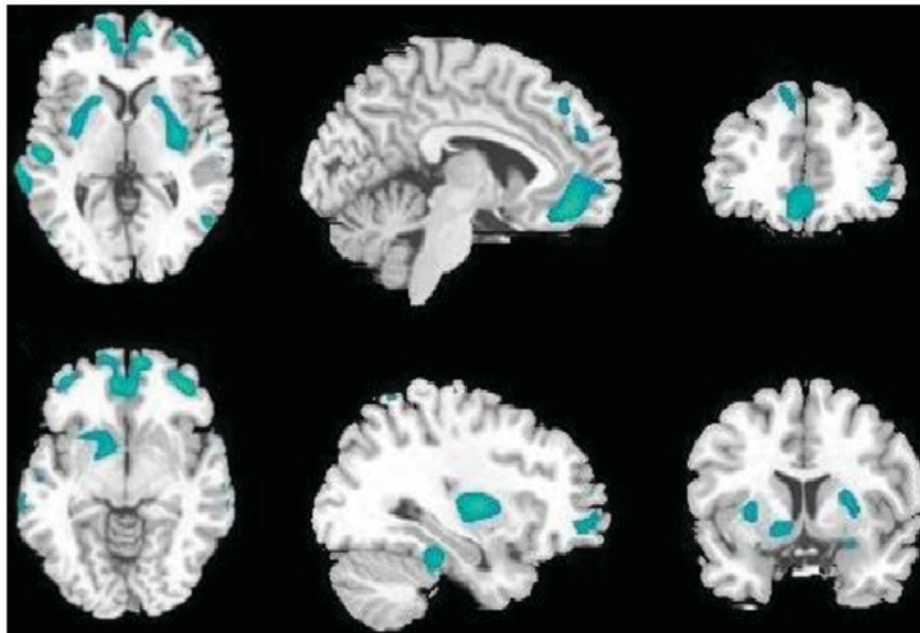


Figure 1. Brain regions with decreased regional glucose metabolism (green areas) as schematic diagrams of statistical results for patients with major depressive disorder in different slices from ^{18}F -fluorodeoxyglucose positron emission tomography computerized tomography scans (cluster-level corrected; $P < 0.05$). Axial, sagittal and coronal images from left to right; analyzed using SPM8. Brain regions include bilateral superior, middle and the inferior frontal gyrus, bilateral superior and middle temporal gyrus, bilateral anterior cingulate cortex, bilateral putamen and caudate, and left globus pallidus.

Result of fMRI. Furthermore, in the 18 patients with MDD, the ReHo values from the resting-state BOLD-fMRI were decreased in the bilateral superior and middle frontal gyrus, in the left globus pallidus, the bilateral putamen and the left anterior cingulate cortex (Fig. 3; Table II), but increased in the right hippocampus and thalamus (Fig. 4; Table II).

Relation between ^{18}F -FDG PET and fMRI. No obvious statistically significant differences were identified between the reduced metabolism and ReHo brain regions of MDD patients ($\chi^2=9.16$; $P=0.90$) and between the increased metabolism and ReHo brain regions ($\chi^2=3.96$; $P=0.27$), when comparing the activated brain regions of PET and MRI. The SUV of the bilateral superior, middle and inferior frontal gyrus, bilateral superior and middle temporal gyrus, bilateral putamen, the left caudate and pallidum, the left anterior cingulate cortex and the bilateral hippocampus and thalamus were correlated with the ReHo values ($r=0.51-0.83$; $P < 0.05$); however, no correlation was detected between the SUV and ReHo values in the right caudate and anterior cingulate cortex ($r=0.41$ and 0.37 , respectively; $P > 0.05$; Table II).

Discussion

^{18}F -FDG PET images are able to reflect cerebral activity by providing information on the uptake of metabolites. When the cerebral activity becomes weak, the uptake decreases, and hypometabolism is revealed in the PET images. However, when the cerebral activity is stronger, hypermetabolism may be observed PET. fMRI revealed a consistency of regional neuronal activities, as indicated by the ReHo of the BOLD signal. It evaluated the level of similarity in intensity changes of BOLD signals and indirectly reflected regional neuronal activities. A decreased ReHo indicates poor consistency of

neuronal activities, which describes regional neuronal activities not synchronizing with the surrounding cerebral regions and indirectly reflecting decreased cerebral function. Conversely, an increased ReHo indicates good consistency of neuronal activities, describing synchronized regional neuronal activities with the surrounding cerebral regions and indirectly reflecting hyperfunction. The two types of imaging methods employed in the present study are able to reflect the cerebral function and activity from different aspects. It is of great benefit for the advancement of research into the pathogenesis of MDD to study changes of cerebral metabolic activity and function in affected patients. Certain previous studies indicated that MDD patients have metabolic or functional abnormalities in part of the cerebral cortex and the limbic system, and they may exhibit a reasonably characteristic pattern of cerebral damage (25,35). However, the results derived from those studies were almost entirely based on PET or fMRI scans of separate subjects, thereby making it difficult to elucidate the pathogenesis of MDD from them. The present study was therefore performed with the reasoning that if PET and fMRI were to be used in combination to scan the same group of untreated MDD patients, more effective image data may be acquired in order to explore the etiology and pathological mechanisms of MDD. The present study demonstrated that several cerebral regions exhibited abnormal glucose metabolism and ReHo, and the abnormal cerebral regions were mainly distributed in parts including the cerebral cortex, limbic system and the thalamus. The results of the present study supported the hypothesis of abnormal LSCPT neurological circuits in patients with depression (36,37). The current study demonstrated that there are abnormal changes of PET and fMRI in some cerebral regions of LSCPT in patients with MDD, including in the temporal lobe, cingulate gyrus and hippocampus. The abnormal changes in the cerebral cortex of patients with MDD included hypometabolism and

Table II. Cerebral regions with abnormal changes and correlation analysis of abnormal changes between positron emission tomography and functional magnetic resonance imaging in patients with major depressive disorder.

Anatomical area	rCMRglc changes	ReHo changes	r	P-value
Frontal gyrus				
Left superior frontal gyrus	Decreased	Decreased	0.52	0.04
Left middle frontal gyrus	Decreased	Decreased	0.64	<0.01
Left inferior frontal gyrus	Decreased	None	0.51	0.04
Right superior frontal gyrus	Decreased	Decreased	0.63	0.01
Right middle frontal gyrus	Decreased	Decreased	0.57	0.03
Right inferior frontal gyrus	Decreased	None	0.59	0.02
Temporal gyrus				
Left superior temporal gyrus	Decreased	None	0.52	0.04
Left middle temporal gyrus	Decreased	None	0.57	0.03
Right superior temporal gyrus	Decreased	None	0.62	0.01
Right middle temporal gyrus	Decreased	None	0.59	0.02
Basal ganglia				
Left putamen	Decreased	Decreased	0.63	0.01
Right putamen	Decreased	Decreased	0.68	<0.01
Left caudate	Decreased	None	0.61	0.01
Right caudate	Decreased	None	0.41	0.12
Left globus pallidus	Decreased	Decreased	0.83	<0.01
Cingulate cortex				
Left anterior cingulate cortex	Decreased	Decreased	0.78	<0.01
Right anterior cingulate cortex	Decreased	None	0.37	0.16
Hippocampus				
Left hippocampus	Increased	None	0.71	<0.01
Right hippocampus	Increased	Increased	0.74	<0.01
Thalamus				
Left thalamus	Increased	None	0.64	<0.01
Right thalamus	None	Increased	0.62	0.01

rCMRglc, regional cerebral metabolic rates of glucose uptake; ReHo, regional homology.

hypofunction in certain regions of the frontal and temporal lobe, while hypometabolism was also identified in the bilateral superior, the middle and inferior frontal gyrus, and decreased ReHo values were observed in the bilateral superior and middle frontal gyrus, with a high correlation existing between them. The frontal lobe serves an important role in attention, perception, planning ability, sustainable behavior, working memory and executive function. Abnormalities in this area may be the most important results with respect to depression in patients. Changes in frontal lobe function are likely to provide the basis of depression, and also to be closely associated with the symptoms of clinical MDD (38). The present study confirmed the above point of view based on the analysis of glucose metabolism and ReHo. Previously published studies that respectively used BOLD-fMRI or FDG-PET in depressed patients identified decreases in ReHo values and glucose uptake in the temporal lobe (39,40). In the present study, it was revealed that glucose uptake in the bilateral middle and anterior temporal gyrus was decreased, although no reduction in the ReHo value was observed in this region; however, a correlation did

exist between them. The anterior cingulate cortex and corpus striatum are the major components of the limbic system that exert an important role in encoding episodic memory, emotional processing and cognizance. In theory, the cerebral function of MDD patients in the striatum and the anterior cingulate gyrus is expected to decline; however, in previously published studies, numerous inconsistencies and uncertainties have arisen. Kennedy *et al* (38) identified that the glucose metabolism decreased in the ventral striatum (caudate nucleus and putamen), but increased in the right pregenual anterior cingulate cortex in a group of depressed patients. However, a study by Mayberg *et al* (41) also demonstrated hypermetabolism in the putamen-pallidum in a subset of depressed patients. Kimbrell *et al* (42) reported that glucose metabolism in the subgenual anterior cingulate cortex was reduced, and the extent of reduction was positively correlated with the severity of depression. A study by De Asis *et al* (36) indicated an increased level of metabolism in the anterior cingulate cortex. Another fMRI study reported decreased ReHo values of the striatum and cingulate cortex, and a good correlation was

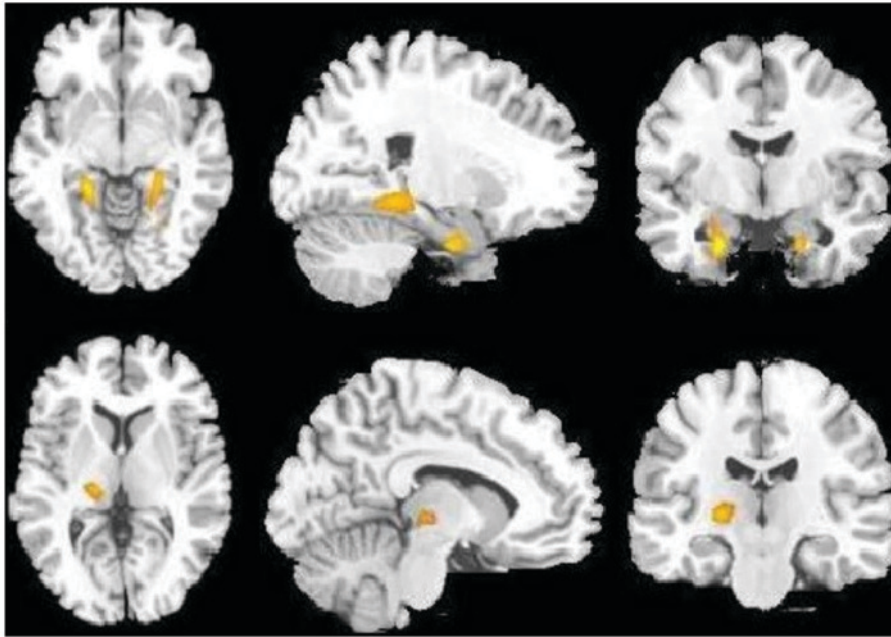


Figure 2. Brain regions with increased regional glucose metabolism (yellow areas) as schematic diagrams of statistical results for patients with major depressive disorder in different slices obtained using ^{18}F -fluorodeoxyglucose positron emission tomography computerized tomography scans (cluster-level corrected $P < 0.05$). Axial, sagittal and coronal images from left to right; analyzed using SPM8. Brain regions include bilateral hippocampus and left thalamus.

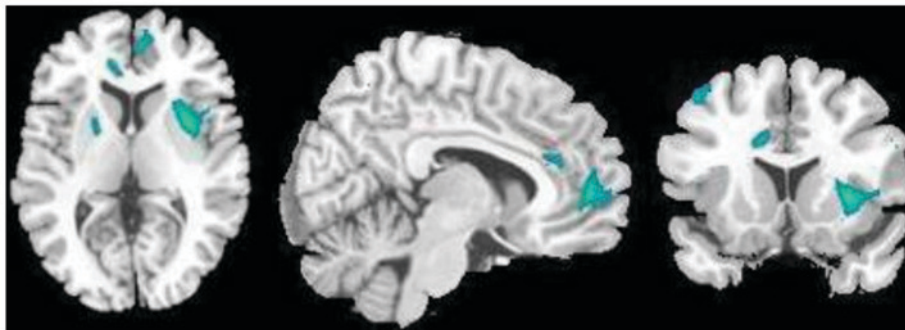

Figure 3. Brain regions with decreased regional homogeneity (green areas) as schematic diagrams of statistical results for patients with major depressive disorder in different slices obtained using functional magnetic resonance imaging (cluster-level corrected; $P < 0.05$). Axial, sagittal and coronal images from left to right; analyzed using SPM8). Brain regions include bilateral superior and middle frontal gyrus, the left globus pallidus, the bilateral putamen and the left anterior cingulate cortex.

identified between them (35). The rCMRglc and ReHo values of the striatum and cingulate cortex were all decreased in the present study. The striatum regions where hypometabolism was identified were distributed in the bilateral lenticular nucleus, the caudate nucleus and the left pallidum, with a decreased ReHo value identified in the bilateral lenticular nucleus. This result further supports the hypothesis that the limbic system, including the striatum and cingulate gyrus, becomes dysfunctional under conditions of depression. In the present study on patients with MDD, thalamic and hippocampal metabolism and the ReHo values were increased, which is consistent with the results of a previous study (39), and is also consistent with the clinical manifestations of increased cerebral function. Other studies indicated that the cerebral function was abnormal in the amygdale of MDD patients (43,44), but in the present study, no abnormal changes in the bilateral amygdale were identified in MDD patients. Furthermore, certain abnormalities of the limbic system, including the temporal lobe, hippocampus

and cingulated gyrus were identified, which may support that depression is associated with the impairment of nerve cell function in the limbic system.

In the present study, the results regarding abnormal cerebrum were largely consistent between the two methods. The characteristics of these changes in MDD patients were not only consistent with the hypothesis of LSCPT neurological circuits but also clarify that brain activities in the anterior cingulate cortex and corpus striatum are reduced. These results suggest that the two imaging techniques are reliable and the evidence from PET and fMRI should be convincing. Another possibly important result was the difference in the extent of the abnormal cerebral regions identified by PET and fMRI: The abnormal cerebral regions on brain PET were obviously larger than those on fMRI in the MDD patients of the present study. As mentioned above, in certain regions, including the bilateral inferior frontal and anterior medial temporal gyrus, the bilateral caudate nucleus, the left pallidus and the right anterior cingulate

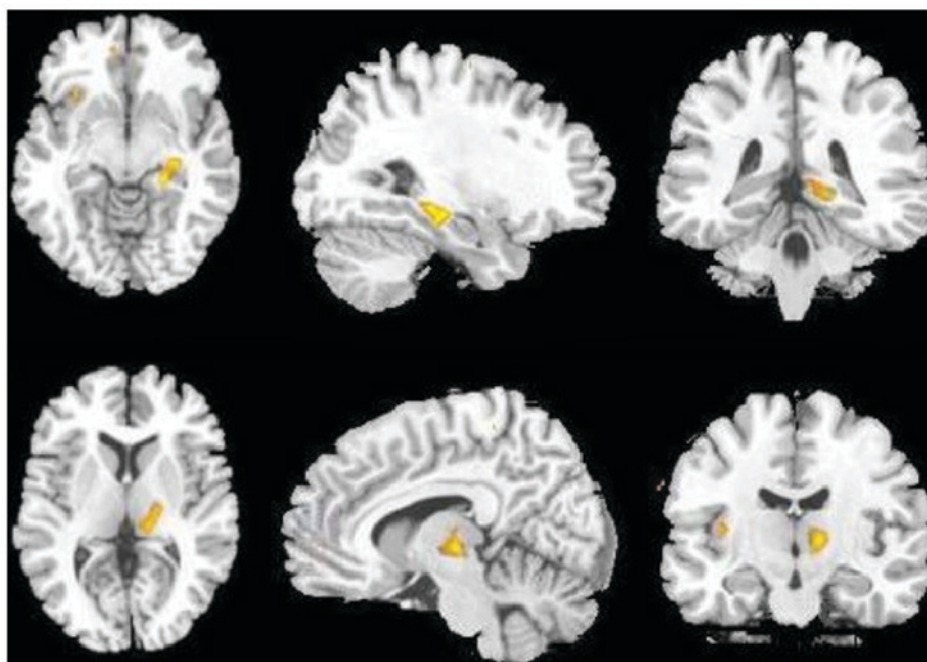


Figure 4. Brain regions with increased regional homogeneity (yellow areas) as schematic diagrams of statistical results for patients with major depressive disorder in different slices obtained using functional magnetic resonance imaging (cluster-level corrected; $P < 0.05$). Axial, sagittal and coronal images from left to right, analyzed using SPM8. Brain regions include the right hippocampus and thalamus.

gyrus, only a decrease in glucose metabolism was demonstrated with no reduced ReHo. These results also indicate that cerebral metabolic abnormalities in MDD patients may occur earlier than ReHo abnormalities, or that ^{18}F -FDG PET may be more sensitive in detecting brain lesions of MDD patients than BOLD-fMRI. These differences were not only observed in MDD patients, but also in patients with numerous other neurological diseases, including dementia, Alzheimer's disease and seizures (11,45,46).

Although the results of the present study are relatively solid due to the use of a multi-mode imaging method, age- and sex-matched control subjects as a reference, normalized data processing regarding regional metabolism and regional homogeneity, the present study has several limitations. First, there was a lack of images for patients with MDD before and after treatment to perform a comparative study. The collection of the post-medication data of these patients is underway. Furthermore, the present study did not perform any comparison between the imaging and clinical results of the patients. Finally, the age and sex of the patients were not fully considered in the present study. These are all areas of future study.

In conclusion, the multimode imaging technique using ^{18}F -FDG PET and resting-state BOLD-fMRI is valuable for investigating brain lesions in MDD patients. MDD patients have relatively characteristic modes of abnormal brain glucose metabolism and regional neuronal activity, which supports the theory of LSCPT neurological circuits. Furthermore, ^{18}F -FDG PET may be more sensitive in detecting brain lesions of MDD patients than BOLD-fMRI.

Acknowledgements

The content of this study has been previously presented as a poster (47; abstract poster no. 2241) at a Society of Nuclear

Medicine and Molecular Imaging conference in June 2017 held in Denver, CO, USA.

Funding

The present study was supported by the Henan Provincial Medical Science and Technology Planning Project (grant no. 201701016).

Availability of data and materials

The analyzed data sets generated during the study are available from the corresponding author on reasonable request.

Authors' contributions

CF conceived and designed the experiments, and wrote the manuscript. HZ contributed to collecting clinical samples and analysis. AX and YG performed the acquisition and analysis of data. JX contributed to the analysis of the data. DS contributed to interpreting the results and revising the manuscript. All authors read and approved the manuscript.

Ethical approval and consent to participate

The present study was approved by the Ethics Committee of Zhengzhou University People's Hospital (Zhengzhou, China). All subjects provided informed consent.

Patient consent for publication

Not applicable.

Competing interests

The authors declare that they have no competing interests.

References

- Knutson B, Bhanji JP, Cooney RE, Atlas LY and Gotlib IH: Neural responses to monetary incentives in major depression. *Biol Psychiatry* 63: 686-692, 2008.
- Maes M, Leonard BE, Myint AM, Kubera M and Verkerk R: The new '5-HT' hypothesis of depression: Cell-mediated immune activation induces indoleamine 2, 3-dioxygenase, which leads to lower plasma tryptophan and an increased synthesis of detrimental tryptophan catabolites (TRYCATs), both of which contribute to the onset of depression. *Prog Neuropsychopharmacol Biol Psychiatr* 35: 702-721, 2011.
- López-Figueroa AL, Norton CS, López-Figueroa MO, Armellini-Dodel D, Burke S, Akil H, López JF and Watson SJ: Serotonin 5-HT_{1A}, 5-HT_{1B}, and 5-HT_{2A} receptor mRNA expression in subjects with major depression, bipolar disorder, and schizophrenia. *Biol Psychiatry* 55: 225-233, 2004.
- Binder EB, Salyakina D, Lichtner P, Wochnik GM, Ising M, Pütz B, Papiol S, Seaman S, Lucae S, Kohli M, *et al*: Polymorphisms in FKBP5 are associated with increased recurrence of depressive episodes and rapid response to antidepressant treatment. *Nat Genet* 36: 1319, 2004.
- Lorenzetti V, Allen NB, Fornito A and Yücel M: Structural brain abnormalities in major depressive disorder: A selective review of recent MRI studies. *J Affect Disord* 117: 1-17, 2009.
- Lui S, Parkes LM, Huang X, Zou K, Chan RC, Yang H, Zou L, Li D, Tang H, Zhang T, *et al*: Depressive disorders: Focally altered cerebral perfusion measured with arterial spin-labeling MR imaging. *Radiology* 251: 476-484, 2009.
- Kim MJ, Hamilton JP and Gotlib LH: Reduced caudate gray matter volume in women with major depressive disorder. *Psychiatry Res* 164: 114-122, 2008.
- Videbech P: PET measurements of brain glucose metabolism and blood flow in major depressive disorder: A critical review. *Acta Psychiatr Scand* 101: 11-20, 2000.
- Mankoff DA, Shields AF and Krohn KA: PET imaging of cellular proliferation. *Radiol Clin North Am* 43: 153-167, 2005.
- Verger A, Roman S, Chaudat RM, Felician O, Ceccaldi M, Didic M and Guedj E: Changes of metabolism and functional connectivity in late-onset deafness: Evidence from cerebral ¹⁸F-FDG-PET. *Hear Res* 353: 8-16, 2017.
- Staffaroni AM, Melrose RJ, Leskin LP, Riskin-Jones H, Harwood D, Mandelkern M and Sultzer DL: The functional neuroanatomy of verbal memory in Alzheimer's disease: [¹⁸F]-Fluoro-2-deoxy-D-glucose positron emission tomography (FDG-PET) correlates of recency and recognition memory. *J Clin Exp Neuropsychol* 39: 682-693, 2017.
- Ogawa S, Lee TM, Nayak AS and Glynn P: Oxygenation-sensitive contrast in magnetic resonance image of rodent brain at high magnetic fields. *Magn Reson Med* 14: 68-78, 1990.
- Biswal B, Yetkin FZ, Haughton VM and Hyde JS: Functional connectivity in the motor cortex of resting human brain using echo-planar MRI. *Magn Reson Med* 34: 537-541, 1995.
- Damoiseaux JS, Rombouts SA, Barkhof F, Scheltens P, Stam CJ, Smith SM and Beckmann CF: Consistent resting-state networks across healthy subjects. *Proc Natl Acad Sci USA* 103: 13848-13853, 2006.
- Fox MD and Raichle ME: Spontaneous fluctuations in brain activity observed with functional magnetic resonance imaging. *Nat Rev Neurosci* 8: 700-711, 2007.
- Zang Y, Jiang T, Lu Y, He Y and Tian L: Regional homogeneity approach to fMRI data analysis. *Neuroimage* 22: 394-400, 2004.
- Yu R, Chien YL, Wang HL, Liu CM, Liu CC, Hsieh MH, Hwu HG and Tseng WY: Frequency-specific alternations in the amplitude of low-frequency fluctuations in schizophrenia. *Hum Brain Mapp* 35: 627-637, 2014.
- de Kwaasteniet B, Ruhe E, Caan M, Rive M, Olabarriaga S, Groefsema M, Heesink L, van Wingen G and Denys D: Relation between structural and functional connectivity in major depressive disorder. *Biol Psychiatry* 74: 40-47, 2013.
- Liu Y, Wang K, Yu C, He Y, Zhou Y, Liang M, Wang L and Jiang T: Regional homogeneity, functional connectivity and imaging markers of Alzheimer's disease: A review of resting-state fMRI studies. *Neuropsychologia* 46: 1648-1656, 2008.
- Hoptman MJ, Zuo XN, Butler PD, Javitt DC, D'Angelo D, Mauro CJ and Milham MP: Amplitude of low-frequency oscillations in schizophrenia: A resting state fMRI study. *Schizophr Res* 117: 13-20, 2010.
- Towgood KJ, Pitkanen M, Kulasegaram R, Fradera A, Soni S, Sibtain N, Reed LJ, Bradbeer C, Barker GJ, Dunn JT, *et al*: Regional cerebral blood flow and FDG uptake in asymptomatic HIV-1 men. *Hum Brain Mapp* 34: 2484-2493, 2013.
- Liu Z, Xu C, Xu Y, Wang Y, Zhao B, Lv Y, Cao X, Zhang K and Du C: Decreased regional homogeneity in insula and cerebellum: A resting-state fMRI study in patients with major depression and subjects at high risk for major depression. *Psychiatry Res* 182: 211-215, 2010.
- Fitzgerald PB, Laird AR, Maller J and Daskalakis ZJ: A meta-analytic study of changes in brain activation in depression. *Hum Brain Mapp* 29: 683-695, 2008.
- Guo WB, Sun XL, Liu L, Xu Q, Wu RR, Liu ZN, Tan CL, Chen HF and Zhao JP: Disrupted regional homogeneity in treatment-resistant depression: A resting-state fMRI study. *Prog Neuropsychopharmacol Biol Psychiatry* 35: 1297-1302, 2011.
- Fujimoto T, Takeuchi K, Matsumoto T, Fujita S, Honda K, Higashi Y and Kato N: Metabolic changes in the brain of patients with late-onset major depression. *Psychiatry Res* 164: 48-57, 2008.
- Lee HS, Choo IH, Lee DY, Kim JW, Seo EH, Kim SG, Park SY, Shin JH, Kim KW and Woo JI: Frontal dysfunction underlies depression in mild cognitive impairment: A FDG-PET study. *Psychiatry Investig* 7: 208-214, 2010.
- Hamilton JP, Etkin A, Furman DJ, Lemus MG, Johnson RF and Gotlib IH: Functional neuroimaging of major depressive disorder: A meta-analysis and new integration of base line activation and neural response data. *Am J Psychiatry* 169: 693-703, 2012.
- Chen S, Wu X, Lui S, Wu Q, Yao Z, Li Q, Liang D, An D, Zhang X, Fang J, *et al*: Resting-state fMRI study of treatment-naïve temporal lobe epilepsy patients with depressive symptoms. *Neuroimage* 60: 299-304, 2012.
- Hamilton JP, Chen G, Thomason ME, Schwartz ME and Gotlib IH: Investigating neural primacy in major depressive disorder: Multivariate Granger causality analysis of resting-state fMRI time-series data. *Mol Psychiatry* 16: 763-772, 2011.
- Kendler KS and Gardner CO Jr: Boundaries of major depression: An evaluation of DSM-IV criteria. *Am J Psychiatry* 155: 172-177, 1998.
- Zimmerman M, Martinez JH, Young D, Chelminski I and Dalrymple K: Severity classification on the Hamilton depression rating scale. *J Affect Disord* 150: 384-388, 2013.
- Kummer A, Cardoso F and Teixeira AL: Generalized anxiety disorder and the Hamilton Anxiety Rating Scale in Parkinson's disease. *Arq Neuropsiquiatr* 68: 495-501, 2010.
- Fox MD and Greicius M: Clinical applications of resting state functional connectivity. *Front Syst Neurosci* 4: 19, 2010.
- Wu T, Long X, Zang Y, Wang L, Hallett M, Li K and Chan P: Regional homogeneity changes in patients with Parkinson's disease. *Human brain mapping* 30: 1502-1510, 2009.
- Yao Z, Wang L, Lu Q, Liu H and Teng G: Regional homogeneity in depression and its relationship with separate depressive symptom clusters: A resting-state fMRI study. *Journal of Affective Disorders* 115: 430-438, 2009.
- De Asis JM, Silbersweig DA, Pan H, Young RC and Stern E: Neuroimaging studies of fronto-limbic dysfunction in geriatric depression. *Clin Neurosci Res* 2: 324-330, 2003.
- Ketter TA, George MS, Kimbrell TA, Benson BE and Post RM: Functional brain imaging, limbic function, and affective disorders. *Neuroscientist* 2: 55-65, 1996.
- Kennedy SH, Evans KR, Krüger S, Mayberg HS, Meyer JH, McCann S, Arifuzzman AI, Houle S and Vaccarino FJ: Changes in regional brain glucose metabolism measured with positron emission tomography after paroxetine treatment of major depression. *Am J Psychiatry* 158: 899-905, 2001.
- Wu JC, Gillin JC, Buchsbaum MA, Schachat C, Darnall LA, Keator DB, Fallon JH and Bunney WE: Sleep deprivation PET correlations of Hamilton symptom improvement ratings with changes in relative glucose metabolism in patients with depression. *J Affect Disord* 107: 181-186, 2008.
- Germain A, Nofzinger EA, Meltzer CC, Wood A, Kupfer DJ, Moore RY and Buysse DJ: Diurnal variation in regional brain glucose metabolism in depression. *Biol Psychiatry* 62: 438-445, 2007.

41. Mayberg HS, Brannan SK, Tekell JL, Silva JA, Mahurin RK, McGinnis S and Jerabek PA: Regional metabolic effects of fluoxetine in major depression: Serial changes and relationship to clinical response. *Biol Psychiatry* 48: 830-843, 2000.
42. Kimbrell TA, Ketter TA, George MS, Little JT, Benson BE, Willis MW, Herscovitch P and Post RM: Regional cerebral glucose utilization in patients with a range of severities of unipolar depression. *Biol Psychiatry* 51: 237-252, 2002.
43. Drevets WC: Neuroimaging abnormalities in the amygdala in mood disorders. *Ann N Y Acad Sci* 985: 420-444, 2003.
44. Abercrombie HC, Schaefer SM, Larson CL, Oakes TR, Lindgren KA, Holden JE, Perlman SB, Turski PA, Krahn DD, Benca RM and Davidson RJ: Metabolic rate in the right amygdala predicts negative affect in depressed patients. *Neuroreport* 9: 3301-3307, 1998.
45. Weyts K, Vernooij M, Steketee R, Valkema R and Smits M: Qualitative agreement and diagnostic performance of arterial spin labelling MRI and FDG PET-CT in suspected early-stage dementia: Comparison of arterial spin labelling MRI and FDG PET-CT in suspected dementia. *Clin Imaging* 45: 1-7, 2017.
46. Kamm J, Boles Ponto LL, Manzel K, Gaasedelen OJ, Nagahama Y, Abel T and Tranel D: Temporal lobe asymmetry in FDG-PET uptake predicts neuropsychological and seizure outcomes after temporal lobectomy. *Epilepsy Behav* 78: 62-67, 2018.
47. Fu C: Regional homogeneity and FDG uptake in patients with major depressive disorder. *J Nucl Med* 58: 1294, 2017.



This work is licensed under a Creative Commons Attribution-NonCommercial-NoDerivatives 4.0 International (CC BY-NC-ND 4.0) License.