

## Unclear Cystic Lesion of the Thumb: A Rare Case of a Mainly Cystic Digital Papillary Adenocarcinoma



### Introduction

Digital papillary adenocarcinoma (DPA) is a malignant neoplasia of the eccrine glands primarily found at the fingers (A. Arsalan-Werner et al. *Handchirurgie, Mikrochirurgie, plastische Chirurgie* 2013; 45: 287–292). It was first described by Helwig 1984 (E. B. Helwig. *Journal of Cutaneous Pathology* 1984; 11: 415–420). These tumors have metastatic potential (W. H. Duke et al. *The American journal of surgical pathology* 2000; 24: 775–784) and a high tendency to recur if not fully resected (T. Kobayashi et al. *The American Journal of dermatopathology* 2016; 38: 910–914). Clinically, these tumors normally present as a painless mass with no signs of inflammation and slow growth over months to years before patients seek medical attention. Imaging diagnosis of digital papillary adenocarcinomas is challenging because there are no specific imaging criteria.

We present the case of a 68-year-old male with a local digital papillary adenocarcinoma of the right thumb with cystic appearance.

### Case Report

The patient, a 68-year-old man, went to the hospital because of a slowly enlarging nodular lesion on the volar side of his right thumb over the last year. The lesion itself was painless but caused the patient increasing discomfort in his daily routine.

Clinical examination showed a painless mass with no redness, discoloration, inflammation of the skin, or alteration of perfusion. The lesion was freely mobile under the skin. The sensitivity and range of motion were normal. X-ray showed soft tissue swelling without any sign of bone destruction. In the ultrasonographic examination the lesion presented as a  $2.2 \times 1.2$  cm sharply circumscribed cystic lesion with a heterogenous echotexture (► **Fig. 1**). Adjacent vascularity was within normal limits. Hematological and biochemical reports showed no abnormalities. Because of the patient's history of a known splinter in the thumb about one year ago, and the radiological appearance of a mostly cystic lesion, diagnosis of a foreign-body granuloma was favored over an adnexal tumor and the patient received local resection of the lesion.

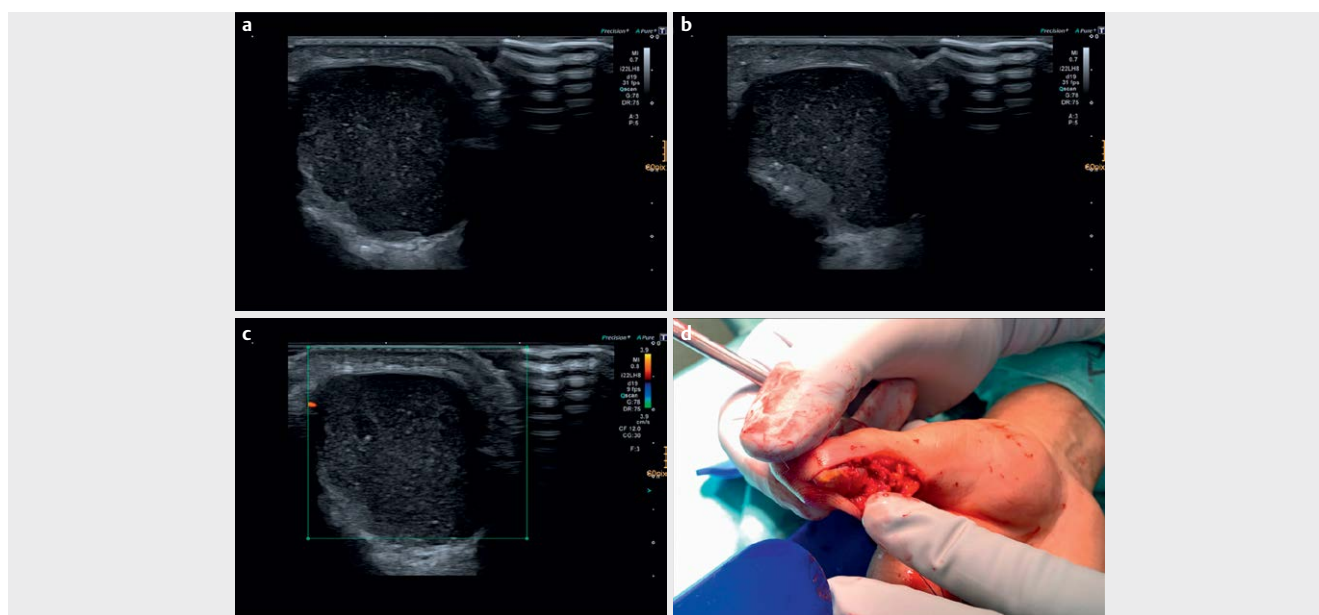
Intraoperatively, the lesion had an atypical appearance for a foreign-body granuloma. Therefore, some further histopathologic examinations were initiated.

In the histopathologic examination the cystic parts of the tumor were mostly debris with just a small number of live cells in the dorsal solid parts of the tumor. Mainly larger cystic cavities with focal intracystic papillary epithelial proliferations were seen. The tumor cells were immunoreactive for AE1/3, CKHMW, CK7 and focal for P63 in the surrounding myoepithelial (► **Fig. 2**). The Ki-67 index was less than 2%.

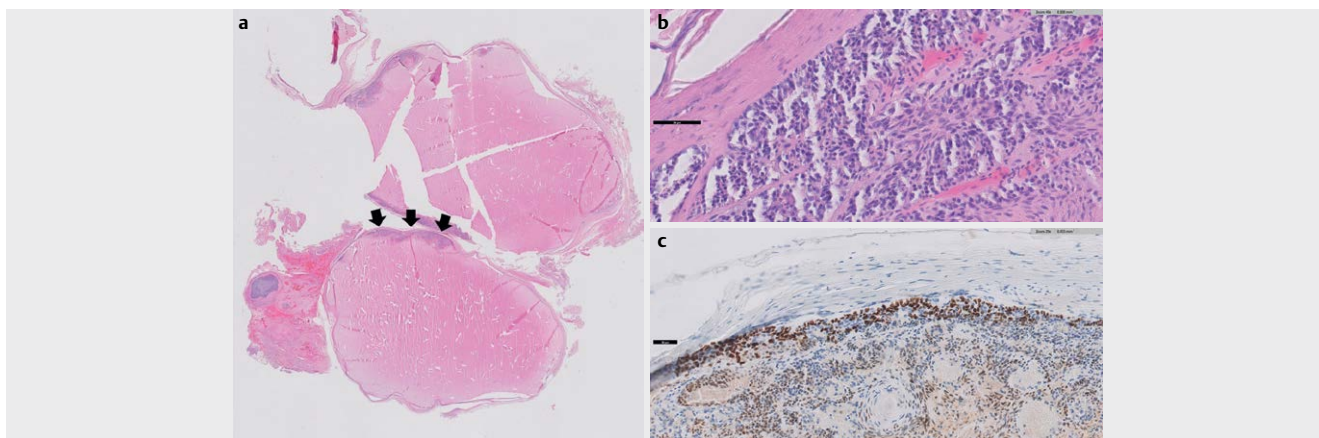
Based on the histopathology, diagnosis of a digital papillary adenocarcinoma (DPA) was made.

Postoperative magnetic resonance imaging (MRI) showed typical postoperative conditions with no residual tumor tissue or sign of bony infiltration. Computed tomography (CT) of the chest/abdomen revealed no signs of hematogenous or lymphatic tumor spread.

Because of the unexpected histopathologic results, the distal phalanx was resected in a second surgery to achieve R0 resection.



► **Fig. 1** a-c B-mode and Doppler. Well circumscribed cystic lesion in the palmar soft tissue of the thumb. The lesion showed an irregular polylobulated dorsal wall and no increased vascularization in the surrounding tissue. d Intraoperative picture.



► **Fig. 2** Histopathology (hematoxylin and eosin stain). **a** Cystic tumor with a small solid component (solid black arrows) matching with the polylobulated solid parts in the sonography. **b** Prominent cellular atypia and nuclear pleomorphism. **c** Immunohistochemistry shows focal nuclear immunoreactivity with P63 in the surrounding myoepithelia.

## Discussion

First described by Helwig the year 1984, digital papillary adenocarcinoma (DPA) is a rare malignant tumor of the sweat glands of the skin. Typically, the tumor is located palmar at the hand, toes and fingers (A. Arsalan-Werner et al. 2013 as cited above). The tumor itself is slowly progressing with a high rate of recurrence (50%) (T. Kobayashi et al. 2016 as cited above). Distant metastases are present in 14–22% of cases (W. H. Duke et al. 2000 as cited above). Macroscopically, DPA mostly demonstrates a multinodular solid and cystic growth pattern. The cysts are formed by central necrosis and/or degeneration or are due to encapsulated mucinous eosinophilic material (W. H. Duke et al. 2000 as cited above, O. Mori et al. European journal of dermatology EJD 2002; 12: 491–494). Only 10–30% of the tumor volume is present as cysts (R. Suchak et al. The American journal of surgical pathology 2012; 36: 1883–1891). Microscopically, a differentiation between other tumors, for example a metastatic adenocarcinoma or an apocrine adenoma, may be difficult (W. H. Duke et al. 2000 as cited above).

The treatment of choice is a wide excision or even amputation of the affected part. Inadequate excision leads to a high recurrence rate. Subsequent re-excision or amputation had a recurrence rate of 5%, whereas cases without re-excision had a recurrence rate of 50% (W. H. Duke et al. 2000 as cited above).

No specific image criteria for a DPA are described in the literature so far. Therefore, the imaging diagnosis of a DPA is challenging. In our case, the tumor was first explored by ultrasonography, where it presented as a

2.2×1.2 cm well circumscribed overall cystic lesion. The liquid part showed mixed echogenicity. In the literature as mentioned above, the DPA normally has a cystic amount of approximately 10–30% and therefore presents normally in the imaging modalities as a more solid tumor with just smaller liquid/cystic parts. Retrospectively, the lesion presented with a thickened polylobulated dorsal wall and atypical vascularization for a foreign body granuloma, which should have favored the diagnosis of an adnexal tumor with mixed solid and cystic components instead of foreign body granuloma despite the patient's history of a splinter. A ganglion cyst was ruled out because of the missing connection to the adjacent interphalangeal joint and the atypical location.

In summary, the digital papillary adenocarcinoma is challenging for imaging diagnostics because there are no specific criteria. However, in the case of a slowly progressing cystic nodule on digits without a known history of foreign body or trauma, an adnexal tumor such as a DPA should be considered as a differential diagnosis, even if the “typical” DPA has a cystic amount of just approximately 10–30%. Nevertheless, the final diagnosis needs to be made by the pathologist.

## Conflict of Interest

The authors declare that they have no conflict of interest.

## Authors

Johannes Deeg<sup>1</sup>, Alexander Loizides<sup>1</sup>, Murat Okcu<sup>2</sup>, Hannes Gruber<sup>1</sup>

## Affiliations

- 1 Department of Radiology, Medical University of Innsbruck, Innsbruck
- 2 Department of Pathology, Histodiagnostik Graz, Graz

## Correspondence

Dr. Johannes Deeg  
Department of Radiology, Medical University of Innsbruck,  
Anichstraße 35,  
6020 Innsbruck  
Austria  
Tel.: 0043 050 5040,  
johannes.deeg@i-med.ac.at

published online 2020

## Bibliography

Ultrasound Int Open 2020; 6: E48–E49

DOI 10.1055/a-1270-7851

ISSN 2199-7152

© 2020. The Author(s).

This is an open access article published by Thieme under the terms of the Creative Commons Attribution-NonDerivative-NonCommercial-License, permitting copying and reproduction so long as the original work is given appropriate credit. Contents may not be used for commercial purposes, or adapted, remixed, transformed or built upon. (<https://creativecommons.org/licenses/by-nc-nd/4.0/>)

Georg Thieme Verlag KG, Rüdigerstraße 14,  
70469 Stuttgart, Germany

