

OPEN

# Multiplane Forehead Shortening: Sparing the Frontalis Muscle and Supraorbital Nerve

Yong Su Ahn, M.D.  
Yun Yong Park, M.D.  
Jung Woo Chang, M.D.,  
Ph.D.  
Seoul and Guri, Republic of Korea



**Background:** An appropriate forehead-to-face ratio is an important factor contributing to a balanced and attractive face. Conventional methods have been used to correct long forehead, but these methods have drawbacks. The primary objective of this study was to introduce a modified technique with better results.

**Methods:** Between March of 2015 and March of 2017, 525 patients with long forehead underwent multiplane forehead shortening with sparing of the frontalis muscle and supraorbital nerve. The operation began with a design indicating the area of skin excision. The sensory nerves were preserved during the skin excision, and the frontalis muscle was not cut. Subgaleal dissection was performed through a small window on the galea. The postoperative assessments included the change in forehead length, sensory changes on the scalp, the presence of a scar, alopecia, and synchronous movement of the flap.

**Results:** A mean forehead shortening of 2.0 cm (range, 1.1 to 2.8 cm) was observed. Sensory deficits were observed only in the anteromedian scalp, which the supratrochlear nerve innervates. However, sensation recovered to the normal level within 6 months. Scars were barely visible or not visible at all in 85.5 percent of the patients. Postoperative alopecia occurred in only two cases. The synchronous movement of the forehead and scalp was natural in all cases.

**Conclusion:** This modified technique of multiplane forehead shortening with sparing the frontalis muscle and supraorbital nerve provided both cosmetic and functional benefits. (*Plast. Reconstr. Surg.* 143: 405, 2019.)

**CLINICAL QUESTION/LEVEL OF EVIDENCE:** Therapeutic, IV.

The forehead-to-face ratio is an important factor for evaluating whether a face is balanced and attractive.<sup>1,2</sup> Farkas and Kolar showed in their anthropometric evaluations that a lower hairline and a slightly smaller upper facial third appeared more attractive.<sup>3</sup> To achieve a shortened forehead, hair transplantation or tattooing can be performed, but these techniques are

not appropriate when the area to be masked is too wide.<sup>4</sup>

Surgical correction procedures, such as anterior advancement of a scalp flap, can be considered if the forehead elongation is more than 10 mm compared to the midface.<sup>5</sup> The conventional subgaleal forehead shortening method, however, is unable to avoid extensive sensory loss in the scalp in the early postoperative period.<sup>6</sup> As the upper portion of the frontalis

From the ATOP Plastic Surgery Clinic; and the Department of Plastic and Reconstructive Surgery, Hanyang University Guri Hospital, Hanyang University College of Medicine. Received for publication January 3, 2018; accepted August 31, 2018.

Drs. Ahn and Park contributed to this work equally as co-first authors.

Copyright © 2019 The Authors. Published by Wolters Kluwer Health, Inc. on behalf of the American Society of Plastic Surgeons. All rights reserved. This is an open-access article distributed under the terms of the Creative Commons Attribution-Non Commercial-No Derivatives License 4.0 (CCBY-NC-ND), where it is permissible to download and share the work provided it is properly cited. The work cannot be changed in any way or used commercially without permission from the journal.

DOI: 10.1097/PRS.0000000000005271

**Disclosure:** The authors have no financial interest to declare in relation to the content of this article. No funding was received.

Supplemental digital content is available for this article. Direct URL citations appear in the text; simply type the URL address into any Web browser to access this content. Clickable links to the material are provided in the HTML text of this article on the *Journal's* website (www.PRSJournal.com).

muscle is excised mostly, unnatural movement of the hairline is also unavoidable. Subcutaneous forehead shortening is an alternative means of overcoming these disadvantages but leads to complications, such as scar widening and focal alopecia around the incision line.<sup>7</sup> To achieve both functional and cosmetic benefits at the same time, we developed a modified technique, which we refer to as multiplane forehead shortening with sparing the frontalis muscle and supraorbital nerve.

## PATIENTS AND METHODS

This study was conducted in conformity with the World Medical Association Declaration of Helsinki, and the protocol was approved by the Institutional Review Board of Hanyang University Guri Hospital (2017-11-012-001). From March of 2015 to March of 2017, 525 patients with a long forehead underwent multiplane forehead shortening with sparing of the frontalis muscle and supraorbital nerve.

Patients were assessed through soft-tissue cephalometric analysis, and the length of the forehead relative to the face was analyzed. The surgical indication was forehead elongation greater than 10 mm compared with the mid-face. Patients with a history of previous surgery on the scalp or forehead, diseases of the hair or scalp, or any history of hair loss were excluded. After the forehead-shortening procedure, postoperative assessments of functional and cosmetic results were performed. A single plastic surgeon (Y.S.A.) performed the surgical procedures and conducted the patient evaluations, including forehead length, alopecia, and synchronous movement. The evaluations for sensory function and scar formation were performed with a patient questionnaire.

### Surgical Techniques

#### Determining the Amount of Excision

The maximal amount of forehead excision is determined by adding the extent of scalp gliding and scalp expansion. The extent of gliding is assessed by simply placing the pulps of the examining fingers on the scalp and moving it on the underlying pericranium (Fig. 1). The extent of scalp expansion is determined by pinching the forehead skin around the hairline with two fingers. After determining the maximal amount of forehead excision, a decision is made regarding the actual extent of excision based on the patient's needs.

#### Design

The incision line is designed with the patient in the sitting position. The upper incision line is drawn 2 mm posteriorly behind the original hairline. The shortening length is pointed inferiorly from the upper incision line, and the lower incision line is drawn on the forehead. Both lines are drawn in zig-zag patterns, and the distance between the two lines is tapered laterally to form an elliptical area of excisional skin (Fig. 1). In female patients, the excision area should be designed to make the postoperative hairline rounded, whereas male patients should have a square hairline.

#### Anesthesia

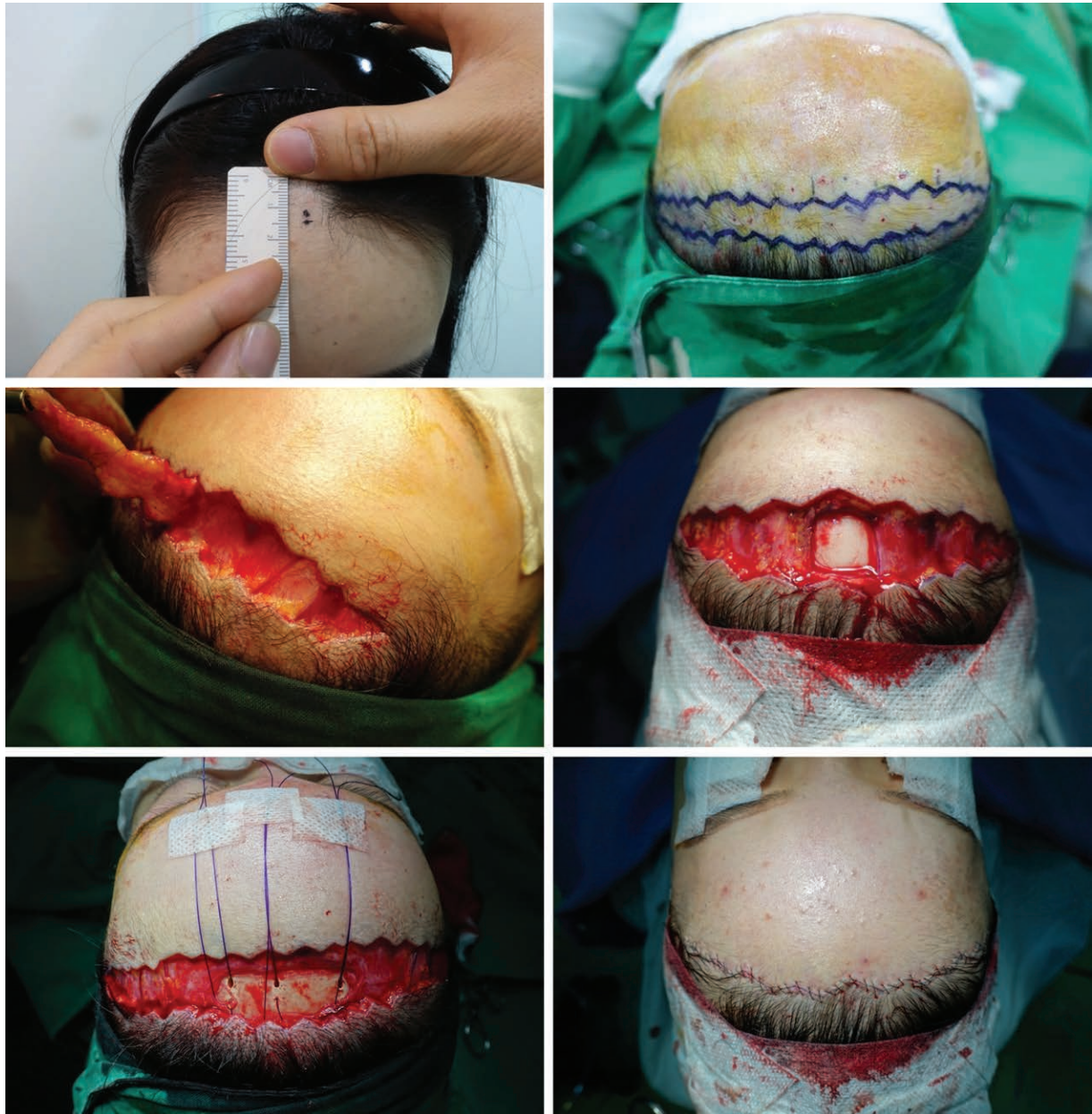The operation is performed with the patient in the supine position under local anesthesia. Patients are sedated with an intravenous injection of 1 mg of midazolam, 25 mg of ketamine, and 30 to 60 mg/hour of propofol. After sedation, 1% lidocaine with 1:100,000 epinephrine is infiltrated along the incision line and the posterior scalp flap to be elevated.

#### Incision and Skin Excision

An incision is made along the designed line. A 30- to 45-degree anteriorly beveled incision is made along the upper incision line to minimize injury to the hair follicles. Skin excision is performed using a scalpel, sparing the sensory nerves between the skin and frontalis muscle (Fig. 1). The superficial branches of the supraorbital nerve can be seen easily with the naked eye. Excision by electrocautery can damage the sensory nerves within the subdermal layer; thus, electrocautery should be avoided as much as possible. If the neurovascular bundle around the temporal fusion line is injured, the bleeding can be stopped simply by temporary compression. After complete excision of the forehead skin, subdermal undermining of the scalp flap is performed, approximately 2 cm in the cephalic direction from the upper incision line.

#### Multiplane Dissection and Galeatomy

In the central portion of the exposed area, a window measuring 5 × 10 mm is made between the two frontalis muscle bellies (Fig. 1). Through the window, subgaleal dissection of the scalp flap is performed in the cephalic direction. The endpoint of the subgaleal dissection is usually the occipital protuberance, which minimizes the tension on the scalp flap when the flap is advanced. The dissection in the lateral portion should be performed across the temporal fusion line in the same manner. However, in this area,



**Fig. 1.** Surgical techniques of multiplane forehead shortening. (Above, left) Deciding the amount of skin excision by the gliding test. (Above, right) Designing the excisional line. (Center, left) Skin excision, sparing the superficial branches of the supraorbital nerve. (Center, right) Making a 5 × 10-mm window for subgaleal dissection. (Below, left) Fixing the posterior scalp flap on the skull with three suture points. (Below, right) Closing the flap, layer by layer.

subperiosteal dissection is preferred instead of subgaleal dissection to avoid injuring the deep branch of the supraorbital nerve. The forehead flap should not be dissected, and only the dissected posterior scalp flap should be advanced anteriorly. If tension on the scalp flap is still observed when advancing the flap, scoring incisions can be made on the galea layer of the scalp flap. The galeotomies should be performed horizontally, at distances of 2 cm.

#### Flap Fixation and Wound Closure

Once optimal scalp advancement is obtained, three bone tunnels are made within the window. The tunnels should be located 2 cm behind the final closure line. A 2-mm drill is used to create two holes approximately 3 mm apart, at opposing 45-degree angles. Fixation is achieved with a 2-0 polydioxanone suture that is passed through the bone tunnel and its corresponding point on the galeal fascia after advancing the scalp flap (Fig. 1).

After confirming the tensionless advancement at the suture line, the excised galea on the central portion is approximated with 4-0 polydioxanone sutures. The subcutaneous layer is closed with 4-0 polydioxanone sutures, and the skin is closed with 6-0 nylon sutures (Fig. 1). (See Video, Supplemental Digital Content 1, which demonstrates multiplane forehead shortening with sparing the frontalis muscle and supraorbital nerve, available in the “Related Videos” section of the full-text article on PRSJJournal.com or, for Ovid users, available at <http://links.lww.com/PRS/D234>.)

### Postoperative Assessments

#### Length of the Forehead

The change in the forehead length is evaluated. The preoperative length and the 6-month postoperative length are measured.

#### Sensory Loss

Sensory changes in the scalp are evaluated. The scalp is divided into 12 sections, and a six-point scale (where 0 = no sensation and 5 = normal sensation) is used for the sensory evaluation. The 12 sections are obtained by dividing the area from the hairline to the vertex in half horizontally, and the medial orbital rim, midpupillary line, and lateral orbital rim are used for vertical divisions (Fig. 2). The evaluations are performed on the day immediately after the operation, and then at 1, 3, and 6 months postoperatively.

#### Presence of a Scar

The presence of a scar on the suture line is evaluated at 6 months postoperatively. The

patient’s satisfaction with the scar is assessed as follows: “not visible,” “barely visible,” “minimally visible,” or “markedly visible.”

#### Alopecia

The postoperative presence of alopecia is recorded.

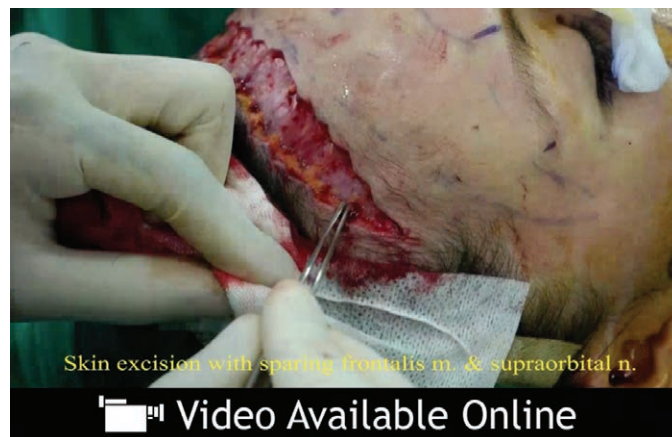#### Synchronous Movement

When the patient elevates his or her eyebrows, the natural and continuous movement of the forehead and scalp is evaluated. We determine whether the movement is synchronous, which refers to movement of the anterior forehead flap and the posterior scalp flap as one unit.


## RESULTS

The total population of 525 patients consisted of 52 men and 473 women, with a mean age of 28.4 years (range, 18 to 60 years) and follow-up period of 11.2 months on average (range, 6 to 18 months). The mean preoperative forehead length was 8.3 cm (range, 6.2 to 10.0 cm), and the mean postoperative forehead length was 6.3 cm (range, 5.3 to 8.2 cm). The length was shortened by an average of 2.0 cm (range, 1.1 to 2.8 cm) (Table 1).

Before surgery, all patients had normal sensory function on the scalp. In the sensory evaluation on the day immediately after surgery, a marked sensory deficit was observed on the anterior median portion of the scalp. The surrounding areas also showed a slight reduction of sensory function, but the lateral portions did not show any sensory deficits (Fig. 2). At 3 months postoperatively, the



**Video** . Supplemental Digital Content 1 demonstrates multiplane forehead shortening with sparing the frontalis muscle and supraorbital nerve, available in the “Related Videos” section of the full-text article on PRSJJournal.com or, for Ovid users, available at <http://links.lww.com/PRS/D234>.



**Fig. 2.** Evaluation of sensory function on the scalp. (Left) Average scores at 1 day postoperatively. (Right) Average scores at 3 months postoperatively. A, half line between the hairline and vertex; B, hairline; C, lateral orbital rim; D, midpupillary line; E, medial orbital rim.

**Table 1. Demographic and Clinical Information of the Patients**

Variables	Value
No. of patients	525
Sex, no.	
Male	52
Female	473
Age, yr	
Mean	28.4
Range	18–60
Follow-up period, mo	
Mean	11.2
Range	6–18
Operative findings	
Preoperative forehead length, cm	
Mean	8.3
Range	6.2–10.0
Postoperative forehead length, cm	
Mean	6.3
Range	5.3–8.2
Shortened length, cm	
Mean	2.0
Range	1.1–2.8

sensory function of most areas had recovered to the preoperative level except for the anterior median portion (Fig. 2). The anterior median portion also recovered its function gradually, and all scalp areas recovered normal sensory function by 6 months postoperatively.

Generally, the scar became hyperemic by 3 months, but its status gradually improved by 6 months, with normal color and softness. In the subjective patient evaluations at 6 months, most patients evaluated the scar as “barely visible” (76.4 percent), whereas only 1.7 percent of the patients selected “markedly visible” (Table 2).

**Table 2. Evaluation of Scarring\***

Scar Assessment	No. (%)
Not visible	48 (9.1)
Barely visible	401 (76.4)
Minimally visible	67 (12.8)
Markedly visible	9 (1.7)

\*n = 525 patients.

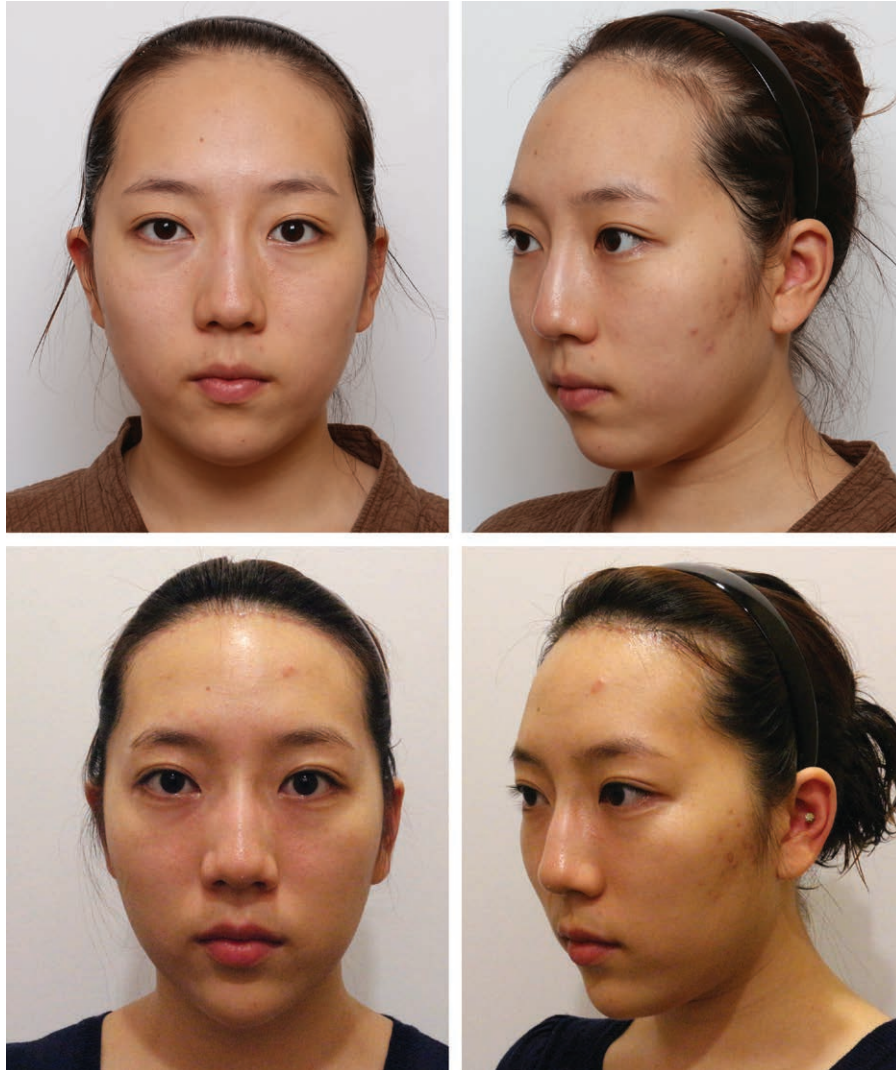There were two cases of postoperative alopecia among the total of 525 cases. The first case was attributable to extensive tension on the scalp flap. The patient experienced alopecia over an extensive area posterior to the suture line. As the alopecia was observed immediately after surgery, diluted triamcinolone was injected in the perifollicular region every month for 5 months. The patient experienced gradual recovery after 3 months, and achieved complete recovery at 5 months. The second case was attributable to a deep galeotomy that injured the hair follicles within the overlying dermis. Focal alopecia was observed on the injured area, and triamcinolone was also injected for recovery. The alopecia improved, but full recovery to the preoperative status was not possible.

Synchronous movement of the forehead and scalp was observed in all 525 cases. All patients could move their forehead and scalp with continuity when elevating their eyebrows. No interrupted movement across the scar line was observed in any cases.

## CASE REPORTS

### Case 1

A 22-year-old female patient with a long forehead measuring 9.5 cm underwent multiplane forehead shortening (Fig. 3).



**Fig. 3.** A 22-year-old female patient who underwent multiplane forehead shortening. (Above, left) Frontal view preoperatively. (Above, right) Semilateral view preoperatively. (Below, left) Frontal view at 1 month postoperatively. (Below, right) Semilateral view at 1 month postoperatively.

The excision length was determined to be 2.0 cm after measuring the extent of gliding and expansion. The final forehead length at 6 months postoperatively was 7.6 cm. After surgery, she did not experience any sensory loss on the scalp, except for the anteromedian portion. The dullness of the anteromedian scalp (score of 2) was temporary, and the sensory function improved gradually to a normal level (score of 5) over 6 months. The scar was acceptable, as the patient's subjective evaluation at 6 months was "barely visible." No alopecia was seen, and the forehead and scalp flap moved synchronously as one unit.

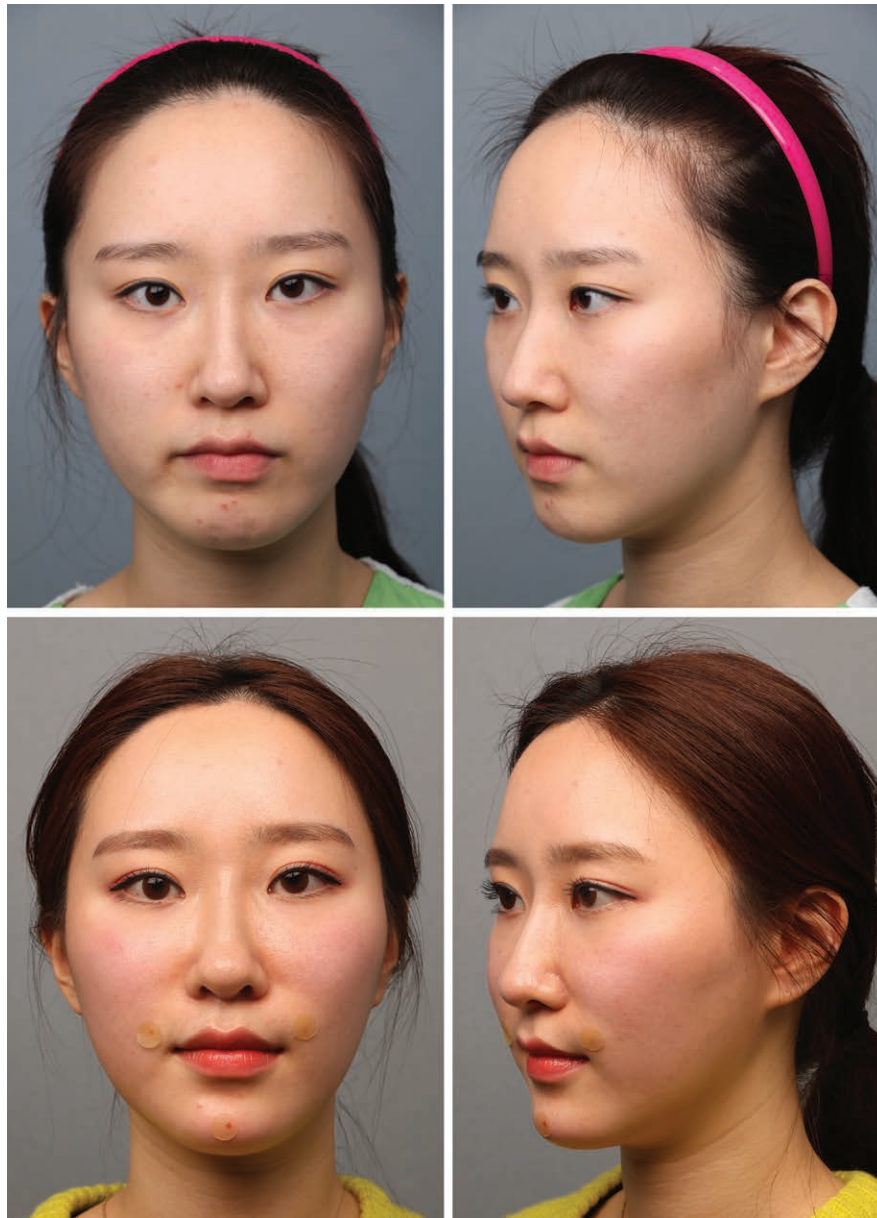### Case 2

A 25-year-old female patient underwent multiplane forehead shortening (Fig. 4). The preoperative forehead length was 8.2 cm, and the excision length was determined to be 1.7 cm after measuring the extent of gliding and expansion. The final forehead length at 6 months postoperatively was 6.5 cm. She experienced diffuse sensory reduction (score of 1 to 3) on the

central portion of the scalp, but the dullness improved to normal levels (score of 5) over 6 months. The scar was acceptable, as the patient's subjective evaluation at 6 months was "not visible." No postoperative alopecia was noted, and synchronous movement of the forehead and scalp was observed.

### DISCUSSION

Forehead shortening is essential for patients with a long forehead to appear more attractive.<sup>5</sup> As a less invasive procedure, hair transplantation has been widely used for forehead shortening.<sup>8-11</sup> However, in many cases, the density of the transplanted hair is low, and the newly formed hairline is unnatural.<sup>12</sup> If the area for transplantation is wide, this phenomenon is more common. Moreover, the final result is achieved only after at least



**Fig. 4.** A 25-year-old female patient who underwent multiplane forehead shortening. (Above, left) Frontal view preoperatively. (Above, right) Semilateral view preoperatively. (Below, left) Frontal view at 6 months postoperatively. (Below, right) Semilateral view at 6 months postoperatively.

6 months. To overcome these drawbacks, surgical options such as scalp advancement by means of an anterior hairline became popular.<sup>13</sup> Although it is more invasive than hair transplantation, it provides a natural hairline with a high density of hair, and the final outcome can be observed more quickly than is possible for hair transplantation.

Scalp advancement can be performed using two methods. The first is subgaleal dissection, which is commonly used. In this method, en bloc excision from the skin to the frontalis muscle is

performed.<sup>14</sup> This causes permanent sensory loss in the posterior scalp, as the supraorbital nerve is cut, including both the superficial and deep branches.<sup>6</sup> Moreover, loss of continuity in the frontalis muscle and scar formation on this site result in unnatural movement of the hairline. The other method is subcutaneous dissection, which has superior results in terms of sensory function.<sup>15</sup> However, this technique can easily cause focal alopecia, because of the relative flap insufficiency that results from losing the connection between

the flap and the underlying galea. Scar widening on the suture line is also easily observed.<sup>16</sup>

The modified technique, multiplane forehead shortening, incorporates the advantages of the both methods and minimizes their drawbacks. This new technique is appropriate for preserving sensory function on the scalp by sparing both the superficial and deep branches of the supraorbital nerve. The superficial branch divides into multiple smaller branches that penetrate the frontalis muscle at various points from the supraorbital rim to the midforehead level, and run just above the frontalis muscle and galea.<sup>17,18</sup> When excising the supragaleal tissue, the superficial branches on the frontalis muscle can be observed, and with careful excision, they can be preserved. The deep branch of the supraorbital nerve can be preserved by sparing the frontalis muscle and dissecting the lateral region through the subperiosteal plane. The deep branch in the orbitofrontal region is located within the subgaleal fascia, and it reaches the subcutaneous layer at the coronal suture line level.<sup>17,19,20</sup> For this reason, excision of the supragaleal tissue around the hairline and dissection through the subperiosteal plane do not interfere with the deep branch of the supraorbital nerve. Unfortunately, almost every patient experienced sensory deficits on the anteromedian scalp in the early postoperative period. This is caused by damage to the supratrochlear nerve, which innervates the anteromedian scalp. As this nerve is located too superficially on the anteromedian portion, preserving it during skin excision is impossible. For this reason, the authors did not attempt to spare this nerve, and made a window by galeal excision on the anteromedian portion. However, the area with the sensory deficit improved gradually after 3 months, and recovered to nearly normal levels by 6 months. This is thought to be the result of reinnervation of the damaged nerves or sprouting from adjacent nerves. The presence of cross-innervation between the supratrochlear nerve and the anteromedial portion of the supraorbital nerve makes this possible.<sup>18</sup>

When preserving the sensory nerves and frontalis muscle, many vascular and lymphatic structures are also preserved at the same time. This facilitates rapid postoperative recovery. The postoperative swelling in the scalp and forehead is reduced rapidly, which improves the outcomes. In addition, as the dissection is performed through the subgaleal plane, the channels between the frontalis muscle and the overlying skin layer are completely spared. The preservation of the perforators makes the scalp flap healthy, preventing postoperative alopecia.

Generally, forehead movements are made by the action of the frontalis muscle. Maintaining the continuity of the frontalis muscle allows the synchronous movement of the forehead and scalp over the scar line. In the conventional subgaleal advancement flap, the frontalis muscle is excised with the skin in an en bloc manner, and most of the continuity between the upper galea and the lower frontalis muscle is lost. In addition, scar formation on the suture site of the excised muscle interferes with the natural gliding plane. However, in our modified technique, the frontalis muscle maintains its entire continuity, except for a central portion where a small window is made. As the window is made in the area between the two bellies of the left and right frontalis muscles, excision of this area does not affect the action of the frontalis muscle.

## CONCLUSIONS

The new technique, multiplane forehead shortening with sparing the frontalis muscle and supraorbital nerve, benefits patients with a long forehead. This new technique provides these patients with not only cosmetic improvements but also functional benefits. The drawbacks of each conventional method are addressed by this new technique.

*Jung Woo Chang M.D., Ph.D.*

Department of Plastic and Reconstructive Surgery  
Hanyang University Guri Hospital  
249-1, Gyomun-dong, Guri-si  
Gyeonggi-do 471-701, Republic of Korea  
mickey404@hanmail.net

## PATIENT CONSENT

*Patients provided written consent for the use of patients' images.*

## REFERENCES

1. Jung JH, Yun IS. Total hairline correction in female patient. *Arch Aesthet Plast Surg.* 2014;20:44–51.
2. Holcomb JD, McCollough EG. Trichophytic incisional approaches to upper facial rejuvenation. *Arch Facial Plast Surg.* 2001;3:48–53.
3. Lee JS, Kim HK, Kim YW. Anthropometric analysis of the attractive and normal faces in Korean female. *J Korean Soc Plast Reconstr Surg.* 2004;31:526–531.
4. Ramirez AL, Ende KH, Kabaker SS. Correction of the high female hairline. *Arch Facial Plast Surg.* 2009;11:84–90.
5. Guyuron B, Rowe DJ. How to make a long forehead more aesthetic. *Aesthet Surg J.* 2008;28:46–50.
6. Knize DM. Reassessment of the coronal incision and subgaleal dissection for foreheadplasty. *Plast Reconstr Surg.* 1999;103:1326–1327.



7. Byun S, Mukovozov I, Farrokhyar F, Thoma A. Complications of browlift techniques: A systematic review. *Aesthet Surg J*. 2013;33:189–200.
8. Beehner M. Hairline design in hair replacement surgery. *Facial Plast Surg*. 2008;24:389–403.
9. Patwardhan N, Mysore V; IADVL Dermatosurgery Task Force. Hair transplantation: Standard guidelines of care. *Indian J Dermatol Venereol Leprol*. 2008;74(Suppl): S46–S53.
10. Lee TS, Minton TJ. An update on hair restoration therapy. *Curr Opin Otolaryngol Head Neck Surg*. 2009;17:287–294.
11. Rawnsley JD. Hair restoration. *Facial Plast Surg Clin North Am*. 2008;16:289–297, v.
12. Burm JS, Oh SJ. Prevention and treatment of wide scar and alopecia in the scalp: Wedge excision and double relaxation suture. *Plast Reconstr Surg*. 1999;103:1143–1149.
13. Kabaker SS, Champagne JP. Hairline lowering. *Facial Plast Surg Clin North Am*. 2013;21:479–486.
14. Tolhurst DE, Carstens MH, Greco RJ, Hurwitz DJ. The surgical anatomy of the scalp. *Plast Reconstr Surg*. 1991;87: 603–612; discussion 613–614.
15. Guyuron B, Davies B. Subcutaneous anterior hairline forehead rhytidectomy. *Aesthetic Plast Surg*. 1988;12:77–83.
16. Unger WP. Hair transplantation: Current concepts and techniques. *J Investig Dermatol Symp Proc*. 2005;10:225–229.
17. Knize DM. A study of the supraorbital nerve. *Plast Reconstr Surg*. 1995;96:564–569.
18. Erdogmus S, Govsa F. Anatomy of the supraorbital region and the evaluation of it for the reconstruction of facial defects. *J Craniofac Surg*. 2007;18:104–112.
19. Carstens MH, Greco RJ, Hurwitz DJ, Tolhurst DE. Clinical applications of the subgaleal fascia. *Plast Reconstr Surg*. 1991;87:615–626.
20. Tremolada C, Fissette J, Candiani P. Anatomical basis for a safe and easier approach to composite rhytidectomy. *Aesthetic Plast Surg*. 1994;18:387–391.