

Case Report

Bell's palsy and partial hypoglossal to facial nerve transfer: Case presentation and literature review

Mariano Socolovsky, Miguel Domínguez Páez¹, Gilda Di Masi, Gonzalo Molina, Eduardo Fernández²

Nerve and Plexus Surgery Program, Division of Neurosurgery, University of Buenos Aires School of Medicine, Buenos Aires, Argentina, ¹Department of Neurosurgery, Hospital Regional Universitario Carlos Haya, Málaga, Spain, ²Department of Neurosurgery, Catholic University, Rome, Italy

E-mail: *Mariano Socolovsky - Socolovsky@fibertel.com.ar; Miguel Domínguez Páez - lenin_@hotmail.com; Gilda Di Masi - gildadimasi@gmail.com, Gonzalo Molina - gmolina@intramed.net; Eduardo Fernández - e.fernandez@rm.unicatt.it

*Corresponding author

Received: 8 March 12

Accepted: 23 March 12

Published: 25 April 12

This article may be cited as:

Socolovsky M, Páez MD, Masi GD, Molina G, Fernández E. Bell's palsy and partial hypoglossal to facial nerve transfer: Case presentation and literature review. *Surg Neurol Int* 2012;3:46.

Available FREE in open access from: <http://www.surgicalneurologyint.com/text.asp?2012/3/1/46/95391>

Copyright: © 2012 Socolovsky M. This is an open-access article distributed under the terms of the Creative Commons Attribution License, which permits unrestricted use, distribution, and reproduction in any medium, provided the original author and source are credited.

Abstract

Background: Idiopathic facial nerve palsy (Bell's palsy) is a very common condition that affects active population. Despite its generally benign course, a minority of patients can remain with permanent and severe sequelae, including facial palsy or dyskinesia. Hypoglossal to facial nerve anastomosis is rarely used to reinnervate the mimic muscle in these patients. In this paper, we present a case where a direct partial hypoglossal to facial nerve transfer was used to reinnervate the upper and lower face. We also discuss the indications of this procedure.

Case Description: A 53-year-old woman presenting a spontaneous complete (House and Brackmann grade 6) facial palsy on her left side showed no improvement after 13 months of conservative treatment. Electromyography (EMG) showed complete denervation of the mimic muscles. A direct partial hypoglossal to facial nerve anastomosis was performed, including dissection of the facial nerve at the fallopian canal. One year after the procedure, the patient showed House and Brackmann grade 3 function in her affected face.

Conclusions: Partial hypoglossal–facial anastomosis with intratemporal drilling of the facial nerve is a viable technique in the rare cases in which severe Bell's palsy does not recover spontaneously. Only carefully selected patients can really benefit from this technique.

Key Words: Bell's palsy, facial palsy, hypoglossal–facial anastomosis, nerve transfer

Access this article online

Website:
www.surgicalneurologyint.com

DOI:
10.4103/2152-7806.95391

Quick Response Code:



INTRODUCTION

Facial palsy is a devastating psychological and social condition. One of the most common procedures for diminishing the consequences of facial palsy is hypoglossal–facial anastomosis.^[21] This procedure has a high rate of success, and even though it was described more than a century ago, variations of the original technique have

helped to keep the interest in it, prompting many recent literature reports.^[1,2,9,10,12,15,16,20,26,27,32]

Nevertheless, the vast majority of the more than 2500 cases of hypoglossal–facial anastomosis reported in the literature are either traumatic, due to direct cranial trauma, petrous bone fractures, or iatrogenic after resection of a cerebello-pontine angle tumor. Hypoglossal to facial nerve transfer for treating Bell's palsy, a very common cause of acute

spontaneous facial nerve palsy, has been exceptionally cited in the literature [Figure 1].^[7,31]

Even though the exact cause of Bell's (idiopathic) facial palsy is not known, many theories exist, including viral (herpes simplex, herpes zoster), immunological, or ischemic.^[11,14] The diagnosis is always done by exclusion.^[11,14,22-24] Symptoms are not only motor, but also include dry eye, salivation at the corner of the mouth, pain in or near the ear, taste alterations (via chorda tympani nerve), hypersensitivity to sounds, and alterations in hearing. The exact place and extent of the nerve compromise in this condition is not precisely determined and could involve a long tract of the nerve, with the swelling of the nerve inside the osseous facial canal being considered to play a major role in the pathophysiology of Bell's palsy. Therefore, with an extensive involvement of the facial nerve, it could be suspected that a reinnervation procedure like hypoglossal-facial anastomosis might not work because of alterations within the facial nerve that might impede the entry and the progression of regenerating axons. The hypothesized extensive longitudinal pathological involvement of the nerve that occurs in Bell's palsy; the type of myelin, axonal, and connective tissue injury; and the eventual target muscular changes in long-term paralyzed cases are all reasons that generate doubts regarding the possibility to obtain good results by using a procedure that requires, to be successful, a healthy target organ.

In Bell's palsy, another problem for nerve transfer is the surgical timing. On one hand, being a benign condition for which very few patients have severe sequelae, a long waiting period for spontaneous recovery should be

preferred before doing any restorative surgery. On the other hand, a long waiting period for performing the nerve transfer favors negative results because of mimic muscle atrophy.

The objective of the present work is: (1) to present a case of Bell's palsy in which the motor deficit remained unrecovered after a congruous waiting period, before an attempt to treat it with a partial hypoglossal nerve transfer was successfully done (to our knowledge, it is the first time this technique has been reported in the literature for Bell's palsy) and (2) to discuss the indications and timing of such reinnervating procedure considering also the other technical options available to treat facial paralysis.

CASE REPORT

A 53-year-old woman presented to us after she had a spontaneous left facial palsy on waking up from sleep. Some days before, she had a complaint of pain in her left ear, but an otological exam was completely normal, including the absence of vesicles at the external ear examination. She received steroids and started physiotherapy that continued for the following months without positive results. Ten months later, she was seen for the first time at the Nerve Surgery Center of the University of Buenos Aires School of Medicine with a complete left facial palsy requiring special care of the cornea to avoid ulcers, which were not present. The physical exam showed at that moment a complete palsy of the upper, lower, and middle left hemi-face [House and Brackmann (HB) grade 6]. She was incompetent to close

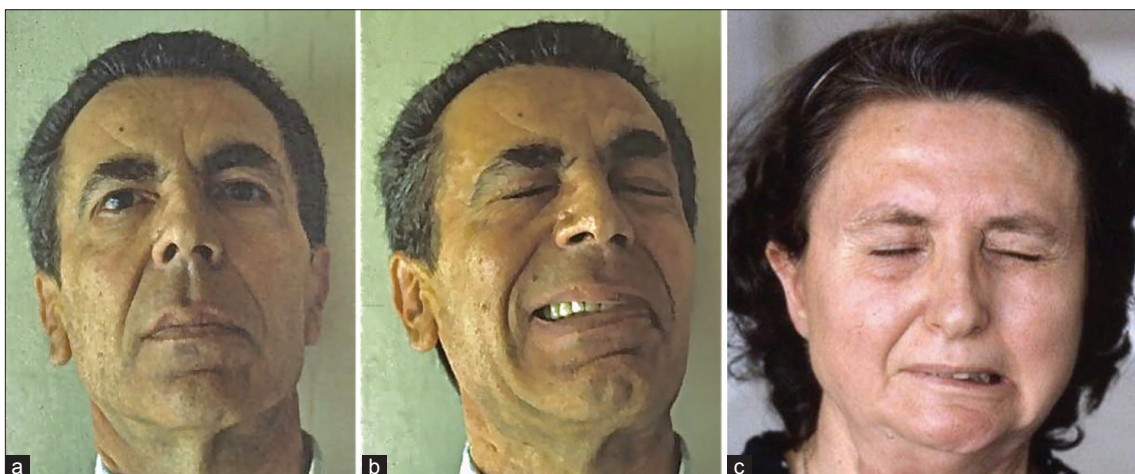


Figure 1: Historical vignette. These Bell's facial palsy cases, unpublished until now, were the only two operated by one of the authors (EF) during a period of more than 30 years (1980–2011), and were included to illustrate the rarity of this severe sequel in spontaneous facial palsy. An unrecovered facial Bell's palsy on the left side (House and Brackmann grade 6) affected a 55-year-old woman and a 54-year-old man. They were operated on employing the classical hypoglossal-facial anastomosis, 12 (July 1984) and 14 (August 1991) months after the beginning of the palsy, respectively. This technique involved complete section of the hypoglossal nerve to reinnervate the mimic muscles. In both patients, the acute event of Bell's palsy was treated shortly by low dosages of corticosteroids. At the time of operation, electromyography confirmed the clinically evident total facial paralysis. One year after operation, a good static and dynamic symmetry was obtained in both patients; the closure of the eye was complete (a–c). The final result was a House and Brackmann grade 3 in both patients

the left eye, the facial symmetry was lost, and she could not make any kind of active movement on the left side of the mouth. Signs of mimic muscle atrophy were evident on the affected side of the face [Figure 2]. The rest of the physical exam, including vertigo-dizziness tests and tongue movements, showed absolutely normal results. Magnetic resonance (MR) imaging showed a normal brain. Electromyography confirmed complete denervation of mimic muscles on the left side of the face, with fibrillations and positive sharp waves, and no voluntary motor action potentials in the affected muscles signs. She was entrusted to our intensive physiotherapy program at that moment, but no further improvement of the palsy was evident after reevaluation at 11 and 13 months. At that moment, a facial reinnervation procedure was offered to the patient, namely, a partial direct hypoglossal to facial nerve transfer involving mastoid bone drilling [Figure 3]. The procedure was accepted by the patient and finally performed 14 months after the start of the symptoms.

The surgical technique is described elsewhere.^[5,20] Briefly, the facial nerve is dissected at the temporal bone, into the fallopian canal, up to the second knee where the nerve is cut to be sutured directly to one-third of the hypoglossal nerve, in which partial section was done at the neck near the digastric muscle and the internal jugular vein. The nerve suture was performed with two 10.0 monofilament nylon stitches; fibrin glue was employed to reinforce the suture line. Macroscopically, no special changes were seen on the facial nerve with the exception of those normally seen after more than 1 year of palsy (namely, slight diminution of the nerve width compared to a normal nerve). The patient was discharged 3 days after the procedure. Physiotherapy was started again at our institution after 3 weeks.

Some active contraction of the facial muscles was seen 5

months after the procedure. At 12 months, the patient showed a complete facial symmetry at rest, active movements under voluntary control with mild eye–tongue synkinesia, adequate eye closure – which prompted her to abandon the artificial tears – and no signs of tongue atrophy or asymmetry (grade 1 tongue atrophy in the scale describing the grade of tongue dysfunction after hypoglossal–facial neurotomy).^[20] A grade 3 of the HB facial palsy scale was stated at that moment [Figure 4].

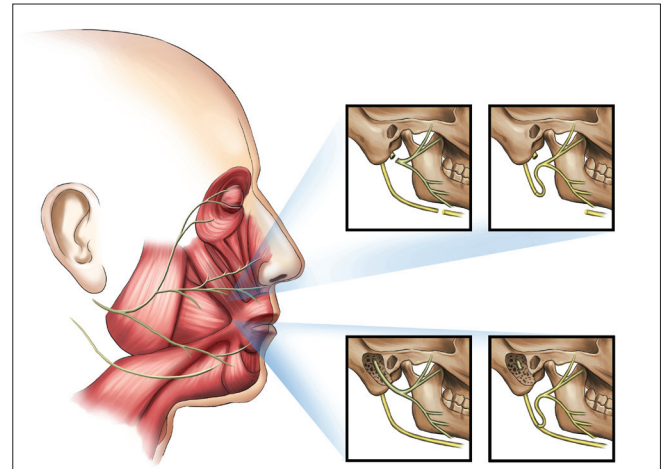


Figure 3: Classical and partial direct hypoglossal–facial anastomosis technique. The classical technique was employed in the historical cases presented in Figure 1 and has been the procedure of choice for facial reanimation for more than 100 years, since its original description by Korte in 1903. By contrast, the partial direct hypoglossal–facial anastomosis was described in 1997, and its main advantage is avoiding severe tongue atrophy. Upper left and right squares: classical technique with complete sectioning of the hypoglossal nerve. Bottom left and right squares: partial hypoglossal nerve sectioning, and anastomosis with a “longer” facial nerve obtained after drilling the mastoid bone. The main advantage of the partial section of the hypoglossal technique is avoiding the tongue atrophy

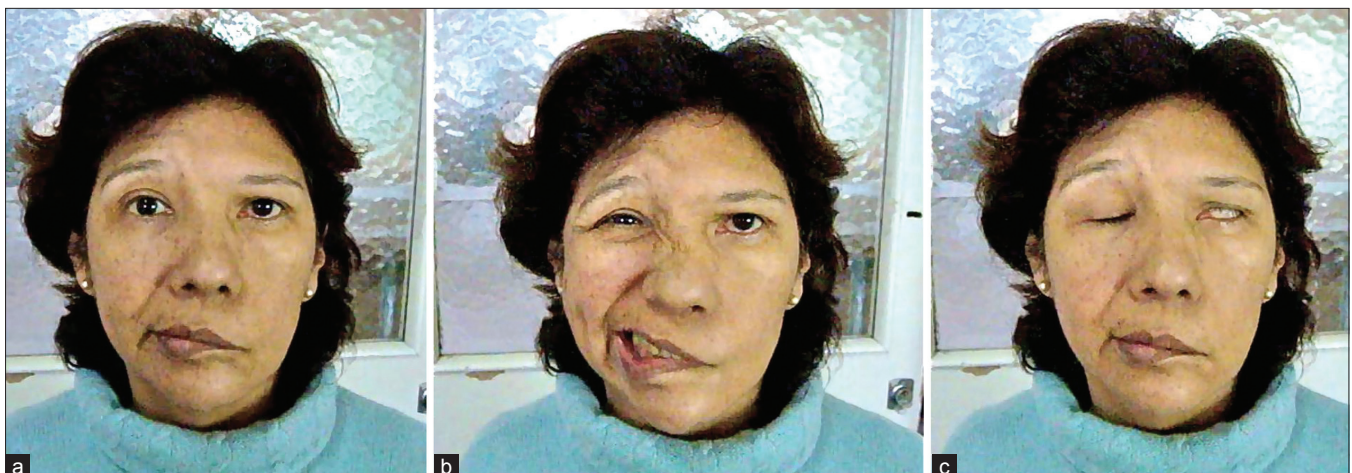

Figure 2: Preoperative (a–c) images of the presented case. House and Brackmann grade 6 left facial palsy was observed 13 months after the beginning of the spontaneous left facial palsy

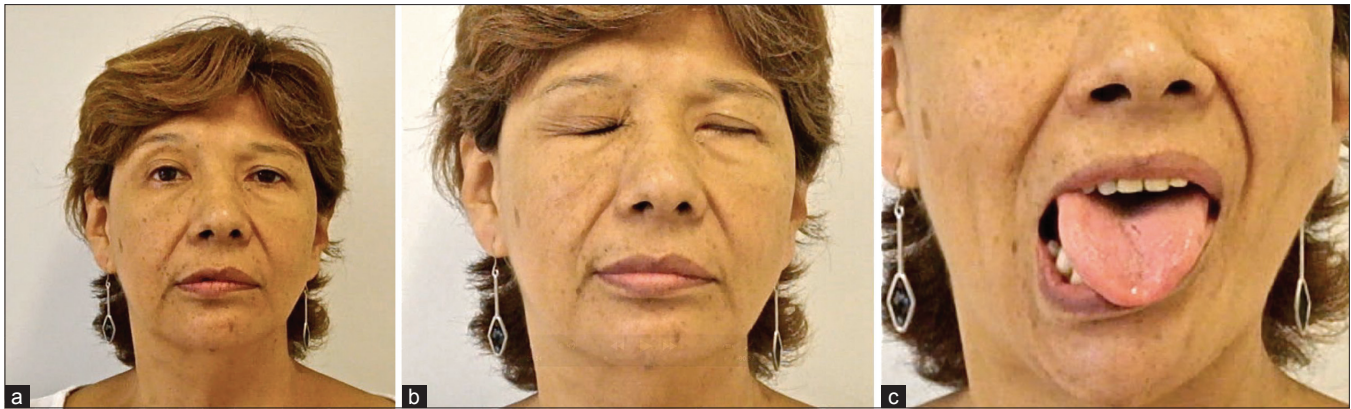

Figure 4: Postoperative (a–c) images of the presented case. A good symmetry at rest, good active movement, and no tongue atrophy were obtained

DISCUSSION

Spontaneous evolution of Bell's palsy

According to The Copenhagen Facial Nerve Study, spontaneous facial nerve palsy (Bell's palsy) is a benign condition which implies an acute unilateral partial or total facial motor deficit of undetermined etiology, having an incidence of 32/100,000, without seasonal, side, or gender variations, and is more frequent between 15 and 60 years.^[22-24] This Denmark group, after studying 2570 cases of facial nerve palsy, including 1701 cases of Bell's palsy, concluded that the onset was total in 30% and partial in 30% of their cases. Nevertheless, 85% of the patients evidenced recovery within 3 weeks and the remaining 15% in 3–5 months. A total of 71% of patients regained normal mimic function, and sequels were slight in 12%, mild in 13%, and severe in 4%. The authors did not find patients with permanent total palsy, but according to their own scale, 68 (4%) had a severe paresis at final follow-up with “just visible” function. Also interestingly, the authors concluded that if a patient does not show clear evidence of facial motion at 3 months, the probabilities of normalization are very low, and null if no signs of recovery are evident at 6 months. Prognosis of peripheral facial nerve palsies caused by herpes zoster is more severe: of 116 cases, only 21% achieved normal function, 25% had mild sequelae, 26% moderate, 24% severe, and 4% had no function at all. Diagnosis of herpes zoster was based on clinical observations (vesicles in the external meatus, soft palate, tongue, and vestibulocochlear dysfunction) and specific antibodies in serum and CSF. This study describes a scale, which differs (but is comparable) from the more popular HB scale.^[17] These findings regarding the poorer results of herpes zoster compromise of facial nerve were recently confirmed in an Asian study.^[25]

In a Switzerland study of 196 patients suffering from idiopathic facial palsy (Bell's and herpes zoster), the

results were similar and the prognosis was significantly different between individuals having at the onset a total facial deficit compared to those having a partial one; all but one patient had a normal functional recovery in the latter group, compared to one third remaining with deficits, including synkinesias, in the former).^[18]

On the other hand, Finester concluded in an extensive review that 15–20% of cases experience permanent damage to the nerve, 5% being severe.^[11] This includes not only severe paresis or paralysis, but also contractures, facial spasms, and synkinesias, together with decreased or crocodile tearing. Of note, the same author concluded that spontaneous amelioration can be expected up to 1 year after the onset of the symptoms.

The absence of complete (HB grade 6) long-term facial palsy in Bell's patients, as described by the Denmark group, has been contested. Terzis *et al.* describe many patients with severe idiopathic facial sequelae on whom they performed a series of different procedures.^[30] Two complete facial palsy cases from Bell's disease were described as receiving a free muscle transfer; and also recently, a nerve transfer from the masseteric nerve to the facial nerve was performed in a patient with an idiopathic facial palsy.^[4]

Classical treatment of Bell's palsy facial sequelae

Facial palsy can be treated by static and dynamic techniques. The natural evolution of Bell's palsy, as mentioned, is very good, with a minor proportion of the patients with sequelae, this deficit being mild in the vast majority. Therefore, many patients benefit from partial procedures, mainly static, to minimize this problem. This includes eyelid weight placement, lateral tarsorrhaphy, upper eyelid blepharoplasty, and static facial suspension, among others.

Many surgeons usually prefer dynamic procedures, even in patients with partial deficit. Examples of these partial techniques have been frequently reported in the

literature. Terzis *et al.* presented five cases of Bell's palsy, in which blinking was ameliorated by a nerve transfer or a free vascularized functional muscle transfer.^[28] Middle and lower face palsies can also be treated separately with dynamic techniques, yielding good results.^[13] Again, Terzis *et al.* used partial hypoglossal (so called mini-hypoglossal) technique for lower face reanimation in six Bell's patients and also direct muscle neurotization in 11 Bell's palsy sequelae individuals to innervate targeted mimic movements.^[29,31] Chuang employed a free muscle transfer technique in 249 patients with facial palsy, some of them idiopathic (no data regarding the exact number of Bell's palsy and its HB grade are given), with good results.^[6]

Bell's palsy and hypoglossal–facial anastomosis: Pros and cons

Nowadays, hypoglossal to facial nerve transfer still remains as the preferred means to surgically minimize the effects of facial palsy.^[21] This technique has a high rate of success. Whereas the classical one, using the whole hypoglossal nerve sutured to the facial nerve cut at the stilo-mastoid foramen, is not technically demanding, the partial hypoglossal nerve transfer with facial rerouting (employed in the presented case) requires some special anatomical knowledge of the petrous bone.^[20] According to the literature, a result of grade 3 or 4 in the HB scale is expectable, with some cases achieving a successful grade 2 (always considering that this scale was not originally described for this purpose).^[8,17]

Some reasons could explain the lack of popularity of hypoglossal transfer to facial nerve in Bell's palsy. Probably the most important reason is the fact that most of the cases recover completely, and if not, sequelae can be generally classified as grades 2, 3, or 4 in HB scale. Therefore, it sounds not logical to perform a surgery in a patient with a certain grade, to end up in the same grade months later. In this scenario, it is preferable to adopt some of the classical alternate techniques described before.

However, hypoglossal nerve transfer to the facial nerve should be considered, obviously, only in patients with HB 5 or 6, which as stated before are infrequent. The apparently lengthy nerve affection in Bell's palsy raises the question regarding the viability of the receptor nerve and the eventual result of such a nerve transfer. The results shown in this case and also in the scarce earlier reported ones with the classical technique demonstrate that those very rare cases of unrecovered Bell's palsy, of severe grade, can be successfully treated by hypoglossal–facial anastomosis. Furthermore, perhaps the indications of such nerve transfer could be extended also to those cases showing severe syncinesias, where botulin toxin injections do not work. If a hypoglossal nerve transfer is considered, the authors believe that at present the

procedure of choice is the direct partial hypoglossal to facial nerve transfer, used in the patient presented in this case report, which avoids severe tongue sequelae.

Finally, the surgical timing of such a nerve transfer is another issue to be considered. Mantsopoulos *et al.*, studying retrospectively 44 patients from Greece for a long term, also concluded, as many others, that if no recovery is seen after 1 year of palsy, no further improvement is to be expected later on.^[3,11,19,22-24] Classical hypoglossal to facial nerve anastomosis was performed in 43 patients after 2 years of paralysis; good results were obtained only in 41% of cases.^[7] Much more successful reinnervation of the face by the hypoglossal nerve can be achieved if surgery is performed between 1 and 1½ years.^[33] Thus, we can conclude that the ideal timing of a hypoglossal–facial anastomosis for a severe and permanent Bell's palsy patient should be around 1 year after the start of the symptoms.

CONCLUSIONS

Partial hypoglossal–facial anastomosis with intratemporal drilling of the facial nerve is a viable technique in the rare cases in which severe Bell's palsy does not recover spontaneously. Only carefully selected patients can really benefit from this technique.

REFERENCES

1. Arai H, Sato K, Yanai A. Hemihypoglossal-facial nerve anastomosis in treating unilateral facial palsy after acoustic neuroma resection. *J Neurosurg* 1995; 82:51-4.
2. Atlas MD, Lowinger DS. A new technique for hypoglossal-facial nerve repair. *Laryngoscope* 1997; 107:984-91.
3. Atzema C, Goldman RD. Should we use steroids to treat children with Bell's palsy? *Can Fam Physician* 2006; 52:313-4.
4. Biglioli F, Frigerio A, Colombo V, Colletti G, Rabbiosi D, Mortini P, *et al.* Masseteric-facial nerve anastomosis for early facial reanimation. *J Craniomaxillofac Surg* 2012; 40:149-55.
5. Campero A, Socolovsky M. Facial reanimation by means of the hypoglossal nerve: Anatomic comparison of different techniques. *Neurosurgery* 2007; 61 Suppl 3:41-9; discussion 49-50.
6. Chuang DC. Free tissue transfer for the treatment of facial paralysis. *Facial Plast Surg* 2008; 24:194-203.
7. Conley J, Baker DC. Hypoglossal–facial nerve anastomosis for reinnervation of the paralyzed face. *Plast Reconstr Surg* 1979; 63:63-72.
8. Coulson SE, Croxson GR, Adams RD, O'Dwyer NJ. Reliability of the "Sydney," "Sunnybrook" and "House Brackmann" facial grading systems to assess voluntary movement and syncinesias after facial nerve paralysis. *Otolaryngol Head Neck Surg* 2005; 132:543-9.
9. Darrouzet V, Guerin J, Bebear JP. New technique of side-to-end hypoglossal–facial nerve attachment with translocation of the infratemporal facial nerve. *J Neurosurg* 1999; 90:27-34.
10. Ferraresi S, Garozzo D, Migliorini V, Buffatti P. End-to-side intrapetrous hypoglossal–facial anastomosis for reanimation of the face. Technical note. *J Neurosurg* 2006; 104:457-60.
11. Finsterer J. Management of peripheral facial nerve palsy. *Eur Arch Otorhinolaryngol* 2008; 265:743-52.
12. Flores LP. Surgical results of the hypoglossal–facial nerve jump graft technique. *Acta Neurochir (Wien)* 2007; 149:1205-10, discussion 1210.
13. Ghali S, MacQuillan A, Grobbelaar AO. Reanimation of the middle and lower

- face in facial paralysis: Review of the literature and personal approach. *J Plast Reconstr Aesthet Surg* 2011;64:423-31.
14. Gilden DH. Clinical practice. Bell's Palsy. *N Engl J Med* 2004;351:1323-31.
 15. Godefroy WP, Malessy MJ, Tromp AA, van der Mey AG. Intratemporal facial nerve transfer with direct coaptation to the hypoglossal nerve. *Otol Neurotol* 2007;28:546-50.
 16. Guntinas-Lichius O, Streppel M, Stennert E. Postoperative functional evaluation of different reanimation techniques for facial nerve repair. *Am J Surg* 2006;191:61-7.
 17. House JW, Brackmann DE. Facial nerve grading system. *Otolaryngol Head Neck Surg* 1985;93:146-7.
 18. Linder TE, Abdelkafy W, Cavero-Vanek S. The management of peripheral facial nerve palsy: "Paresis" versus "paralysis" and sources of ambiguity in study designs. *Otol Neurotol* 2010;31:319-27.
 19. Mantsopoulos K, Psillas G, Psychogios G, Brase C, Iro H, Constantinidis J. Predicting the long-term outcome after idiopathic facial nerve paralysis. *Otol Neurotol* 2011;32:848-51.
 20. Martins RS, Socolovsky M, Siqueira MG, Campero A. Hemihypoglossal-facial neurotization after mastoid dissection of the facial nerve: Results in 24 patients and comparison with the classic technique. *Neurosurgery* 2008;63:310-6, discussion 317.
 21. Ozsoy U, Hizay A, Demirel BM, Ozsoy O, Bilmen Sarikcioglu S, Turhan M, et al. The hypoglossal-facial nerve repair as a method to improve recovery of motor function after facial nerve injury. *Ann Anat* 2011;193:304-13.
 22. Peitersen E. The natural history of Bell's palsy. *Am J Otol* 1982;4:107-11.
 23. Peitersen E. Natural history of Bell's palsy. *Acta Otolaryngol Suppl* 1992;492:122-4.
 24. Peitersen E. Bell's palsy: The spontaneous course of 2,500 peripheral facial nerve palsies of different etiologies. *Acta Otolaryngol Suppl* 2002;549:4-30.
 25. Ryu EV, Lee HY, Lee SY, Park MS, Yeo SG. Clinical manifestations and prognosis of patients with Ramsay Hunt syndrome. *Am J Otolaryngol* 2011. [In press]
 26. Sawamura Y, Abe H. Hypoglossal-facial nerve side-to-end anastomosis for preservation of hypoglossal function: Results of delayed treatment with a new technique. *J Neurosurg* 1997;86:203-6.
 27. Shipchandler TZ, Seth R, Alam DS. Split hypoglossal-facial nerve neurotization for treatment of the paralyzed face. *Am J Otolaryngol* 2011;32:511-6.
 28. Terzis JK, Karypidis D. Blink restoration in adult facial paralysis. *Plast Reconstr Surg* 2010;126:126-39.
 29. Terzis JK, Karypidis D. Outcomes of direct muscle neurotization in adult facial paralysis. *J Plast Reconstr Aesthet Surg* 2011;64:174-84.
 30. Terzis JK, Olivares FS. Long-term outcomes of free-muscle transfer for smile restoration in adults. *Plast Reconstr Surg* 2009;123:877-88.
 31. Terzis JK, Tzafetta K. Outcomes of mini-hypoglossal nerve transfer and direct muscle neurotization for restoration of lower lip function in facial palsy. *Plast Reconstr Surg* 2009;124:1891-904.
 32. Ueda K, Akiyoshi K, Suzuki Y, Ohkouchi M, Hirose T, Asai E, et al. Combination of hypoglossal-facial nerve jump graft by end-to-side neurotization and cross-face nerve graft for the treatment of facial paralysis. *J Reconstr Microsurg* 2007;23:181-7.
 33. Volk GF, Pantel M, Guntinas-Lichius O. Modern concepts in facial nerve reconstruction. *Head Face Med* 2010;6:25.