



Case report

Dieulafoy's lesion in the cecum: A rare case report presentation

Ana Matos Ribeiro^{*}, Sílvia da Silva, Rui Almeida Reis, Inês Romero, Susana Costa, João Barros da Silva

Department of General Surgery, Centro Hospitalar Tâmega e Sousa, Penafiel, Portugal

ARTICLE INFO

Keywords:

Dieulafoy's lesion
Calibre persistent artery
Vascular malformation
Acute gastrointestinal bleeding
Haematochezia

ABSTRACT

Introduction and importance: Dieulafoy's lesion is a rare entity, normally present in the stomach and more rarely in the colon, and it is responsible for 1% to 5% of acute gastrointestinal bleeding cases. Its true incidence may be underrated, since most cases are asymptomatic and difficult to diagnose despite endoscopic advances. We present a clinical case of acute gastrointestinal bleeding due to Dieulafoy's lesion in the cecum.

Case presentation: An 85-year-old woman presented with a clinical condition of haematochezia associated with anaemia and haemodynamic instability, needing blood transfusion. Colonoscopy demonstrated a Dieulafoy's lesion in the cecum with active bleeding, and haemostasis was performed successfully with localized adrenaline injection and haemostatic clip placement. Hospitalization occurred without further complications.

Discussion: The diagnosis of Dieulafoy's lesion is difficult because it is a rare condition and thus, usually not included in the differential diagnosis of gastrointestinal bleeding. Its endoscopic diagnostic and therapeutic approach is the standard method in the event of an acute gastrointestinal bleeding episode, with greater efficiency with the combined use of haemostatic techniques. Surgery is necessary in less than 5% of cases when bleeding is not effectively controlled by endoscopic or angiographic techniques.

Conclusion: It is essential to be aware of this lesion as a possible cause of gastrointestinal bleeding and differentiate it from other causes. Advances in endoscopy have increased the rate of diagnosis of these lesions and reduced their associated mortality.

1. Introduction

Acute gastrointestinal bleeding is a frequent medical condition with a potential of significant morbidity and mortality. Symptoms and severity vary depending on the location and bleeding output. The common causes include peptic ulcers and gastroesophageal or duodenal erosions [1,2]. Dieulafoy's lesion is a rare cause of acute gastrointestinal bleeding [1,3].

Dieulafoy's lesion, first reported by Gallard in 1984 and then described in detail by Georges Dieulafoy in 1898, is a rare vascular malformation characterized by an abnormally dilated submucosal artery (1 to 3 mm). Since its description first, it has rarely been reported in the literature. These lesions can be found in any location of the gastrointestinal tract; however, they occur more frequently in the stomach and rarely in the colon [2,4].

This uncommon lesion normally presents without associated symptoms. It is diagnosed by gastrointestinal endoscopy. When the patient

presents with bleeding, most cases require therapy to control it, which is mainly performed by minimally invasive methods, such as endoscopy or angiography; a few cases need surgery [4,5].

This report presents a clinical case of gastrointestinal bleeding due to Dieulafoy's lesion in the cecum, a very rare location with sparse literature representation. This article has been written in accordance with the SCARE 2020 criteria [6].

2. Presentation of case

An 85-year-old woman was institutionalized at a retirement home and was partially dependent for daily life activities with multiple medical and surgical backgrounds (arterial hypertension, dyslipidaemia, grade II obesity, class II heart failure, chronic renal disease, atrial fibrillation and biological aortic valve prosthesis under oral hypocoagulation with apixaban, and antiplatelet therapy with aspirin).

The patient was admitted to the emergency room with a clinical

^{*} Corresponding author at: Department of General Surgery, Centro Hospitalar Tâmega e Sousa, Avenida do Hospital Padre Américo, número 210, 4564-007 Penafiel, Portugal.

E-mail address: 73228@chts.min-saude.pt (A.M. Ribeiro).

<https://doi.org/10.1016/j.ijscr.2021.106157>

Received 1 June 2021; Received in revised form 24 June 2021; Accepted 26 June 2021

Available online 30 June 2021

2210-2612/© 2021 Published by Elsevier Ltd on behalf of IJS Publishing Group Ltd. This is an open access article under the CC BY-NC-ND license

(<http://creativecommons.org/licenses/by-nc-nd/4.0/>).

condition of ongoing haematochezia for two days and an associated episode of syncope. On physical examination, she was hypotensive (96/50 mmHg) and had bright red blood on rectal examination, without other major associated changes. Blood analysis revealed a haemoglobin level of 3.7 g/dL and acute renal dysfunction with a creatinine level of 2.2 mg/dL, thus requiring intravenous fluid therapy and 5 units of erythrocyte concentrate transfusion.

After colonic preparation, a colonoscopy was performed that showed the presence of a tortuous pulsatile vessel in the submucosa of the cecum (suggestive of Dieulafoy's lesion) with oozing haemorrhage (Figs. 1 and 2).

Endoscopic haemostasis with local injection of 6 mL of adrenaline and placement of haemostatic clips on the vessel (Fig. 3) was performed.

For long-term maintenance, we decided to stop aspirin and restart apixaban after discussion with the Cardiology Department and analysing the patient's risk-benefit ratio.

During hospitalization, the patient was stable with no new haematic losses; the haemoglobin levels were stable at 8.8 g/dL with resolution of the acute renal dysfunction presented at admission (creatinine level of 1.3 mg/dL at discharge).

The patient was discharged after 6 days of hospitalization with no complications.

3. Discussion

Gastrointestinal bleeding is one of the most common medical emergencies in the world, with an incidence of 50 to 150 per 100,000 individuals each year [1–3]. Upper gastrointestinal bleeding is approximately four times more frequent than lower gastrointestinal bleeding [7]. Almost 80% of bleeding cases are caused by ulcerative disease, varicose disease or angiectasis, with occult haemorrhage occurring in less than 5% of cases [2].

Dieulafoy's lesion, also known as calibre persistent artery, is a rare vascular malformation, which is an uncommon cause of potentially life-threatening bleeding [2,3]. Despite its rarity, it is being increasingly reported due to the widespread use of endoscopy. The artery is otherwise histologically normal; however, it consists of an aberrant submucous artery, in the absence of a primary ulcer, that erodes the epithelium and does not normally branch to the mucosa, maintaining a diameter of 1 to 3 mm (a calibre 10 times larger than a normal mucous capillary) [4,9,10]. These lesions are thought to be the cause of only 1% to 5% of all gastrointestinal bleeding cases. Most cases are asymptomatic and even with clinical presentation its diagnosis is difficult; therefore, its true incidence is unknown [2,3,8,10].

Its pathophysiology is not fully understood, and two main hypotheses are currently proposed. The first is that of a congenital base predisposing to the appearance of an abnormally dilated artery with risk of

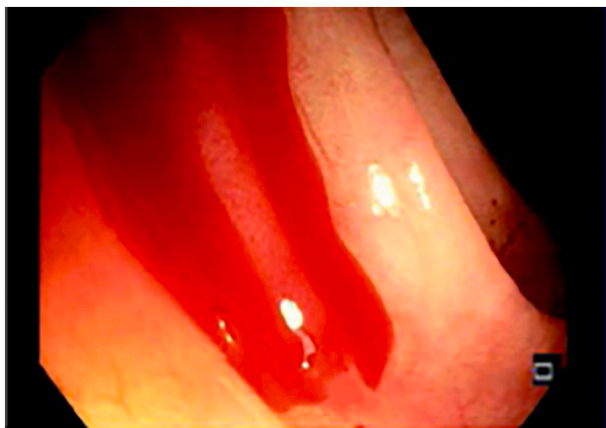


Fig. 1. Dieulafoy's lesion with oozing haemorrhage.

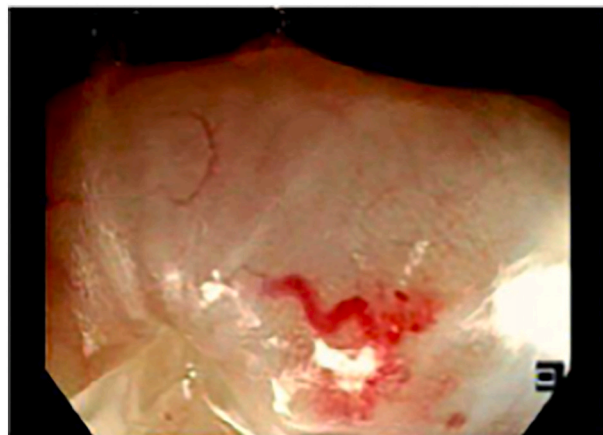


Fig. 2. Dieulafoy's lesion after washing with saline fluid.

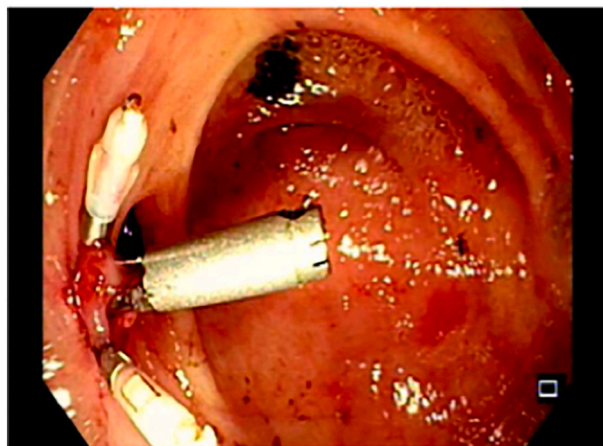


Fig. 3. Dieulafoy's lesion after endoscopic haemostasis.

protrusion, rupture, and haemorrhage. The second hypothesis is based on a degenerative background caused by oxidative and ischemic stress of diverse or even multifactorial causes, such as chronic gastritis, previous surgeries, and alcohol consumption or non-steroidal anti-inflammatory drug usage [2,4,10–12]. Despite its uncertain pathogenesis, it is known that these vascular lesions are more frequent in the elderly or individuals with more underlying diseases [2,4,9,11,13].

Dieulafoy's lesions affect males twice as often as females and can occur at any age [2,5,14]. The stomach is the most commonly affected organ (80% to 95%), usually at 5 to 6 cm from the gastroesophageal junction along the lesser curvature. However, they can be found at any gastrointestinal location, including the oesophagus, small intestine, colon, or rectum; although, these locations are much less frequent [2–4,8].

The lesion usually remains asymptomatic until the overlying epithelium completely erodes with full arterial exposure [2,5,14]. The mechanism that causes haemorrhage is still unclear; however, there is a general consensus that a mucosal erosion or ischemic lesion leads to greater weakening of an intrinsically vulnerable point, possibly leading to bleeding and unmasking this silent abnormality [2,12].

Its presentation depends on its location, ranging from haematemesis or melena to haematochezia or fresh bleeding per rectum. Most of the haemorrhage caused is intermittent and severe, with haemodynamic instability present in almost 80% of the cases. The mortality has decreased significantly due to the effectiveness of the treatment [2–5,14].

The present patient had a Dieulafoy's lesion present in the colon,

namely in the cecum. As reported in the literature, she had significant haemorrhage with haemodynamic instability, thus requiring blood transfusion. The first lesion to be found and reported in the colon was originally described in 1985 by Barbier. Since then, limited cases of colonic lesions have been published, mostly located in the right colon [14].

The diagnosis is challenging since these lesions have a small and indiscriminate dimension with intermittent bleeding; besides, its rarity can lead to it being easily confused with other lesions such as arteriovenous malformations and aneurysms [4,5,14]. Gastrointestinal endoscopy is the first line diagnostic procedure since it allows for diagnosis and a possible therapeutic approach during active bleeding [4,5]. Endoscopy is effective in diagnosing about 70% of the patients, and diagnostic accuracy increases with active bleeding. For this reason, this diagnosis should always be considered during an endoscopic examination without a clear bleeding identification. The presence of an isolated protruding vessel surrounded by normal mucosa without any ulcer or associated mass are classic endoscopic findings [2,4,11].

Despite the existence of several effective therapeutic approaches, there is neither consensus nor randomized controlled studies comparing the different endoscopic techniques. However, endoscopic treatment has been the method of choice since this approach has been shown to be effective towards bleeding from a Dieulafoy's lesion with a success rate of over 90% [2,4]. Studies demonstrated a higher success rate with mechanical haemostatic techniques than with local haemostatic injections alone [2,4,15]. In addition, the combined use of different endoscopic techniques showed a lower rate of haemorrhagic recurrence compared with endoscopic monotherapy [4,9,16]. In most cases, haemostasis is achieved through local injection of epinephrine in conjunction with heat probe coagulation or haemostatic clip placement [4,17,18].

When endoscopy fails to find the bleeding source, angiography may be helpful in locating and controlling it, with selective arterial embolization. This approach should be used in endoscopic failure, lesions not accessible by endoscopy and patients unsuitable for surgery [2,8,19]. Surgical treatment is necessary in less than 5% of cases, being reserved only when endoscopic or angiographic treatment fail [2,8,11,20].

The present case of Dieulafoy's lesion in the colon was diagnosed through colonoscopy, performed after patient's stabilization, with effective haemostasis after combined use of endoscopic techniques (local injection of adrenaline and placement of haemostatic clips), as well as most lesions reported in the literature.

The risk of bleeding recurrence varies between 9% and 40% and is higher when endoscopic monotherapy is performed. Repeated endoscopy is the therapy of choice in the evidence of recurrence [9,11,21]. The prognosis for acute bleeding due to a Dieulafoy's lesion is better than that caused by ulcerative disease, matching that endoscopic advances have increased the diagnostic rate and decreased the mortality rate from 80% to 8.6% [9,19,21]. In the present case, treatment was effective without recurrence, and therefore, a favourable outcome was seen.

4. Conclusion

Dieulafoy's lesion in the colon is a very rare entity with a potential for massive haemorrhage with consequent mortality. Its diagnosis is difficult, mainly due to its rarity, especially when this lesion is found in less frequent locations. Endoscopic treatment is the first diagnostic and therapeutic choice due to its effectiveness, mainly through the combined use of available techniques, as performed in the presented case. Clinicians should be aware of this lesion as a possible cause of gastrointestinal bleeding; thus being able to differentiate it from others aetiologies for selective and prompt therapeutic management.

Funding

This research did not receive any specific grant from funding

agencies in the public, commercial, or not-for-profit sectors.

Ethical approval

No ethical approval was obtained as it is a case report but a written consent was taken from the patient.

Consent

Written informed consent was obtained from the patient for publication of this case report and accompanying images. A copy of the written consent is available for review by the Editor-in-Chief of this journal on request.

Author contribution

Ana Matos Ribeiro – Study design, data collection, and writing the paper.

Sílvia da Silva – Reviewing the paper.

Rui Almeida Reis – Reviewing the paper.

Inês Romero – Study design and reviewing the paper.

Susana Costa – Study design and reviewing the paper.

João Barros da Silva – Reviewing the paper.

Research registration

Our paper is a case report; no registration was done for it.

Guarantor

Ana Matos Ribeiro: ana_claudia_acmr@hotmail.com.

Provenance and peer review

Not commissioned, externally peer-reviewed.

Declaration of competing interest

All authors have nothing to disclose.

Acknowledgement

None.

References

- [1] K.R. Palmer, Non-variceal upper gastrointestinal haemorrhage: guidelines, *Gut* 51 (2002) iv1–iv6.
- [2] M. Baxter, E.H. Aly, Dieulafoy's lesion: current trends in diagnosis and management, *Ann R Coll Surg Engl* 92 (2010) 548–554.
- [3] H.F. Reilly, F.H. Al-Kawas, Dieulafoy's lesion. Diagnosis and management, *Dig. Dis. Sci.* 36 (1991) 1702–1707.
- [4] Z. Kaufman, S. Liverant, B. Shiptz, A. Dinbar, Massive gastrointestinal bleeding caused by Dieulafoy's lesion, *Am. Surg.* 61 (1995) 453–455.
- [5] P.A. Gambhire, S.S. Jain, P.M. Rathi, A.D. Amarpurkar, Dieulafoy disease of stomach—an uncommon cause of gastrointestinal system bleeding, *J. Assoc. Physicians India* 62 (2014) 526–528.
- [6] R.A. Agha, T. Franchi, C. Sohrabi, G. Mathew, A. Kerwan, A. Thoma, et al., The SCARE 2020 guideline: updating consensus Surgical CAse REport (SCARE) guidelines, *Int. J. Surg.* 84 (2020) 226–230.
- [7] M.A. Fallah, C. Prakash, S. Edmondowicz, Acute gastrointestinal bleeding, *Med. Clin. North Am.* 84 (2000) 1183–1208.
- [8] R.A. Chaer, W.S. Helton, Dieulafoy's disease, *J. Am. Coll. Surg.* 196 (2003) 290–296.
- [9] Y.T. Lee, R.S. Walmsley, R.W. Leong, J.J. Sung, Dieulafoy's lesion, *Gastrointest. Endosc.* 58 (2003) 236–243.
- [10] L.F. Lara, J. Sreenarasimhaiah, S.J. Tang, B.B. Afonso, D.C. Rockey, Dieulafoy lesions of the GI tract: localization and therapeutic outcomes, *Dig. Dis. Sci.* 55 (2010) 3436–3441.
- [11] G. Marangoni, A.B. Cresswell, W. Faraj, H. Shaikh, M.J. Bowles, An uncommon cause of lifethreatening gastrointestinal bleeding: 2 synchronous Dieulafoy lesions, *J. Pediatr. Surg.* 44 (2009) 441–443.
- [12] N. Schmulewitz, J. Baillie, Dieulafoy lesions: a review of 6 years of experience at a tertiary referral center, *Am. J. Gastroenterol* 96 (2001) 1688–1694.

- [13] M. Marchese, R. De Cristofaro, A.B. Federici, A. Biondi, L. Petruzzello, A. Tringali, et al., Duodenal and gastric Dieulafoy's lesions in a patient with type 2A von Willebrand's disease, *Gastrointest. Endosc.* 61 (2005) 322–325.
- [14] R. Jain, R. Chetty, Dieulafoy disease of the colon, *Arch. Pathol. Lab. Med.* 133 (2009) 1865–1867.
- [15] I.K. Chung, E.J. Kim, M.S. Lee, H.S. Kim, S.H. Park, M.H. Lee, et al., Bleeding Dieulafoy's lesions and the choice of endoscopic method: comparing the hemostatic efficacy of mechanical and injection methods, *Gastrointest. Endosc.* 52 (2000) 721–724.
- [16] A. Batouli, A. Kazemi, M.S. Hartman, M.T. Heller, R. Midian, A.R. Lupetin, Dieulafoy lesion: CT diagnosis of this lesser-known cause of gastrointestinal bleeding, *Clin. Radiol.* 70 (2015) 661–666.
- [17] E. Dulic-Lakovic, M. Dulic, D. Hubner, H. Fuchssteiner, T. Pachofszky, B. Stadler, et al., Bleeding Dieulafoy lesions of the small bowel: a systematic study on the epidemiology and efficacy of enteroscopic treatment, *Gastrointest. Endosc.* 74 (2011) 573–580.
- [18] Y. Yamaguchi, T. Yamato, N. Katsumi, Y. Imao, K. Aoki, Y. Morita, et al., Short-term and long-term benefits of endoscopic hemoclip application for Dieulafoy's lesion in the upper GI tract, *Gastrointest. Endosc.* 57 (2003) 653–656.
- [19] G. Alshumrani, M. Almuaikel, Angiographic findings and endovascular embolization in Dieulafoy disease: a case report and literature review, *Diagn. Interv. Radiol.* 12 (2006) 151–154.
- [20] T.R. Sai Prasad, K.H. Lim, K.H. Lim, T.L. Yap, Bleeding jejunal Dieulafoy pseudopolyp: capsule endoscopic detection and laparoscopic-assisted resection, *J. Laparoendosc. Adv. Surg. Tech. A* 17 (2007) 509–512.
- [21] L.F. Luis, J. Sreenarasimhaiah, S. Jiang Tang, B.B. Afonso, D.C. Rockey, Localization, efficacy of therapy, and outcomes of Dieulafoy lesions of the GI tract - the UT Southwestern GI Bleed Team experience, *Gastrointest. Endosc.* 67 (2008) AB87, <https://doi.org/10.1016/j.gie.2008.03.063>.