



Herpesvirus associated dermal papillomatosis in Williams' mud turtle *Pelusios williamsi* with effects of autogenous vaccine therapy

Pavel ŠIROKÝ^{1)*}, Fredric L. FRYE²⁾, Nela DVOŘÁKOVÁ^{1,3)}, Martin HOSTOVSKÝ⁴⁾, Hynek PROKOP⁵⁾ and Pavel KULICH⁶⁾

¹⁾Department of Biology and Wildlife Diseases, Faculty of Veterinary Hygiene and Ecology, University of Veterinary and Pharmaceutical Sciences Brno, Palackého 1946/1, 612 42 Brno, Czech Republic

²⁾La Primavera Organic Farm, 33422 Highway 128, Cloverdale, California 95425-9428 U.S.A.

³⁾Institute for State Control of Veterinary Biologicals and Medicines, Hudcova 56a, 621 00 Brno, Czech Republic

⁴⁾Department of Animal Protection, Welfare and Behaviour, Faculty of Veterinary Hygiene and Ecology, University of Veterinary and Pharmaceutical Sciences Brno, Palackého 1946/1, 612 42 Brno, Czech Republic

⁵⁾U Zámečku, 459, 530 03 Pardubice, Czech Republic

⁶⁾Veterinary Research Institute, v.v.i., Hudcova 70, 621 00 Brno, Czech Republic

ABSTRACT. An adult female of Williams' mud turtle, *Pelusios williamsi* long-term captive, that was allegedly caught wild in Kenya was found to have developed papilloma-like skin lesions. Excised tumors were examined histologically after routine processing with hematoxylin and eosin (H & E) stained slides, examined for the presence of viral particles by electron microscopy employing negative staining, and examined for the presence of viral DNA by PCR. Microscopic features in pre-treatment biopsies were fully diagnostic and consistent with multifocal squamous cell papilloma. Viral-type inclusion bodies were not identified. Turtle was found to be infected by reptilian herpesvirus. Association with herpesvirus and vast multiplicity of tumors thwarted surgical solution. An autogenous vaccine was prepared using 5 g of excised fresh tissue, aseptically ground, treated with diluted formalin, centrifuged to obtain a supernatant, and subsequently exposed to UV light. Autogenous vaccine induced substantial areas of necrosis of the papillomatous lesions noted by the loss of cytological architecture, nuclear loss, and by edema. The outer edges of the healing biopsies appeared to be regenerating. Therefore, our vaccine application could be considered as effective. It is difficult to treat and eliminate herpesvirus infection because of its cryptic presence and sudden onset of disease. Successful application of autogenous vaccine could be a potentially promising strategy, which deserves further testing.

KEY WORDS: autogenous vaccine, herpesvirus, histology, PCR

J. Vet. Med. Sci.

80(8): 1248–1254, 2018

doi: 10.1292/jvms.18-0126

Received: 12 March 2018

Accepted: 28 May 2018

Published online in J-STAGE:

11 June 2018

Neoplastic skin disorders in reptiles are represented by numerous kinds of tumors [9, 12, 19, 31]. Among them, papillomata, which have recently been most intensively studied, because of the growing incidence of fibropapillomatosis in cheloniid sea turtles, thus, representing an emerging health problem and by its massive circumtropical occurrence representing one of the possible threats for future survival of sea turtles' populations [1]. The presence of herpesvirus associated with similar proliferative and/or ulcerative lesions of the skin and shell has also been reported in freshwater turtles, namely in common snapping turtles (*Chelydra serpentina*), matamata (*Chelus fimbriatus*), box turtles (*Terrapene carolina*), and Krefft's river turtle (*Emydura macquarii krefftii*) that were often kept in long-term captivity [5, 9, 47]. Reports on papillomata in other reptilian taxa are substantially less frequent except some taxa of squamates, especially green lizards (*Lacerta viridis*) [26, 27, 39].

Presence of herpesviruses is frequently reported and considered as a possible causative agent [17] in such cases with environmental circumstances as cofactors [3, 25]. Herpesviruses are of significant concern in various diseases of chelonians. They have been reported to be associated with necrotizing and ulceration of respiratory and gastrointestinal tract (e.g. stomatitis-rhinitis, stomatitis-glossitis syndromes) in tortoises [4, 28, 42], lethargy, anorexia, subcutaneous edema and hemorrhages in emydid freshwater turtles [8, 11, 23], lung, eye, and trachea disease (LETD), gray-patch disease, and green turtle fibropapillomatosis (GTFP) in cheloniid sea turtles [22, 24, 38]. Reptilian herpesviruses are now classified in the subfamily *Alphaherpesvirinae* [13].

*Correspondence to: Široký, P.: sirokyp@vfu.cz

©2018 The Japanese Society of Veterinary Science



This is an open-access article distributed under the terms of the Creative Commons Attribution Non-Commercial No Derivatives (by-nc-nd) License. (CC-BY-NC-ND 4.0: <https://creativecommons.org/licenses/by-nc-nd/4.0/>)




Fig. 1. Macroscopic view of neoplasia; a) neoplastic changes on turtle's head partially affected the ability of its retraction beneath the shell; b) neoplastic changes on the hind limb after their generalization.

Williams' mud turtle (*Pelusios williamsi*) is native to eastern Africa, around Lakes Victoria, Edward, and Albert in eastern Democratic Republic of Congo, Uganda, western Kenya, and northern Tanzania [7, 18]. Lakes, rivers and swamps represent their typical habitat [6]. A case of neoplastic skin disorder in this turtle species is described in this paper.

MATERIALS AND METHODS

All procedures with animal were in compliance with national legislation (Act No. 246/1992 Coll., on the Protection of Animals Against Cruelty, as amended) and they were approved by the Institutional Commission on Animal Protection at University of Veterinary and Pharmaceutical Sciences Brno.

Clinical signs and gross pathology

A mature female of Williams' mud turtle, which was a long-term captive, but allegedly originating from nature of Kenya was diagnosed for chronic, proliferative, skin lesions. Multifocal proliferative pathologic changes were first identified on her head, later spreading to soft parts of the body and eventually, becoming generalized. The majority of the affected tissues interfered with the turtle's movement and partly affected the turtle's ability to retract its head beneath its shell (Fig. 1A). Grossly, the raised lesions appeared characteristic of squamous cell papillomata (Fig. 1B). We considered resolving the turtle's condition surgically. However, because of the multiplicity and confluent nature of the lesions which involved the external soft body tissues, it was impossible to surgically excise each of the tumors individually. Instead, an autogenous vaccine was prepared and administered by repeated injections. To evaluate whether the autogenous vaccine was effective, we excised several other papillomatous masses for repeated histological examinations after the first and the second dose injections, respectively [10].

Surgery and tissue sampling

The turtle was anesthetized with ketamine hydrochloride (80 mg/kg, IM) and the full thickness of selected tumors were excised with wide margins of apparently normal skin. The excised tissue was divided into three parts. One portion that was intended for histological examination was fixed in 10% neutral-buffered formalin and processed routinely and stained with hematoxylin and eosin (H & E). The second part was set aside for diagnosis of the presence of viral particles by electron microscopy and thus frozen at -20°C . Third portion meant for PCR based diagnosis of presence of viral DNA was stored in 96% pure ethanol at -20°C .

Histological processing

Representative specimens from multifocal raised papillomatous lesions were preserved in neutral buffered formalin and cut into blocks measuring 2–3 mm for histopathological processing and microscopic examination. Each of these specimens was processed by routine histological methods, cut to 5 μm thickness, dehydrated, stained with H & E, mounted, coverslipped prior to microscopic examination, and representative microscopic fields were imaged.

Electron microscopy

Samples of skin lesions taken for negative staining were homogenized and suspended within a drop of distilled water. The resulting suspension was covered with a grid coated formvar film and carbon (Sigma-Aldrich, Prague, Czech Republic). The grid was removed from the suspension after 10–15 sec, and the residual water was dried with a strip of filtration paper. A drop of 2% ammonium molybdate NH_4MoO_4 (SERVA, Heidelberg, Germany) was placed onto the grid for a few seconds, and then excess stain was dried with filtration paper. Sections prepared in this way were observed under a Philips 208s Morgagni electron

microscope (FEI, Brno, Czech Republic) at 18,000 × magnification and an accelerating voltage of 80 kV.

Preparation and application of autogenous vaccine

Autogenous vaccine was prepared using circa 5 g of excised fresh tissue. It was ground aseptically with sterile sand and tissue culture diluents (10 ml). It then was treated with diluted formalin solution (2%, 5 ml) for one hour and then centrifuged to obtain a supernatant product. Five ml of supernatant was subsequently exposed to unfiltered artificial UV light (including UV-C) for one hour. The vaccine was stored at –20°C. Before its application, we were assured that the turtle did not receive any corticosteroid therapy in the previous period.

Two doses of 1 ml each were injected intramuscularly into the turtle, with boosting dose 4 weeks apart, with each dose divided into two halves applied to different parts of the body.

DNA isolation and PCR

Overnight incubation of tissue sample with a proteinase K preceded DNA isolation. NucleoSpin Tissue kit (Macherey-Nagel, Düren, Germany) was used for extracting whole genomic DNA according to the manufacturer's instructions. DNA was eluted in 100 µl of the provided elution buffer water and then stored at –20°C. Amplification of approximately 215 to 315 bp long fragment of the herpesviral DNA-directed DNA polymerase gene was performed by nested-PCR protocol [46]. In the first step of PCR reaction, a pair of upstream primers (DFA, 5'-GAYTTYGCNAGYYTNTAYCC-3'; and ILK, 5'-TCCTGGACAAGCAGCARNYSGCNMTNAA-3') and one downstream primer (KG1, 5'-GTCTTGCTCACCAGNTCNACNCCYTT-3') in a multiplex format were used. Upstream primer (TGV, 5'-TGTAACCTCGGTGTAYGGNTTYACNGGNGT-3') and downstream primer (IYG, 5'-CACAGAGTCCGTRTCNCRTADAT-3') were included in the second PCR step. Both PCR reactions were prepared in a total volume 25 µl; primary mixture consisted of 12.5 µl of Combi PPP Master Mix (Top-Bio, Vestec, Czech Republic), 1 µl of each 10 µM PCR primer (KRD, Prague, Czech Republic), 8.5 µl of PCR water (Top-Bio) and 1 µl of isolated DNA. Secondary mixture was comprised 12.5 µl of mastermix, 1 µl of each 10 µM PCR primer and 8 µl of PCR water. A 2.5 µl aliquot of PCR product of the first reaction was utilized as a template for the secondary reaction. PCR products of expected sizes were purified by Gel/PCR DNA Fragments Extraction Kit (Geneaid Biotech Ltd., New Taipei City, Taiwan) and then quantified with the Nanodrop ASP-3700 (ACTGene, Piscataway, NJ, U.S.A.). Direct sequencing was provided by the service laboratory Macrogen Inc., Amsterdam, the Netherlands.

Sequence analyses

Unique sequence was compared with publicly available GenBank sequences using BLAST algorithm (www.ncbi.nlm.nih.gov), edited (DNASTAR program package, DNASTAR Inc., Madison, WI, U.S.A.) and then was stored to the NCBI GenBank database under accession number KX374559. Additional sequences of the group of herpesviral DNA-directed DNA polymerase gene, largely chelonian and other reptilian herpesviruses, were acquired from the GenBank database (NCBI) to specify the phylogenetic relationships. Alignment was created in BioEdit [15] with the Clustal W algorithm [43]. Bayesian inference (BI) and Maximum likelihood (ML) methods were selected to reconstruct the phylogeny within the related organisms. BI was carried out with MrBayes 3.1.2. using a GTR+Γ+I model for 10⁷ generations [40]. The trees were summarized after removing the burn-in (9 trees). ML analysis was carried out by PHYML version 2.4.4. under the GTR+Γ+I model; bootstrap values were calculated for 1,000 replicates [14]. Resulting trees were visualized in TreeView 1.6.6 (Bio-Soft Net, Glasgow, U.K.) [37] and graphically adjusted in Adobe Illustrator CS5 v.15.0 (Adobe Systems Inc., San Jose, CA, U.S.A.) with macaque monkey's herpesvirus as an outgroup.

RESULTS

Histopathology

Microscopic features in pre-treatment biopsies were fully diagnostic and consistent with multifocal squamous cell papilloma (Fig. 2). Each of the specimens shared identical histopathological characteristics irrespective of the anatomical site where they were excised, and consisted of frond-like masses of hyperkeratotic squamous epithelium, often with a core of dense fibrocollagenous connective tissue. Dense spherical keratin “pearls” were most numerous subjacent to the outermost squamous epithelial surface. Random inflammatory leukocytes, mostly lymphocytes and histiocytes, with rare heterophils, were scattered throughout these foci. Viral-type inclusion bodies were not identified.

The results of biopsy specimens obtained several weeks after the administration of autogenous vaccine, were similar but differed from those specimens selected from the turtle prior to its vaccination, in that in the vaccinated animal, there was leukocytic infiltration adjacent and superficial, extending to deeper focal- to -confluent ulcerations and multifocal necrosis.

Repeated histological examination showed that autogenous vaccine induced substantial areas of necrosis of the papillomatous lesions. Specimens displayed diffuse necrosis especially noted by the loss of cytological architecture, nuclear loss, and in some areas by edema. Fine bands of collagenous fibres were left in the wake of the necrosis. The loss of cytological detail was remarkable and visible in all of the biopsy specimens. The outer edges of the biopsies retained a few wisps of intact epithelial cells that appeared to be regenerating.

Electron microscopy

Virus particles were not detected by negative staining method.

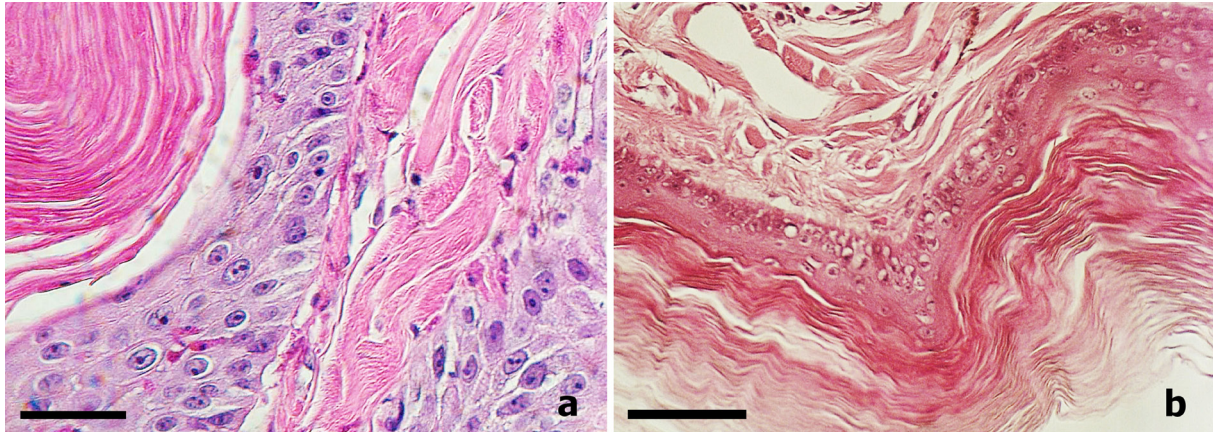


Fig. 2. Microscopic features of neoplastic changes, H & E staining; a) pre-treatment, b) post treatment; scale bar=50 μ m.

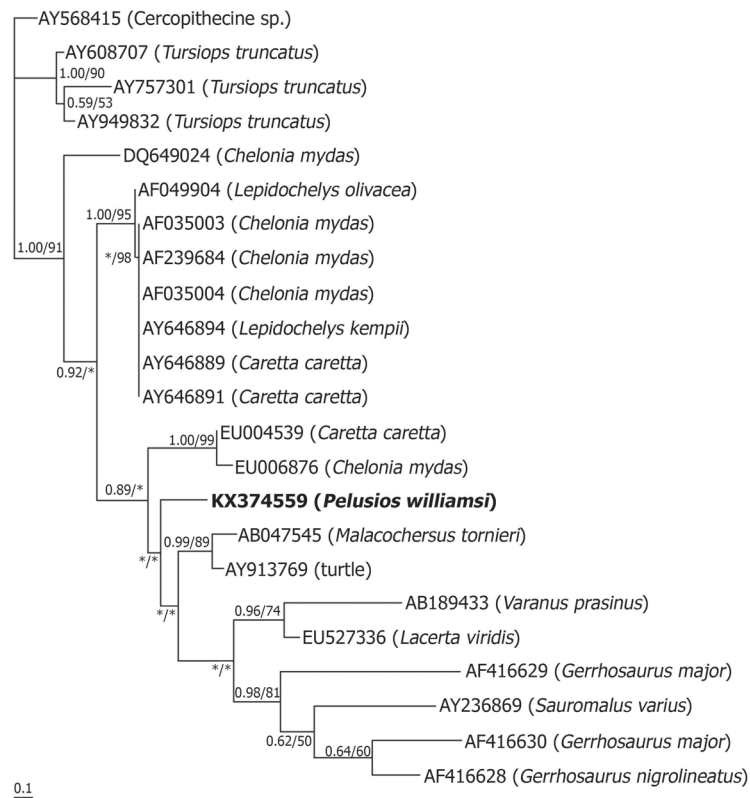


Fig. 3. Maximum likelihood phylogenetic tree of turtle herpesvirus inferred from DNA-directed DNA polymerase sequences. Numbers at the nodes show posterior probabilities under BI/bootstrap values for ML higher than 0.50 or 50%, respectively. Posterior probabilities and bootstrap that supports lower than 0.50 or 50% are marked with asterisk (*). Sequence obtained in this study is printed in bold.

Sequence determination of virus

Amplicon of expected length was obtained, purified, and sequenced. The obtained sequence of the length 181 bp was included into phylogenies. Phylogenetic analyses were based on 185 bp alignment of 23 sequences. Analyses provided similar topologies based on monophyletic cluster forming by the 3 main branches: (1) the single herpesvirus isolated from green sea turtle *Chelonia mydas*; (2) the well-supported clade consisting of sea turtle herpesviruses; and (3) the herpesviruses of reptilians (Fig. 3). The third branch is composed of herpesviruses isolated from lizards, sea turtles, freshwater turtle, tortoise and our sample isolated from this Williams' mud turtle.

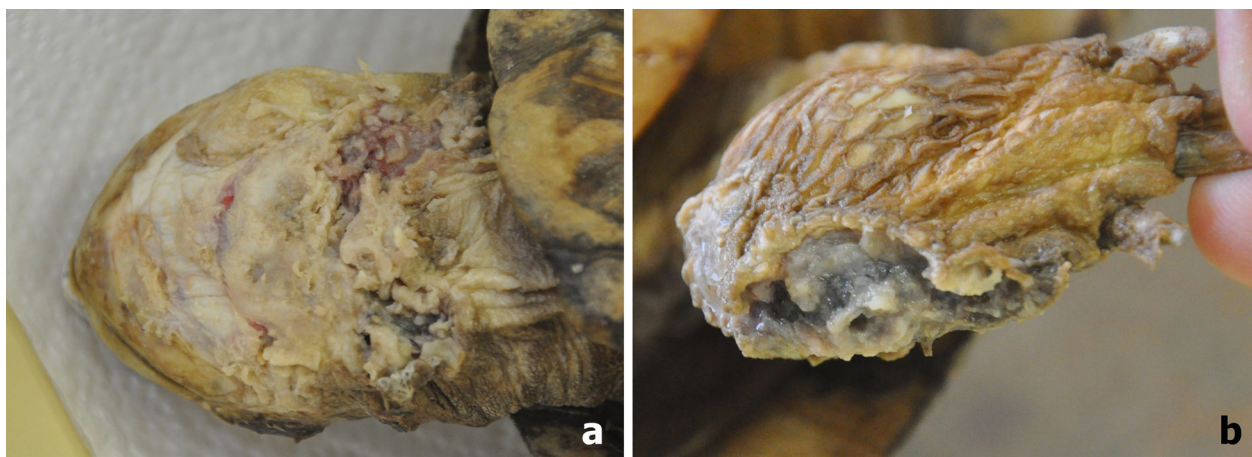


Fig. 4. Skin regeneration following autogenous vaccine application; a) skin on the neck after necrotizing of tumors with early process of regeneration; b) regenerating skin on hind limb.

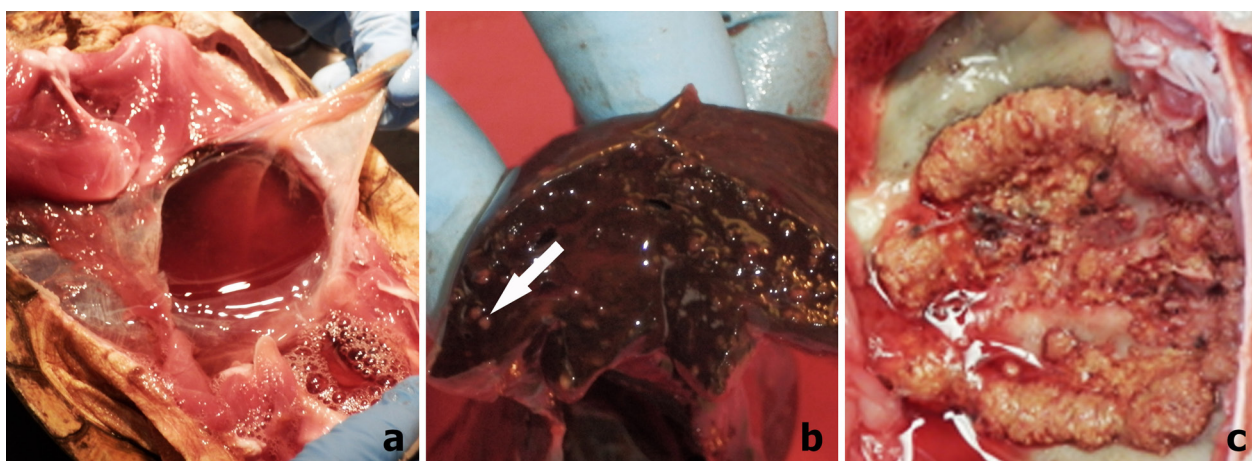


Fig. 5. Gross necropsy; a) exudate in body cavity; b) multiple granulomas in liver, one marked by white arrow; c) granulomas are probable result of inflammatory process at the left lung.

Clinical outcome and gross pathology

Since the beginning the turtle displayed little activity with slow movement. After application of the autogenous vaccine, skin tumors accelerated in their necrosis, and afterward its previously papillomatous-affected cutaneous tissues exhibited regeneration (Fig. 4). However, the turtle was found dead three weeks after second injection of vaccine, despite it had been eating throughout the period of observation. Histopathological diagnosis was thwarted because the cadaver had been frozen. Gross necropsy showed good nutritional condition, exudate in body cavity (Fig. 5A) with one autolytic egg, multiple hepatic and ovarian granulomas (Fig. 5B) appearing as miliary extension of an inflammatory process, likely hematogenous spread of the infection of the left lung (Fig. 5C). No visceral neoplasia was found.

DISCUSSION

It is difficult to expect complete resolution of severely fibropapillomata-affected animals by solely surgical intervention. We tested application of autogenous vaccine because of the generalized dissemination of dermal tumors. The superficial necrotizing effect of these neoplasms was macroscopically evident and accelerated after vaccine application. Necrosis was later confirmed by histopathology findings (Fig. 2B). Unfortunately, the turtle died suddenly before we could finalize our trial and obtain unequivocal results. Nevertheless, histological examination has shown an unambiguous picture of post-vaccine tumor necrosis for which our vaccine application is thought to have been effective and, thus, successful.

Vaccination trials in reptiles are summarized as ambiguous [34]. Experiment with inactivated paramyxovirus suspension was carried out on group of 18 western diamondback rattlesnakes (*Crotalus atrox*) [21]. At 296 days post vaccination, all but one of the snakes were seronegative. Similarly, no significant rise in antibody titres was noted in group of Mediterranean tortoises of

the genus *Testudo* that were vaccinated by inactivated tortoise herpesvirus [30]. On the contrary, all but one *Testudo* tortoises seroconverted after application of a live tortoise herpesvirus [35, 36].

We are unaware of the inducing factors of this instance of neoplasia: however, crowded captive conditions connected with higher level of fecal contamination must be considered. We also cannot exclude general exhaustion due to an ageing or the effects of ageing on the immune system and its surveillance leading to initiation of neoplastic growth [2, 48]. Additionally, the studied turtle was kept in open breeding group with frequent exchanges of animals. Notably, some other turtles from the same group have developed proliferative or ulcerative skin disorders. They belonged to other *Pelusios* species, namely *P. marani*, *P. upembae*, and *P. bechuanicus*. Unfortunately, these specimens were not available to us for examination and treatment, when all of them finally died. Thus, introduction of herpesvirus or other pathogen(s) by some of recently introduced infected turtle(s) without clinical signs of disease must also be considered.

Fibropapillomatosis has a multifactorial etiology, where environmental conditions, genetic and biological traits (e.g. host immune response) serve as important cofactors [17, 25]. Presence of Alphaherpesvirus is usual in sea turtles affected by this disease (up to 95%) [1, 3, 16, 32] and it has been considered as its primary etiological agent. From this point of view, our finding of herpesvirus was not unexpected. However, herpesvirus-associated skin disorders are comparably much less studied in freshwater turtle species [5, 11, 47]. Our finding is the first instance regarding herpesvirus-associated papillomatosis in African pelomedusids. Although we did not find viral particles in tissue samples, presence of herpesvirus DNA was confirmed by PCR based diagnostic analysis. Phylogenetic analysis placed it among reptilian herpesviruses (Fig. 3).

Difficulty of treatment and elimination of herpesvirus infection makes avoidance by lengthy-term quarantine isolation prior to their introduction into breeding facility the essential key point of prevention. Frequently the cryptic presence of herpesviruses in clinically healthy turtles and sudden onset of disease represents one of most significant threats to larger breeding groups [20, 33, 44]. PCR screening is theoretically possible during quarantine [29, 41, 45], but its routine application is practically hardly plausible due to high number of traded animals. From this point of view, successful application of autogenous vaccine could be promising strategy, which deserves further testing.

REFERENCES

1. Aguirre, A. A. and Lutz, P. L. 2004. Marine turtles as sentinels of ecosystem health: Is fibropapillomatosis an indicator? *EcoHealth* **1**: 275–283.
2. Aguirre, A. A., Balazs, G. H., Spraker, T. R. and Gross, T. S. 1995. Adrenal and hematological responses to stress in juvenile green turtles (*Chelonia mydas*) with and without fibropapillomas. *Physiol. Zool.* **68**: 831–854. [[CrossRef](#)]
3. Alfaro-Núñez, A., Frost Bertelsen, M., Bojesen, A. M., Rasmussen, I., Zepeda-Mendoza, L., Tange Olsen, M. and Gilbert, M. T. P. 2014. Global distribution of Chelonid fibropapilloma-associated herpesvirus among clinically healthy sea turtles. *BMC Evol. Biol.* **14**: 206. [[Medline](#)] [[CrossRef](#)]
4. Cooper, J. E., Gschmeissner, S. and Bone, R. D. 1988. Herpes-like virus particles in necrotic stomatitis of tortoises. *Vet. Rec.* **123**: 544. [[Medline](#)] [[CrossRef](#)]
5. Cowan, M. L., Raidal, S. R. and Peters, A. 2015. Herpesvirus in a captive Australian Krefft's river turtle (*Emydura macquarii krefftii*). *Aust. Vet. J.* **93**: 46–49. [[Medline](#)] [[CrossRef](#)]
6. Ernst, C. H. and Barbour, R. W. 1989. *Turtles of the World*. Smithsonian Institution Press, Washington, D.C.
7. Fritz, U. and Havaš, P. 2007. Checklist of chelonians of the world. *Vertebr. Zool.* **57**: 149–368.
8. Frye, F. L. 1976. Spontaneous herpesvirus infection in two turtles. pp. 97–103. *Proc. Am. Ass. Zoo Vet.* St. Louis.
9. Frye, F. L. 1991. *Biomedical and Surgical Aspects of Captive Reptile Husbandry*, 2nd ed. Krieger Publishing, Inc., Malabar.
10. Frye, F. L. 2016. *Self-Assessment Color Review of Reptiles and Amphibians*, 2nd ed. CRC Press, Baton Rouge.
11. Frye, F. L., Oshiro, L. S., Dutra, F. R. and Carney, J. D. 1977. Herpesvirus-like infection in two Pacific pond turtles. *J. Am. Vet. Med. Assoc.* **171**: 882–884. [[Medline](#)]
12. Frye, F. L., Modrý, D. and Siroký, P. 2009. Pathology in practice. Primary osteoma cutis (benign). *J. Am. Vet. Med. Assoc.* **235**: 511–512. [[Medline](#)] [[CrossRef](#)]
13. Greenblatt, R. J., Quackenbush, S. L., Casey, R. N., Rovnak, J., Balazs, G. H., Work, T. M., Casey, J. W. and Sutton, C. A. 2005. Genomic variation of the fibropapilloma-associated marine turtle herpesvirus across seven geographic areas and three host species. *J. Virol.* **79**: 1125–1132. [[Medline](#)] [[CrossRef](#)]
14. Guindon, S. and Gascuel, O. 2003. A simple, fast, and accurate algorithm to estimate large phylogenies by maximum likelihood. *Syst. Biol.* **52**: 696–704. [[Medline](#)] [[CrossRef](#)]
15. Hall, T. A. 1999. BioEdit: a user-friendly biological sequence alignment editor and analysis program for Windows 95/98/NT. *Nucleic Acids Symp. Ser.* **41**: 95–98.
16. Herbst, L. H. 1994. Fibropapillomatosis of marine turtles. *Annu. Rev. Fish Dis.* **4**: 389–425. [[CrossRef](#)]
17. Herbst, L. H., Jacobson, E. R., Moretti, R. H., Brown, T., Sundberg, J. P. and Klein, P. A. 1995. Experimental transmission of green turtle fibropapillomatosis using cell-free tumor extracts. *Dis. Aquat. Organ.* **22**: 1–12. [[CrossRef](#)]
18. Iverson, J. B. 1992. *A revised Checklist with Distribution Maps of the Turtles of the World*. Privately printed, Richmond, IN.
19. Jacobson, E. R. 2007. *Infectious Diseases and Pathology of Reptiles. Colour Atlas and Text*. CRC Press, Taylor & Francis, Boca Raton.
20. Jacobson, E. R., Clubb, S., Gaskin, J. M. and Gardiner, C. 1985. Herpesvirus-like infection in Argentine tortoises. *J. Am. Vet. Med. Assoc.* **187**: 1227–1229. [[Medline](#)]
21. Jacobson, E. R., Gaskin, J. M., Flanagan, J. P. and Odum, R. A. 1991. Antibody responses of western diamondback rattlesnakes (*Crotalus atrox*) to inactivated ophidian paramyxovirus vaccines. *J. Zoo Wildl. Med.* **22**: 184–190.
22. Jacobson, E. R., Gaskin, J. M., Roelke, M., Greiner, E. C. and Allen, J. 1986. Conjunctivitis, tracheitis, and pneumonia associated with herpesvirus infection in green sea turtles. *J. Am. Vet. Med. Assoc.* **189**: 1020–1023. [[Medline](#)]
23. Jacobson, E. R., Gaskin, J. M. and Wahlquist, H. 1982. Herpesvirus-like infection in map turtles. *J. Am. Vet. Med. Assoc.* **181**: 1322–1324. [[Medline](#)]
24. Jacobson, E. R., Mansell, J. L., Sundberg, J. P., Hajjar, L., Reichmann, M. E., Ehrhart, L. M., Walsh, M. and Murru, F. 1989. Cutaneous

- fibropapillomas of green turtles (*Chelonia mydas*). *J. Comp. Pathol.* **101**: 39–52. [[Medline](#)] [[CrossRef](#)]
25. Landsberg, J. H., Balazs, G. H., Steidinger, K. A., Baden, D. G., Work, T. M. and Russell, D. J. 1999. The potential role of natural tumor promoters in marine turtle fibropapillomatosis. *J. Aquat. Anim. Health* **11**: 199–210. [[CrossRef](#)]
 26. Literák, I., Robesova, B., Majlathova, V., Majlath, I., Kulich, P., Fabian, P. and Roubalova, E. 2010. Herpesvirus-associated papillomatosis in a green lizard. *J. Wildl. Dis.* **46**: 257–261. [[Medline](#)] [[CrossRef](#)]
 27. Mader, D. R. and Divers, S. J. 2014. *Current Veterinary Therapy in Reptile Medicine & Surgery*. Elsevier, St. Louis.
 28. Marschang, R. E. 1999. Evidence for a New Herpesvirus Serotype Associated with Stomatitis in Afghan Tortoises (*Testudo horsfieldi*). pp. 77–80. *Proc. Assoc. Rept. Amphib. Vet.* Columbus.
 29. Marschang, R. E., Gleiser, C. B., Papp, T., Pfitzner, A. J. P., Böhm, R. and Roth, B. N. 2006. Comparison of 11 herpesvirus isolates from tortoises using partial sequences from three conserved genes. *Vet. Microbiol.* **117**: 258–266. [[Medline](#)] [[CrossRef](#)]
 30. Marschang, R. E., Milde, K. and Bellavista, M. 2001. Virus isolation and vaccination of Mediterranean tortoises against a chelonid herpesvirus in a chronically infected population in Italy. *Dtsch. Tierarztl. Wochenschr.* **108**: 376–379. [[Medline](#)]
 31. Mauldin, G. N. and Done, L. B. 2006. Oncology. pp. 299–322. *In: Reptile Medicine and Surgery*, 2nd ed. (Mader D. R. ed.), Saunders Elsevier, St. Louis.
 32. Monezi, T. A., Mehnert, D. U., de Moura, E. M. M., Müller, N. M. G., Garrafa, P., Matushima, E. R., Werneck, M. R. and Borella, M. I. 2016. Chelonid herpesvirus 5 in secretions and tumor tissues from green turtles (*Chelonia mydas*) from Southeastern Brazil: A ten-year study. *Vet. Microbiol.* **186**: 150–156. [[Medline](#)] [[CrossRef](#)]
 33. Muro, J., Ramis, A., Pastor, J., Velarde, R., Tarres, J. and Lavin, S. 1998. Chronic rhinitis associated with herpesviral infection in captive spur-thighed tortoises from Spain. *J. Wildl. Dis.* **34**: 487–495. [[Medline](#)] [[CrossRef](#)]
 34. Oraggi, F. C. 2007. Reptile immunology. pp. 131–166. *In: Infectious Diseases and Pathology of Reptiles Colour Atlas and Text* (Jacobson E. R. ed.), CRC Press, Taylor & Francis, Boca Raton.
 35. Oraggi, F. C., Klein, P. A., Mathes, K., Blahak, S., Marschang, R. E., Tucker, S. J. and Jacobson, E. R. 2001. Enzyme-linked immunosorbent assay for detecting herpesvirus exposure in Mediterranean tortoises (spur-thighed tortoise [*Testudo graeca*] and Hermann's tortoise [*Testudo hermanni*]). *J. Clin. Microbiol.* **39**: 3156–3163. [[Medline](#)] [[CrossRef](#)]
 36. Oraggi, F. C., Romero, C. H., Bloom, D. C., Klein, P. A., Gaskin, J. M., Tucker, S. J. and Jacobson, E. R. 2004. Experimental transmission of a herpesvirus in Greek tortoises (*Testudo graeca*). *Vet. Pathol.* **41**: 50–61. [[Medline](#)] [[CrossRef](#)]
 37. Page, R. D. M. 1996. TreeView: an application to display phylogenetic trees on personal computers. *Comput. Appl. Biosci.* **12**: 357–358. [[Medline](#)]
 38. Rebell, G., Rywlin, A. and Haines, H. 1975. A herpesvirus-type agent associated with skin lesions of green sea turtles in aquaculture. *Am. J. Vet. Res.* **36**: 1221–1224. [[Medline](#)]
 39. Richie, B. 2006. Virology. pp. 391–417. *In: Reptile Medicine and Surgery*, 2nd ed. (Mader, D. R. ed.), Saunders Elsevier, St. Louis.
 40. Ronquist, F. and Huelsenbeck, J. P. 2003. MrBayes 3: Bayesian phylogenetic inference under mixed models. *Bioinformatics* **19**: 1572–1574. [[Medline](#)] [[CrossRef](#)]
 41. Soares, J. F., Chalker, V. J., Eries, K., Holtby, S., Waters, M. and McArthur, S. 2004. Prevalence of *Mycoplasma agassizii* and Chelonian herpesvirus in captive tortoises (*Testudo* sp.) in the United Kingdom. *J. Zoo Wildl. Med.* **35**: 25–33. [[Medline](#)] [[CrossRef](#)]
 42. Teifke, J. P., Löhr, C. V., Marschang, R. E., Osterrieder, N. and Posthaus, H. 2000. Detection of chelonid herpesvirus DNA by nonradioactive in situ hybridization in tissues from tortoises suffering from stomatitis-rhinitis complex in Europe and North America. *Vet. Pathol.* **37**: 377–385. [[Medline](#)] [[CrossRef](#)]
 43. Thompson, J. D., Higgins, D. G. and Gibson, T. J. 1994. CLUSTAL W: improving the sensitivity of progressive multiple sequence alignment through sequence weighting, position-specific gap penalties and weight matrix choice. *Nucleic Acids Res.* **22**: 4673–4680. [[Medline](#)] [[CrossRef](#)]
 44. Une, Y., Uemura, K., Nakano, Y., Kamiie, J., Ishibashi, T. and Nomura, Y. 1999. Herpesvirus infection in tortoises (*Malacochersus tornieri* and *Testudo horsfieldii*). *Vet. Pathol.* **36**: 624–627. [[Medline](#)] [[CrossRef](#)]
 45. Une, Y., Murakami, M., Uemura, K., Fujitani, H., Ishibashi, T. and Nomura, Y. 2000. Polymerase chain reaction (PCR) for the detection of herpesvirus in tortoises. *J. Vet. Med. Sci.* **62**: 905–907. [[Medline](#)] [[CrossRef](#)]
 46. VanDevanter, D. R., Warrenner, P., Bennett, L., Schultz, E. R., Coulter, S., Garber, R. L. and Rose, T. M. 1996. Detection and analysis of diverse herpesviral species by consensus primer PCR. *J. Clin. Microbiol.* **34**: 1666–1671. [[Medline](#)]
 47. Yonkers, S. B., Schneider, R., Reavill, D. R., Archer, L. L., Childress, A. L. and Wellehan, J. F. X. Jr. 2015. Coinfection with a novel fibropapilloma-associated herpesvirus and a novel *Spirorchis* sp. in an eastern box turtle (*Terrapene carolina*) in Florida. *J. Vet. Diagn. Invest.* **27**: 408–413. [[Medline](#)] [[CrossRef](#)]
 48. Zimmerman, L. M., Paitz, R. T., Vogel, L. A. and Bowden, R. M. 2010. Variation in the seasonal patterns of innate and adaptive immunity in the red-eared slider (*Trachemys scripta*). *J. Exp. Biol.* **213**: 1477–1483. [[Medline](#)] [[CrossRef](#)]