

# Abdominal Ultrasound for the Diagnosis of Tuberculosis Among Human Immunodeficiency Virus-Positive Inpatients With World Health Organization Danger Signs

Rulan Griesel,<sup>1</sup> Karen Cohen,<sup>1</sup> Marc Mendelson,<sup>2</sup> and Gary Maartens<sup>1</sup>

<sup>1</sup>Division of Clinical Pharmacology and <sup>2</sup>Division of Infectious Diseases and HIV Medicine, Department of Medicine, University of Cape Town, South Africa

**Background.** Studies of the value of abdominal ultrasound for diagnosing human immunodeficiency virus (HIV)-associated tuberculosis have major limitations.

**Methods.** We conducted a prospective study of HIV-positive inpatients with cough and World Health Organization danger signs. The reference standard was positive *Mycobacterium tuberculosis* culture from any site. Participants had at least 2 sputa and 1 blood specimen sent for mycobacterial cultures. Standardized data capture sheets were used for ultrasound reports. A blinded radiologist interpreted chest radiographs, categorized as “likely”, “possible”, and “unlikely” for HIV-associated tuberculosis.

**Results.** We enrolled 377 participants: 249 women, median age 35 years, 201 with tuberculosis, and median CD4 count 75 cells/ $\mu$ L. The following abdominal ultrasound findings independently predicted tuberculosis: lymph node long-axis  $\geq 10$  mm (adjusted odds ratio [aOR], 4.76; 95% confidence interval [CI], 2.41–9.38), splenic hypoechoic lesions (aOR, 3.45; 95% CI, 1.91–6.24), and abdominal/pleural/pericardial effusions (aOR, 1.95; 95% CI, 1.16–3.29). Presence of  $\geq 1$  of these 3 features had a sensitivity of 76.4% (95% CI, 69.8–82.3), a specificity of 68.6% (95% CI, 61.1–75.4), and a c-statistic of 0.784 (95% CI, 0.739–0.830). The sensitivity and specificity of chest radiograph assessed as likely tuberculosis was 55.2% (95% CI, 47.2–62.9) and 83.9% (95% CI, 77.0–89.4), respectively.

**Conclusions.** Three features of tuberculosis on abdominal ultrasound independently predicted tuberculosis with moderate diagnostic performance in seriously ill HIV-positive inpatients. Abdominal ultrasound was more sensitive but less specific than chest radiograph for diagnosing tuberculosis in this patient population.

**Keywords.** abdominal ultrasound; HIV; inpatients; tuberculosis diagnosis; WHO algorithm.

Tuberculosis remains the commonest cause of hospital admission in human immunodeficiency virus (HIV)-positive patients globally in the antiretroviral therapy (ART) era [1]. A systematic review of autopsy studies from resource-limited countries showed that tuberculosis causes 40% of facility-based deaths among HIV-positive patients [2]. Disseminated or extrapulmonary tuberculosis (EPTB) is increasingly common with advancing immune suppression [3, 4], with the abdomen being a common site of involvement [2]. Diagnosing disseminated or EPTB is challenging.

Most hospitalized patients with HIV-associated tuberculosis have severe immune suppression with disseminated tuberculosis. The current World Health Organization (WHO) algorithm

for the diagnosis of tuberculosis in seriously ill HIV-positive patients suggests that abdominal ultrasound “may be performed” if EPTB is suspected, without making a firm recommendation [5]. Features on abdominal ultrasound that may be associated with tuberculosis include the following: lymphadenopathy, splenic hypoechoic lesions, hepato- and/or splenomegaly, ascites (with or without fibrinous stranding), bowel wall thickening and intramural abscesses (with or without fistulae), and pleural or pericardial effusions. Studies that have assessed the predictive value of abdominal ultrasound for diagnosing tuberculosis among HIV-positive inpatients have found lymphadenopathy, ascites, and hypoechoic splenic lesions to be most strongly associated with tuberculosis [6–8]. However, these studies have major limitations, including small sample sizes, retrospective design, and abdominal ultrasound features incorporated in the diagnostic criteria for tuberculosis [9–11]. No studies have been conducted of the diagnostic accuracy of abdominal ultrasound in inpatients with danger signs.

The WHO algorithm for seriously ill patients is widely followed in low- to middle-income countries and is therefore an important group in which to evaluate the diagnostic accuracy of ultrasound. We aimed to establish which of the commonly assessed features of abdominal ultrasound (including detection

Received 31 December 2018; editorial decision 21 February 2019; accepted 1 March 2019.

Correspondence: G. Maartens, MBChB, MMed, Division of Clinical Pharmacology, Health Sciences Faculty, University of Cape Town, Anzio Road, Observatory 7925, South Africa (gary.maartens@uct.ac.za).

Open Forum Infectious Diseases®

© The Author(s) 2019. Published by Oxford University Press on behalf of Infectious Diseases Society of America. This is an Open Access article distributed under the terms of the Creative Commons Attribution-NonCommercial-NoDerivs licence (<http://creativecommons.org/licenses/by-nc-nd/4.0/>), which permits non-commercial reproduction and distribution of the work, in any medium, provided the original work is not altered or transformed in any way, and that the work is properly cited. For commercial re-use, please contact [journals.permissions@oup.com](mailto:journals.permissions@oup.com)  
 DOI: 10.1093/ofid/ofz094

of pleural or pericardial effusions) among seriously ill HIV-positive inpatients with suspected tuberculosis are predictive of tuberculosis. We assessed the diagnostic accuracy of these features individually and in combination. Furthermore, we aimed to compare the diagnostic accuracy of a chest radiograph assessment with that of an abdominal ultrasound for tuberculosis in this population.

## METHODS

### Study Population

We prospectively recruited seriously ill HIV-positive inpatients with suspected tuberculosis at 2 secondary level hospitals in Cape Town, South Africa. The main aim of the study was to develop clinical prediction rules for tuberculosis in this patient population; this study has been published [12]. Determining the diagnostic accuracy of abdominal ultrasound for tuberculosis was a prespecified secondary aim of the study. The inclusion criteria for this analysis were as follows: HIV-positive, age  $\geq 18$  years, enrolled within 24 hours of admission, coughing for any duration, 1 or more WHO danger signs (respiratory rate  $>30$ /minute, fever  $>39^{\circ}\text{C}$ , pulse rate  $>120$ /minute, and unable to walk unaided), and abdominal ultrasound performed during admission work-up. Exclusion criteria were as follows: antituberculosis therapy that was current or completed in the previous month or disengagement with treatment within the past 6 months, exacerbation of cardiac failure or chronic obstructive pulmonary disease, and the inability to produce a spontaneous or induced sputum sample.

### Investigations

Chest radiographs were performed on all participants as part of the diagnostic work-up for tuberculosis. Digital chest radiographs were available at the one hospital and films at the other; however, some chest radiograph films were lost when the hospital closed. An experienced radiologist blinded to the tuberculosis culture result retrospectively assessed all available chest radiographs and classified them as “likely”, “possible”, or “unlikely” for HIV-associated tuberculosis on the basis of the overall interpretation of the chest radiograph; the classification of likely tuberculosis was the strongest predictor of tuberculosis in our study to develop clinical prediction rules for tuberculosis in this cohort [12].

Abdominal ultrasounds were performed by trained ultrasonographers at the enrollment hospital’s radiology department. Ultrasounds at the first enrollment facility were performed using the Xario SSA-660A (Toshiba, Tokyo, Japan), with 2–6 MHz convex probe and 5–11 MHz linear probe, and at the second enrollment facility with a Nemio MX UIDM-590A (Toshiba, Tokyo, Japan), with 3.75 MHz convex probe and 7.5 MHz linear probe. We captured the following ultrasound findings using a standardized case record form: spleen size, splenic hypoechoic lesions, presence of enlarged lymph node(s), long-axis length of

the largest visualized lymph node, and the presence of abdominal, pleural, or pericardial effusions. Our intention was to perform an abdominal ultrasound on all participants, but there was limited capacity at the study site hospitals; therefore, abdominal ultrasounds were not done on all participants.

Induction with ultrasonic nebulizer and hypertonic saline was performed in participants unable to spontaneously produce sputum. We sent 2 sputum samples for smear microscopy with auramine staining and liquid mycobacterial culture (BACTEC MGIT 960; Becton Dickinson Diagnostic Systems, Sparks, MD). The sputum pellet on one of the samples for mycobacterial culture was split after decontamination for Xpert MTB/RIF assay (Cepheid, Sunnyvale, CA). We performed mycobacterial blood culture (BacT/Alert MP; bioMerieux, Durham, NC) on all participants. Extrapulmonary samples were sent for liquid mycobacterial culture when clinically indicated. Urinary lipopolysaccharide (LAM) was analyzed retrospectively on available samples using a LAM assay (Alere Determine TB LAM Ag; Alere Inc., Waltham, MA) [13].

### Statistical Analysis

Our reference standard for the diagnosis of tuberculosis was a positive culture for *Mycobacterium tuberculosis* from any site. We did not do a formal sample size calculation for this substudy. However, we had more than the recommended 10 outcome events (culture-positive tuberculosis) per assessed variable for the multivariable logistic regression analysis [14].

We compared proportions between groups using the  $\chi^2$  test. Because the data were not parametrically distributed, we summarized continuous variables as medians and interquartile ranges, and we compared the distribution between groups using the Wilcoxon rank-sum test. Using univariable and multivariable logistic regression, we explored associations between the following ultrasound features and culture-positive tuberculosis based on prior literature: the presence of lymph nodes, long-axis lymph node length as a continuous variable and as a categorical variable ( $\geq 10$  mm), splenic hypoechoic lesions, spleen enlargement  $\geq 110$  mm, and the presence of any one of abdominal, pleural, or pericardial effusions. A  $P$  value of  $\leq 0.05$  was regarded as significant throughout. Analyses were performed using STATA 12.1 [15]. We calculated the  $c$ -statistic for the final model with 95% confidence intervals (CIs).

We determined the diagnostic accuracy of individual and combined ultrasound features that were independently associated with culture-positive tuberculosis in the multivariable logistic regression model. We also determined the diagnostic accuracy of having a chest radiograph assessment of likely tuberculosis. We calculated 95% CIs for all measures of diagnostic performance (sensitivity, specificity, positive predictive value, negative predictive value, positive likelihood ratio, and negative likelihood ratio).

## Ethics Approval

Approval for the study was obtained from the University of Cape Town Human Research Ethics Committee. Eligible participants signed informed consent before enrollment into the study. Confused participants were enrolled and given the option to continue with participation once orientated; their data were removed from the study if consent was declined.

## RESULTS

Abdominal ultrasound was not performed in 123 of the 500 participants in the cohort and were excluded. Participant characteristics differed between those who did and did not have an abdominal ultrasound: CD4 count was lower (median 76 cells/mm<sup>3</sup> versus 191 cells/mm<sup>3</sup>,  $P < .001$ ), ART use (32% versus 44%,  $P = .015$ ), and body mass index (BMI) (median 20 kg/m<sup>2</sup> versus 21 kg/m<sup>2</sup>,  $P = .031$ ).

The characteristics of the 377 included participants are described in Table 1. All of the assessed ultrasound features were present in a significantly higher proportion among

participants with culture-positive tuberculosis compared with those without culture-positive tuberculosis (Table 1). The yield of culture-positive tuberculosis from all samples collected were as follows: sputum 45% (172 of 377), blood 28% (101 of 363), and other extrapulmonary sites 38% (26 of 69).

On univariable logistic regression, all of the assessed ultrasound features were associated with culture-positive tuberculosis (Table 2). We did a subanalysis of effusions at single sites, all of which were associated with culture-positive tuberculosis: abdomen odds ratio (OR) = 2.89 (1.48–5.66), pleural OR = 2.31 (1.27–4.21), and pericardial effusion OR = 2.74 (1.45–5.17). In the multivariable logistic regression model, long-axis lymph node length  $\geq 10$  mm, splenic hypoechoic lesions, and abdominal/pleural/pericardial effusions were significantly associated with culture-positive tuberculosis (Table 2). Seventy-six percent (146 of 191) of participants with culture-positive tuberculosis had at least 1 or more of these 3 features on abdominal ultrasound. The numbers of participants with individual and combined ultrasound features significantly associated with

**Table 1. Participant Characteristics, Chest Radiograph Assessments, Abdominal Ultrasound Features, and Results of Rapid Tuberculosis Assays Among 377 Participants**

Participant Feature	Participants With Culture-Positive Tuberculosis From Any Site (201)	Participants Without Tuberculosis (Culture-Negative) (176)	P Value for Difference
<b>Participant Characteristic</b>			
Age (years), median (IQR)	35 (30–41)	36 (30–42)	.322
Sex (female), n (%)	137 (68)	112 (64)	.355
BMI (kg/m <sup>2</sup> ), median (IQR)	20 (18–24) <sup>a</sup>	20 (18–25) <sup>b</sup>	.720
CD4 (cells/mm <sup>3</sup> ), median (IQR)	61 (25–136)	108 (39–230)	<.001
Cough duration (days), median (IQR)	14 (11–25) <sup>c</sup>	14 (7–21) <sup>c</sup>	<.001
Using ART, n (%)	59 (29)	61 (35)	.270
Duration on ART (years), median (IQR)	1.0 (0.6–4.0) <sup>c</sup>	2.9 (0.7–5.9)	.013
<b>Chest Radiograph Assessment of Tuberculosis<sup>d</sup></b>			
Unlikely, n (%)	9 (6)	25 (17)	.004
Possible, n (%)	65 (39)	100 (67)	<.001
Likely, n (%)	91 (55)	24 (16)	<.001
<b>Abdominal Ultrasound Feature</b>			
Lymph nodes present, n (%)	105 (52)	23 (13)	<.001
Multiple lymph nodes, n (%)	90 (45)	13 (7)	<.001
Long-axis lymph node length (mm), median (IQR)	21 (13–27) <sup>e</sup>	14 (9–22) <sup>c</sup>	.073
Long-axis lymph node length $\geq 10$ mm, n (%)	85 (45) <sup>e</sup>	14 (8) <sup>c</sup>	<.001
Splenic hypoechoic lesions, n (%)	113 (56)	25 (14)	<.001
Splenic enlargement $\geq 100$ mm, n (%)	47 (23)	20 (11)	.002
Ascites, n (%)	38 (19)	13 (7)	.001
Pleural effusion, n (%)	45 (22)	18 (10)	.002
Pericardial effusion, n (%)	43 (21)	15 (9)	.001
<b>Rapid Tuberculosis Assay</b>			
Xpert MTB/RIF positive/done, n/N (%)	172/191 (90)	8/173 (5)	—
Urinary LAM positive/done, n/N (%)	48/121 (40)	10/108 (9)	—

Abbreviations: ART, antiretroviral therapy; BMI, body mass index; IQR, interquartile range; LAM, lipoarabinomannan.

<sup>a</sup>Six values missing.

<sup>b</sup>Five values missing.

<sup>c</sup>One value missing.

<sup>d</sup>Sixty-three values missing (36 values missing among culture-positive tuberculosis and 27 values missing among culture-negative tuberculosis).

<sup>e</sup>Ten values missing.

**Table 2. Univariable and Multivariable Associations of Abdominal Ultrasound Features With Culture-Positive Tuberculosis Among 366 Participants (11 Values Missing for Long-Axis Lymph Node Length)**

Variable	Univariable Associations		Multivariable Associations	
	OR (95% CI)	Wald's PValue	aOR (95% CI)	Wald's PValue
<b>Long-Axis Lymph Node Length</b>				
Absent lymph nodes	Referent group			
<10 mm	1.99 (0.76–5.22)	.161	0.99 (0.33–2.91)	.986
≥10 mm	9.68 (5.20–17.99)	<.001	4.76 (2.41–9.38)	<.001
<b>Splenic Hypoechoic Lesions Present</b>				
No	Referent group			
Yes	7.17 (4.31–11.95)	<.001	3.45 (1.91–6.24)	<.001
<b>Splenic Enlargement ≥110 mm</b>				
No	Referent group			
Yes	2.32 (1.31–4.12)	.004	1.50 (0.76–2.94)	.241
<b>Abdominal/Pleural/Pericardial Effusions</b>				
No	Referent group			
Yes	3.21 (2.03–5.08)	<.001	1.95 (1.16–3.29)	.012

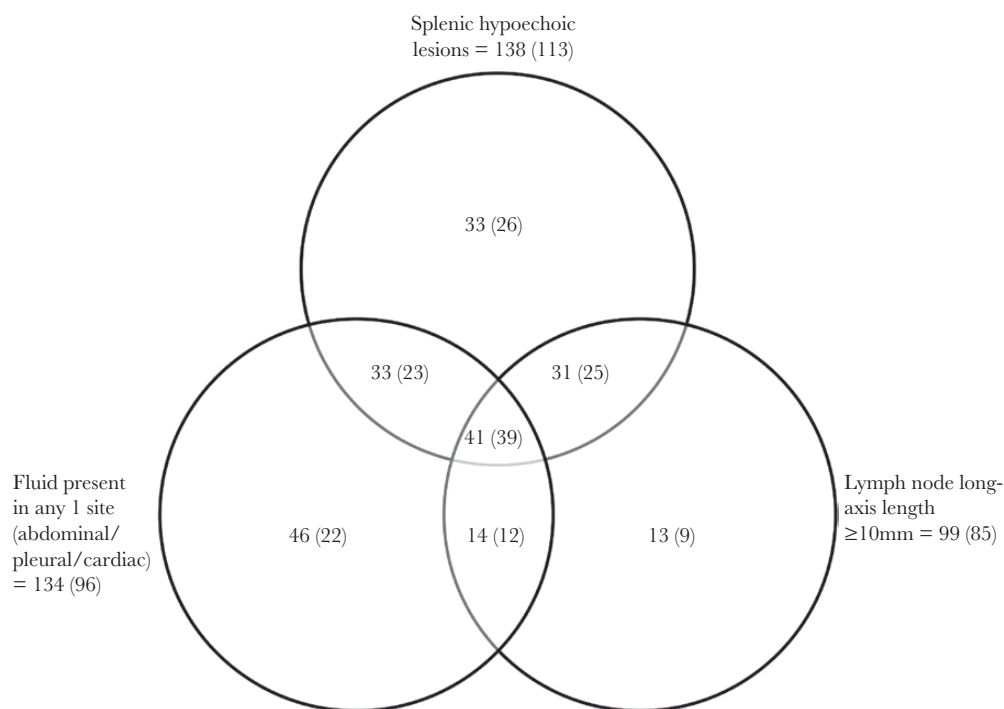
Abbreviations: aOR, adjusted odds ratio; CI, confidence interval; OR, odds ratio.

culture-positive tuberculosis on multivariable logistic regression are shown in [Figure 1](#). The c-statistic for the multivariable model had moderate discrimination (0.784; 95% CI, 0.739–0.830) ([Figure 2](#)).

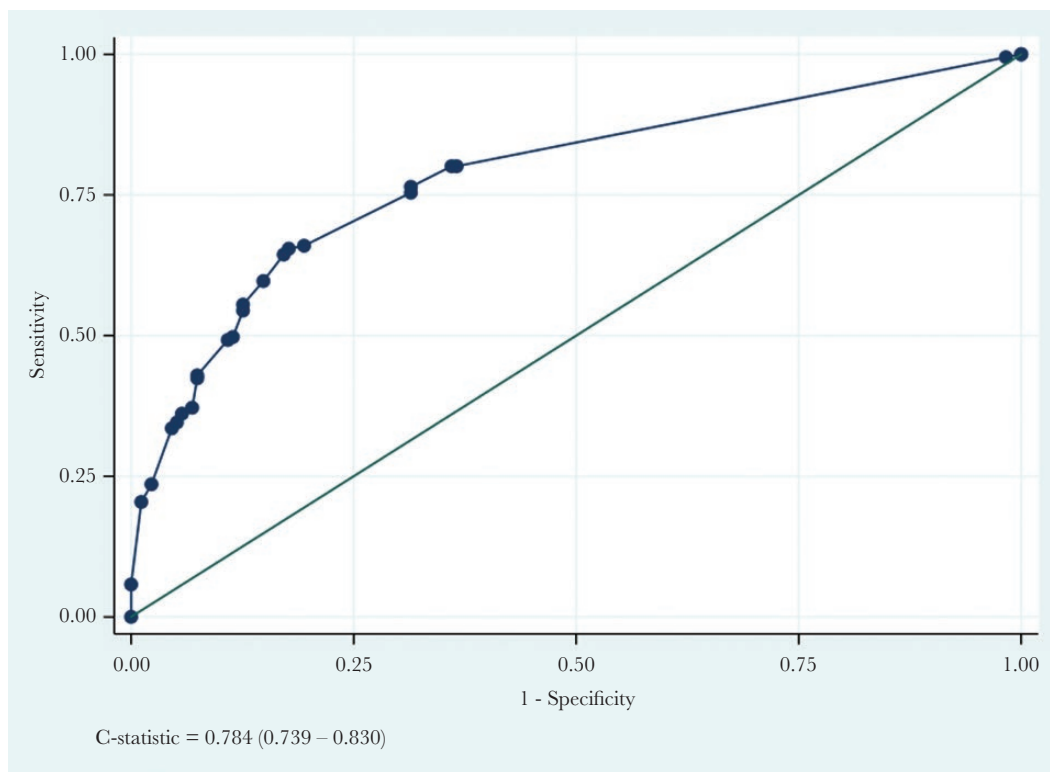
The diagnostic accuracy assessment of the 3 ultrasound features independently associated with culture-positive tuberculosis (long-axis lymph node ≥10 mm, splenic hypoechoic lesions, and abdominal/pleural/pericardial effusions) individually showed low sensitivity with high specificity ([Table 3](#);

lymph node long-axis ≥10 mm was the most specific feature (92%; 95% CI, 86.9–95.6). Combinations of these 3 ultrasound features improved specificity but reduced sensitivity ([Table 3](#)).

Three hundred fourteen participants had an ultrasound as well as chest radiograph assessment performed: 165 of 314 (53%) had culture-positive tuberculosis. The diagnostic accuracy of a chest radiograph assessment of likely tuberculosis is shown in [Table 3](#). Chest radiograph assessment of likely tuberculosis was less sensitive but more specific than the presence of 1 or more of the 3



**Figure 1.** Venn diagram depicting numbers of participants with ultrasound features significantly associated with culture-positive tuberculosis on multivariable logistic regression. Values in parenthesis represent number of participants with culture-positive tuberculosis for each category.



**Figure 2.** C-statistic for the model including multivariable adjusted ultrasound features (long-axis lymph node length  $\geq 10$  mm, splenic hypoechoic lesions, splenic enlargement  $\geq 110$  mm, and fluid present in either abdominal/pleural/cardiac sites) for the diagnosis of culture-positive tuberculosis among 366 participants.

predictive ultrasound features. **Figure 3** shows the diagnostic yield of chest radiograph and abdominal ultrasound features; most participants had radiographic features of both pulmonary and extrapulmonary tuberculosis indicating disseminated disease.

## DISCUSSION

Our prospective study is the first to assess abdominal ultrasound features for the diagnosis of tuberculosis in HIV-positive inpatients with WHO-defined danger signs and is the largest study

of abdominal ultrasound assessments among HIV-positive patients with suspected tuberculosis. On multivariable analysis, we found that lymph node long-axis length  $\geq 10$  mm, splenic hypoechoic lesions, or abdominal/pleural/pericardial effusions were independent predictors of tuberculosis on abdominal ultrasound. Presence of any 1 or more of these ultrasound features had a higher sensitivity but lower specificity for the diagnosis of tuberculosis than a chest radiograph assessment of likely tuberculosis. The combination of all 3 features was highly

**Table 3. Diagnostic Accuracy of Individual and Combined Variables Assessed on Abdominal Ultrasound and Chest Radiograph Among 377 Participants, 201 of Whom Had Culture-Positive Tuberculosis**

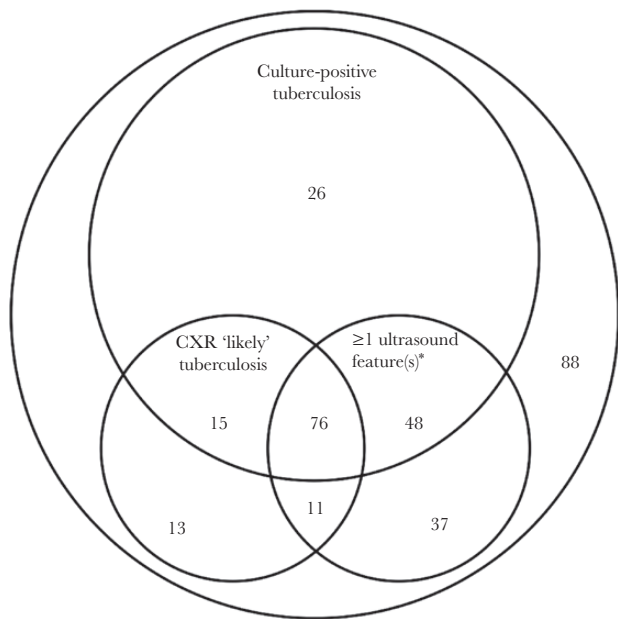
Imaging Feature	% Sensitivity (95% CI)	% Specificity (95% CI)	% PPV (95% CI)	% NPV (95% CI)	+LR (95% CI)	-LR (95% CI)
<b>Abdominal Ultrasound Feature</b>						
Long-axis lymph node $\geq 10$ mm (99) <sup>a</sup>	44.5 (37.3–51.9)	92 (86.9–95.6)	85.9 (77.4–92)	60.3 (54.2–66.2)	5.56 (3.28–9.42)	0.60 (0.53–0.69)
Splenic hypoechoic lesions present (138)	56.2 (49.1–63.2)	85.8 (79.7–90.6)	81.9 (74.4–87.9)	63.2 (56.7–69.3)	3.96 (2.7–5.81)	0.51 (0.43–0.60)
Fluid present in either abdominal/pleural/cardiac sites (134)	47.8 (40.7–54.9)	78.4 (71.6–84.2)	71.6 (63.2–79.1)	56.8 (50.3–63.1)	2.21 (1.61–3.04)	0.67 (0.57–0.78)
Any 1 or more features present <sup>b</sup> (201) <sup>a</sup>	76.4 (69.8–82.3)	68.6 (61.1–75.4)	72.6 (65.9–78.7)	72.7 (65.3–79.4)	2.43 (1.93–3.07)	0.34 (0.26–0.45)
Any 2 or more features present <sup>b</sup> (114) <sup>a</sup>	49.2 (41.9–56.5)	88.6 (82.9–92.9)	82.5 (74.2–88.9)	61.5 (55.2–67.5)	4.31 (2.78–6.67)	0.57 (0.49–0.67)
3 features present <sup>b</sup> (41) <sup>a</sup>	20.4 (14.9–26.8)	98.9 (95.9–99.9)	95.1 (83.5–99.4)	53.2 (47.6–58.8)	17.9 (4.38–72.9)	0.81 (0.75–0.87)
Chest radiograph “likely” tuberculosis (115) <sup>c</sup>	55.2 (47.2–62.9)	83.9 (77–89.4)	79.1 (70.6–86.1)	62.8 (55.7–69.5)	3.42 (2.31–5.06)	0.54 (0.45–0.64)

Abbreviations: -LR, negative likelihood ratio; +LR, positive likelihood ratio; NPV, negative predictive value; PPV, positive predictive value.

<sup>a</sup>Eleven missing values.

<sup>b</sup>Long-axis lymph node  $\geq 10$  mm or splenic hypoechoic lesions or fluid present in either abdominal/pleural/cardiac sites.

<sup>c</sup>Sixty-three missing chest radiograph assessments.



\*long-axis lymph node length  $\geq 10$  mm of splenic hypoechoic lesions or fluid present in either abdominal/pleural/cardiac sites

**Figure 3.** Venn diagram of the yield of abdominal ultrasound features (long-axis lymph node length  $\geq 10$  mm, splenic hypoechoic lesions, splenic enlargement  $\geq 110$  mm, and fluid present in either abdominal/pleural/cardiac sites) and chest radiograph (CXR) assessment of "likely" tuberculosis using the reference standard of culture-positive tuberculosis in the 314 participants who had an abdominal ultrasound performed and chest radiograph assessment done.

specific for the diagnosis of tuberculosis. A long-axis lymph node length  $\geq 10$  mm had the highest specificity among the assessed ultrasound features. Our findings suggest that abdominal ultrasound should be incorporated into diagnostic algorithms for HIV-positive inpatients with suspected tuberculosis.

We were only able to find 3 published studies that prospectively assessed abdominal ultrasound features for their association with tuberculosis among symptomatic HIV-positive patients. A South African study prospectively assessed abdominal ultrasound predictors of tuberculosis among inpatients (91% HIV-positive) with suspected disseminated or EPTB [6]. Their findings were similar to ours with abdominal lymphadenopathy  $>10$  mm in minimum diameter, pericardial effusions, ascites, and splenic lesions significantly associated with active tuberculosis. However, their study had limitations: they only performed univariable logistic regression to assess the predictive value of ultrasound features, did not do tests of diagnostic accuracy, did not do a standardized microbiologic work-up for tuberculosis and no mycobacterial blood cultures were done, did not assess the value of pleural effusions, and used either smear or culture as the reference standard. A Cambodian study assessed the performance of abdominal ultrasound (without assessment of pleural or pericardial effusions) for the diagnosis of tuberculosis in HIV-positive outpatients in an active case-finding study. Abnormal

abdominal ultrasound (defined as any 1 of the following:  $\geq 1$  lymph node(s)  $\geq 12$  mm, ascites, hepatomegaly, splenomegaly, hepatic or splenic hypoechoic lesions with or without organ enlargement) was seen more often in those with than those without tuberculosis. On multivariable logistic regression (which included symptoms, CD4 counts, chest radiograph, and 1 ultrasound feature), they found that multiple enlarged ( $\geq 12$  mm) abdominal lymph nodes were significant predictors of tuberculosis with a positive likelihood ratio of 11.4, but the 95% CIs were wide (4.3–30.3) due to the small numbers of patients with tuberculosis [8]. An Indian study prospectively assessed point-of-care ultrasound for EPTB in 81 HIV-positive patients using a composite reference standard of clinical and microbiologically confirmed tuberculosis [16]. Only focal splenic lesions and abdominal lymphadenopathy were significantly associated with tuberculosis. None of these 3 prospective studies determined which abnormal ultrasound feature independently predicted HIV-associated tuberculosis on multivariable analysis.

Retrospective studies of the diagnostic accuracy assessment of individual abdominal ultrasound features have been small, mostly case-control in design, and several included abdominal ultrasound in the reference standard for the diagnosis of tuberculosis. A South African study found abdominal ultrasound features of adenopathy, splenic abscesses, and ascites to be highly specific for disseminated tuberculosis with abdominal involvement among HIV-positive in- and outpatients [7]. A case-control study from Spain that assessed abdominal ultrasound findings in advanced HIV found that ascites, intra-abdominal lymph nodes ( $>15$  mm), and splenic hypoechoic lesions all had high specificities but low sensitivities for the diagnosis of disseminated tuberculosis [17].

A chest radiograph assessed as likely tuberculosis was less sensitive but more specific for the diagnosis of tuberculosis than having at least 1 or more of the most significantly associated abdominal ultrasound features (long-axis lymph node  $\geq 10$  mm or splenic hypoechoic lesions or abdominal/pleural/pericardial effusions). In a case-control study by Sculier et al [8], having an "abnormal chest radiograph" had similar sensitivity and specificity to our findings for the diagnosis of disseminated tuberculosis. In our study, the sensitivity and specificity of combining chest radiograph assessment of likely tuberculosis with having at least 1 or more of the significantly associated abdominal ultrasound features for the diagnosis of culture-positive tuberculosis (long-axis lymph node  $\geq 10$  mm or splenic hypoechoic lesions abdominal/pleural/pericardial effusions) were 48.1% (95% CI, 40.1–56.2) and 92.6% (95% CI, 87.1–96.2), respectively, making the combination of these variables a potentially valuable rule-in test for diagnosing tuberculosis among seriously ill HIV-positive inpatients.

Our study has some limitations. First, ultrasounds were not performed by a single observer but by duty radiographers.

However, this does reflect real-world circumstances. Second, ultrasound findings were not histologically or microbiologically confirmed as EPTB, because these invasive procedures are not routinely indicated. Third, our findings may not be generalizable to patients without WHO danger signs and cough or in outpatients. Due to limited capacity, not all participants had an abdominal ultrasound done and were excluded from the analysis; these participants had significantly lower CD4 counts and BMIs and were less likely to be on ART. Therefore, there was selection bias, which further limits the generalizability of our findings. However, other studies of the diagnostic accuracy of abdominal ultrasound for tuberculosis found broadly similar results. Finally, only 1 radiologist assessed the chest radiographs, making these findings difficult to reproduce. Strengths of our study included the following: the prospective design, a large enough sample size to assess multiple abdominal ultrasound features as predictive variables in a multivariable model, a robust reference standard of culture-positive tuberculosis, and staff performing chest radiograph and ultrasound assessments were blinded to the diagnoses of participants.

## CONCLUSIONS

Ultrasound has become an easily accessible diagnostic tool, particularly with the advent of point-of-care ultrasound equipment. Training of medical staff can occur through short courses and seminars, thereby increasing the utility of abdominal ultrasound for the diagnosis of disseminated and EPTB. Our findings highlight the usefulness and limitations of abdominal ultrasound as a diagnostic procedure among seriously ill HIV-positive inpatients in resource-limited countries. The presence of at least 1 of the abdominal ultrasound features we found to be independently associated with tuberculosis had high specificity, making it a valuable rule-in test. Chest radiograph remains a valuable diagnostic tool, even among patients with disseminated or EPTB. Future research should focus on defining the use of ultrasound as point-of-care diagnostic test in this population and its incremental value with other rapid diagnostic tests such as Xpert MTB/RIF and urine LAM.

## Acknowledgments

Chest radiographic interpretation was done by Hillel Goodman, Division of Radiology, Department of Radiation Medicine, University of Cape Town.

**Financial support.** This work was funded by the National Institutes of Health (Grant Number R01 AI 96735-01 IRIDA).

**Potential conflicts of interest.** The authors have no conflicts of interest to declare.

## References

1. Ford N, Shubber Z, Meintjes G, et al. Causes of hospital admission among people living with HIV worldwide: a systematic review and meta-analysis. *Lancet HIV* **2015**; 2:e438–44.
2. Gupta RK, Lucas SB, Fielding KL, Lawn SD. Prevalence of tuberculosis in post-mortem studies of HIV-infected adults and children in resource-limited settings: a systematic review and meta-analysis. *AIDS* **2015**; 29:1987–2002.
3. Bates M, Mudenda V, Shibemba A, et al. Burden of tuberculosis at post-mortem in inpatients at a tertiary referral centre in sub-Saharan Africa: a prospective descriptive autopsy study. *Lancet Infect Dis* **2015**; 15:544–51.
4. Naing C, Mak JW, Maung M, et al. Meta-analysis: the association between HIV infection and extrapulmonary tuberculosis. *Lung* **2013**; 191:27–34.
5. World Health Organization. Consolidated Guidelines on the Use of Antiretroviral Drugs for Treating and Preventing HIV Infection: Recommendations for a Public Health Approach. Geneva: World Health Organization; **2016**.
6. Patel MN, Beningfield S, Burch V. Abdominal and pericardial ultrasound in suspected extrapulmonary or disseminated tuberculosis. *S Afr Med J* **2011**; 101:39–42.
7. O'Keefe EA, Wood R, Van Zyl A, Cariem AK. Human immunodeficiency virus-related abdominal pain in South Africa. Aetiology, diagnosis and survival. *Scand J Gastroenterol* **1998**; 33:212–7.
8. Sculier D, Vannarith C, Pe R, et al. Performance of abdominal ultrasound for diagnosis of tuberculosis in HIV-infected persons living in Cambodia. *J Acquir Immune Defic Syndr* **2010**; 55:500–2.
9. Spalgais S, Agarwal U, Sarin R, et al. Role of routine abdominal ultrasonography in intensified tuberculosis case finding algorithms at HIV clinics in high TB burden settings. *BMC Infect Dis* **2017**; 17:351.
10. Heller T, Goblirsch S, Wallrauch C, et al. Abdominal tuberculosis: sonographic diagnosis and treatment response in HIV-positive adults in rural South Africa. *Int J Infect Dis* **2010**; 14(Suppl 3):e108–12.
11. Giordani MT, Brunetti E, Binazzi R, et al. Extrapulmonary mycobacterial infections in a cohort of HIV-positive patients: ultrasound experience from Vicenza, Italy. *Infection* **2013**; 41:409–14.
12. Griesel R, Stewart A, van der Plas H, et al. Optimizing tuberculosis diagnosis in human immunodeficiency virus-infected inpatients meeting the criteria of seriously ill in the world health organization algorithm. *Clin Infect Dis* **2018**; 66:1419–26.
13. Boyles TH, Griesel R, Stewart A, et al. Incremental yield and cost of urine determine TB-LAM and sputum induction in seriously ill adults with HIV. *Int J Infect Dis* **2018**; 75:67–73.
14. Peduzzi P, Concato J, Kemper E, et al. A simulation study of the number of events per variable in logistic regression analysis. *J Clin Epidemiol* **1996**; 49:1373–9.
15. StataCorp. *Stata Statistical Software: Release 12*. College Station, TX: StataCorp LP; **2011**.
16. Weber SF, Saravu K, Heller T, et al. Point-of-care ultrasound for extrapulmonary tuberculosis in India: a prospective cohort study in HIV-positive and HIV-negative presumptive tuberculosis patients. *Am J Trop Med Hyg* **2018**; 98:266–73.
17. Monill-Serra JM, Martinez-Noguera A, Montserrat E, et al. Abdominal ultrasound findings of disseminated tuberculosis in AIDS. *J Clin Ultrasound* **1997**; 25:1–6.