



## Case report

## Capsule endoscopy with retention of 4 years: A case report

Hongchao Chen, Zhe Zhang, Muhan Zhang, Dandan Wang, Mengmeng Jia, Baisui Feng\*

Gastroenterology and Hepatology, The Second Affiliated Hospital of Zhengzhou University, NO.2 Jingba Road, Zhengzhou 450003, Henan, China

## ARTICLE INFO

## Keywords:

Capsule endoscopy  
Crohn's disease  
Capsule retention

## ABSTRACT

**Introduction and importance:** Capsule endoscopy has been widely used in the diagnosis of small bowel diseases. Most CE can be smoothly excreted through the digestive tract. However, very few retention of CE may happen.

**Case presentation:** A 64-year-old man had been suffering from intermittent abdominal pain for 10 years. Capsule endoscopy was performed in local hospital 4 years ago. He was initially diagnosed with Crohn's disease and started on treatment. CTE and X-ray film of abdomen showed a suspected capsule endoscopy on the right side of pelvic cavity. Surgery was performed to remove the capsule. After the surgical treatment, no gastrointestinal symptoms relapsed for 9 months.

**Clinical discussion:** It isn't uncommon for capsule endoscopy to be detained in Crohn's disease, because Strictures are the commonest complication of Crohn's disease. In order to prevent intestinal retention of capsule endoscopy, risk assessment should be carried out before capsule endoscopy. If detained CE isn't removed successfully by drug therapy and endoscopic therapy, surgery treatment has to be considered.

**Conclusion:** In the present case, capsule endoscopy was found in the small intestine after 4 years, and the reason is worth pondering. We strongly recommend performing routine CTE, MRE and patency capsule examination before capsule endoscopy for patients suspected of stenosis. Routine abdominal X-ray film after examination is also useful for timely detection of capsule retention.

## 1. Introduction

Capsule endoscopy (CE) has been widely used in the diagnosis of small bowel diseases. Especially in patients with obscure gastrointestinal bleeding (OGIB) [1,2] and inflammatory bowel disease, Doctors are more likely to use it. Most CE can be smoothly excreted through the digestive tract. However, very few retention of CE may happen.

We report a case of an elderly man suspected of Crohn's disease. After 4 years of performance, the CE was found to be trapped in the small intestine without any symptoms of obstruction or perforation. Finally, the capsule endoscopy was surgically removed. Pathological examination confirmed capsule retention caused by Crohn's disease intestinal stenosis.

## 2. Method

This work has been reported in line with the SCARE 2020 criteria [3].

## 3. Case presentation

A 64-year-old male smoker had been suffering from intermittent abdominal pain for 10 years, mainly around the umbilicus and upper left abdomen. His manifestation was not accompanied by fever, vomiting, abdominal distension or diarrhea. He took omeprazole capsules intermittently. Five years ago, he was diagnosed as "incomplete ileus" and relieved after conservative treatment. Capsule endoscopy revealed small intestinal erosion in local hospital 4 years ago. Colonoscopy displayed terminal ileum lesions and inflammatory changes in the left colon. Pathological examinations of terminal ileum and colon showed chronic inflammation of mucosa. He had been taking mesalazine orally to relieve abdominal pain for a long time.

During the examination of computed tomography enterography (CTE) in our hospital recently, slight thickening and enhancement of ileocecal region and part of ileum wall were exhibited, and dense shadows in small intestine of pelvic cavity. X-ray film of abdomen showed a suspected capsule endoscopy on the right side of pelvic cavity. Since the patient had a history of capsule endoscopy, it was considered that the capsule endoscopy may be detained in the small intestine. As the

\* Corresponding author.

E-mail address: [fengbs@zzu.edu.cn](mailto:fengbs@zzu.edu.cn) (B. Feng).<https://doi.org/10.1016/j.ijscr.2022.107197>

Received 7 April 2022; Received in revised form 8 May 2022; Accepted 10 May 2022

Available online 13 May 2022

2210-2612/© 2022 Published by Elsevier Ltd on behalf of IJS Publishing Group Ltd. This is an open access article under the CC BY-NC-ND license (<http://creativecommons.org/licenses/by-nc-nd/4.0/>).

retention time of capsule endoscopy was more than 4 years, and the patient had abdominal pain, the patient agreed to undergo surgical treatment. The surgery was conducted by a senior surgeon with twenty years surgical specialty experience. Partial small bowel resection was performed after communication with the patient to prevent battery leakage, intestinal erosion and perforation. During the operation, a stenosis was found in ileum 80 cm from ileocecal valve. The proximal end of the stenosis was obviously dilated, and a 3 cm hard object could be palpable in the lumen. After resection of the diseased bowel, a complete capsule endoscopy was observed. Postoperative pathological examination of the diseased intestine suggested severe chronic inflammation of the mucosa with ulceration. The mucosal defective in the ulceration area was replaced by inflammatory exudate and granulation tissue. The ulceration reached deep muscle layer, and the formation of lymphoid follicles was observed in submucosal and muscle layer. Crohn's disease was diagnosed. After surgery, the patient's abdominal pain disappeared and he was discharged several days after surgery. She was suggested oral mesalamine and glutamine. There was no abdominal pain during the 10-month follow-up by telephone consultation. He was not taking mesalamine postoperatively (Fig. 1).

#### 4. Discussion

Capsule endoscopy is often used in the diagnosis of unexplained intestinal bleeding or inflammatory bowel disease. In most cases, capsule endoscopy is excreted in the stool within 10 to 48 h. The retention rate of capsule endoscopy in normal people is about 1.5%, while the probability of retention increases in Crohn's disease, NSAIDs-related enteritis, intestinal tuberculosis, radiation enteritis, ischemic bowel disease, and postoperative stenosis. In particular, the retention rate of Crohn's disease is 7.4 to 13% [4,5], significantly higher than other diseases.

In the Rezapour's systematical review of 25 studies involving 5876 patients, retention rates of capsule endoscopy is 2%. 54% of the retention is due to stenosis, and 57% needs surgery [6].

According to the report of Catia, a patient with retention of capsule

endoscopy in the small intestine was asymptomatic for 7 years, and the capsule endoscopy was finally removed surgically due to intestinal diverticulitis and intestinal obstruction [7]. This may be the longest case of capsule endoscopy retention reported so far. The capsule endoscopy can be discharged spontaneously after retention only in very few patients. Lee et al. reported a case of small intestinal Crohn's disease, which underwent endoscopic self-discharge after capsule retention for one year and hydrocortisone treatment for 14 days [8]. In this case, capsule endoscopy was retained in the body for more than 4 years due to Crohn's disease, and no obvious symptoms of intestinal obstruction occurred, which was indeed rare. Strictures are the commonest complication of Crohn's disease [9]. Strictures comprise both inflammatory and non-inflammatory components including smooth muscle hyperplasia and fibrosis. [10,11] In order to prevent intestinal retention of capsule endoscopy, risk assessment should be carried out before capsule endoscopy. Digestive tract radiography, CTE/MRE or patency capsule [12,13] is necessary to identify intestinal stenosis before capsule endoscopy. After capsule endoscopy, routine abdominal X-ray film examination should be performed to identify whether capsule endoscopy has been discharged. Capsule retention can be mostly asymptomatic and need to be followed-up in a short time. Once the abdominal pain worsened, vomiting and other obstruction symptoms happened, steroid or laxative treatment can be performed firstly to help the discharge of capsule endoscopy. Secondly, the capsule endoscopy can be removed with enteroscopy [14]. If all the above methods fail, or perforation is suspected, the capsule endoscope should be removed surgically [15] (Fig. 2).

#### 5. Conclusion

In this study, we highlighted how the retention of capsule endoscopy is long due to Crohn's disease and easily missed diagnosis. In suspected intestinal stricture cases, patients should receive Digestive tract radiography, CTE/MRE or patency capsule before operating capsule

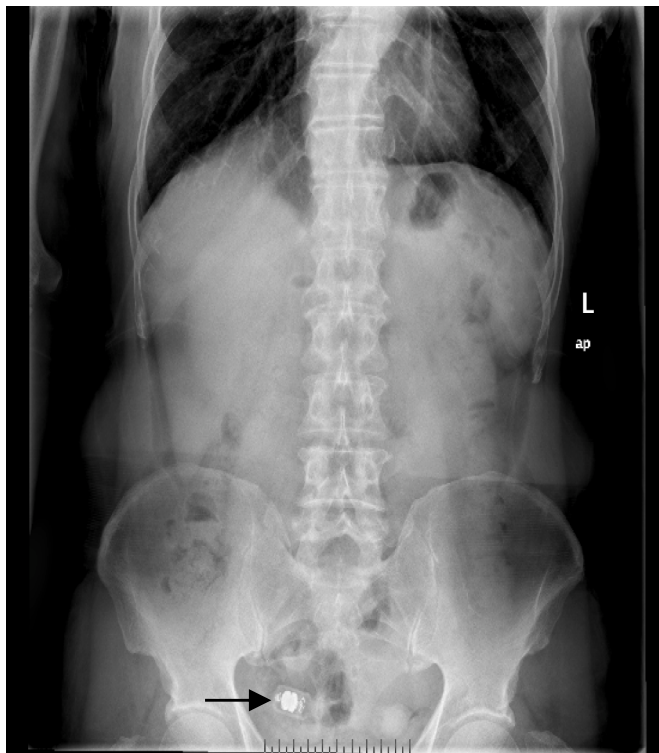


Fig. 1. X-ray film of abdomen showed a suspected capsule endoscopy on the right side of pelvic cavity (arrow).

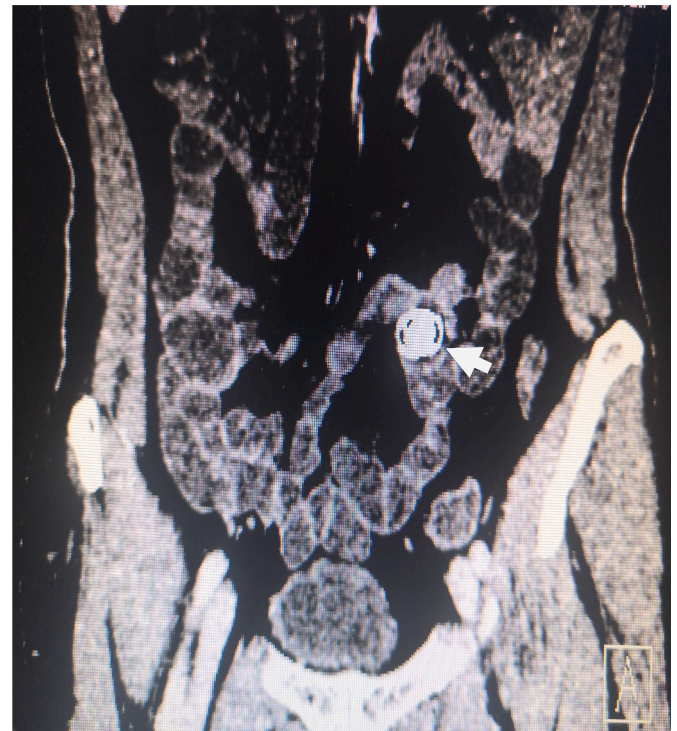

Fig. 2. Examination of computed tomography enterography (CTE) showed slight thickening and enhancement of ileocecal region and part of ileum wall , dense shadows in small intestine of pelvic cavity (arrow).



endoscopy. It was important to follow-up and routine abdominal X-ray film examination after capsule endoscopy (Fig. 3).

### Ethical approval

This case report has been exempt from ethical approval.

### Sources of funding

This article was supported by grant Henan Provincial Science and Technology Department, the People's Republic of China (grant number 222102310460).

### Author contribution

Conceptualization: Hongchao Chen.  
Supervision: Baisui Feng.  
Writing - original draft: Hongchao Chen.  
Writing - review & editing: Hongchao Chen, Zhe Zhang, Muhan

Zhang, Dandan Wang, Mengmeng Jia.

### Guarantor

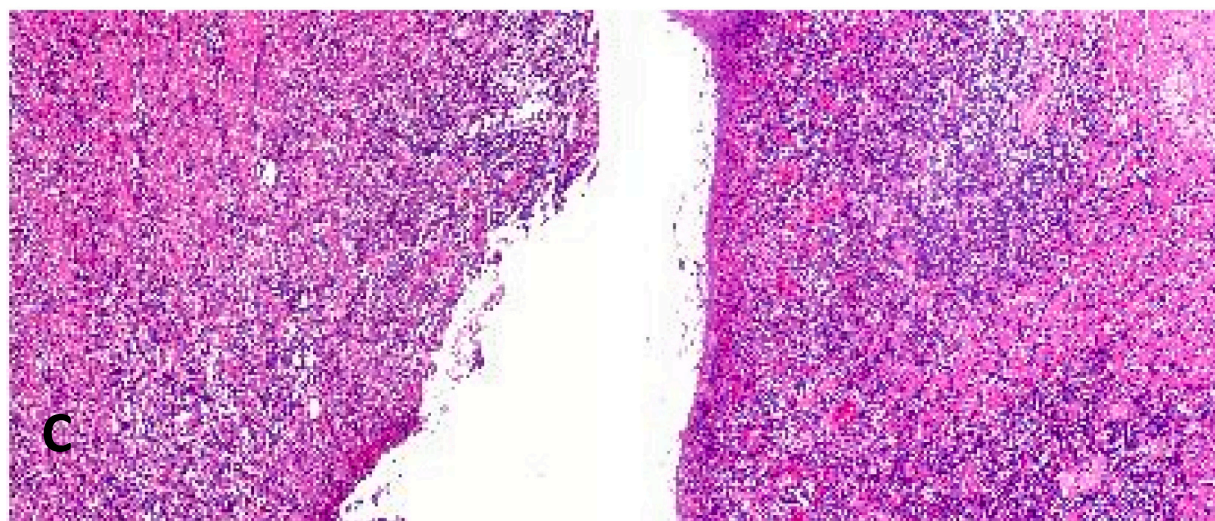
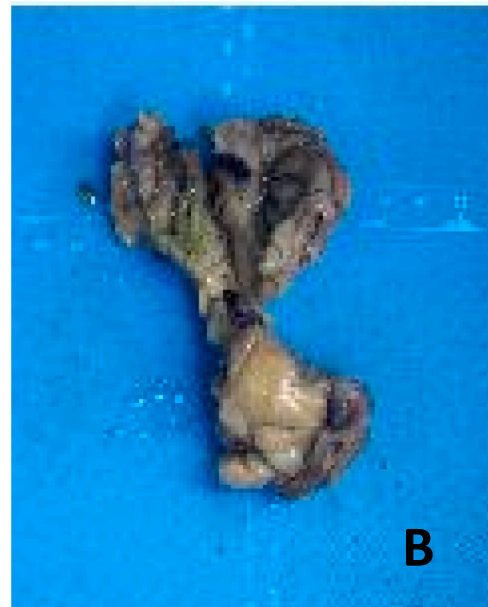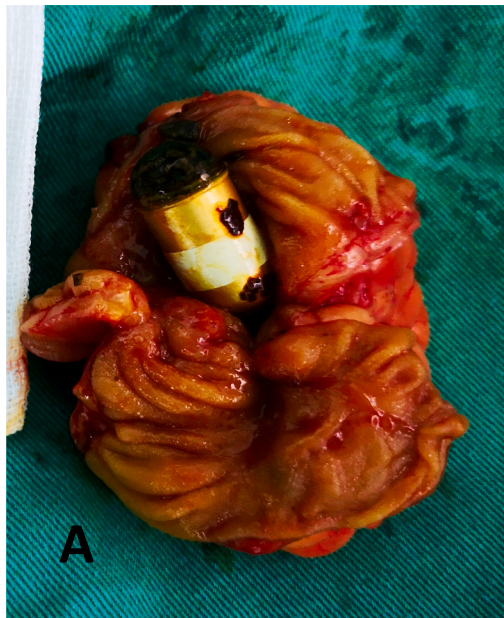Baisui Feng, M.D.

### Registration of research studies

N/a.

### Consent

Written informed consent was obtained from the patient for publication of this case report and accompanying images. A copy of the written consent is available for review by the Editor-in-Chief of this journal on request.



**Fig. 3.** Lesions and pathology of the surgical specimen. (A) Lesions in the intestine and capsule endoscopy. (B) The gross specimen for pathological examination. (C) The picture of pathological examination.

**Provenance and peer review**

Not commissioned, externally peer-reviewed.

**Declaration of competing interest**

The authors declare that they have no conflicts of interest.

**Acknowledgments**

None.

**References**

- [1] J.J.Y. Sung, R.S.Y. Tang, J.Y.L. Ching, T.H. Rainer, J.Y.W. Lau, Use of capsule endoscopy in the emergency department as a triage of patients with GI bleeding, *Gastrointest. Endosc.* 84 (2016) 907–913.
- [2] N.B. Marya, S. Jawaid, A. Foley, et al., A randomized controlled trial comparing efficacy of early video capsule endoscopy with standard of care in the approach to nonhematemesis GI bleeding (with videos), *Gastrointest. Endosc.* 89 (2019) 33.
- [3] R.A. Agha, T. Franchi, C. Sohrabi, G. Mathew, for the SCARE Group, The SCARE 2020 guideline: updating consensus Surgical CAse REport (SCARE) guidelines, *Int. J. Surg.* 84 (2020) 226–230.
- [4] M. Esaki, T. Matsumoto, K. Watanabe, et al., Use of capsule endoscopy in patients with Crohn's disease in Japan: a multicenter survey, *J. Gastroenterol. Hepatol.* 29 (1) (2014) 96–101.
- [5] D.R. Cave, S. Hakimian, K. Patel, Current controversies concerning capsule endoscopy, *Dig. Dis. Sci.* 64 (11) (2019) 3040–3047.
- [6] M. Rezapour, C. Amadi, L.B. Gerson, Retention associated with video capsule endoscopy: systematic review and meta-analysis, *Gastrointest. Endosc.* 85 (6) (2017) 1157–68 e2.
- [7] O.C. Leit, A. Caldeira, A. Banhudo, Small bowel obstruction seven years after video capsule retention, *GE Portuguese J. Gastroenterol.* 23 (6) (2016) 333–334.
- [8] S.Y. Lee, J.Y. Lee, Y.J. Lee, et al., Natural elimination of a video capsule after retention for 1 year in a patient with small bowel Crohn disease: a case report, *Medicine* 98 (43) (2019), e17580.
- [9] L. Peyrin-Biroulet, E.V. Loftus Jr., J.F. Colombel, W.J. Sandborn, The natural history of adult Crohn's disease in population-based cohorts, *Am. J. Gastroenterol.* 105 (2) (2010) 289–297.
- [10] W. Chen, C. Lu, C. Hirota, M. Iacucci, S. Ghosh, X. Gui, Smooth muscle hyperplasia/hypertrophy is the most prominent histological change in Crohn's fibrostenosing bowel strictures: a semiquantitative analysis by using a novel histological grading scheme, *J. Crohn's Colitis* 11 (1) (2017) 92–104.
- [11] F. Rieder, E.M. Zimmermann, F.H. Remzi, W.J. Sandborn, Crohn's disease complicated by strictures: a systematic review, *Gut* 62 (7) (2013) 1072–1084.
- [12] S.F. Pasha, M. Pennazio, E. Rondonotti, et al., Capsule retention in Crohn's disease: a meta-analysis, *Inflamm. Bowel Dis.* 26 (1) (2020 Jan 1) 33–42.
- [13] David R. Cave, Shahrhad Hakimian, Krunal Patel, et al., Current controversies concerning capsule endoscopy, *Dig. Dis. Sci.* 64 (11) (2019) 3040–3047.
- [14] M. Keuchel, N. Kurniawan, P. Baltes, Small bowel ulcers: when is it not inflammatory bowel disease? *Curr. Opin. Gastroenterol.* 35 (3) (2019) 213–222.
- [15] D. Cave, P. Legnani, R. de Franchis, et al., ICCE consensus for capsule retention, *Endoscopy* 37 (2005) 1065–1067.