

Outcomes of corneal crosslinking for central and paracentral keratoconus

Mingxia Tian, MS^a, Ping Ma, MD^b, Weiyan Zhou, MD^b, Jie Feng, MS^a, Guoying Mu, MD^{b,*}

Abstract

Background: The aim of the study was to compare the therapy of corneal collagen crosslinking (CXL) for central and paracentral keratoconus.

Methods: 64 eyes of 43 central keratoconus patients whose highest power of the cornea located in the central 3 mm zone and 24 eyes of 16 paracentral keratoconus patients whose highest power located out of the central 3 mm zone received standard corneal CXL were included. Maximum keratometry (Kmax) and astigmatism according to topography, uncorrected distant visual acuity (UDVA), corrected distant visual acuity (CDVA) were studied preoperatively and 2 years postoperatively.

Results: Central group: Preoperative UDVA and CDVA were 0.9 ± 0.4 and 0.5 ± 0.4 logMAR, respectively. At 2 years, UDVA and CDVA significantly improved to 0.8 ± 0.4 and 0.4 ± 0.3 logMAR ($P < 0.01$). Preoperative Kmax and astigmatism were 61.5 ± 14.7 diopter (D) and 4.0 ± 2.9 D, respectively. At 2 years, Kmax and astigmatism significantly decreased to 57.0 ± 10.4 and 3.0 ± 2.2 D ($P < 0.01$). Paracentral group: preoperative UDVA and CDVA were 0.8 ± 0.7 and 0.2 ± 0.4 logMAR, respectively. At 2 years, UDVA significantly improved to 0.4 ± 0.4 logMAR ($P < 0.01$), whereas CDVA remained 0.2 ± 0.3 logMAR ($P > 0.05$). Preoperative Kmax and astigmatism were 50.3 ± 5.3 and 2.4 ± 1.7 D, respectively. At 2 years, Kmax significantly decreased to 48.8 ± 4.6 ($P < 0.01$), whereas astigmatism remained 2.2 ± 1.8 D ($P > 0.05$).

Conclusion: This study indicated that CXL was more effective for central keratoconus than paracentral keratoconus.

Abbreviations: ANOVA = analysis of variance, CDVA = corrected distant visual acuity, CXL = crosslinking, D = diopter, Km = mean keratometry, Kmax = maximum keratometry, LASIK = laser in situ keratomileusis, OCT = optical coherence tomography, PTK = phototherapeutic keratectomy, RGP = rigid gas permeable contact lens, UDVA = uncorrected distant visual acuity, UVA = ultraviolet A.

Keywords: central, cone location, corneal crosslinking, keratoconus, peripheral

1. Introduction

Keratoconus is a corneal noninflammatory disease, characterized by the ectasia of the central or paracentral region leading to corneal thinning steepening and scarring.^[1] The disease often happens bilaterally at puberty^[2] and can lead to blindness. The traditional treatments are corneal penetrating or lamellar transplantation and wearing rigid gas permeable contact lens (RGP). These therapies were not always satisfied. Crosslinking is a natural phenomenon in cornea with aging in an enzymatic or

nonenzymatic pattern.^[3] In 2003, Wollensak et al^[4] first introduced corneal collagen crosslinking (CXL) using riboflavin and ultraviolet A (UVA) as a new hope for treatment of progressing keratoconus. From then on, many documents^[5–9] have shown that CXL could increase the corneal biomechanical stability and visual acuity and decrease the corneal keratometry readings.

Traditionally, it is defined as central keratoconus when the highest power of the cornea located in the central 3 mm zone, whereas paracentral when the highest power located out of the central 3 mm zone. And based on mean keratometry (Km) of corneal topography, the patients of keratoconus could be classified into 3 stages: (1) Km value less than 45 D as mild, (2) Km value between 45 and 52 D as moderate, and (3) Km value more than 52 D as advanced.^[10] We wondered what about the therapy of CXL for the central keratoconus and the paracentral keratoconus and designed the study to find out the answer.

2. Methods

2.1. Patients

In total, 59 patients (88 eyes) with keratoconus or ectasia underwent CXL with 1 eye or both eyes from July 2012 to June 2014 in Shandong provincial hospital affiliated to Shandong University were included in the prospective comparative study. All the patients were followed for 2 years. Among them, 64 eyes of 43 patients were central keratoconus while other 24 eyes of 16 patients were paracentral keratoconus according to the

Editor: Khaled Ahmed Abdelrahman.

The authors have no funding and conflicts of interest to disclose.

^a Department of Ophthalmology, The First People's Hospital of Jining Affiliated to Jining Medical College, Jining, ^b Department of Ophthalmology, Shandong Provincial Hospital Affiliated to Shandong University, Jinan, Shandong Province, China.

* Correspondence: Guoying Mu, Department of Ophthalmology, Shandong Provincial Hospital Affiliated to Shandong University, Jinan, Shandong Province, China (e-mail: mgyeyes@163.com).

Copyright © 2017 the Author(s). Published by Wolters Kluwer Health, Inc. This is an open access article distributed under the terms of the Creative Commons Attribution-Non Commercial License 4.0 (CCBY-NC), where it is permissible to download, share, remix, transform, and buildup the work provided it is properly cited. The work cannot be used commercially without permission from the journal.

Medicine (2017) 96:10(e6247)

Received: 12 December 2016 / Received in final form: 7 February 2017 /

Accepted: 7 February 2017

<http://dx.doi.org/10.1097/MD.0000000000006247>

Table 1**The changes of UDVA and CDVA after 2 years of crosslinking.**

	The distant visual acuity (no. of patients[%])				
	Improvement		No change	Worsening	
	≥2 lines	Between 1 and 2 lines		Between 1 and 2 lines	≥2 lines
The uncorrected DVA					
The combined cohort (n=88)	18 (20.5)	27 (30.7)	37 (42)	5 (5.7)	1 (1.1)
The central group (n=64)	9 (14)	21 (32.8)	28 (43.8)	5 (7.8)	1 (1.6)
The paracentral group (n=24)	9 (37.5)	6 (25)	9 (37.5)	0 (0)	0 (0)
The Corrected DVA					
The combined cohort (n=88)	14 (15.9)	31 (35.2)	34 (38.6)	5 (5.7)	4 (4.6)
The central group (n=64)	13 (20.3)	22 (34.4)	23 (35.9)	4 (6.3)	2 (3.1)
The paracentral group (n=24)	1 (4.2)	9 (37.5)	11 (45.8)	1 (4.2)	2 (8.3)

CDVA=the corrected distant visual acuity, DVA=distant visual acuity, UDVA=the uncorrected distant visual acuity.

topography by Pentacam (Oculus Optikgeräte GmbH, Frankfurt, Germany).

A written consent was obtained from all the patients. The study protocol was approved by the ethics committee of Shandong Provincial hospital affiliated to Shandong University.

Inclusive criteria were patients coming to our outpatient with progressive keratoconus or corneal ectasia confirmed by corneal topography and being followed up for 2 years. Exclusive criteria were history of corneal surgeries (except for Laser in situ Keratomileusis [LASIK]), chemical injury, delayed epithelial healing, and corneal thickness <300 μm.

The uncorrected distant visual acuity (UDVA), the corrected distant visual acuity (CDVA), refraction, slit lamp bioscopy, topography, noncontact tonometer, and anterior segment optical coherence tomography (OCT, Carl Zeiss Meditec, Inc., Dublin) were examined before and after CXL.

2.2. CXL

Under topical anaesthesia, the epithelium diameter about 9 mm was removed by mechanical debridement. Riboflavin (Medio-Cross riboflavin/dextran solution, 0.1%) was administered topically for 30 minutes at intervals of 2 minutes. The cornea was illuminated for 30 minutes using a UV light lamp (UV-X 1000 system, IROC Innocross AG Co, Switzerland; wavelength 365 nm, irradiance 3 mW/cm², total dose 5.4 J/cm²). Riboflavin administration was continued during UV illumination at the same intervals. OCT was performed and if the thinnest corneal thickness <400 μm, hypotonic riboflavin (0.1% in sterile water) was administered 1 drop every 10 seconds for 2 minutes. OCT was performed to confirm that the thinnest stroma had swollen to ≥400 μm. This was repeated until adequate corneal thickness had been obtained. Antibiotic and fluorometholone drops were administered and a bandage contact lens was placed after CXL.

The bandage contact lens was removed after healing of corneal epithelium in 3 to 5 days postoperatively. Antibiotic drops were used for a week and fluorometholone drops for 2 weeks.

2.3. Statistics analysis

SPSS 17.0 was used for statistical analysis. Analysis of variance (ANOVA) was used to analyze the differences between the central and paracentral groups. The paired *t* test was used to analyze the difference of the same group at different times. Differences were considered to be statistically significant when the *P* value was < 0.05.

3. Results

However, 88 eyes of 59 patients underwent CXL and followed up for 2 years. Also, 64 eyes of 43 patients (29 males and 14 females) aged from 14 to 30 years had cone located inside the central 3 mm zone and 24 eyes of 16 patients (10 males and 6 females) aged from 12 to 31 years had cone location out of the central 3 mm zone.

3.1. UDVA and CDVA

Combined cohort. Preoperative UDVA and CDVA were 0.9 ± 0.5 and 0.4 ± 0.4 logMAR, respectively. At 2 years, UDVA and CDVA significantly improved to 0.7 ± 0.4 and 0.3 ± 0.3 logMAR ($P < 0.01$) (Tables 1 and 2).

Central group. Preoperative UDVA and CDVA were 0.9 ± 0.4 and 0.5 ± 0.4 logMAR, respectively. At 2 years, UDVA and CDVA significantly improved to 0.8 ± 0.4 and 0.4 ± 0.3 logMAR ($P < 0.01$) (Tables 1 and 2, Fig. 1A and B).

Paracentral group. Preoperative UDVA and CDVA were 0.8 ± 0.7 and 0.2 ± 0.4 logMAR, respectively. At 2 years, UDVA significantly improved to 0.4 ± 0.4 logMAR ($P < 0.01$), whereas

Table 2**Pre- and postoperative 2 years visual acuity and topography data.**

	UDVA		CDVA		Kmax (D)		Astigmatism (D)	
	Preoperative	2 years	Preoperative	2 years	Preoperative	2 years	Preoperative	2 years
The combined cohort (n=88)	0.9 ± 0.5	$0.7 \pm 0.4^*$	0.4 ± 0.4	$0.3 \pm 0.3^*$	61.5 ± 14.7	$57.0 \pm 10.4^*$	4.0 ± 2.9	$3.0 \pm 2.2^*$
The central group (n=64)	0.9 ± 0.4	$0.8 \pm 0.4^*$	0.5 ± 0.4	$0.4 \pm 0.3^*$	65.6 ± 15.0	$60.1 \pm 10.3^*$	4.6 ± 3.0	$3.3 \pm 2.2^*$
The paracentral group (n=24)	0.8 ± 0.7	$0.4 \pm 0.4^*$	0.2 ± 0.4	0.2 ± 0.3	50.3 ± 5.3	$48.8 \pm 4.6^*$	2.4 ± 1.7	2.2 ± 1.8

CDVA=the corrected distant visual acuity, Kmax = maximum keratectomy, UDVA=the uncorrected distant visual acuity.

* Indicates a significant change compared to the baseline ($P < 0.01$).

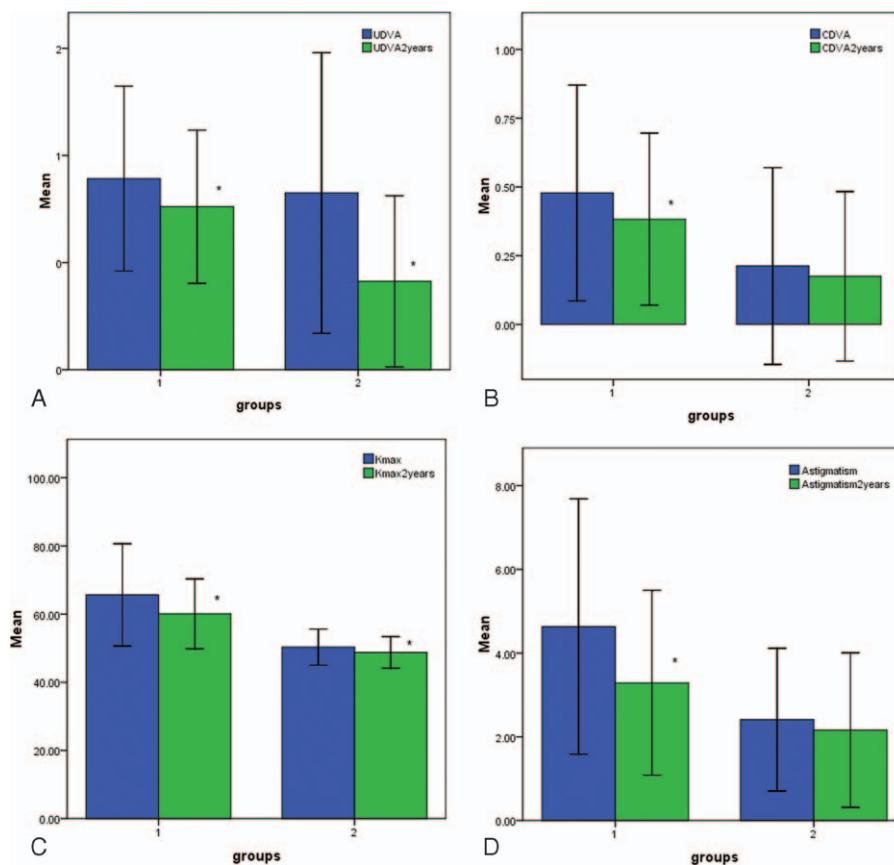


Figure 1. The preoperative and postoperative 2 years of UDVA, CDVA, maximum keratometry, astigmatism of the central group, and the paracentral group. The preoperative and postoperative 2 years of UDVA (A), CDVA (B), maximum keratometry (C), astigmatism (D) between the central group (1) and the paracentral group (2) indicated significant differences between preoperative and postoperative 2 years ($P < 0.01$). CDVA=the corrected distant visual acuity, UDVA=the uncorrected distant visual acuity.

CDVA remained 0.2 ± 0.3 logMAR ($P > 0.05$) (Tables 1 and 2, Fig. 1A and B).

The changes of UDVA of the central and paracentral groups were -0.13 ± 0.23 and -0.41 ± 0.51 logMAR, respectively, and the difference between them was significant ($P < 0.01$). The changes of CDVA of the central and paracentral groups were -0.10 ± 0.25 and -0.04 ± 0.17 logMAR, respectively, and the difference between them had no significance ($P = 0.25$).

3.2. Maximum keratectomy and astigmatism

Combined cohort. Preoperative Kmax and astigmatism were 61.5 ± 14.7 D and 4.0 ± 2.9 D, respectively. At 2 years, Kmax and

astigmatism significantly decreased to 57.0 ± 10.4 and 3.0 ± 2.2 D ($P < 0.01$) (Tables 2 and 3).

Central group. Preoperative Kmax and astigmatism were 65.6 ± 15.0 D and 4.6 ± 3.0 D respectively. At 2 years, Kmax and astigmatism significantly decreased to 60.1 ± 10.3 and 3.3 ± 2.2 D ($P < 0.01$) (Tables 2 and 3, Fig. 1C and D).

Paracentral group. Preoperative Kmax and astigmatism were 50.3 ± 5.3 and 2.4 ± 1.7 D, respectively. At 2 years, Kmax significantly decreased to 48.8 ± 4.6 ($P < 0.01$), whereas astigmatism remained 2.2 ± 1.8 D ($P > 0.05$) (Tables 2 and 3, Fig. 1C and D).

The changes of Kmax of the central and paracentral groups were -5.56 ± 8.31 D and -1.55 ± 2.10 D, respectively, and the

Table 3
The changes of maximum keratectomy and astigmatism after 2 years of crosslinking.

	Maximum keratectomy and astigmatism (No. of patients[%])				
	Decreased		No change	Increased	
	≥ 2 D	Between 1 D and 2 D		Between 1 D and 2 D	≥ 2 D
Maximum keratectomy					
The combined cohort (n=88)	44 (50)	22 (25)	20 (22.8)	1 (1.1)	1 (1.1)
The central group (n=64)	38 (43.2)	13 (20.3)	11 (12.5)	1 (1.5)	1 (1.5)
The paracentral group (n=24)	6 (25)	9 (37.5)	9 (37.5)	0 (0)	0 (0)
Astigmatism					
The combined cohort (n=88)	11 (12.5)	20 (22.7)	53 (60.2)	3 (3.5)	1 (1.1)
The central group (n=64)	12 (18.7)	18 (28.2)	32 (50)	1 (1.5)	1 (1.5)
The paracentral group (n=24)	1 (4.2)	2 (8.3)	20 (83.3)	1 (4.2)	0 (0)

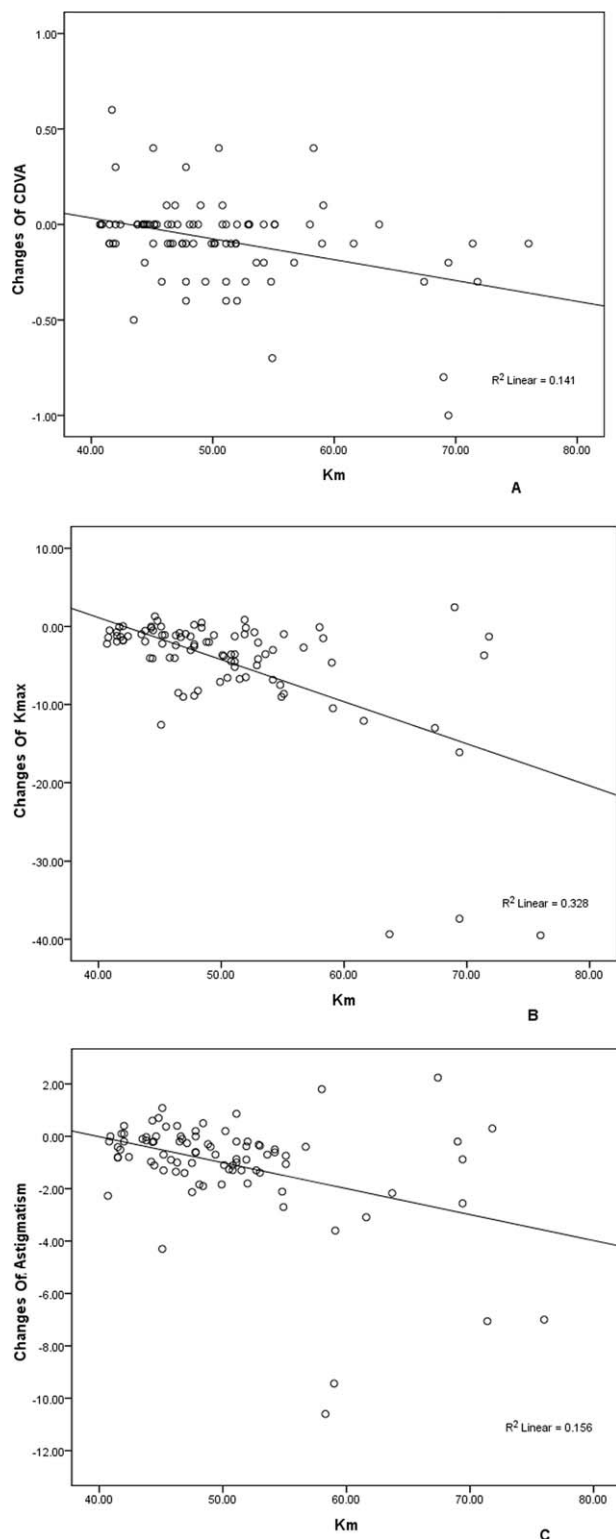


Figure 2. The correlations between the changes of CDVA, maximum keratometry, astigmatism and preoperative mean keratometry. After CXL 2 years, the changes of CDVA (A), maximum keratometry (B), and astigmatism (C) had minus correlations with preoperative mean keratometry of the combined group ($P < 0.01$). CDVA = the corrected distant visual acuity, CXL = crosslinking.

difference between them was significant ($P = 0.01$). At the same time, the changes of astigmatism were -1.34 ± 2.19 D and -0.25 ± 0.76 D, respectively, and the difference was significant ($P = 0.04$).

3.3. Mean keratometry

In the paracentral group of our study, 15 eyes' Km staged as mild and 9 eyes' as moderate, whereas in the central group, 7 eyes staged as mild, 33 eyes as moderated and 24 eyes as advanced.

After CXL 2 years, correlations between the preoperative Km and the changes of UDVA, CDVA, Kmax, astigmatism of the combined cohort were -0.044 , -0.375 , -0.573 , -0.395 respectively and all of them had significantly minus correlations ($P < 0.01$) (Fig. 2) except for the changes of UDVA ($P > 0.05$).

4. Discussion

CXL is a very hopeful method for progressive keratoconus treatment. It is a para-surgical, invasive procedure which can delay the progression of keratoconus. CXL is easy to perform and had no side effects for the endothelial cells, lens, and retina because riboflavin is a photosensibilizing agent for the production of reactive oxygen radicals and it has endothelial protection.^[11,12] And, it is safe and effective in halting the progression of keratoconus in pediatric patients (under 19 years) at Uçakhan's 4-year follow-up.^[13]

Topography is a very important device of diagnosis and therapy evaluation for keratoconus. Lamy et al^[9] found that CXL with riboflavin and UV-A decreased simulated keratometry and inhibited the progression of keratoconus. This was accordant with our results. The study found that after CXL 2 years, in the combined group, the UDVA and CDVA improved significantly and the Kmax and astigmatism decreased significantly too. This showed that CXL was effective for treating keratoconus.

The improvement of UDVA and the flattening of Kmax, astigmatism had significantly differences between the central and the paracentral groups. Furthermore, the central group showed very similar changes with the combined group while in the paracentral group, although UDVA significantly improved and Kmax significantly decreased, the CDVA and astigmatism had no significance compared to the baseline. These indicated the central cone group had more effectiveness for the CXL treatment. Unlike RGP,^[14] Greenstein et al^[15] also found that for both keratoconus and ectasia, more topographic flattening occurs in eyes with centrally located cones than the eyes with cone located paracentrally and peripherally after CXL.

First, the radiation diameter of the CXL for keratoconus is 9 mm. As the curvature of cornea, that is, the central area was nearer to the CXL radiation, the radiation intensity was possibly stronger in the central area than the paracentral area. Second, Koller et al^[16] found that the intended depth of CXL was achieved only received within the central area of the cornea and the CXL depth 3 mm away from the center decreases on average to 65% of the central depth. Third, Km of the central cone group was higher than the paracentral cone group so the therapy was perhaps affected by the stage of keratoconus. We found that in the combined group, the changes of CDVA, Kmax, and astigmatism after CXL 2 years had minus correlations with preoperative mean keratometry, that is, the higher of the Km was, the better CDVA elevated and the more decreasing of Kmax and astigmatism. In summary, these may be the causes for the central group achieved better therapy than the paracentral group.

We found that at 2 years, in the combined group, 2 eyes' (2.2%) Kmax and 4 eyes' (4.6%) astigmatism increased. The rate of keratoconic progression following CXL was about 7.6% at 1-year follow-up by Koller et al^[17] and they found that the risk factors for CXL failure included a maximum keratometry reading greater than 58.00 D, a CDVA better than 20/25 and the

patients' age older than 35 years. So in our study, the rate of progressing Kmax was less than the above study of 1 year after CXL and the patients would probably redo CXL later.

In our study, about 1/4 patients were ectasia after LASIK and most of them had paracentral cone location. Because of the less quantity of the paracentral group, we did not separate to keratoconus and ectasia subgroups in both groups. And according to Kapasi et al,^[18] long-term visual outcomes of keratoconus treated with phototherapeutic keratectomy (PTK) epithelial removal before CXL was better than that of mechanical epithelial removal before CXL. We could do these jobs later.

In conclusion, we found that CXL worked more effective for keratoconus with central location than that with paracentral location.

References

- [1] Mathew JH, Goosey JD, Bergmanson JP. Quantified histopathology of the keratoconic cornea. *Optom Vis Sci* 2011;88:988–97.
- [2] Akçay BE, Özgürhan EB, Bozkurt E, et al. Evaluation of pachymetric measurements with Scheimpflug photography-based system and optical coherence tomography pachymetry at different stages of keratoconus. *J Ophthalmol* 2014;2014:7.
- [3] Zhang X, Tao XC, Zhang J, et al. A review of collagen cross-linking in cornea and sclera. *J Ophthalmol* 2015;2015:12.
- [4] Wollensak G, Spoerl E, Seiler T. Riboflavin/ultraviolet-A-induced collagen crosslinking for the treatment of keratoconus. *Am J Ophthalmol* 2003;135:620–7.
- [5] Raiskup-Wolf F, Hoyer A, Spoerl E, et al. Collagen crosslinking with riboflavin and ultraviolet-A light in keratoconus: long-term results. *J Cataract Refract Surg* 2008;34:796–801.
- [6] Caporossi A, Mazzotta C, Baiocchi S, et al. Long-term results of riboflavin ultraviolet A corneal collagen cross-linking for keratoconus in Italy: the Siena Eye Cross Study. *Am J Ophthalmol* 2010;149:585–93.
- [7] Hersh PS, Greenstein SA, Fry KL. Corneal collagen crosslinking for keratoconus and corneal ectasia: one-year results. *J Cataract Refract Surg* 2011;37:149–60.
- [8] Toprak I, Yaylali V, Yildirim C. Factors affecting outcomes of corneal collagen crosslinking treatment. *Eye* 2014;28:41–6.
- [9] Lamy R, Netto CF, Reis RG, et al. Effects of corneal cross-linking on contrast sensitivity, visual acuity, and corneal topography in patients with keratoconus. *Cornea* 2013;32:591–6.
- [10] Brautaset RL, Nilsson M, Miller WL, et al. Central and peripheral corneal thinning in keratoconus. *Cornea* 2013;32:257–61.
- [11] Niculaa C, Niculaa D, Popescua R, et al. Corneal collagen cross-linking in keratoconus—long-term prospective study. *J Fr Ophthalmol* 2015;38:199–205.
- [12] Raiskup F, Theuring A, Pillunat LE, et al. Corneal collagen crosslinking with riboflavin and ultraviolet-A light in progressive keratoconus: ten-year results. *J Cataract Refract Surg* 2015;41:41–6.
- [13] Uçakhan ÖÖ, Bayraktutar BN, Sağlık A. Pediatric corneal collagen cross-linking: long-term follow-up of visual, refractive, and topographic outcomes. *Cornea* 2016;35:162–8.
- [14] Nejabata M, Khalili MR, Dehghani C. Cone location and correction of keratoconus with rigid gas-permeable contact lenses. *Contact Lens Anterior Eye* 2012;35:17–21.
- [15] Greenstein SA, Fry KL, Hersh PS. Effect of topographic cone location on outcomes of corneal collagen cross-linking for keratoconus and corneal ectasia. *J Refract Surg* 2012;28:397–405.
- [16] Koller T, Schumacher S, Fankhauser FII, et al. Riboflavin/ultraviolet A crosslinking of the paracentral cornea. *Cornea* 2013;32:165–8.
- [17] Koller T, Mrochen M, Seiler T. Complication and failure rates after corneal crosslinking. *J Cataract Refract Surg* 2009;35:1358–62.
- [18] Kapasi M, Dhaliwal A, Mintsoulis G, et al. Long-term results of phototherapeutic keratectomy versus mechanical epithelial removal followed by corneal collagen cross-linking for keratoconus. *Cornea* 2016;35:157–61.