



Contents lists available at ScienceDirect

International Journal of Surgery Case Reports

journal homepage: www.casereports.com

The successful salvage of a thrombosed pancreatic graft at the early postoperative period of a simultaneous pancreas and kidney transplantation

Rauf Shahbazov^{a,*}, Feredun Azari^c, Park Auh Whan^b, Liu Wei^a, Avinash Agarwal^a, Kenneth L. Brayman^a

^a Department of Surgery, University of Virginia, Charlottesville, Virginia, PO Box 800709, Charlottesville, VA 22908-0709, USA

^b Department of Interventional Radiology, University of Virginia, Charlottesville, Virginia, PO Box 800709, Charlottesville, VA 22908-0709, USA

^c Department of Surgery, Hospital of the University of Pennsylvania, Philadelphia, PA, 19104

ARTICLE INFO

Article history:

Received 19 January 2018

Accepted 5 March 2018

Available online 16 March 2018

Keywords:

Pancreas

Kidney

Transplant

Venous thrombosis

Complications

ABSTRACT

INTRODUCTION: Simultaneous kidney and pancreas transplant is the preferred treatment option for end-stage renal disease due to type 1 diabetic nephropathy. Vascular complications are detrimental to graft survival and can lead to graft loss in the early postoperative phase of transplantation. Generally, duplex Doppler ultrasound is used for vascular patency monitoring and pancreatectomy followed by re-transplantation is required in the majority of cases. Recently, pancreatic graft salvage with non-operative management, including medical anticoagulation and endovascular thrombectomy, in the early postoperative period has been described with success.

PRESENTATION OF CASE: We report a case of early detection of pancreas venous graft thrombosis via clinical suspicion and radiological methods, and early intervention with endovascular thrombolysis. As a result, the pancreatic graft was successfully salvaged.

DISCUSSION: A limited number of studies had showed successful graft salvage in only 30–45% of thrombosed pancreatic graft with surgical thrombectomy. Our patient also had bleeding from the vascular access site and ultimately required blood transfusion, however she recovered well after procedure.

CONCLUSION: Given the complexity and significance of PVGT, urgent and prompt treatment is necessary. Interpreting outcomes from our case and other small studies, it appears that endovascular pharmacomechanical thrombectomy can be a vital tool to salvage graft organs in those receiving SPK.

Published by Elsevier Ltd on behalf of IJS Publishing Group Ltd. This is an open access article under the CC BY-NC-ND license (<http://creativecommons.org/licenses/by-nc-nd/4.0/>).

Introduction

Transplant options for patients with end stage renal disease (ESRD) due to type 1 diabetes mellitus (T1DM) include deceased donor kidney (DDK), living donor kidney (LDK) and simultaneous pancreas and kidney transplantation (SPK). Among all the options, SPK is an established treatment for T1DM due to its associated high graft survival rate and high patient overall survival rate compared

Abbreviations: ATG, anti-thymocyte globulin; CMV, cyto megalovirus; DVT, deep vein thrombosis; SMV, superior mesenteric vein; SMA, superior mesenteric artery; T1DM, type 1 diabetes mellitus; DDK, deceased donor kidney; LDKT, living donor kidney transplantation; GFR, glomerular filtration rate; ESRD, end stage renal disease; SPK, simultaneous pancreas and kidney transplantation; PVGT, pancreas venous graft thrombosis; MRI, magnetic resonance imaging.

* Corresponding author.

E-mail addresses: RS2V@hscmail.mcc.virginia.edu (R. Shahbazov), Feredun.Azari@uphs.upenn.edu (F. Azari), AP7WV@virginia.edu (P.A. Whan), WL8CG@virginia.edu (L. Wei), AA4VB@virginia.edu (A. Agarwal), KLB9R@virginia.edu (K.L. Brayman).

<https://doi.org/10.1016/j.ijscr.2018.03.014>

2210-2612/Published by Elsevier Ltd on behalf of IJS Publishing Group Ltd. This is an open access article under the CC BY-NC-ND license (<http://creativecommons.org/licenses/by-nc-nd/4.0/>).

to DDK and LDK [1]. Specifically, the current 1 year graft survival rate for SPK is 85% [2]. In addition, SPK improves patients' quality of life via better glycemic control without requiring insulin, which is especially important in patients with hypoglycemic unawareness and hyperlabile diabetes. More recently successful SPK procedure have been reported for even morbid obese patients and living donors using minimal invasive technique [3,4]. The main advantage of SPK is optimal glycemic control therefore, the reduction and reversal of long-term micro and macrovascular complications of diabetes, including diabetic retinopathy, nephropathy and cardiovascular diseases.

Although SPK is the preferred treatment for patients with T1DM, it is a complex procedure and is associated with high morbidity and mortality rate due to early and late complications [5,6]. Among many contributing factors, including immunosuppression, post-operative management and surgical techniques, technical failure is responsible for the majority of pancreatic graft losses in the first 6 months after transplantation [5]. Technical failure in pancreatic transplantation is described as graft loss due to vascular thrombo-

sis, pancreatitis, intra-abdominal infections, anastomotic leaks or bleeding [7]. Furthermore, multiple studies have shown that vascular thrombosis is the major cause of pancreatic graft failure and is responsible for more than half of all losses within the first 3 months after transplant [8,9].

Pancreas venous graft thrombosis (PVGT) is very difficult to detect clinically due to the lack of clinical signs on physical exams and highly fluctuated serum glucose levels that could be affected by medications, electrolyte supplementation and fluid resuscitation. In addition, certain imaging modalities require nephrotoxic agents and are time consuming in the case of an urgent salvageable thrombotic event [10]. Therefore, many centers use duplex Doppler ultrasound to routinely monitor vascular patency of the pancreatic graft. Once vascular thrombosis is detected, surgical re-exploration and pancreatectomy followed by re-transplant is usually required. More recently, there has been an increasing amount of reports on the successful salvage of pancreatic grafts with medical anticoagulation or endovascular thrombectomy in the early post-operative period [11,13].

Here, we describe a case involving a 29-year-old female who underwent SPK transplantation and developed PVGT during the early postoperative period. Her venous thrombosis was successfully diagnosed and salvaged using endovascular intervention. This case report has been reported in line with SCARE criteria [12].

Case report

The patient was a 29-year-old woman with a 16-year history of T1DM who developed ESRD and had been dependent on peritoneal dialysis since 2012. Her T1DM was complicated by hyper-labile glucose levels and she was frequently unaware of hypoglycemic

episodes. Her comorbidities also included diabetic retinopathy, controlled hypothyroidism, hypertension and hyperlipidemia. She was placed on the UNOS list for an SPK transplant in 2013 after completing all the appropriate evaluations. Additionally, a dobutamine stress echocardiogram and cardiopulmonary exercise stress test were performed 6 months before the transplant and both tests demonstrated good cardiac reserve.

The patient underwent a deceased-donor SPK on January 16th 2016. The pancreas was implanted intra-peritoneally in the right iliac fossa. Pancreatic arterialization was achieved via anastomosis of the donor iliac artery Y graft to the recipient's right external iliac artery. Pancreatic venous drainage was achieved with primary anastomosis of the donor's portal vein to the recipient's right external iliac vein, with no venous extension graft. Exocrine drainage was established to the bladder. The kidney was implanted intra-abdominally in the left iliac fossa. Its arterial and venous drainage were achieved via vascular anastomoses to the left external iliac artery and vein respectively. The operation was uneventful.

Intra-operatiely the induction regime consisted 500 mg of methylprednisolone intravenously prior to organ reperfusion and 1.5 mg/kg anti-thymocyte globulin (ATG) intravenously via central line after reperfusion. Total thymoglobulin administration was 6 mg/kg. Maintenance immunosuppressive therapy included prednisolone, tacrolimus and mycophenolate mofetil.

There was immediate function of both transplanted organs. The kidney started making urine right after reperfusion, and the patient remained euglycemic throughout her hospital course. She did not require any exogenous insulin after the transplant. Postoperative capillary blood glucose levels remained stable as shown in Fig. 1. Heparin was given at a dosage of 5000 units subcutaneously 3 times daily, as a prophylaxis for venous thromboembolism. In our center,

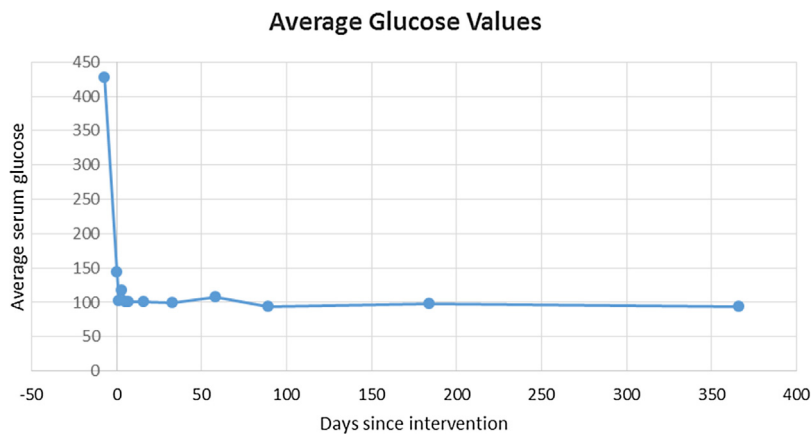


Fig. 1. Serum Glucose level after SPK transplantation.

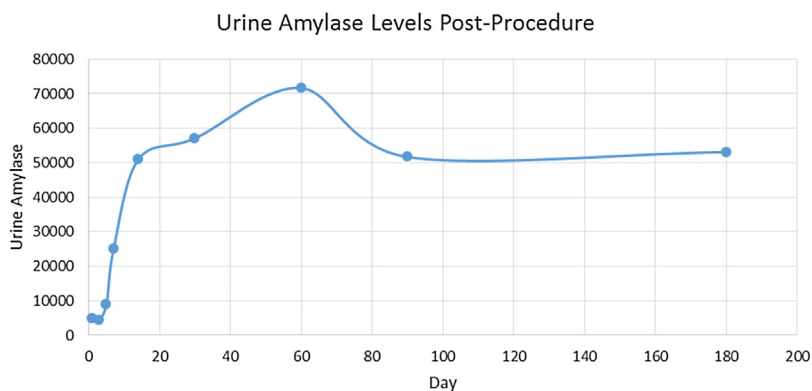


Fig. 2. Urine Amylase Levels Post SPK transplantation.

the exocrine pancreas is routinely drained via the bladder because it allows for serial measuring of amylase levels in the urine as a marker for early acute rejection. She did not have any laboratory abnormalities in urine amylase level as shown in Fig. 2, nor did she have any abnormal clinical signs.

However, on post op day 5, the patient complained of bilateral leg swelling and pain. She also noticed the symptoms to be more severe on the right side. Therefore, she was placed on continuous heparin infusion for DVT prophylaxis. MRI/MRA was obtained and showed near occlusive thrombus that extended from the right external iliac vein up to the right common iliac vein and further extended through the transplant pancreas anastomosis, including the donor portal vein, splenic vein and SMV. Imaging also showed occlusion of the right internal iliac vein and peripancreatic edema. The main arterial supply and iliac Y graft were intact except for an occlusive thrombus in the distal SMA supplying the distal pancreatic head. However, parenchymal enhancement of the transplant pancreas on imaging suggested tissue viability. Based on these findings, a decision was made to perform an emergent endovascular thrombectomy to improve venous outflow by our interventional radiologists.

With the patient on prone position, an access was obtained under ultrasound guidance through the right popliteal vein. After advancing a vascular sheath up to the right common femoral vein, venography was obtained which revealed an extensive intraluminal filling defect in the right common and external iliac vein with the development of collaterals (Fig. 3). Pulse spray with 6 mg of tPA was performed across the clots followed by mechanical thrombectomy using a device (Angiojet). Additional balloon angioplasty with a 14 mm–4 cm balloon (Atlas) was done to open more of the residual stenosis and to macerate the residual clots (Fig. 4). Completion venogram demonstrated a rapid flow through the right common

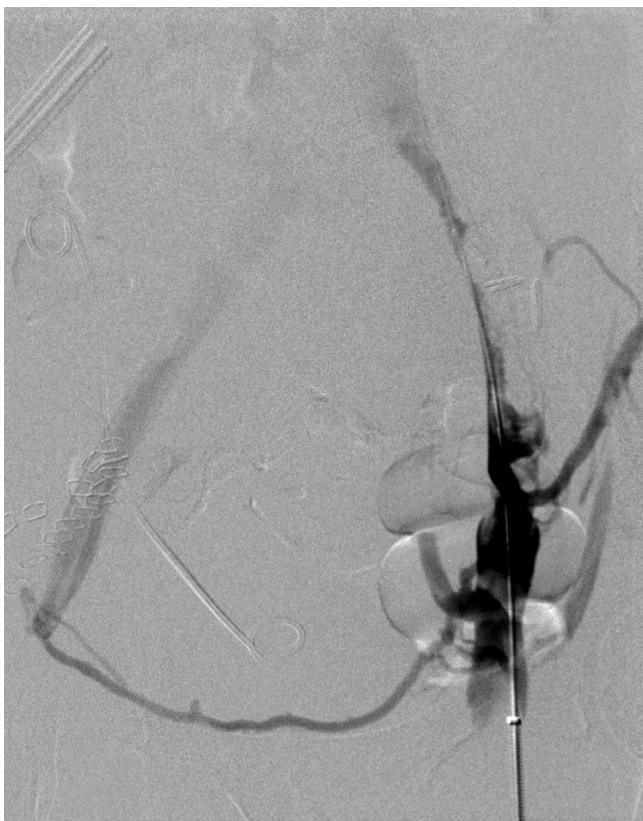

Fig. 3. The venogram of the right pelvis on prone position reveals an almost complete luminal occlusion of the right common and external iliac veins with development of the pelvic collaterals.

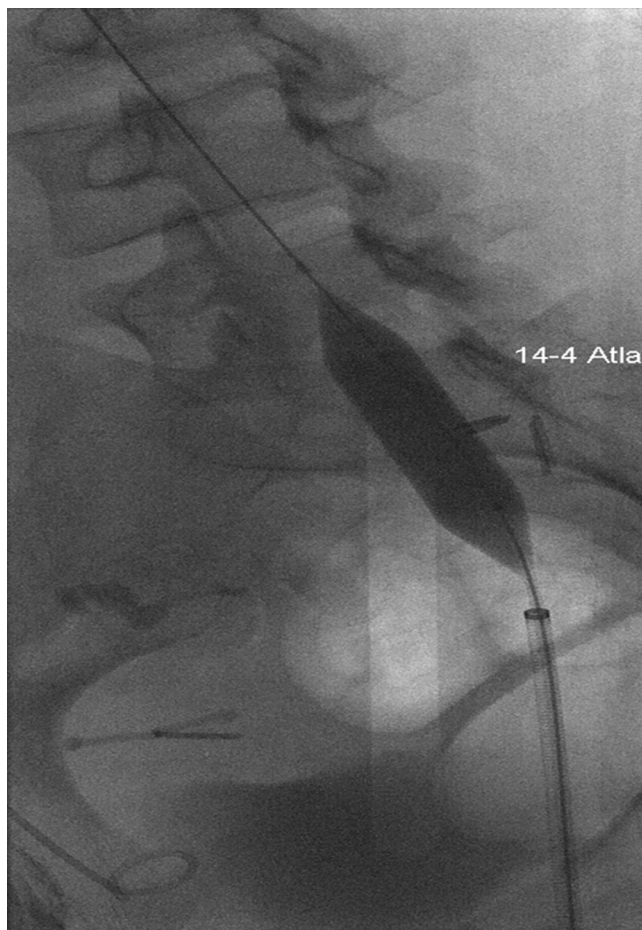


Fig. 4. The stenotic segments were dilated using balloon catheters up to 14 mm following pharcomechanical thrombectomy with tPA pulse spray and negative suctioning thrombectomy.

and external iliac veins even though about 50% of luminal stenosis still remained with no more residual clots (Fig. 5).

After the thrombectomy, systemic anticoagulation was administered with an intravenous heparin infusion titrated to maintain heparin level of 0.20–0.50. The patient was subsequently converted to oral Apixaban. A Doppler ultrasound scan was performed 2 days after the thrombectomy, which showed normal arterial and venous flow, and a fully patent pancreatic portal vein showing normal cardiac variations.

Heparin infusion protocol was reinitiated after the procedure. However, on the eve of her procedure she had bleeding from the femoral arterial access site. The patient required manual compression, discontinuation of the heparin infusion, and ultimately required two units of packed red blood cells. Furthermore, on post procedure day 1, she had significantly improved flow through the iliac veins but transplant pancreas vein anastomosis was not visualized until post procedure day 2. Her kidney and pancreas grafts were found to be working well as demonstrated by normal creatinine and fasting blood glucose values. She was discharged on post-operative day 10 with Apixaban. At her 6-month clinic follow-up, there was no evidence of hyperglycemia or any further elevation of serum amylase level. At her 1-year clinic follow-up, she remained euglycemic and had stopped taking Apixaban.

Discussion

SPK is one of the well-recognized treatment options for combined T1DM and ESRD. However, technical failure has been shown

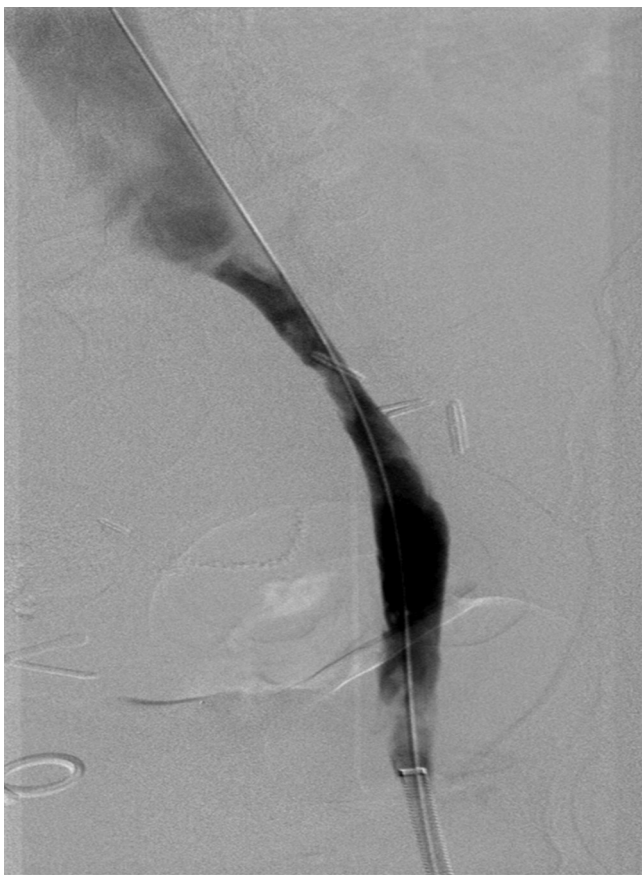

Fig. 5. The venogram after balloon angioplasty shows restoration of flow even with about 50% luminal stenosis but without any existing residual clots.

to be responsible for more than half of all pancreas graft lost in the first 6 months after SPK [5]. According Fridell et al., vascular thrombosis accounts for the majority of the cases of early graft loss [10]. Routine systemic anticoagulation protocols used by multiple centers are controversial due to an increased risk of bleeding and lack of randomized controlled studies proving their effectiveness [14]. Despite the lack of clear consensus on the treatment of patients with graft thrombosis, it is clear that some kind of treatment is needed promptly in order to salvage the graft organ [15]. The choice of treatment depends on the availability of skilled interventional radiologist, location of the thrombosis, and experience of the treatment team [16]. Given that our patient developed thrombosis despite being on systemic anti-coagulation, the only viable option was mechanical thrombectomy by the interventional radiology team. The procedure was highly effective in our patient as her kidney and pancreas grafts remained functional.

Literature is limited in regards to endovascular thrombectomy in SPK patients. Nevertheless, in a single-center report by Barrufet et al., either partial or complete lysis of thrombi was achieved in 94% of the patients who received pancreatic graft vein thrombectomy [17]. The study did not mention complications directly related to the endovascular treatment but had recognizable risks related to post-procedural bleeding [11]. As mentioned previously, our patient also had bleeding from the vascular access site and ultimately required blood transfusion. In comparison, a limited study by Fridell et al. showed successful graft salvage in only 45% of thrombosed pancreatic graft with surgical thrombectomy [10].

Given the complexity and significance of PVGT, urgent and prompt treatment is necessary. Interpreting outcomes from our case and other small studies, it appears that endovascular phar-

macomechanical thrombectomy can be a vital tool to salvage graft organs in those receiving SPK.

Conflicts of interest

We disclose that there are no financial and personal relationships with other people.

Funding

We do not have sponsors.

Ethical approval

Ethical approval has been exempted by University of Virginia Health System for this case report.

Consent

Patient has written consent for the publication of this case report.

Author contribution

Rauf Shahbazov, study concept or design, data collection, data analysis or interpretation, writing the paper. Feredun Azari, data collection, data analysis or interpretation, writing the paper. Park Auh Whan, data collection, data analysis or interpretation, writing the paper. Liu Wei, data collection, data analysis or interpretation, writing the paper. Avinash Agarwal, data analysis or interpretation, writing the paper. Kenneth Brayman, study concept or design, data analysis or interpretation, writing the paper.

Registration of research studies

None.

Guarantor

Dr Kenneth L. Brayman MD, PhD is a guarantor for this study.

References

- [1] J.P. Lindahl, A. Hartmann, R. Horneland, H. Holdaas, A.V. Reisaeter, K. Midtvedt, et al., Improved patient survival with simultaneous pancreas and kidney transplantation in recipients with diabetic end-stage renal disease, *Diabetologia* 56 (6) (2013) 1364–1371.
- [2] R. Kandaswamy, P.G. Stock, S.K. Gustafson, M.A. Skeans, M.A. Curry, M.A. Prentice, et al., OPTN/SRTR 2015 annual data report: pancreas, *Am. J. Transplant.* 17 (Suppl. 1) (2017) 117–173.
- [3] C.C. Yeh, M. Spaggiari, I. Tzvetanov, J. Oberholzer, Robotic pancreas transplantation in a type 1 diabetic patient with morbid obesity: a case report, *Medicine* 96 (6) (2017) e5847.
- [4] J. Oberholzer, I. Tzvetanov, A. Mele, E. Benedetti, Laparoscopic and robotic donor pancreatectomy for living donor pancreas and pancreas-kidney transplantation, *J. Hepato-Biliary-Pancreat. Sci.* 17 (2) (2010) 97–100.
- [5] A. Humar, T. Ramcharan, R. Kandaswamy, R.W. Gruessner, A.C. Gruessner, D.E. Sutherland, Technical failures after pancreas transplants: why grafts fail and the risk factors—a multivariate analysis, *Transplantation* 78 (8) (2004) 1188–1192.
- [6] T. Alhamad, A.F. Malone, D.C. Brennan, R.J. Stratta, S.H. Chang, J.R. Wellen, et al., Transplant center volume and the risk of pancreas allograft failure, *Transplantation* 101 (11) (2017) 2757–2764.
- [7] M.S. Khubutia, A.V. Pinchuk, I.V. Dmitriev, A.G. Balkarov, R.V. Storozhev, Y.A. Anisimov, Surgical complications after simultaneous pancreas-kidney transplantation: a single-center experience, *Asian J. Surg.* 39 (4) (2016) 232–237.
- [8] E. MacCraith, N.F. Davis, C. Browne, P. Mohan, D. Hickey, Simultaneous pancreas and kidney transplantation: incidence and risk factors for amputation after 10 years follow-up, *Clin. Transplant.* 31 (6) (2017) e12976.
- [9] A. Moiz, T. Javed, H. Bohorquez, D.S. Bruce, I.C. Carmody, A.J. Cohen, et al., Role of special coagulation studies for preoperative screening of thrombotic

- complications in simultaneous pancreas-kidney transplantation, *Ochsner J.* 15 (3) (2015) 272–276.
- [10] J.A. Fridell, R.S. Mangus, A.B. Mull, T.E. Taber, C.E. Sanders, R.C. Slisher, et al., Early reexploration for suspected thrombosis after pancreas transplantation, *Transplantation* 91 (8) (2011) 902–907.
- [11] K. Izaki, M. Yamaguchi, I. Matsumoto, M. Shinzeki, Y. Ku, K. Sugimura, et al., Percutaneous selective embolectomy using a Fogarty Thru-Lumen Catheter for pancreas graft thrombosis: a case report, *Cardiovasc. Intervent. Radiol.* 34 (3) (2011) 650–653.
- [12] R.A. Agha, A.J. Fowler, A. Saeta, I. Barai, S. Rajmohan, D.P. Orgill, Erratum to the SCARE guidelines: consensus-based surgical case report guidelines [*Int. J. surg.* 34 (2016) 180–186], *Int. J. Surg. (Lond., Engl.)* 36 (Pt A) (2016) 396.
- [13] J.L. Scheffert, D.J. Taber, N.A. Pilch, K.D. Chavin, P.K. Baliga, C.F. Bratton, Clinical outcomes associated with the early postoperative use of heparin in pancreas transplantation, *Transplantation* 97 (6) (2014) 681–685.
- [14] O.M. Reslan, J.M. Kirsch, H. Kaul, S. Campos, R. Zaki, P.S. Brady, et al., Endovascular stenting of portal vein for graft rescue after a pancreas transplant venous graft thrombosis: a case report, *Ann. Vasc. Surg.* 42 (2017) 301.e13–301.e17.
- [15] C. Troppmann, Complications after pancreas transplantation, *Current Opin. Organ Transplant.* 15 (1) (2010) 112–118.
- [16] M. Barrufet, M. Burrel, M. Angeles Garcia-Criado, X. Montana, M.I. Real, J. Ferrer, et al., Pancreas transplants venous graft thrombosis: endovascular thrombolysis for graft rescue, *Cardiovasc. Intervent. Radiol.* 37 (5) (2014) 1226–1234.
- [17] A.H. Stockland, D.L. Willingham, R. Paz-Fumagalli, H.P. Grewal, J.M. McKinney, C.B. Hughes, et al., Pancreas transplant venous thrombosis: role of endovascular interventions for graft salvage, *Cardiovasc. Intervent. Radiol.* 32 (2) (2009) 279–283.

Open Access

This article is published Open Access at [sciencedirect.com](https://www.sciencedirect.com). It is distributed under the [IJSCR Supplemental terms and conditions](#), which permits unrestricted non commercial use, distribution, and reproduction in any medium, provided the original authors and source are credited.