



ELSEVIER

Contents lists available at [ScienceDirect](https://www.sciencedirect.com)

Trauma Case Reports

journal homepage: www.elsevier.com/locate/tcr

Case Report

Drainage of an extradural haematoma by intraosseous needle in a remote hospital

Aruni Sen^{a,*}, Nemer Kharroubi^a, Anthea Pinder^a, Jonathan Hempenstall^b^a Princess Elizabeth Hospital, Guernsey, UK^b Wessex Neurosurgical Centre, Southampton General Hospital, UK

ARTICLE INFO

Keywords:

Traumatic brain injury
 Acute extradural haematoma
 Intraosseous needle drainage
 Remote medicine

ABSTRACT

We report the case of an intraosseous needle used to drain an acute extra-dural haematoma in a remote hospital. An 18 yr. old female attended the Emergency Department, after sustaining a closed head injury from a fall. After a CT scan, she was diagnosed with a large acute extradural haematoma (EDH). Prior to air ambulance transfer to the Neurosurgical Centre, she developed a fixed dilated pupil and hemodynamic instability. The Neurosurgeon advised that an intraosseous (IO) needle drainage would prevent brain stem herniation. An Emergency Medicine (EM) consultant drained 60 ml of blood and clot via an IO needle. The pupil and cardiovascular status normalised. The patient underwent neurosurgical drainage with full neurological recovery.

We believe that this is the first IO drainage of an EDH at a remote hospital followed by full neurological recovery.

Background

Extradural haematoma is a known complication of closed head injury. If large, it constitutes a neurosurgical emergency requiring formal craniotomy and evacuation of the haematoma. The NICE standard of care for EDH drainage is 4 h from CT diagnosis [1].

However, many patients with low intensity, closed head injury are likely to present to a local hospital and not to a Level 1 trauma centre. This always adds to the delay in transfer. When the receiving hospital is on a remote island, 180 miles off the UK coast, the logistics of air transfer is significant.

The extent of neurological and cardiovascular compromise is dictated by a rising Intra Cranial Pressure (ICP). ICP can be pharmacologically temporised by reducing brain volume with sedation and osmotherapy. Drainage of a small amount of haematoma may dramatically reduce the ICP.

If faced with imminent brain stem catastrophe, this is the only means of averting death.

Options of draining an EDH are limited outside a neurosurgical unit. Emergency burr hole decompression has been used on rare instances. It has not been routinely adopted due to unfamiliarity with the surgical technique in ED. Focus has shifted to rapid transfer to a neurosurgical centre.

We describe a successful use of an IO needle to drain the haematoma at a remote hospital intensive care unit (ICU), to normalise anisocoria and cardiovascular status. The patient reached the neurosurgical theatre alive and made a full functional recovery.

* Corresponding author at: Emergency Department, Princess Elizabeth Hospital, Rue Mignot, St Martin GY4 6UU, Guernsey.
 E-mail address: thesens@msn.com (A. Sen).

<https://doi.org/10.1016/j.tcr.2022.100750>

Accepted 30 December 2022

Available online 31 December 2022

2352-6440/Crown Copyright © 2023 Published by Elsevier Ltd. This is an open access article under the CC BY-NC-ND license (<http://creativecommons.org/licenses/by-nc-nd/4.0/>).

Case presentation

An 18 year old patient was brought to our Emergency Department (ED) after a fall from standing height. There was a possible brief loss of consciousness, followed by rapid recovery. Her Glasgow Coma Score (GCS) on arrival was 15, both pupils were size 3 & reacting to light. Her neurological status & vital signs were normal. She reported earache, which did not resolve with analgesia.

Investigations

A CT brain scan showed a large left extradural haematoma (EDH), overlying linear fracture of the temporal bone (petrous & squamous) and small volume pneumocephalus ([Image 1](#)).

Treatment

Within 2 h, her GCS dropped to 9 (E2 V2 M5), heart rate (HR) dropped to 43 bpm and systolic blood pressure (SBP) dropped to 86 mm Hg. She was intubated and ventilated in ED. The bradycardia was corrected IV Atropine. The hypotension needed 500 ml of crystalloid and a phenylephrine infusion (SBP 100 mm Hg).

On arrival in the Intensive Care Unit (ICU), her left pupil dilated to size 6 and was minimally reacting to light (right pupil size 3). She was accepted by the regional Neurosurgical Unit for urgent surgical evacuation of the EDH.

Neither the air ambulance nor coastguard helicopter was able to reach for at least 2 h due to flight logistics.

The anisocoria responded temporarily to hypertonic (2.7 %) saline. BP was maintained on phenylephrine infusion.

Given the risk of coning, our ICU consultant was advised by the Neurosurgeon that closed drainage of the EDH would be lifesaving. The technique had been previously used at the neurosurgical centre. This involved using an EZ-IO intraosseous needle (Vidacare®), removing as much blood as possible and leaving the needle in for future aspiration. The anticipated volume of EDH was 100–120 ml. The best site for the IO needle was deemed to be a point on the scalp, 6 cm vertically above the external auditory meatus and 2 cm posterior.

The ED consultant was asked to do this procedure, given his familiarity with the use of IO needle in resuscitation.

A 15G (45 mm) IO (yellow) needle was inserted to 75 % of its depth. 60 ml of fresh blood and clot was evacuated via the IO needle. The needle was stable through the skull and kept in position with gauze & bandage round the head for future use ([Picture 1](#)). The entire procedure took less than 10 min.

The left pupil reduced to size 3 immediately and started reacting to light.

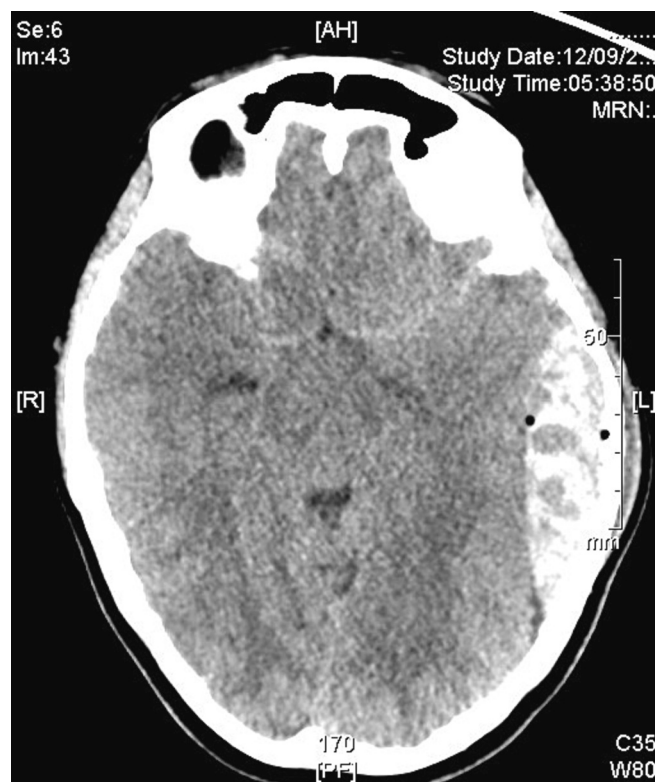
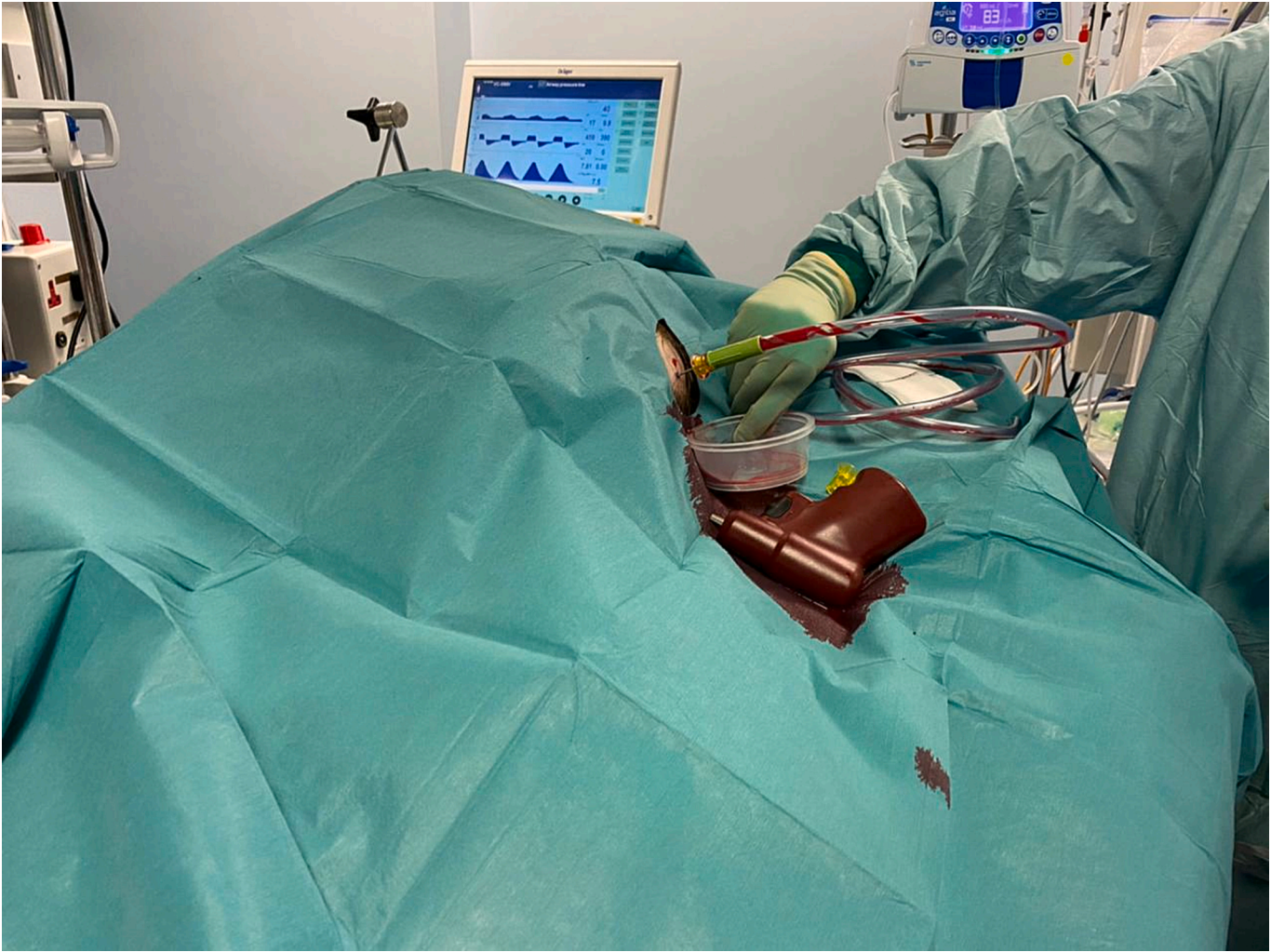


Image 1. CT scan showing large EDH and intracranial air.



Picture 1. IO needle in situ on left temporal bone.

The patient was handed over to the Retrieval team and was flown over to the neurosurgical unit. The IO drainage did not delay the transfer.

Her left pupil dilated again (size 6) during take-off (35 min flight), which was treated by 160 ml bolus of hypertonic (2.7 %) saline and repeat aspiration of blood (3 ml) via the IO needle. This cured the anisocoria. On arrival at the Neurosurgical Centre, the patient was taken directly to operating room for craniotomy and haematoma evacuation. She was extubated in neuro-ICU on post-operative Day 1.

Outcome and follow-up

She was GCS 15 and showed no neurodeficit. On Day 2, she was returned to the neurosurgery ward and repatriated home on Day 8, having made a full recovery.

She returned to full function and resumed her job after 2 months.

Discussion

We report the first IO needle drainage of an EDH done at a remote hospital off UK mainland with full functional recovery.

Use of IO needles to drain such haematomas by neurosurgeons, in the context of high ICP and haemodynamic instability, have been reported [2]. The procedure has been successfully performed by non-neurosurgeons in the ED in USA [3] and ICU in UK [4]. Good neurological outcome has also been reported from Burr Hole drainage of EDH performed in ED at a remote location [5]. Under similar time pressures in a rural ED in USA, even subdural haematomas have been drained by IO needle [6].

The insertion of IO needle takes very little time, universally successful in drainage of blood and has relied on the ready availability of this skill [3,4,6]. However, functional outcome has been variable as this is dependent on the primary injury, duration of anisocoria and pressure on the brain stem.

Drainage of EDH is a time critical intervention. This is even more emergent where the patient develops early anisocoria, shows haemodynamic instability (HR & BP) and is about to cone, risking brain stem damage or death.

A remote hospital is located away from the Level 1 trauma centre. Our hospital is on a small channel island 137 air miles (35 minute flying time) away from UK. A critical transfer via air ambulance takes 2–4 h. In our case, it was 2.5 h from the decision to transfer to the retrieval crew arriving. The patient did not reach neurosurgery OR till 6 h from the first episode of bradycardia. If we waited for formal neurosurgical drainage, despite signs of brain stem compression, there was a clear risk of harm and probable death.

Under these circumstances, where life is at risk, and neurosurgical evacuation is not imminent, the bedside IO needle decompression is well justified, albeit off-label, as a last resort. The rising number of successful case reports worldwide is adding to the evidence of its feasibility and safety.

The determinant of success was the discussion with the neurosurgeon and localisation of the spot to insert the IO needle.

The authors emphasize that this procedure must not be attempted without input from a neurosurgeon.

Concerns have been raised about off-label use of an IO needle to drain EDH. This should not deter against such use when a patient's life is at obvious risk.

Similar off-label use of IV cannula (Venflon®) to decompress a tension pneumothorax is widely practised by trauma clinicians, bears evidence of its efficacy and is formally taught at ATLS® courses worldwide [7].

The procedure was relatively straight forward to do and took less than 10 min. Skills of inserting an IO needle through a bone (usually tibia) is widely practised in adult & paediatric resuscitation, is a core skill in EM and is formally taught at life support courses (APLS, EPALS) in UK [8,9]. Blood aspirated confirms the benefit of even a small volume reduction on rising ICP. Each time an IO needle has been used, a meaningful volume of blood has been aspirated [2–4,6].

We were fortunate that the retrieval crew had the necessary skills to use the IO needle in situ to drain more blood, when the anisocoria returned during take-off. The procedure was successful for the second time.

The risks of IO needle drainage would be missing the EDH, infection or brain tissue damage. This appears no worse than insertion of an ICP bolt [10]. Formal craniotomy would mitigate some of these risks and is certainly less harmful than death.

In conclusion, we believe IO needle should become a lifesaving procedure of last resort in any hospital, if the patient is showing brainstem compression, and neurosurgical evacuation of the EDH is not immediately possible. Discussion with the receiving neurosurgical team and accurate localisation of the EDH are essential. Skills of IO insertion is widely present in many acute clinicians. It is gratifying to know that blood & clot can be aspirated and washed out by an IO needle, even 6 h after head injury.

Our young patient made a full neurological recovery and is now back to normal life. This alone must underscore the need.

Learning points

- A large extradural haematoma can raise ICP rapidly and risk causing potentially fatal brain stem herniation.
- Urgent transfer to a neurosurgical theatre for formal drainage is the norm.
- Where immediate transfer is not feasible, decompression of the haematoma by an intra-osseous needle is safe and potentially life-saving.

Patient's perspective

The patient signed a written consent for this case report.

She had no recall of events after the fall. She has made a full recovery and has resumed her job. She is under review for emotional lability and poor memory.

She met the author to review the CT images and the picture of the IO needle in situ.

Consent

The author obtained written consent from the patient.

Funding

None received.

Peer review

Not commissioned. Externally peer reviewed.

CRedit authorship contribution statement

NK treated the patient in ED and arranged an early CT scan on clinical judgement. AP managed the patient in ED & ICU, and strongly believed that IO was an excellent solution. AS performed the procedure and wrote the paper. JH was the receiving neurosurgeon and advised AP & AS about the procedure.

All authors contributed to revisions of the paper.

Conflict of interest

None declared.

Acknowledgement

The procedure was conceived originally by JH, who guided the author on the day.

We acknowledge the skills shown by ED, ICU, Theatre staff and the retrieval crew (ICU doctor & critical care paramedic) in managing the patient, assisting with a procedure without precedence both in Guernsey and during retrieval flight.

References

- [1] National Institute of Clinical Excellence, Head Injury – Assessment & Early Management. CG 176, 2019.
- [2] H. Bulstrode, S. Kabwama, A. Durnford, et al., Temporising extradural haematoma by craniostomy using an intraosseous needle, *Injury* 48 (2017) 1098–1100.
- [3] C. McClung, J. Anshus, A. Anshus, et al., Bedside craniostomy and serial aspiration with an intraosseous drill/needle to temporize an acute epidural haemorrhage with mass effect, *World Neurosurg.* 142 (2020) 218–221.
- [4] S. Durnford, H. Bulstrode, A. Durnford, et al., Temporising an extradural haematoma by intraosseous needle craniostomy in the district general hospital by non-neurosurgical doctors – a case report, *JICS* 19 (2018) 76–79.
- [5] A. Howard, V. Krishnan, G. Lane, et al., Cranial Burr holes in the emergency department: to drill or not to drill, *EMJ* 37 (2020) 151–153.
- [6] B. Barro, S. Kobner, A. Ansari, Decompression of subdural haematomas using an intraosseous needle in the emergency department: a case series, *Clin.Pract. CasesEmerg.Med.* 4 (3) (2020) 312–315.
- [7] Advanced Trauma Life Support® – Student Course Manual, 10th Edition, American College of Surgeons; Committee of Trauma, Chicago, 2018.
- [8] Advanced Life Support Manual, 8th edition, Resuscitation Council UK, 2021.
- [9] Advanced Paediatric Life Support – A Practical Approach, 6th Edition, Advanced Life Support Group, 2016.
- [10] I. Piper, A. Barnes, D. Smith, et al., The Camino intracranial pressure sensor: is it optimal technology? An internal audit with a review of current intracranial pressure monitoring technologies, *Neurosurgery* 49 (2001) 1158–1165.