

# The first case of abdominal mycotic aneurysm caused by K1 hypervirulent *Klebsiella pneumoniae* in a healthy adult

Misun Kim<sup>1</sup>, Jeong Rae Yoo<sup>1,2</sup>, Hyunjoo Oh<sup>1</sup>, Young Ree Kim<sup>3</sup>, Keun Hwa Lee<sup>4</sup>, Sang Taek Heo<sup>1,2</sup>

<sup>1</sup>Department of Internal Medicine, Jeju National University Hospital, Jeju; Departments of <sup>2</sup>Internal Medicine and <sup>3</sup>Laboratory Medicine, Jeju National University School of Medicine, Jeju; <sup>4</sup>Department of Microbiology, Hanyang University College of Medicine, Seoul, Korea

Incidence of hypervirulent *Klebsiella pneumoniae* (hvKp) infection has been steadily increasing in the Asia-Pacific rim. The characteristic of hvKp infection is its ability to cause multiple site infections and unpredictable metastatic spread in the community. We describe the first case of mycotic aneurysm caused by hvKp serotype K1 in a previously healthy man and review the literature. Of a total of 13 cases, including our case, three cases were related to hvKp. Among patients with hvKp, the level of mycotic aneurysm in most patients was the infrarenal aorta, and they underwent an aortic graft or coil embolization. All strains were susceptible to most antimicrobial agents, except ampicillin. Early detection of hvKp can help to prevent the metastatic spread of pathogens and be useful for optimal patient care and epidemiologic research.

**Key Words:** hypervirulent; infected aneurysm; *Klebsiella pneumoniae*; liver abscess; metastatic infection

The prevalence of *Klebsiella pneumoniae* colonization rate in healthy adults range from 20% to 87% in Asian countries [1-3]. In particular, hypervirulent *K. pneumoniae* (hvKp) with a hypermucoviscous phenotype has recently been increasing in the community [1,4]. The hvKp has an ability to infect healthy individuals of any age and can infect any part of the body [5]. Liver abscess in the absence of biliary tract disease is a hallmark of the clinical syndrome. These patients have pneumonia, necrotizing fasciitis, endophthalmitis, prostatic abscess, and meningitis [3,6]. In addition, they are more likely to have diabetes mellitus (DM) and are at risk of life-threatening diseases even in healthy conditions [6]. Although extrahepatic complications from bacteremic dissemination have been observed, infected aneurysms are rare. Herein, we report a case of hvKp (serotype K1) causing liver abscess, septic emboli in both lungs, renal abscess, and prostate abscess, followed by an abdominal mycotic aneurysm that was not discovered at the initial presentation time in a previously healthy man. We further review the literature on the clinical characteristics of mycotic aneurysms caused by *K. pneumoniae* reported worldwide.

## CASE REPORT

A previously healthy 50-year-old man was admitted on July 29, 2020, with a headache and

## Case Report

Received: January 1, 2021

Revised: May 7, 2021

Accepted: May 11, 2021

### Corresponding author

Sang Taek Heo

Department of Internal Medicine,  
Jeju National University School of  
Medicine, 102 Jejudaehang-ro, Jeju  
54987, Korea

Tel: +82-64-754-8151

Fax: +82-64-717-1311

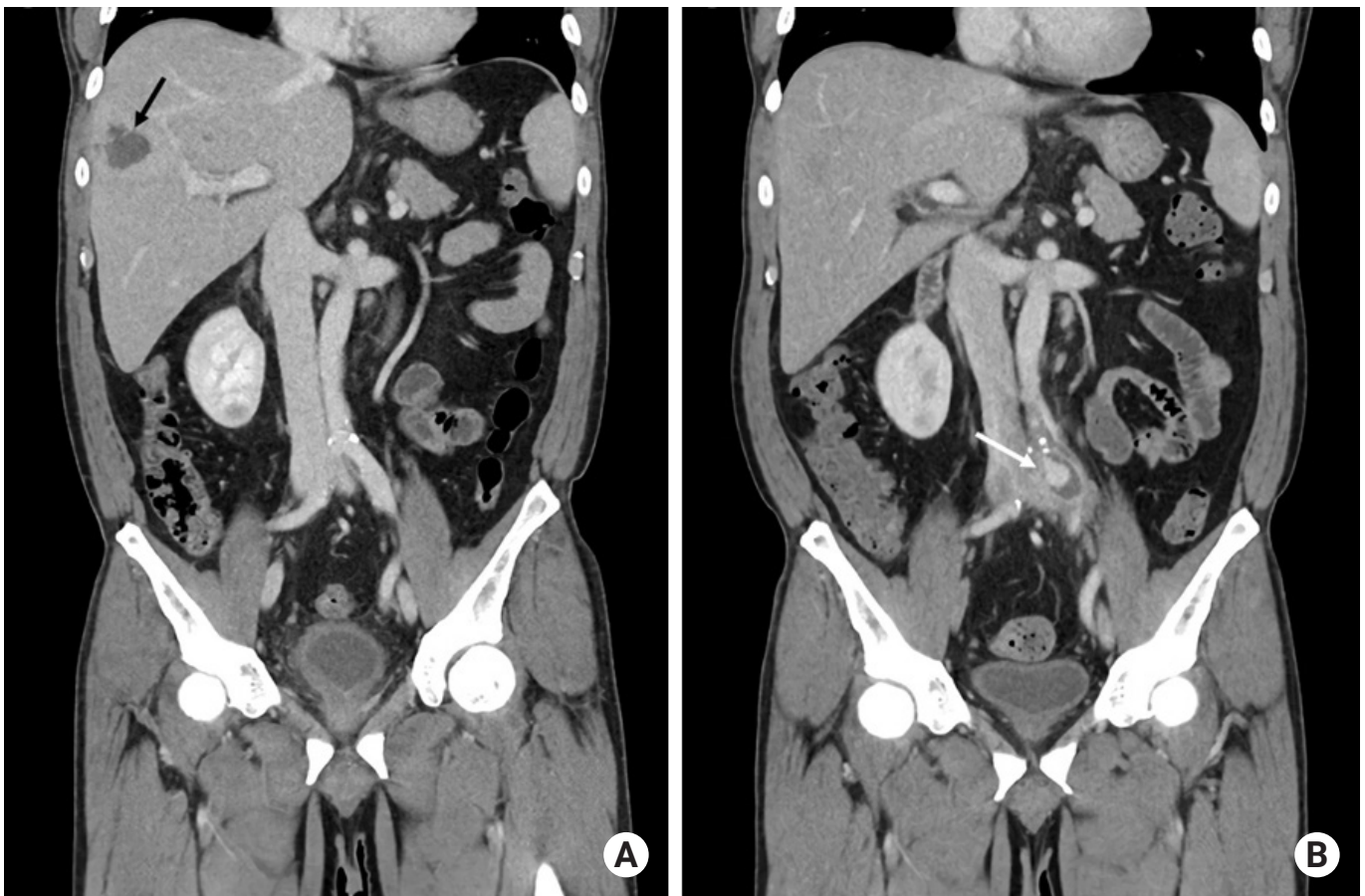E-mail: neosangtaek@naver.com

Copyright © 2021 The Korean Society of  
Critical Care Medicine

This is an Open Access article distributed  
under the terms of Creative Attributions  
Non-Commercial License ([https://  
creativecommons.org/licenses/by-nc/4.0/](https://creativecommons.org/licenses/by-nc/4.0/))  
which permits unrestricted noncommercial  
use, distribution, and reproduction in any  
medium, provided the original work is  
properly cited.

fever which had lasted for a week. His body temperature was 39.3°C, blood pressure was 106/65 mm Hg, pulse rate was 80 beats/min, and he was mentally alert. We suspected acute meningitis of the sudden and persistent severe headache with fever that has not been previously. A lumbar puncture was performed, but pleocytosis was not observed. Laboratory findings revealed a white blood cell count of 19,200/ $\mu$ l (reference range, 4,000–10,000), a C-reactive protein level of 36.1 mg/dl (reference range, 0.0–0.3), an erythrocyte sedimentation rate of 120 mm/hr (reference range, 0–20), an alkaline phosphatase level of 1,284 IU/L (reference range, 104–338), an alanine aminotransferase of 29 IU/L (reference range, 4–44), an aspartate aminotransferase of 47 IU/L (reference range, 8–38), and a serum creatinine level which was within the normal range. The multifocal abscesses in the liver (Figure 1A), lung, kidney, and prostate was seen on enhanced abdominal computed tomography (CT). Piperacillin/tazobactam was administered as an empirical antibiotic agent. Ultrasound-guided percutaneous

drainage of the liver was performed, and a yellowish fluid was drained. The patient was diagnosed with DM (glycated hemoglobin, 9.8%) on admission. *K. pneumoniae* with susceptibility to all antibiotics except ampicillin was isolated from blood and liver abscess culture (BACT/ALERT 3D system; bioMérieux, Marcy-l'Étoile, France) on August 2, 2020 (Table 1). The cultures were incubated for 24–48 hours, inoculated onto blood agar, and colonies were collected from the plates for identification using an automated system (VITEK II, bioMérieux). The antibiotic agent was changed to ciprofloxacin, which has a definite narrow spectrum on August 2, 2020. There were no abnormal findings on ophthalmological examination, brain magnetic resonance imaging, and transthoracic echocardiography. After antibiotic administration and liver abscess aspiration, bacteremia and inflammation marker were improved. However intermittent up to 38°C of fever has been continued. Although liver abscess and metastatic infections improved on follow-up CT on the 11th day of hospitaliza-



**Figure 1.** (A) Low-density lesion in the liver (black arrow) and (B) new aneurysmal dilatation with thrombosis, wall enhancement, and periarterial fatty infiltration in left common iliac artery (white arrow) are observed using enhanced abdominal computed tomography.

**Table 1.** Antibiotic susceptibility of *Klebsiella pneumoniae* isolated from blood and liver abscess

Antibiotic agent	MIC ( $\mu\text{g/ml}$ )	Interpretation
Amoxicillin plus clavulanic acid	$\leq 2$	S
Amikacin	$\leq 2$	S
Aztreonam	$\leq 1$	S
Ciprofloxacin	$\leq 0.25$	S
Ertapenem	$\leq 0.5$	S
Imipenem	$\leq 0.25$	S
Cefotaxime	$\leq 1$	S
Cefepime	$\leq 1$	S
Piperacillin plus tazobactam	$\leq 4$	S

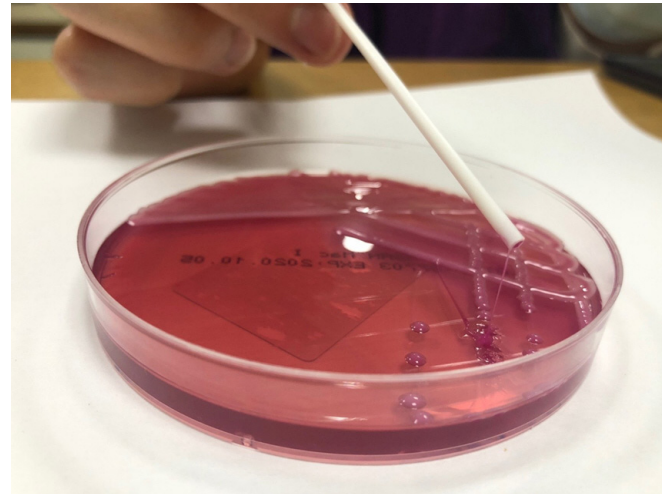
MIC: minimum inhibitory concentration; S: susceptible.

tion, a mycotic aneurysm developed in the left common iliac artery (Figure 1B). *K. pneumoniae* isolates with hypermucoviscosity phenotype were recovered from the string test of colonies obtained from the blood culture and pus from the liver abscess (Figure 2). The K1 serotype was identified by 16S rRNA gene analysis. The patient underwent left common iliac artery resection and repair with a Dacron graft performed on a 2.7 cm pseudoaneurysm in the abdominal aorta on the 15th hospital day. He was treated with a 6-week course of antibiotic treatment and recovered well.

## DISCUSSION

*K. pneumoniae* is a common pathogen that causes urinary tract infection, intra-abdominal infection, and pneumonia in the community [7]. It also causes multidrug resistance in healthcare-associated infections. In addition, the emergence of severe community onset of hvKp has been increasing in East Asia since 1980, and more recently worldwide, mainly by serotypes K1 and K2. Clonal groups 23 are associated with the highly serum-resistant K1 capsule and a number of virulence factors [4,7]. However, there are a few reports of infected aortic aneurysms caused by classical *K. pneumoniae*, and those caused by hvKP are extremely rare. Because the mortality of mycotic aneurysms remains high, and hvKp is a very rapidly progressing infectious disease, close monitoring and evaluation of the clinical condition and imaging might be needed. Surgical intervention and appropriate antibiotic treatment are indispensable for reducing mortality rates.

This is the first case of a mycotic aneurysm caused by the hvKP serotype K1. The patient was previously healthy, except for newly diagnosed DM. In addition, he showed rapidly pro-



**Figure 2.** String test is used to confirm the hypermucoviscosity of *Klebsiella pneumoniae* isolates recovered from the blood culture. A positive result was defined as the formation of a viscous rope of length  $> 5$  mm when a bacterial colony was touched with a loop on the agar plate.

gressive multifocal abscesses. Despite adequate antibiotic therapy and drainage, an additional mycotic aneurysm developed. It is likely that it is not easy to control the progress of the disease with only appropriate antibiotic treatment in the early phase of hvKP. The K1 structure might confer increased resistance to a group of hvKp in which the hypermucoviscous phenotype capsule protects the cell from external factors (complement, anti-microbial peptides). It may also interfere with the function of other surface-located proteins to form biofilms [8].

The pathophysiology of mycotic aneurysms consists of bacteremia with septic emboli and subsequent arterial wall invasion, local proliferation of adjacent infectious lesions, and pathogens lodging in pre-existing aortic aneurysms in patients with predisposing factors such as hypertension and diabetes mellitus. Mycotic aneurysms caused by gram-positive cocci were significantly more likely to occur in the suprarenal arteries. Gram-negative bacilli causing mycotic aneurysms developed in patients receiving steroid treatment and in those with DM [3]. However, although this patient was newly diagnosed with DM, he did not have any other predisposing factors. No atherosclerotic lesion was found on the resected aorta.

A PubMed review of the literature published between 1980 and August 2020 was performed using a combination of terms, including “mycotic aneurysm,” “aortitis,” and “*Klebsiella*.” A total of 12 cases in 10 articles were identified, which reported mycotic aneurysm and aortitis caused by *K. pneumoniae*.

**Table 2.** Clinical characteristics of patients with mycotic aneurysm caused by *Klebsiella pneumoniae* in worldwide

Case no.	Year	Age (yr)	Gender	Country	Medical Hx	Symptom	Level of MA	Other infection site	String test	Serotype	Genotype	Op	Outcome
1	2020	50	M	KR	DM	Fever, headache	Left common iliac artery	Liver, lung, kidney, prostate	P	K1	NA	Aortic graft	Improved
2	2011	47	M	TW	HTN	Fever, dyspnea	Aortic arch to suprarenal aorta	None	NA	NA	NA	Aortic graft	Died
3	2016	81	M	JP	None	Vision loss	Left internal iliac artery	Liver, brain, prostate	P	NA	<i>magA rmpS</i>	Coil	Improved
4	2018	63	M	KR	None	Abdominal pain	Infrarenal aorta	None	NA	NA	NA	Aortic graft	Improved
5	2008	48	M	TW	DM	Abdominal pain	Infrarenal aorta	None	NA	K5	<i>rmpA iuc</i>	Aortic graft	Improved
6	2005	70	M	JP	lymphoma	Fever	Distal aortic arch	None	NA	NA	NA	Aortic graft	Improved
7	2005	75	M	JP	DM, myositis <sup>a</sup>	Fever, back pain	Suprarenal aorta	None	NA	NA	NA	Aortic graft	Improved
8	2005	82	M	JP	DM, CVA	Fever	Distal aortic arch	None	NA	NA	NA	Aortic graft	Improved
9	1996	68	M	TW	DM	Lower back pain, fever	Suprarenal aorta	None	NA	NA	NA	Refuse <sup>b</sup>	Died
10	1996	NA	M	JP	DM	NA	Right internal iliac artery	None	NA	NA	NA	Excision and bypass	Improved
11	2004	67	M	USA	DM, CKD, CAD	abdominal pain, fever	Infrarenal aorta <sup>c</sup>	Psoas muscle	NA	NA	NA	Resection of the infected aorta	Improved
12	2005	68	F	TW	DM	NA	Thoracic and abdominal aorta	None	NA	NA	NA	Surgical intervention	NA
13	2008	69	M	KR	DM	back pain, fever	Infrarenal aorta	Endophthalmitis	NA	NA	NA	Aortic graft	Vision loss

Hx: history; MA: mycotic aneurysm; Op: operation; KR: South Korea; DM: diabetes mellitus; P: positive; NA: not applicable; TW: Taiwan; HTN: hypertension; JP: Japan; KR: Korea; CVA: cerebral vascular accident; USA: United States of America; CKD: chronic kidney disease; CAD: coronary artery disease.

<sup>a</sup>He had taken prednisolone for *rmpS* in the lower part of left lower extremity; <sup>b</sup>An emergency operation was suggested, but the family refused any surgical procedure; <sup>c</sup>He had a ruptured abdominal aortic aneurysm.

This amounts to a total of 13 cases, including the current case. Three cases were associated with hvKP (one serotype K1 in Korea in 2020 [this case], one virulent factor *magA*, *rmpS* in Japan in 2016 [9], and one serotype K5 in Taiwan in 2008 [10]). The main clinical features of these patients are shown in Table 2. The clinical presentation symptoms were not specific. All patients required imaging like computer tomography for diagnosis. They improved after antibiotic treatment and surgical treatment. Most patients were men. Two patients died. All strains were generally highly susceptible to antimicrobial agents, except for ampicillin. Antibiotic susceptibility has not changed over the last four decades worldwide. In the three hvKp cases, the patients had diabetes or received steroids; two cases had multiple abscesses including a liver abscess, and one

case was a primary mycotic aneurysm without a liver abscess. The patients' levels of mycotic aneurysm were the infrarenal aorta, and they underwent aortic graft or coil embolization.

In conclusion, to the best of our knowledge, this is the first documented report worldwide of a mycotic aneurysm with multiple disseminated abscesses, including a liver abscess caused by serotype K1 *K. pneumoniae*. HvKp causes a metastatic infectious lesion from an early phase of the clinical course. Even with proper treatment, it did not improve. In particular, vascular complications of hvKp are associated with poor prognosis, and long-term treatment is inevitable owing to the difficult surgical approach. Therefore, it would be helpful for good prognosis that hvKp is diagnosed early and managed actively through multidisciplinary treatment.

## CONFLICT OF INTEREST

No potential conflict of interest relevant to this article was reported.

## ACKNOWLEDGMENTS

This work was supported by the 2021 education, research and student guidance grant funded by Jeju National University.

## ORCID

Misun Kim	<a href="https://orcid.org/0000-0003-3771-6101">https://orcid.org/0000-0003-3771-6101</a>
Jeong Rae Yoo	<a href="https://orcid.org/0000-0002-5488-7925">https://orcid.org/0000-0002-5488-7925</a>
Hyunjoo Oh	<a href="https://orcid.org/0000-0003-4815-2743">https://orcid.org/0000-0003-4815-2743</a>
Young Ree Kim	<a href="https://orcid.org/0000-0003-2454-8815">https://orcid.org/0000-0003-2454-8815</a>
Keun Hwa Lee	<a href="https://orcid.org/0000-0002-2259-2751">https://orcid.org/0000-0002-2259-2751</a>
Sang Taek Heo	<a href="https://orcid.org/0000-0001-8947-5069">https://orcid.org/0000-0001-8947-5069</a>

## AUTHOR CONTRIBUTIONS

Conceptualization: JRY. Data curation: YRK, KHL. Formal analysis: MK. Investigation: HO, JRY. Methodology: JRY. Project administration: JRY. Software: KHL. Supervision: JRY. Validation: STH. Visualization: JRY. Writing–original draft: MK. Writing–review & editing: JRY, STH.

## REFERENCES

1. Choby JE, Howard-Anderson J, Weiss DS. Hypervirulent *Klebsiella pneumoniae*: clinical and molecular perspectives. *J Intern Med* 2020;287:283-300.
2. Harada S, Ishii Y, Saga T, Aoki K, Tateda K. Molecular epidemiology of *Klebsiella pneumoniae* K1 and K2 isolates in Japan. *Diagn Microbiol Infect Dis* 2018;91:354-9.
3. Hsu PJ, Lee CH, Lee FY, Liu JW. Clinical and microbiological characteristics of mycotic aneurysms in a medical center in southern Taiwan. *J Microbiol Immunol Infect* 2008;41:318-24.
4. Lam MM, Wyres KL, Duchêne S, Wick RR, Judd LM, Gan YH, et al. Population genomics of hypervirulent *Klebsiella pneumoniae* clonal-group 23 reveals early emergence and rapid global dissemination. *Nat Commun* 2018;9:2703.
5. Russo TA, Marr CM. Hypervirulent *Klebsiella pneumoniae*. *Clin Microbiol Rev* 2019;15;3:e00001-19.
6. Siu LK, Yeh KM, Lin JC, Fung CP, Chang FY. *Klebsiella pneumoniae* liver abscess: a new invasive syndrome. *Lancet Infect Dis* 2012;12:881-7.
7. Martin RM, Bachman MA. Colonization, infection, and the accessory genome of *Klebsiella pneumoniae*. *Front Cell Infect Microbiol* 2018;8:4.
8. Cubero M, Marti S, Domínguez MÁ, González-Díaz A, Berbel D, Ardanuy C. Hypervirulent *Klebsiella pneumoniae* serotype K1 clinical isolates form robust biofilms at the air-liquid interface. *PLoS One* 2019;14:e0222628.
9. Namikawa H, Yamada K, Fujimoto H, Oinuma KI, Tochino Y, Takemoto Y, et al. Two unusual cases of successful treatment of hypermucoviscous *Klebsiella pneumoniae* invasive syndrome. *BMC Infect Dis* 2016;16:680.
10. Chen YJ, Chen SY, Wang JT, Hsueh PR. Mycotic aneurysm caused by gas-forming serotype K5 *Klebsiella pneumoniae*. *Int J Infect Dis* 2009;13:e47-8.