

## Living with Dead Spaces: Closing Complex Posterior Midline Defects with Midline-Based Perforator Flaps

Louis de Weerd, MD, PhD\*†; Tore K. Solberg, MD, PhD†‡; Birgit Margrethe Falch, MD§; Sven Weum, MD, PhD†¶

Sir:

We read with interest the article by Datli et al.<sup>1</sup> on closure of defects with large dead spaces on the posterior trunk. The authors made a valuable contribution with their technique for closure of these defects. They stress that complete debridement and obliteration of dead space with well-vascularized tissue should be one of the primary concerns to avoid secondary complications, especially infection. Traditionally, muscle flaps have been used to close posterior trunk defects with dead spaces because their rich vascularity enhances wound healing and assists in elimination of residual infection. The pliable and bulky muscle easily obliterates dead spaces.<sup>1</sup> The authors followed the general reconstructive principles for posterior trunk defects as formulated by Ramasastry et al.,<sup>2</sup> which are:

1. Control of infection with appropriate systemic antibiotic agents
2. Local wound care
3. Extensive debridement of all devitalized tissue
4. Reestablishment or maintenance of skeletal stability
5. Preservation of neural function
6. Obliteration of dead space with well-vascularized tissue
7. Early definitive coverage of the defect to minimize infective complications.<sup>2</sup>

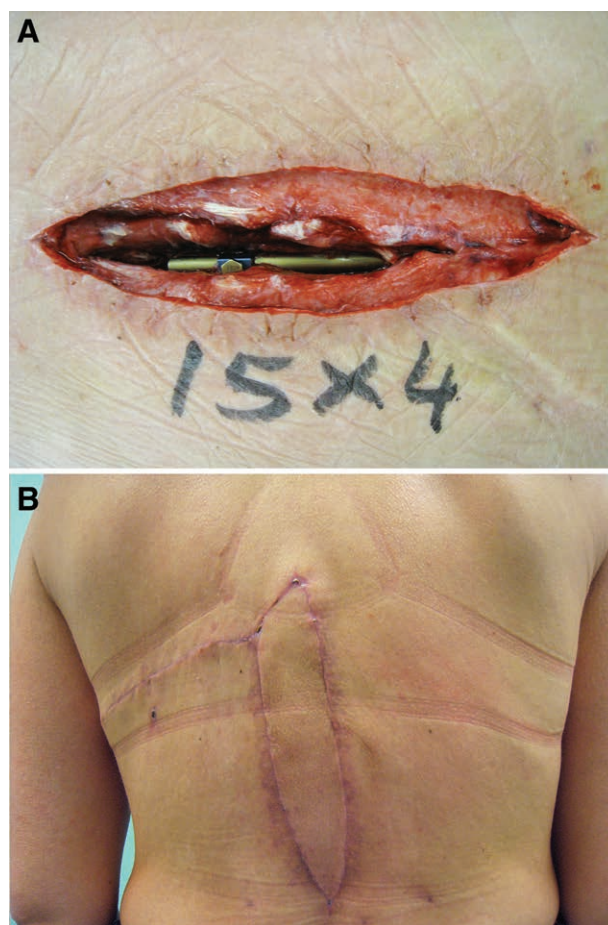
The authors used a free-style and buried deepithelialized propeller flap to obliterate dead space and obtained stable closure in their patients. We agree with the authors that successful closure of posterior trunk defects can be challenging when dead spaces are large, infected, or located in the middle of the posterior trunk. Five of their 7 patients had midback defects.

Perhaps the most challenging posterior midline defects to treat are those with infected and exposed spinal hardware. Although this was not mentioned by the authors, we reported on the successful use of the sensate medial dorsal intercostal artery perforator (MDICAP) flap for closure of

such defects.<sup>3</sup> This flap has its pivot point at the midline. A tension-free wound closure was obtained by suturing the flap into the wound defect. Spinal hardware was not removed. The mean follow-up in our series of 9 patients with 10 flaps was 65 months (range, 7–106). Only 1 patient developed an infection in the operated area that occurred 81 months postoperatively.

Unlike the authors, we did not use a free-style propeller flap. Based on our anatomic study, a perforator flap was elevated on the MDICAP.<sup>4</sup> Inclusion of the accompanying cutaneous nerve resulted in protective sensibility in the reconstructed area.

We tried to adhere to the principles formulated by Ramasastry et al.<sup>2</sup> However, it was difficult to obtain obliteration of the large dead spaces due to extensive debridement and exposed hardware. The use of a negative pressure device reduced the 3-dimensional complexity of the wound, and therewith dead space. Nevertheless, some dead space remained and could not be obliterated with the use of the MDICAP flap (Fig. 1). The long-term results of our study



**Fig. 1.** A complex midline defect with infected and exposed spinal hardware (A) was successfully closed using a sensate MDICAP flap (B) without obliteration of dead spaces.

From the \*Department of Plastic Surgery and Reconstructive Surgery, University Hospital of North Norway, Tromsø, Norway; †Department of Clinical Medicine, UiT the Arctic University of Norway, Tromsø, Norway; ‡Department of Neurosurgery, University Hospital of North Norway, Tromsø, Norway; §Department of Microbiology, University Hospital of North Norway, Tromsø, Norway; and ¶Department of Radiology, University Hospital of North Norway, Tromsø, Norway.

Supported by a grant from the publication fund of UiT The Arctic University of Norway.

Copyright © 2017 The Authors. Published by Wolters Kluwer Health, Inc. on behalf of The American Society of Plastic Surgeons. This is an open-access article distributed under the terms of the Creative Commons Attribution-Non Commercial-No Derivatives License 4.0 (CCBY-NC-ND), where it is permissible to download and share the work provided it is properly cited. The work cannot be changed in any way or used commercially without permission from the journal.

Plast Reconstr Surg Glob Open 2017;5:e1453; doi:10.1097/GOX.0000000000001453; Published online 11 August 2017.

may indicate that it is not necessary to obliterate all dead space completely to prevent infection.

**Louis de Weerd, MD, PhD**

Department of Plastic Surgery and Reconstructive Surgery  
 University Hospital of North Norway  
 9038 Tromsø  
 Norway  
 E-mail: Louis.deweerd@unn.no

**DISCLOSURE**

*The authors have no financial interest to declare in relation to the content of this article. The Article Processing Charge was paid for from the publication fund of UiT The Arctic University of Norway.*

**REFERENCES**

1. Datli A, Suh H, Kim YC, et al. Free-style deepithelialized propeller flaps: an ideal local flap to obliterate wounds with dead space. *Plast Reconstr Surg Glob Open*. 2017;5:e1249.
2. Ramasastry SS, Schlechter B, Cohen M. Reconstruction of posterior trunk defects. *Clin Plast Surg*. 1995;22:167–185.
3. de Weerd L, Solberg TK, Weum S. Closure of complex posterior midline defects after spinal surgery with sensate midline-based perforator flaps and the long-term results. *Spine (Phila Pa 1976)*. 2015;40:E1233–E1238.
4. de Weerd L, Weum S. The sensate medial dorsal intercostal artery perforator flap for closure of cervicothoracic midline defects after spinal surgery: an anatomic study and case reports. *Ann Plast Surg*. 2009;63:418–421.