

Case Report

Takotsubo Cardiomyopathy in Dextrocardia with Situs Inversus

A. Ganes  and L. Segan

Department of Cardiology, Barwon Health, Bellerine Street, Geelong, VIC 3220, Australia

Correspondence should be addressed to A. Ganes; anand.ganes@barwonhealth.org.au

Received 11 June 2020; Revised 30 July 2020; Accepted 6 August 2020; Published 20 August 2020

Academic Editor: Kathleen Ngu

Copyright © 2020 A. Ganes and L. Segan. This is an open access article distributed under the Creative Commons Attribution License, which permits unrestricted use, distribution, and reproduction in any medium, provided the original work is properly cited.

Takotsubo cardiomyopathy (TTC) is an acute reversible form of left ventricular (LV) systolic dysfunction extending beyond a coronary artery vascular territory usually due to physical or psychological stressors. Dextrocardia with situs inversus is a rare embryologic anomaly whereby the heart and aorta are mirrored on the contralateral side. We describe a case of a 93-year-old female with dextrocardia who presented with chest pain, atrial fibrillation with rapid ventricular response, and transient inferior ST elevation. Coronary angiography demonstrated an eccentric mid right coronary artery (RCA) lesion and apical ballooning consistent with concurrent takotsubo cardiomyopathy (TTC). To our knowledge, this is the first reported case of this dual pathology in a patient with dextrocardia, highlighting the procedural and diagnostic complexity in the setting of a rare anatomic variant.

1. Introduction

Takotsubo cardiomyopathy (TTC) is an acute reversible form of symmetrical left ventricular systolic dysfunction extending beyond a coronary artery vascular territory, often occurring in postmenopausal women and frequently in the context of physical or psychological stressors [1, 2]. It is a recognised acute coronary syndrome (ACS) mimic, accounting for 2 % of ACS presentations [3]. While the aetiology of this condition is incompletely understood, it is believed to be precipitated by an increase in the level of circulating plasma catecholamines [1]. Historically, the diagnosis was made during coronary angiography in the absence of obstructive coronary artery disease (OCAD); however, the coexistence of TTC and OCAD is increasingly recognised [4–7].

We present a rare case of simultaneous TTC and OCAD in a patient with situs inversus dextrocardia, reinforcing that the presence of OCAD should not preclude a diagnosis of TTC. Moreover, the coexistence of TTC and OCAD in a patient with situs inversus dextrocardia raises unique diagnostic and procedural challenges not previously described.

2. Case Description

A 93-year-old female with known situs inversus dextrocardia presented with chest pain, increased work of breathing and a productive cough for the preceding 24 hrs. She was tachypnoeic (respiratory rate of 30 breaths per minute), hypoxic (oxygen saturation of 88% on room air), and in atrial fibrillation (AF) with rapid ventricular response. She was normotensive and afebrile. She had dual heart sounds with no murmurs and coarse crepitations in right upper and lower lung fields. Her admission ECG demonstrated inferior ST-segment elevation (Figure 1) in the setting of AF with rapid ventricular response. Her ECG had hallmark features of dextrocardia (loss of praecordial R wave progression and a dominant S wave). Chest X-ray demonstrated multifocal pneumonia and a rightward-facing cardiac apex, a right-sided aortic arch, and a right-sided gastric bubble consistent with situs inversus dextrocardia (Figure 2). Laboratory investigations revealed an acute inflammatory process with elevated neutrophil count (16.3×10^9 cells/L), C-reactive protein (CRP 293 mg/L) and subsequent sputum culture detecting *Haemophilus Influenzae*. Initial Troponin I was elevated (0.74 µg/L), which incremented to 4.25 µg/L after

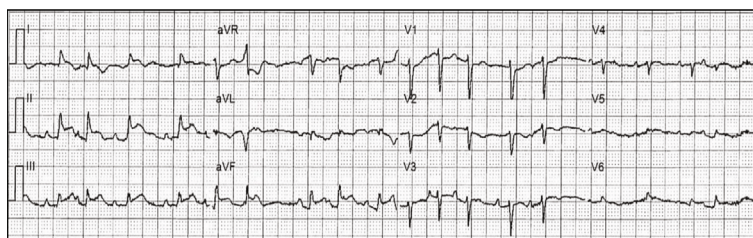


FIGURE 1: Admission standard 12-lead electrocardiogram (ECG) demonstrating inferior ST elevation, atrial fibrillation with rapid ventricular response, and features associated with dextrocardia (loss of praecordial R wave progression, dominant praecordial S wave).

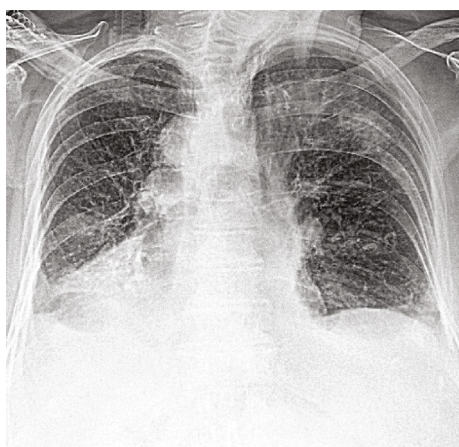


FIGURE 2: Chest X-ray demonstrating multifocal pneumonia, right-sided aortic arch, cardiac silhouette, and gastric bubble.

6 hours (normal range $<0.05 \mu\text{g/L}$). Coronary angiography demonstrated an eccentric mid-RCA stenosis (Figure 3(a)) with mild bystander disease. The RCA originated from the left coronary cusp and was engaged with a traditional Judkins Right 4.0 catheter with conventional angiographic image acquisition. The left coronary system (arising from the right coronary cusp) was engaged using a Judkins left 3.5 diagnostic catheter using traditional angiographic angulation. She spontaneously reverted to sinus rhythm at the time of angiography, with resolution of chest discomfort and ECG changes (Supplementary Figure 1). Left ventriculography demonstrated symmetrical apical ballooning with basal sparing consistent with an apical-variant TTC (Figure 3(b)). A decision was made against intervention as the RCA lesion was deemed high risk, the symptoms had resolved with recovery of sinus rhythm and the finding of TTC. Apical modified transthoracic echocardiography (TTE) confirmed severe hypokinesis of the apical segments consistent with left ventriculography. Guideline-directed pharmacotherapy was initiated including an Angiotensin-Converting Enzyme Inhibitor (ACEi) and beta-blocker. Intravenous antibiotics were administered for 48 hours and then de-escalated to oral therapy for multifocal pneumonia with interval improvement in chest X-ray and inflammatory markers (Supplementary Table 1). She was transferred to a subacute rehabilitation unit following a protracted medical admission.

3. Discussion

Situs inversus dextrocardia is a rare congenital condition whereby the internal viscera are mirrored to the contralateral side, with an estimated prevalence of $<0.0001\%$ in the general population [8, 9]. Undertaking cardiac investigations in the setting of anatomical variations is challenging, requiring careful consideration of impact on diagnostic accuracy and interpretation. Dextrocardia is identified on a standard 12-lead ECG by hallmark features including dominant S waves in praecordial leads with poor R wave progression, right axis deviation, T wave inversion in lead I and a VL and a positive QRS complex in aVR [10]. Right-sided ECG is recommended to aid in interpretation of the praecordial leads [11]. In our case, the right-sided ECG demonstrated appropriate R wave progression in the praecordial leads (Supplementary Figure 1).

ECG findings in TTC and OCAD are often indistinguishable [12] with invasive angiography being the gold standard diagnostic tool [13]. This is further complicated by marked anatomic variation, requiring careful consideration of procedural technique, equipment, and image acquisition to formulate a diagnosis. Literature regarding the approach to invasive coronary angiography *in situ* inversus dextrocardia is variable, describing a limited user experience with catheter selection, catheter engagement strategy, and modified image acquisition techniques, including mirror image fluoroscopic views and double inversion techniques [14–18]. Acquiring adequate TTE images is also extremely challenging and requires contralateral imaging with a mirror-image technique [19].

Historically, the Mayo Clinic Framework guidelines dictated that a diagnosis of TTC could not be made in the presence of OCAD [20]. Recent literature recognises an increasing incidence of dual pathology in a proportion of presentations, suggesting that these conditions are not mutually exclusive [20–23] and this enhanced understanding is now reflected in contemporary literature [23, 24].

In this case, TTC appeared to be triggered by a combination of pneumonia, tachyarrhythmia, and underlying coronary artery disease. The decision not to intervene on the RCA lesion was made on the basis of multiple physical stressors likely leading to demand ischaemia within a fixed stenosis, with complete symptom and electrographic resolution following the restoration of sinus rhythm. TTC was also likely a consequence of systemic illness and haemodynamic stress.

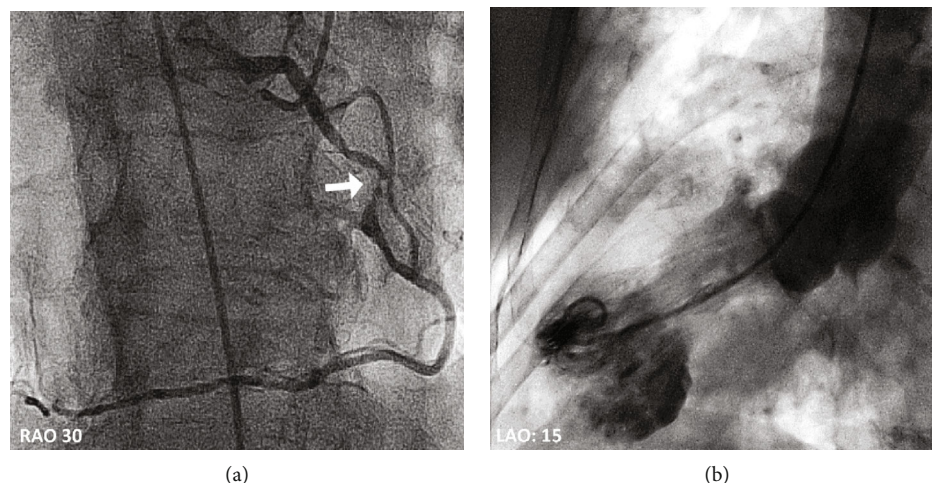


FIGURE 3: (a) Coronary angiography demonstrating RCA arising from left coronary cusp with an eccentric mid-RCA stenosis (depicted by white arrow). (b) Left ventriculography demonstrating apical ballooning in keeping with TTC.

In cases with coexistent TTC and OCAD, the diagnosis can be clarified with the use of cardiac MRI whereby TTC and myocardial ischaemia have distinctly different characteristics [25].

4. Conclusion

We describe a patient with situs inversus dextrocardia presenting with TTC and concurrent OCAD. This case highlights that the presence of coronary artery disease should not preclude a diagnosis of TTC in the appropriate context and the procedural and diagnostic complexities of recognising dual pathology in the setting of situs inversus dextrocardia.

Conflicts of Interest

The authors declare that they have no conflicts of interest.

Supplementary Materials

Supplementary Figure 1. (a) Right-sided ECG depicting inferior STE with reciprocal T wave inversion in I, a VL leads. (b) Standard ECG after resolution of atrial fibrillation and inferior ST segment elevation. Supplementary Table 1: trend of biochemistry from admission to discharge. Elevated biochemistry findings are underlined. (*Supplementary Materials*)

References

- [1] I. S. Wittstein, D. R. Thiemann, J. A. C. Lima et al., "Neurohumoral features of myocardial stunning due to sudden emotional stress," *The New England Journal of Medicine*, vol. 352, no. 6, pp. 539–548, 2005.
- [2] J. Abraham, J. O. Mudd, N. Kapur, K. Klein, H. C. Champion, and I. S. Wittstein, "Stress cardiomyopathy after intravenous administration of catecholamines and beta-receptor agonists," *Journal of the American College of Cardiology*, vol. 53, no. 15, pp. 1320–1325, 2009.
- [3] K. Komamura, M. Fukui, T. Iwasaku, S. Hirofumi, and T. Masuyama, "Takotsubo cardiomyopathy: pathophysiology, diagnosis and treatment," *World Journal of Cardiology*, vol. 6, no. 7, pp. 602–609, 2014.
- [4] D. Haghi, T. Papavassiliou, K. Hamm, J. J. Kaden, M. Borggrefe, and T. Suselbeck, "Coronary artery disease in takotsubo cardiomyopathy," *Circulation Journal*, vol. 71, no. 7, pp. 1092–1094, 2007.
- [5] C. Henriquez, R. Landau, N. Sabharwal et al., "Unusual Sequence of Events in a Case of Takotsubo Syndrome," *Case Reports in Cardiology*, vol. 2018, Article ID 5498052, 3 pages, 2018.
- [6] N. Mencer, L. T. Justice, W. Black, and K. Litton, "A Rare Case of Takotsubo Syndrome and Acute Coronary Syndrome of the Right Coronary Artery," *Case Reports in Cardiology*, vol. 2019, Article ID 9128273, 4 pages, 2019.
- [7] S. W. Sharkey, A. Kalra, T. D. Henry et al., "Coexistence of acute takotsubo syndrome and acute coronary syndrome," *Catheterization & Cardiovascular Interventions*, 2019.
- [8] G. Supriya, S. Saritha, and S. Madan, "Situs inversus totalis—a case report," *IOSR Journal of Applied Physics*, vol. 3, no. 6, pp. 2278–4861, 2013.
- [9] C. M. Bohun, J. E. Potts, B. M. Casey, and G. G. S. Sandor, "A population-based study of cardiac malformations and outcomes associated with dextrocardia," *American Journal of Cardiology*, vol. 100, no. 2, pp. 305–309, 2007.
- [10] T. Tanawuttiwat, S. Vasaiwala, and M. Dia, "Mirror Mirror," *The American Journal of Medicine*, vol. 123, no. 1, pp. 34–36, 2010.
- [11] P. Kligfield, L. S. Gettes, J. J. Bailey et al., "Recommendations for the standardization and interpretation of the electrocardiogram: part I: the electrocardiogram and its technology a scientific statement from the American Heart Association Electrocardiography and Arrhythmias Committee, Council on Clinical Cardiology; the American College of Cardiology Foundation; and the Heart Rhythm Society endorsed by the International Society for Computerized Electrocardiology," *Journal of the American College of Cardiology*, vol. 49, no. 10, pp. 1109–1127, 2007.

- [12] J. Namgung, "Electrocardiographic findings in takotsubo cardiomyopathy: ECG evolution and its difference from the ECG of acute coronary syndrome," *Clinical Medicine Insights: Cardiology*, vol. 8, pp. 29–34, 2014.
- [13] J.-R. Ghadri, I. S. Wittstein, A. Prasad et al., "International expert consensus document on Takotsubo syndrome (part II): diagnostic workup, outcome, and management," *European Heart Journal*, vol. 39, no. 22, pp. 2047–2062, 2018.
- [14] H.-S. Lo, M.-L. Chen, P.-C. Chou, and H.-C. Chiou, "Successful percutaneous coronary intervention in a patient with dextrocardia and situs inversus," *Acta Cardiologica Sinica*, vol. 20, no. 3, pp. 191–196, 2004.
- [15] N. Kakouros, S. J. Patel, S. Redwood, and B. S. Wasan, "Triple-vessel percutaneous coronary revascularization in situs inversus dextrocardia," *Cardiology Research and Practice*, vol. 2010, Article ID 606327, 4 pages, 2010.
- [16] P. K. Goel and N. Moorthy, "Trans-radial primary percutaneous coronary intervention in dextrocardia using double inversion technique," *Journal of Cardiology Cases*, vol. 8, no. 1, pp. e31–e33, 2013.
- [17] G. J. Sinner, B. George, and A. W. Messerli, "Transradial approach to coronary angiography and percutaneous intervention in patients with dextrocardia," *The Journal of Invasive Cardiology*, vol. 31, no. 5, pp. E83–E88, 2019.
- [18] P. K. Goel, "Double-inversion technique for coronary angiography viewing in dextrocardia," *Catheterization and Cardiovascular Interventions*, vol. 66, no. 2, pp. 281–285, 2005.
- [19] Y. Li, R. Liu, and X. Zhang, "Dextrocardia: why significant left-axis deviation?," *Circulation*, vol. 136, no. 17, pp. 1662–1664, 2017.
- [20] K. A. Bybee, T. Kara, A. Prasad et al., "Systematic review: transient left ventricular apical ballooning: a syndrome that mimics ST-segment elevation myocardial infarction," *Annals of Internal Medicine*, vol. 141, no. 11, pp. 858–865, 2004.
- [21] C. E. Alfonso, "Takotsubo cardiomyopathy and coronary artery disease: a meaningful coincidence?," *Journal of the American Heart Association*, vol. 5, no. 12, article e005131, 2016.
- [22] J. E. Madias, "Why the current diagnostic criteria of Takotsubo syndrome are outmoded: A proposal for new criteria," *International Journal of Cardiology*, vol. 174, no. 3, pp. 468–470, 2014.
- [23] A. Prasad, A. Lerman, and C. S. Rihal, "Apical ballooning syndrome (Tako-Tsubo or stress cardiomyopathy): a mimic of acute myocardial infarction," *American Heart Journal*, vol. 155, no. 3, pp. 408–417, 2008.
- [24] J.-R. Ghadri, I. S. Wittstein, A. Prasad et al., "International Expert Consensus Document on Takotsubo Syndrome (Part I): Clinical Characteristics, Diagnostic Criteria, and Pathophysiology," *European Heart Journal*, vol. 39, no. 22, pp. 2032–2046, 2018.
- [25] I. Eitel, F. von Knobelsdorff-Brenkenhoff, P. Bernhardt et al., "Clinical characteristics and cardiovascular magnetic resonance findings in stress (takotsubo) cardiomyopathy," *Journal of the American Medical Association*, vol. 306, no. 3, pp. 277–286, 2011.