

Successful Microsurgical Replantation of Amputated Penis: A Case Report and Review of Literature

Mohammad-Reza Akhoondinasab¹, Hamid-Reza Farahmand², Afshin Zahedi², Amir Saraee¹

1. Department of Plastic and Reconstructive Surgery, Faculty of Medicine, Iran University of Medical Sciences, Tehran, Iran
2. Faculty of Medicine, Iran University of Medical Sciences, Tehran, Iran

ABSTRACT

This study aims to explain microscopic replantation in a rare case of a wholly amputated penis after prolonged ischemia. A 36-year-old patient underwent microscopic replantation of the penis after 9 hours. The penis was completely amputated due to self-mutilation. Microvascular replantation was performed after pre-operative preparation. On the second day after surgery, congestion was observed in the penis, and three sessions of leech therapy were conducted each time the leeches were placed for 30 minutes and then detached by themselves. The patient was referred to a psychiatrist to continue treatment after discharge from the hospital. Penile amputation is a rare situation and has different causes. There are various treatments to repair the amputated penis, which are both microvascular and microvascular. The microsurgery methods have shown the best results. In the present case, due to microsurgical artery repair and the early start of leech therapy, there was limited and predictable necrosis in the area of the penoscrotal junction flap, which underwent debridement and skin graft. Complete amputation of the penis is a rare phenomenon. Efforts should be made to perform the replantation surgery as soon as possible. The venous outflow is an essential factor in the success of penile re-implantation, and completely restored vascular and sensory function in this case. Early initiation of psychological care to control underlying disease leads to further cooperation of the patient to handle complications and avoid the recurrence of self-injury.

KEYWORDS

Penile microsurgical replantation; Penile amputation; Penile self-mutilation

Please cite this paper as:

Akhoondinasab MR., Farahmand HR., Zahedi A., Saraee A. Successful Microsurgical Replantation of Amputated Penis: A Case Report and Review of Literature. *World J Plast Surg.* 2023;12(3):18-23.

doi: 10.61186/wjps.12.3.18

*Corresponding Author:

Amir Saraee, M.D

Fatima Plastic and Reconstructive Surgery Hospital

Tehran, Tehran, Iran

Email: dr.a.saraee@gmail.com

Received: 2023.05.06

Accepted: 2023.10.08

INTRODUCTION

Penile amputation trauma is a rare emergency and has various causes, including self-mutilation secondary to psychosis, domestic violence, burns or industrial accidents, and injuries inflicted by improper circumcision in men. This trauma can result in complications such as urination disorders, erectile dysfunction, and sensory problems^{1,2}.

The treatment involves maintaining the function and sensation of the penis as well as the capacity of urination³. Several successful penile transplantation cases have been reported, and the first successful penile

transplant was performed by Cohen et al. in the late 1970s⁴. Several successful cases also have been written using the microvascular method^{2, 5-7}. In this case, the amputated penis was replanted by microsurgery after 9 hours of ischemia.

CASE REPORT

A 36-year-old man was referred to this center due to penis amputation from the penoscrotal junction as a result of self-mutilation. In the previous hospital, a Foley catheter was placed in the proximal part of the urethra the bleeding vessels were ligated skin closed over the proximal part of amputation as well as compressive dressing. The amputated part was received in a plastic bag with ice. The patient was a smoker and a user of amphetamine. After beginning resuscitation, the amputated part was undergone exploration. The detected structures included the urethra, corpus carvenosum and spongiosum, dorsal veins (superficial and deep), two dorsal arteries, and dorsal nerves. The patient was transferred to the

operating room after obtaining informed consent. Under general anesthesia, the proximal stump was explored, and bleeding control was performed with a Foley catheter as a tourniquet. All the primary surgical sutures were opened. The corpus cavernosum and corpus spongiosum were cut in two levels, so the edges were freshened to remove any damaged tissue (Fig. 1). Two dorsal arteries, as well as superficial and deep dorsal veins of the proximal stump were suitable for anastomosis. Artery and vein control was performed with a microvascular clamp; then, the catheter passed through the urethra from the distal to the proximal urethra. The urethra was repaired with 5-0 chromic sutures in a simple interrupted suture over the Foley catheter. The corpus spongiosum was repaired by 4-0 PDS continuous running, and waterproof closure of the corpus spongiosum was performed with 4-0 PDS. The severely damaged deep artery was not suitable for anastomosis. The dorsal deep and superficial veins and dorsal arteries were washed with heparinized saline and repaired under microscope magnification using Prolene 10-0 (Fig. 2). The amputated penis was

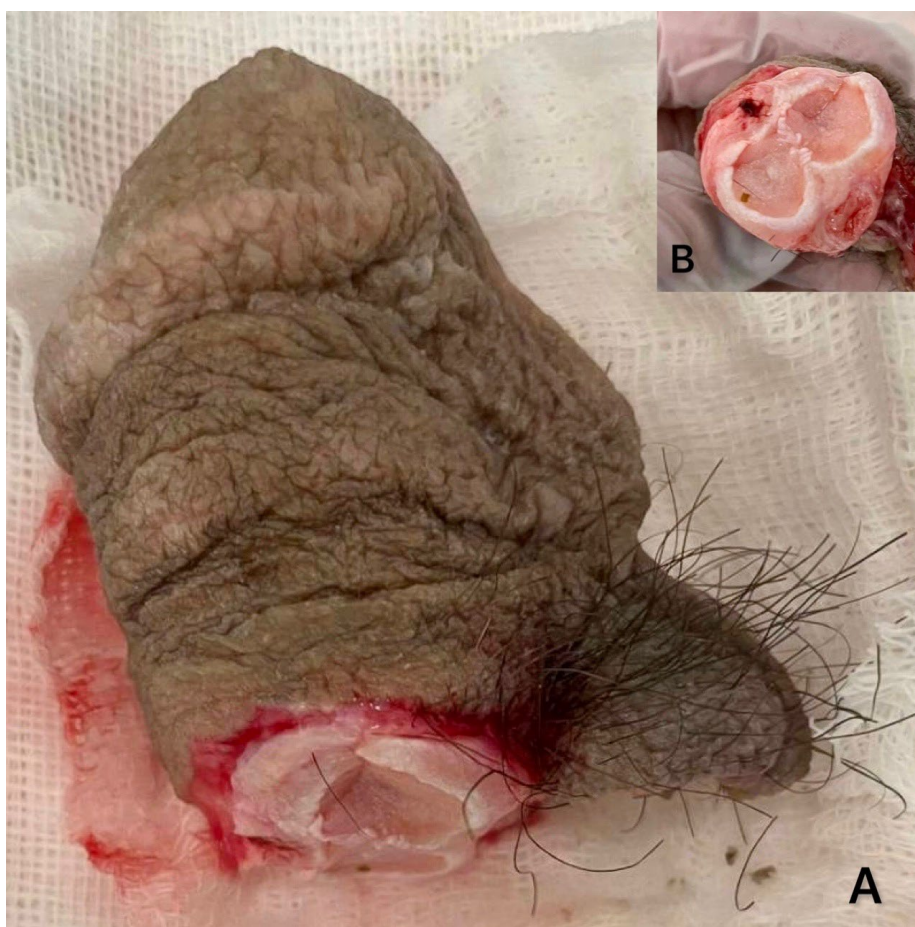


Figure 1: Amputated distal part gross view (A), cross sectional view (B)

immediately filled with blood (Figure 3). The Dartos layer was repaired with Chromic 5-0 and the dorsal nerves were repaired using 10-0 Prolene. Skin closure was also performed with Chromic 5-0 at dorsal and penoscrotal. The penis was positioned vertically by securing the Foley catheter to the skin of the lower abdomen with a silk 2-0 suture, and a light dressing was applied.

Post-operatively, the patient received three units of packed red blood cells and in order to control the pain narcotics medicines were given. Anticoagulant (enoxaparin 40 mg subcutaneous daily) and antibiotic therapy (ceftriaxone 1 gr/ IV /BD) started after the operation, the patient underwent psychological consultation and antipsychotic medication was prescribed for him.

After 24 hours of monitoring, penile congestion was observed, and three sessions of leech therapy performed at intervals every 4 hours. Congestion and edema resolved after two days. Necrosis of the penoscrotal junction skin was debrided on post-operative day 12. The wound was cleaned and dressed until good granulation was achieved. The penoscrotal defect area was covered by a 12 cm² full-thickness skin graft.

The patient was monitored by telemedicine every 2 or three days for a month. After ten months, the patient had complete sensation, erection, and normal urination and was satisfied with the outcome of operation.

Informed consent was obtained from the patient to publish his photos and information. The local Ethics Committee approved the study.

DISCUSSION

Penile amputation is a rare situation and has a different causes, including self-mutilation, vehicle accidents, child abuse, animal bites, gunshot wounds, or correction of severe genital abnormalities⁸⁻¹². The case presented above had used methamphetamine. Various studies have reported complications such as disorders in decision-making, attention control, and working memory in such a person that cause changes in psychomotor performance¹³. In a study conducted by McFaul et al., the side effects of using this drug was reported as self-harm, unintentional injuries, and poisoning¹⁴. It was found that the available substance and the dosage of this drug are effective in genital self-mutilation¹⁵.

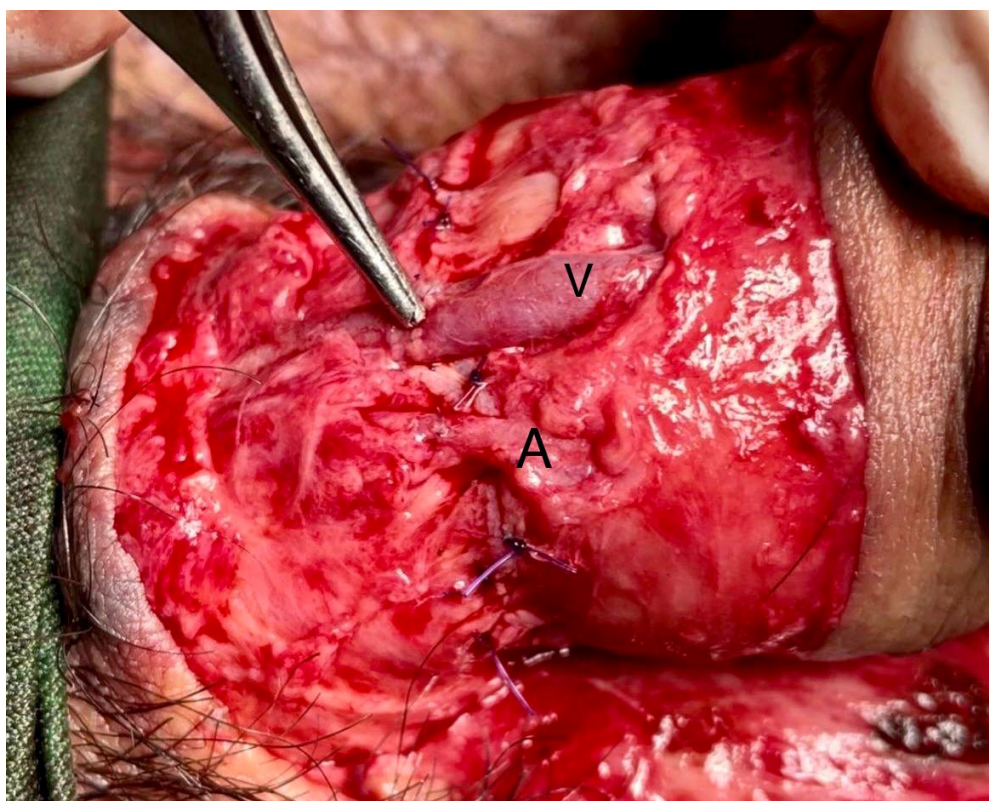


Figure 2: Microvascular anastomosis of the artery (A) and vein (V)

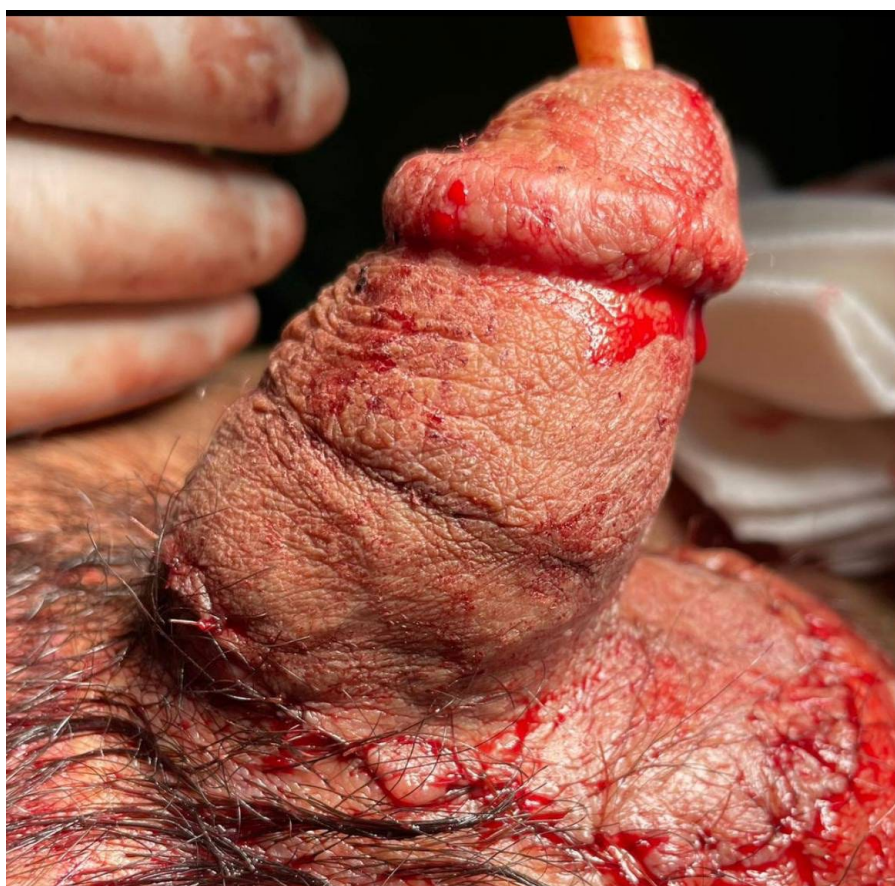


Figure 3: Just after penis re-implantation

There are various types of treatments to repair the amputated penis, which are both microvascular and macrovascular. The microsurgery methods have shown the best results¹⁶. Erich et al. first performed penile replantation by macrosurgery in 1929 and reported at least 30 successful cases of this method by 1970^{17, 18}. In 1970, Cohen et al. successfully re-implanted the penis for the first time by microsurgery, after which this method was developed and used by a large number of surgeons¹⁹. The most difficult issue in the repair of this organ is the reconstruction of vessels, and among the arteries, the dorsal artery is the most important because it is highly effective in perfusion, and failure to repair it probably leads to distal necrosis^{19, 20}. In this study, microsurgery was chosen because there was a good dorsal artery in the amputated penis, as well as a better prognosis for this method.

Skin necrosis is the most common complication after penile re-implantation, which has been reported in almost half of the cases. Its potential causes could include ischemic time, postoperative edema, and congestion, but there is no acceptable statistical data

to support these results²¹. In various case studies, this complication was resolved by debridement and re-grafting²².

In the present case, due to microsurgical artery repair and the early start of leech therapy, there were limited and predictable necrosis in the area of the penoscrotal junction flap, which underwent debridement and skin graft. Three months after the initial surgery, no tissue necrosis was observed. It seems that early intervention for the treatment of edema and congestion has been effective in reducing skin necrosis.

The main goals in re-implantation of the penis are to restore the direct flow of urine, as well as correcting the impotence and giving a satisfactory aesthetic appearance for patients²³⁻²⁵. In this patient, about three weeks after the surgery, the urinary catheter was removed after Retro Urethrogram results showed complete recovery without stricture or emptying disorder. Also, feeling the sense of the penile and erectile capacity back in our patient after ten months. Limited sensory loss was in the penoscrotal junction, which may have been due to skin necrosis and FTSG in the mentioned area.

CONCLUSION

The venous outflow is an essential factor in the success of penile reimplantation, and we were able to completely restore vascular and sensory function in this case. This case is one of the few penile reimplantation cases that have been successfully performed in Iran after a prolonged ischemia period (9 hours). Early psychological care after surgery to control the underlying disease leads to cooperation of the patient, control of the possible complications and avoids the repetition of these cases (self-harm).

ACKNOWLEDGMENTS

There were no financial sources.

CONFLICT OF INTEREST

The authors declare that there is no conflict of interests.

REFERENCES

1. Facio Jr FN, Spessoto LC, Arruda P, Paiva CS, Arruda JG, Facio MF. Penile replantation after five hours of warm ischemia. *Urol Case Rep* 2015;**3**(3):77-9.
2. Li G-z, He F, Huang G-l, Man L-b, Liu K, Shen Y-m. Penile replantation: report of two cases and review of the literature. *Chin J Traumatol* 2013;**16**(01):54-7.
3. Salem H, Mostafa T. Primary anastomosis of the traumatically amputated penis. *Andrologia* 2009;**41**(4):264-7.
4. Cohen Be, May Jr Jw, Daly Js, Hugh H Young I. Successful clinical replantation of an amputated penis by microneurovascular repair: Case report. *Plast Reconstr Surg* 1977;**59**(2):276-80.
5. Henriksson T-G, Hahne B, Hakelius L, Lantto S, Norlen B. Microsurgical replantation of an amputated penis. *Scand J Urol Nephrol* 1980;**14**(1):111-4.
6. Liu X-D, Li Y-F, Wang Q, Zhang Y, Luo Y, Zhou B, et al. microscopic replantation of completely amputated penis and testes: a case report and literature review. *Int Urol Nephrol* 2020;**52**(7):1271-7.
7. Riyach O, El Majdoub A, Tazi MF, El Ammari JE, El Fassi MJ, Khallouk A, et al. Successful replantation of an amputated penis: a case report and review of the literature. *J Med Case Rep* 2014;**8**(1):1-3.
8. Amukele SA, Lee GW, Stock JA, Hanna MK. 20-year experience with iatrogenic penile injury. *J Urol* 2003;**170**(4 Part 2):1691-4.
9. Chang AJ, Brandes SB. Advances in diagnosis and management of genital injuries. *Urol Clin North Am* 2013;**40**(3):427-38.
10. Furr J, Culkin D. Injury to the male external genitalia: a comprehensive review. *Int Urol Nephrol* 2017;**49**(4):553-61.
11. Gomes CM, Ribeiro-Filho L, Giron AM, Mitre AI, Figueira ER, Arap S. Genital trauma due to animal bites. *J Urol* 2001;**165**(1):80-3.
12. Virasoro R, Tonkin JB, McCammon KA, Jordan GH. Penile amputation: cosmetic and functional results. *Sex Med Rev* 2015;**3**(3):214-22.
13. Mizoguchi H, Yamada K. Methamphetamine use causes cognitive impairment and altered decision-making. *Neurochem Int* 2019; **124**:106-13.
14. McFaull SR, Champagne A, Thompson W, Bang F. Injuries and poisonings associated with methamphetamine use: sentinel surveillance, the electronic Canadian Hospitals Injury Reporting and Prevention Program (eCHIRPP), 2011-2019. *Health Promot Chronic Dis Prev Can* 2020;**40**(4):126-9.
15. Israel JA, Lee K. Amphetamine usage and genital self-mutilation. *Addiction* 2002;**97**(9):1215-8.
16. Djordjevic ML, Bizic M, Stojanovic B, Joksic I, Bumbasirevic UV, Ducic S, et al. Outcomes and special techniques for treatment of penile amputation injury. *Injury* 2019; **50**:S131-S6.
17. Babaei AR, Safarinejad MR. Penile replantation, science or myth? A systematic review. *Urol J* 2007 Spring;**4**(2):62-5. PMID: 17701923.
18. Volkmer B, Maier S. Successful penile replantation following autoamputation: twice! *Int J Impot Res* 2002;**14**(3):197-8.
19. Morrison SD, Shakir A, Vyas KS, Remington AC, Mogni B, Wilson SC, et al. Penile replantation: a retrospective analysis of outcomes and complications. *J Reconstr Microsurg* 2017;**33**(04):227-32.
20. Tuffaha SH, Sacks JM, Shores JT, Brandacher G, Lee WA, Cooney DS, et al. Using the dorsal, cavernosal, and external pudendal arteries for penile transplantation: technical considerations and perfusion territories. *Plast Reconstr Surg* 2014;**134**(1):111e-9e.
21. Fujiki M, Ozaki M, Kai A, Takushima A, Harii K. Successful second microsurgical replantation for amputated penis. *Plast Reconstr Surg Glob Open* 2017;**5**(9): e1512.

22. De M, Dawar R. The challenges and complications of re-implantation of the penis following amputation. *Ghana Med J* 2022;**56**(1):49-52.
23. Mawuko-Gadosseh Y, Mayele M, Gallouo M, Graioud M, Dakir M, Debbagh A, et al. Automutilation des organes génitaux externes chez l'homme. *Prog Urol* 2020;**30**(3):172-8.
24. Shappell HW, Kislevitz M, Reddy G, Amirlak B, Morey A, Stone JA. Successful replantation of amputated penis with adjuvant hyperbaric oxygen therapy. *Shappell HW, Kislevitz M, Reddy G, Amirlak B, Morey A, Stone JA. Successful replantation of amputated penis with adjuvant hyperbaric oxygen therapy. Undersea Hyperb Med* 2019; **46**:695-9.
25. Wang P, Luo Y, Li Y-F, Zhang Y, Bi G, Jin D-C, et al. Microscopic Replantation of Complete Penile Amputation with Video Demonstration. *Urology* 2022; **164**:e303-e306.