

Effect of an intensive conservative therapy with daily teriparatide administration and rehabilitation for osteoporotic delayed vertebral collapse and paralysis

Norimitsu Wakao, MD, PhD^{a,b,*}, Mikinobu Takeuchi, MD, PhD^a, Daniel K. Riew, MD^c, Atsuhiko Hirasawa, MD, PhD^a, Shiro Imagama, MD, PhD^d, Katsuhisa Kawanami, MD, PhD^b, Toshihiro Matsuo, MD, PhD^b, Kenta Murotani, PhD^e, Masataka Deie, MD, PhD^b

Abstract

Although patients with osteoporotic delayed vertebral collapse (ODVC) have frequently been treated surgically, the efficacy and limitation of conservative treatment for it have not yet been reported. The purpose of this study was to investigate the effectiveness and limitation of further intensive conservative treatment for patients with ODVC.

Patients treated for ODVC from 2011 to 2014 with a follow-up period of more than 1 year were eligible. The fundamental treatment strategy consisted of surgical treatment following intensive conservative treatment with daily teriparatide and rehabilitation for 3 months. We conducted a surgical treatment for patients who could not keep standing position by themselves because of prolonged leg paralysis or intolerable back pain. We performed a logistic regression model in which surgical treatment was set as an objective variable, and other related factors including sex, age, the level of affected vertebrae, the quality of paralysis, changing rate (δ) of spinal canal encroachment, local kyphotic angle, mobility of collapsed vertebrae, EuroQol questionnaires (EQ5D), numerical rating scale (NRS), and Frankel grade as explanatory variables. We also plotted receiver operating curves (ROCs) to investigate the cutoff values of parameters at the baseline.

Thirty patients (6 males and 24 females, mean age 76.7 years) were enrolled. Eventually 12 out of 30 patients avoided surgical treatment because their symptoms were improved. Logistic regression showed that δ of local kyphotic angle (odds ratio: 1.072), $P=.01$, mobility of collapsed vertebrae (1.063, 0.01), EQ5D (0.98, 0.04), and NRS (1.113, 0.01) were significantly correlated with the need for surgical treatments. Among the factors at baseline, only the mobility of collapsed vertebrae showed a significant value of area under a curve (AUC=0.727, $P=.008$).

The results that 40% of patients with ODVC did not need further surgical treatment after the intensive conservative treatment was of great significance. Patients with greater mobility of collapsed vertebrae might be treated surgically as quickly as possible.

Abbreviations: AUC = area under curve, EQ5D = EuroQol questionnaires, MRI = magnetic resonance imaging, NRS = numerical rating scale, ODVC = osteoporotic delayed vertebral collapse, OR = odds ratio, ROC = receiver operating curves.

Keywords: conservative therapy, daily teriparatide, osteoporotic delayed vertebral collapse, rehabilitation, risk factor, surgical treatment

Editor: Eric Bush.

The manuscript submitted does not contain information about medical device(s)/drug(s).

This study was supported by JSPS KAKENHI Grant Number 15K10423 (2015).

The authors have no conflicts of interest to disclose.

^a Department of Spine Center, ^b Department of Orthopedic Surgery, Clinical Research Center, Aichi Medical University, Yazako, Nagakute-city, Aichi-pref, Japan, ^c Department of Orthopedic Surgery, Columbia University, New York, NY, ^d Department of Orthopedic Surgery, Nagoya University, Nagoya, ^e Division of Biostatistics, Clinical Research Center, Aichi Medical University, Yazako, Nagakute-city, Aichi-pref, Japan.

* Correspondence: Norimitsu Wakao, Department of Spine Center, Aichi Medical University, Nagakute 21, Aichi 480-1195, Japan (e-mail: nwakao2009@yahoo.co.jp).

Copyright © 2018 the Author(s). Published by Wolters Kluwer Health, Inc. This is an open access article distributed under the terms of the Creative Commons Attribution-Non Commercial License 4.0 (CCBY-NC), where it is permissible to download, share, remix, transform, and buildup the work provided it is properly cited. The work cannot be used commercially without permission from the journal.

Medicine (2018) 97:23(e10906)

Received: 26 December 2017 / Accepted: 9 May 2018

<http://dx.doi.org/10.1097/MD.0000000000010906>

1. Introduction

The incidence of osteoporotic thoracolumbar compression fracture increases with age.^[1-5] Although most cases can be treated conservatively with some braces or cast, delayed post-traumatic vertebral collapse and paralysis sometimes occur. The typical sign of an osteoporotic delayed vertebral collapse (ODVC) is an intervertebral cleft, which is a sign of avascular necrosis of the vertebral body. As a result of such a collapse, some patients experience neurologic complications and/or severe low back pain due to instability or aggravation of the local kyphosis.^[6-8] A substantial number of cases of ODVC have been reported in the literature, and various surgical procedures have been proposed to treat them.^[9-12] However, there are only a few reports concerning the conservative treatment of patients with ODVC.

Recombinant human parathyroid hormone (PTH), which has potent anabolic effects on bone remodeling,^[13] has recently been approved as a treatment for severe osteoporosis in the world. We have proposed a conservative treatment involving the daily administration of rhPTH, as well as preoperative physical rehabilitation, the goal being to strengthen the bone. We have

encountered some patients who no longer required surgical treatment because of improvement in their paralysis and back pain after 3-months of conservative treatment.

The purpose of the present study was to investigate the effectiveness and limitations of intensive conservative treatment for patients with ODVC.

2. Materials and methods

2.1. Patient population and study design

The protocol for this study was approved by the institutional review board of Aichi Medical University (2015-H243). Patients treated for ODVC from January 2011 to April 2014 with a follow-up period of more than 1 year were eligible. The definition of ODVC was established to be patients who had already been treated conservatively for more than 3 months after the initial diagnosis with a new osteoporotic vertebral fracture based on magnetic resonance imaging (MRI), and paralysis of the leg or intolerable back pain associated with the intervertebral cleft that remained.^[9,12] Exclusion criteria included patients who desired early surgical treatment, patients with cognitive impairment, patients with an observational period of less than 1 year, and patients with a history of a malignant tumor.

2.2. Study interventions

The fundamental treatment strategy we are reporting on consists of surgical treatment following intensive conservative treatment with daily rhPTH administration, and rehabilitation for 3 months in a nursing home or hospital. During this period, bed rest level was determined based on the existence of paralysis; patients whose paralysis had disappeared participated in a 40 minutes ambulation exercise twice a day, 6 days a week, while those for whom paralysis remained underwent 40 minutes rehabilitation with bed rest twice a day, 6 days a week. All patients used a hard corset for external fixation through the 3 months conservative treatment period. We conducted a surgical treatment for patients who could not keep standing position by themselves because of prolonged motor leg paralysis worse than D grade in Frankel grade, or prolonged back pain worse than 5 in NRS.

2.3. Study measures

The outcome measures utilized were: EuroQol questionnaires (EQ5D) (adjusted values can range from 0 to 1.0)^[14]; numerical rating scale (NRS) on which scores can range from 0 to 10^[15]; and 3Frankel grade (the degree of neurologic deficits on which values can range from A to E). Those measurements were evaluated at baseline, 3 months, and 1 year after enrollment. The authors evaluated the degree of paralysis (spinal cord or cauda equina) based on MRI, as well as the neurologic function at baseline. Radiologic evaluations assessed were as follows:

The level of the affected vertebra based on a whole spine lateral-view radiograph.

Spinal canal encroachment due to retro-pulsed bony fragments viewed on computed tomography (CT) scans. The extent of bony fragment encroachment in the spinal canal was calculated as the ratio (percentage) of the anteroposterior diameter of bony fragments to the anteroposterior diameter of the spinal canal.

Local kyphotic angle on lateral view radiograph in the lying position measured between the upper surface of the vertebral body above the collapse and the lower surface of the vertebral body below.

The mobility of collapsed vertebrae measured by lying-flexion and extension positions. In each position, mobility was defined as the difference between the upper surface of the vertebral body above the collapse and the lower surface of the vertebral body below the collapse.

The evaluations (2) to (4) were obtained at baseline and at 3 and 12 months after conservative treatment.

2.4. Statistical analysis

Baseline characteristics of the surgically treated group (S) and non-surgically treated group (NS) were compared using an unpaired *t* test and a Mann–Whitney *U* test for continuous variables, and a chi-square test for categorical variables. We performed a logistic regression model in which surgical treatment was set as an objective variable, and other relating factors set as explanatory variables, including sex, age, level of affected vertebrae, degree of paralysis, changing rate (δ) of spinal canal encroachment, local kyphotic angle, mobility of collapsed vertebrae, EQ5D, NRS, and Frankel grade. The authors also plotted receiver operating curves (ROCs) to investigate the cutoff values of each parameter at baseline for predicting the necessity of surgical treatment. Calculations were made with SAS software version 9.2 (SAS Institute, Cary, NC). A *P* value of $<.05$ was considered significant.

3. Results

3.1. Index patient population

Overall, 36 patients with ODVC were enrolled in this study. According to the study criteria, 30 patients were eligible and 6 patients were excluded (1 had a desire for early surgical treatment, 2 had cognitive impairment, and 3 had a history of a malignant tumor). The mean age was 76.7 years, with more female than male patients (Fig. 1). All subjects were followed for at least 1 year; there were no deaths. Among 30 eligible subjects, 23 experienced a fall resulting in a spinal compression fracture in the past, but the other 7 did not. The mean period from injury to hospital admission in those 23 subjects was 4 months. Ultimately, 12 out of 30 patients did not need surgical treatments (NS group), and the other 18 patients underwent surgical treatment because

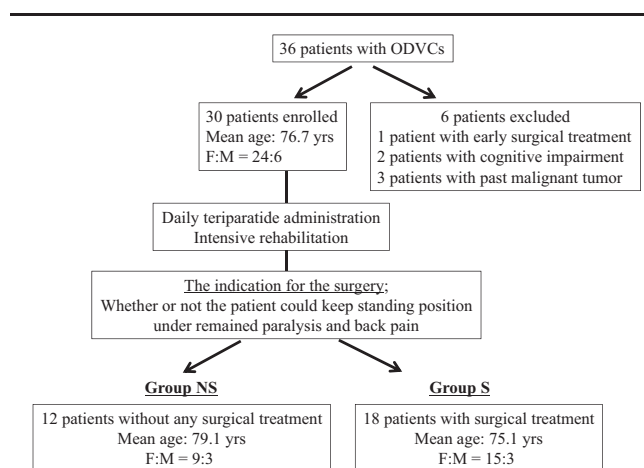


Figure 1. Treatment procedures of 36 patients with osteoporotic delayed vertebral collapse (ODVC). S = surgically treated group, NS = non-surgically treated group.

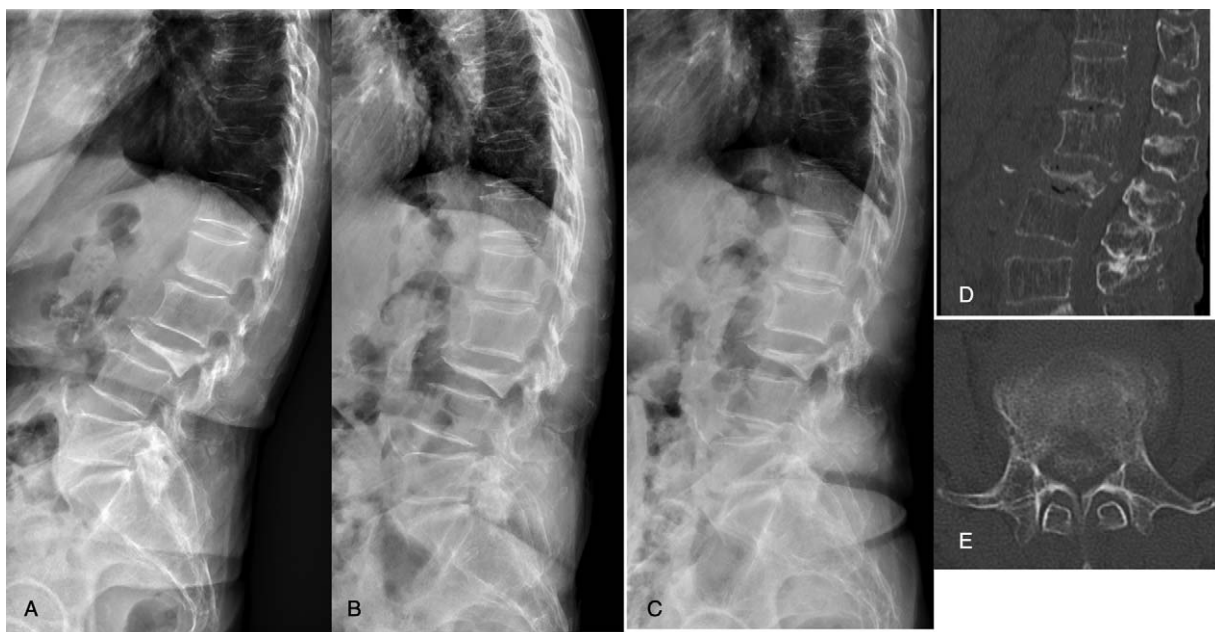


Figure 2. A 82-year-old female patient who underwent anterior and posterior combined surgery for L3 osteoporotic delayed vertebral collapse. Lateral view of thoracolumbar and lumbar radiogram taken in neutral position (A), flexion position (B), and extension position (C) at baseline. The mid-sagittal (D) and axial (E) image of computed tomography reconstruction.

their pain or paralysis had not been recovered enough (S group) (Figs. 2 and 3). The level of affected vertebra was T11 in 5 cases (17%), T12 in 6 cases (20%), L1 in 11 cases (37%), L2 in 3 cases (10%), L3 in 2 cases (7%), and L4 in 1 case (3%). The baseline demographic characteristics in those 2 groups are shown in Table 1.

3.2. Results of outcome measure

Clinical features and radiologic measurements before conservative treatment and 3 months after are shown in Table 2. Although no factor showed any significant difference at baseline in the 2 groups, EQ5D, NRS, Frankel grade, and the mobility of the collapsed vertebrae were significantly different in the 2 groups 3

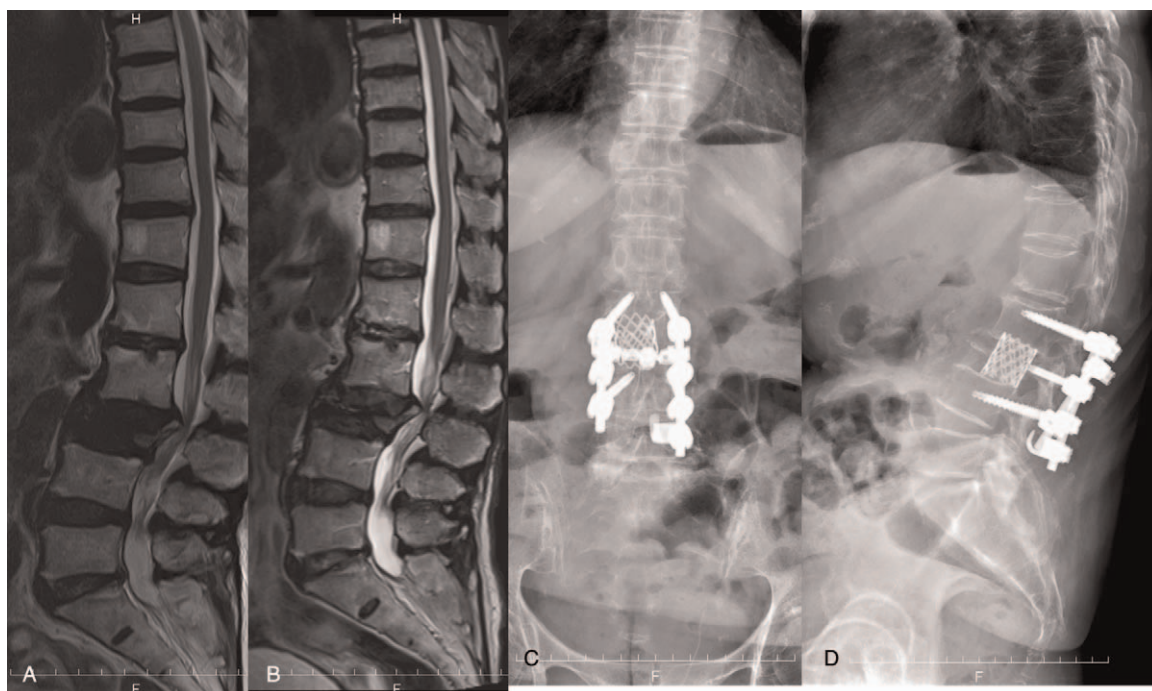


Figure 3. Mid-sagittal T2 magnetic resonance imaging at the baseline (A) and 3 months after the conservative therapy (B). The patient underwent the anterior-posterior decompression and fusion. Postoperative posteroanterior (C) and lateral (D) radiographs.

Table 1
Patients' baseline demographic characteristics in 2 groups.

		NS group, N = 12	S group, N = 18	P	
Age	79.1 ± 8.6	75.1 ± 7.9		0.12	
Female	9 (75%)	15 (83%)		0.58	
Episode of falling	8 (67%)	15 (83%)		0.29	
Comorbidities	Diabetes	5 (42%)	7 (39%)	.9	
	Heart problem	3 (25%)	7 (39%)	.42	
	Respiratory disorder	3 (25%)	5 (28%)	.87	
Drugs	Joint problem	6 (50%)	8 (44%)	.77	
	Anti-platelet drugs	2 (17%)	4 (22%)	.71	
	Warfarin	1 (8%)	3 (17%)	.51	
	Bisphosphonate	5 (42%)	9 (50%)	.65	
	Vitamine D	1 (8%)	1 (6%)	.77	
Level of affected vertebra	Raloxifene	1 (8%)	2 (6%)	.8	
	Th11	2 (17%)	3 (17%)	.18	
	TL	Th12	3 (25%)	5 (28%)	
	L1	3 (25%)	8 (44%)		
	L2	3 (25%)	0 (0%)		
ML	L3	1 (8%)	1 (6%)		
	L4	0 (0%)	1 (6%)		
Quality of paralysis	Spinal cord	8 (67%)	15 (83%)	.4	
	Cauda equina	4 (33%)	3 (17%)		

ML = middle and lower lumbar, NS = non-surgical, S = surgical, TL = thoracolumbar.

months after treatment. The NS group exhibited more improvement 3 months after conservative treatment. The authors also conducted a logistic regression analysis to investigate which factor significantly affected the need for surgical treatment. The mobility of the collapsed vertebrae, EQ5D, and NRS 3 months after the treatment was significantly correlated with the need for surgical intervention (data not shown). Moreover, the δ of those factors showed a remarkable influence upon the necessity for surgical treatment (mobility of the collapsed vertebrae: odds ratio

Table 2
Clinical features and radiologic measurement in 2 groups.

Pre-treatment	NS group, N = 12	S group, N = 18	P	
Clinical features				
EQ5D	0.415	0.323	.24	
NRS	6.8	7.2	.79	
Frankel grade				
	C	0	0	.12
	D	9	15	
E	3	3		
Radiologic measurement				
Spinal canal encroachment	31.80%	28.80%	.72	
Local kyphotic angle	17.5°	13°	.43	
Mobility of collapsed vertebrae	6.5°(2.3–9.6)	8.6°(2.4–12.8)	.47	
3M post-treatment				
Clinical features				
EQ5D	0.595	0.29	.02	
NRS	3	6.7	.03	
Frankel grade				
	C	0	0	<.01
	D	4	14	
E	8	4		
Radiologic measurement				
Spinal canal encroachment	31.60%	29.20%	.67	
Local kyphotic angle	20.5°	24°	.45	
Mobility of collapsed vertebrae	3.7°(2.1–4.4)	15.1°(6.5–17.2)	<.01	

EQ5D = EuroQol questionnaires, NRS = numerical rating scale, NS = non-surgical, S = surgical.

Table 3
Results of logistic regression for the necessity of surgical treatment.

Variable	Category	Univariate logistic regression			
		OR	95% CI	P	
Age		0.911	0.808	1.027	.13
Sex	M	1			
	F	1.667	0.275	10.094	.58
Level of affected vertebra	TL	1			
	ML	0.25	0.037	1.668	.15
Paralysis of spinal cord	No	1			
	Yes	2.5	0.445	14.04	.29
δ Spinal canal encroachment		1.012	0.955	1.074	.68
δ Local kyphotic angle		1.072	1.016	1.13	.01
δ Mobility of collapsed vertebrae		1.063	1.011	1.118	.01
δ EQ5D		0.982	0.965	1	.04
δ NRS		1.113	1.037	1.195	<.01
δ Frankel grade		0.176	0.016	1.951	.16

δ = (Value at 3M) – (Value at baseline)/Value at the baseline.

95% CI = 95% confidence interval, EQ5D = EuroQol questionnaires, ML = middle and lower lumbar, L2, L3, L4, NRS = numerical rating scale, OR = odds ratio, TL = thoracolumbar, Th11, 12, L1.

[OR] = 1.06, P = .01; EQ5D: OR = 0.98, P = .04; and NRS: OR = 1.11, P < .01 (Table 3).

3.3. Results of ROCs

Among factors at baseline, only the mobility of collapsed vertebrae showed a significant value of area under the curve (AUC = 0.727, P = .008). The cutoff value of this was 5.4, of which sensitivity was 0.78 and specificity was 0.67 (Table 4).

4. Discussion

This case series demonstrated that 40% of patients with ODVC showed significant improvements in their back pain as well as their leg paralysis with our treatment protocol. Consequently, they did not need further surgical treatment after the intensive conservative treatment. This result is of great significance for developing a treatment strategy for ODVC.

The initial purpose of this study investigating ODVC treatment was to establish a new treatment strategy for reducing surgery-related complications. Reflecting both on our experience and on the published literature,^[16] we noted that when considering the medium to long-term standpoint, patients have frequently faced numerous major complications related to osteoporosis, such as screw loosening, correction loss, non-union, and the exposure of instruments. Some of these may be unavoidable without

Table 4
Results of ROC, AUC, sensitivity, and specificity of each parameter at baseline for predicting the necessity of surgical treatment.

Variables at baseline	AUC (95% CI)	P
Age	0.6366 (0.4277–0.8455)	NS
Spinal canal encroachment	0.6273 (0.4094–0.8452)	NS
Local kyphotic angle	0.6204 (0.3996–0.8411)	NS
Mobility of collapsed vertebrae	0.7269 (0.5417–0.9120)	.008
EQ5D	0.6806 (0.4653–0.8958)	NS
NRS	0.5741 (0.3661–0.7820)	NS

Cutoff value of mobility of collapsed vertebrae: 5.4 (sensitivity 0.78, specificity 0.67).

AUC = area under the curve, 95% CI = 95% confidence interval, EQ5D = EuroQol questionnaires, NRS = numerical rating scale, NS = not significant, ROC = receiver operating curve.

aggressive treatment of the osteoporosis itself. Then, the authors decided to use daily teriparatide, which was only 1 drug to increase the bone strength, before surgical treatments. Eventually, 40% of patients with ODVC showed improvements. The reason behind this result was the remediation of the mobility of the collapsed vertebrae shown in the Table 2. The authors investigated further changes inside the collapsed vertebrae associated with this conservative treatment. However, CT evaluation as well as bone marker did not show significant difference between the NS and S group at that time. Possible mechanism of this improvement was the effect of both the rehabilitation and daily teriparatide. Enhancement of trunk muscle by rehabilitation might encompass a beneficial effect for stabilizing the collapsed vertebrae, or teriparatide also might improve both cortical and cancellous bone structure within 3 months, which had been proven in the 19 months investigation in the past.^[17] Further investigation is indispensable in future.

Although the results of quality of life evaluation, pain scale, and the degree of paralysis did not exhibit a significant difference between the 2 groups at baseline, those results changed by 3 months, and the patients with poorer improvement eventually required further surgical treatment. The factors associated with surgical treatment in this analysis were the deterioration of the mobility of collapsed vertebrae and the local kyphotic angle. Cutoff values of the ROC also demonstrated the significance of collapsed vertebrae mobility at baseline, which was already reported to be 1 major risk factor for a worse prognosis for ODVC.^[18–20] It is noteworthy that the remained mobility of collapsed vertebrae was proven to be the key for the surgical intervention by logistic regression as well as ROC analysis. Although the local kyphosis angle did not show a significant difference at baseline, the change ratio of this parameter did reflect a significant difference in the end. Taking those results into account, patients whose mobility of collapsed vertebrae greater than 5.4 degrees should be treated surgically as quickly as possible because they are at a greater risk for requiring surgical treatment.

At the beginning of this study, the authors assumed that the level of the affected vertebrae could be a significant factor influencing the need for surgical treatment. Previous reports revealed that a vertebral body fracture in the lower lumbar spine had quite different characteristics than such a fracture in the thoracolumbar lesion because the physiologic and biomechanical functioning of this area are very peculiar.^[21,22] We therefore assumed that ODVC occurring in the lower lumbar spine would always require further surgical treatment. However, possibly due to a small sample size, we were unable to find a correlation between the level of the fractured vertebrae and the need for surgical treatment. This needs to be investigated further in a study with a larger sample size.

There are multiple limitations inherent with this study. First, this is not a cohort study that follows all patients with osteoporotic vertebral fractures. Eligible subjects were patients referred to our institution based on the assumption that a surgical treatment would be required immediately. Some patients with ODVC might not have been referred because of poor general condition. Second, the number of patients was small, meaning that the analysis power was relatively weak and that statistically insignificant results may not be fully generalizable. Third, the definition of ODVC remains ambiguous. Fourth, 3 months further conservative treatment might be too long for fragile patients who wanted to get better sooner. Given this, the authors defined ODVC as patients who had already been treated

conservatively more than 3 months after their initial diagnosis with a new osteoporotic vertebral fracture based on MRI, and leg weakness or intolerable back pain associated with a persistent intervertebral cleft. However, patients who were likely to develop fused vertebrae sooner might exist in this ODVC group. A standard based on pathophysiology such as aseptic necrosis (eg, Kümmell's disease^[6]) would be required.

Generally, case series studies of osteoporotic vertebral fractures or ODVC are biased because there are many confounders, and because long-term follow-up is sometimes difficult. Regardless of country of origin, female and elderly patients may be likely to develop ODVC. However, potential confounders include comorbidities, oral medications, lifestyle, degree of osteoporosis, level(s) of collapsed vertebrae, degree of paralysis, and sagittal imbalance of the spinal column before injury. All of these could influence long-term clinical outcomes, and many spine surgeons have experienced a variety of complications after surgical treatments of ODVC. Therefore, the results of this case series, which may well contribute to the establishment of an effective treatment strategy for ODVC, may be important in the treatment of osteoporosis or ODVC in many countries experiencing the super-aged societies.

Author contributions

Norimitsu Wakao: Study design, managing study, manuscript draft
 Mikinobu Takeuchi, Atsuhiko Hirasawa, Katshuhisa Kawanami, Masataka Deie, Toshihiro Matsuo, and Masakazu Takayasu: Data acquisition and measurement.
 K. Daniel Riew and Shiro Imagama: Study design and supervising this article
 Kenta Murotani: Analysis and interpretation of data
Conceptualization: Norimitsu Wakao.
Data curation: Norimitsu Wakao, Mikinobu Takeuchi, Atsuhiko Hirasawa, Katsuhisa Kawanami, Toshihiro Matsuo.
Methodology: Kenta Murotani.
Supervision: Daniel K Riew, Shiro Imagama, Masataka Deie.
Writing – original draft: Norimitsu Wakao.

References

- Harada A, Matsuyama Y, Nakano T, et al. Nationwide survey of current medical practices for hospitalized elderly with spine fractures in Japan. *J Orthop Sci* 2010;15:79–85.
- Hoshino M, Tsujio T, Terai H, et al. Impact of initial conservative treatment interventions on the outcomes of patients with osteoporotic vertebral fractures. *Spine* 2013;38:E641–8.
- Lavelle EA, Cheney R, Lavelle WF. Mortality prediction in a vertebral compression fracture population: the ASA physical status score versus the Charlson comorbidity index. *Int J Spine Surg* 2015;9:63.
- Nakamura K, Kitamura K, Inoue M, et al. Physical activity and 10-year incidence of self-reported vertebral fractures in Japanese women: the Japan Public Health Center-based Prospective Study. *Osteoporos Int* 2014;25:2565–71.
- Nishimura A, Akeda K, Kato K, et al. Osteoporosis, vertebral fractures and mortality in a Japanese rural community. *Mod Rheumatol* 2014;24:840–3.
- Kim YC, Kim YH, Ha KY. Pathomechanism of intravertebral clefts in osteoporotic compression fractures of the spine. *Spine J* 2014;14:659–66.
- Hoshino M, Nakamura H, Terai H, et al. Factors affecting neurological deficits and intractable back pain in patients with insufficient bone union following osteoporotic vertebral fracture. *Eur Spine J* 2009;18:1279–86.
- Tsujio T, Nakamura H, Terai H, et al. Characteristic radiographic or magnetic resonance images of fresh osteoporotic vertebral fractures predicting potential risk for nonunion: a 10 multicenter study. *Spine* 2011;36:1229–35.

- [9] Nakashima H, Imagama S, Yukawa Y, et al. Comparative study of 2 surgical procedures for osteoporotic delayed vertebral collapse: anterior and posterior combined surgery versus posterior spinal fusion with vertebroplasty. *Spine* 2015;40:E120–6.
- [10] Suk SI, Kim JH, Lee SM, et al. Anterior-posterior surgery versus posterior closing wedge osteotomy in posttraumatic kyphosis with neurologic compromised osteoporotic fracture. *Spine* 2003;28:2170–5.
- [11] Kaneda K, Asano S, Hashimoto T, et al. The treatment of osteoporotic-posttraumatic vertebral collapse using the Kaneda device and a bioactive ceramic vertebral prosthesis. *Spine* 1992;17(Suppl):S295–303.
- [12] Uchida K, Kobayashi S, Matsuzaki M, et al. Anterior versus posterior surgery for osteoporotic vertebral collapse with neurological deficit in the thoracolumbar spine. *Eur Spine J* 2006;15:1759–67.
- [13] Lee SK, Lorenzo JA. Regulation of receptor activator of nuclear factor-kappa B ligand and osteoprotegerin mRNA expression by parathyroid hormone is predominantly mediated by the protein kinase a pathway in murine bone marrow cultures. *Bone* 2002;31:252–9.
- [14] Tsuchiya A, Ikeda S, Ikegami N, et al. Estimating an EQ-5D population value set: the case of Japan. *Health Econ* 2002;11:341–53.
- [15] Welsh EM, Gettinby G, Nolan AM. Comparison of a visual analogue scale and a numerical rating scale for assessment of lameness, using sheep as a model. *Am J Vet Res* 1993;54:976–83.
- [16] Ohtori S, Orita S, Yamauchi K, et al. More than 6 months of teriparatide treatment was more effective for bone union than shorter treatment following lumbar posterolateral fusion surgery. *Asian Spine J* 2015;9: 573–80.
- [17] Jiang Y, Zhao JJ, Mitlak BH, et al. Recombinant human parathyroid hormone (1-34) [teriparatide] improves both cortical and cancellous bone structure. *J Bone Min Res* 2003;18:1932–41.
- [18] Wu AM, Chi YL, Ni WF. Vertebral compression fracture with intravertebral vacuum cleft sign: pathogenesis, image, and surgical intervention. *Asian Spine J* 2013;7:148–55.
- [19] Leung Y, Samartzis D, Cheung KM, et al. Osteoporotic vertebral compression fracture: the clinical impact of “intravertebral clefts”. *Spine J* 2010;10:1035–6.
- [20] Ryu CW, Han H, Lee YM, et al. The intravertebral cleft in benign vertebral compression fracture: the diagnostic performance of non-enhanced MRI and fat-suppressed contrast-enhanced MRI. *Br J Radiol* 2009;82:976–81.
- [21] Moore TA, Bransford RJ, France JC, et al. Low lumbar fractures: does thoracolumbar injury classification and severity score work? *Spine* 2014;39:E1021–5.
- [22] Lehman RA Jr, Kang DG, Bellabarba C. A new classification for complex lumbosacral injuries. *Spine J* 2012;12:612–28.