

Case report

Total hip arthroplasty for an intracapsular femoral neck fracture of high-femoral amputee

Panagiotis Christidis*, Theofanis Kantas, Christos Kalitsis, Sampria Georgia Frechat, Georgios Biniaris, Nikolaos Gougoulas

Department of Orthopedic Surgery, General Hospital of Katerini, Katerini, Greece

Abstract

Femoral neck fractures in transfemoral amputees are not common and management is associated with surgical technique and post-operative rehabilitation challenges. A 61-year-old Caucasian, male, above-knee amputee (following mangled extremity trauma 8 months before) who mobilized with a prosthesis presented to the emergency department with a right femoral neck fracture (Garden III). The patient underwent cementless total hip replacement (THR), using the lateral (Hardinge's) approach. No additional instrument was used to manipulate the residual femoral stump. The absence of the distal limb required careful preparation of the femoral canal, taking into consideration the position of the lesser trochanter, in order to appropriately align the femoral prosthesis regarding anteversion. Postoperative recovery was uneventful. Six months later, the patient was ambulating using his prosthesis and had almost returned to his pre-injury activity status. Satisfactory results can be obtained after THR in trans-femoral amputees.

Keywords: *total hip arthroplasty; total hip replacement; above-knee amputation; femoral neck fracture; intracapsular femoral fracture; subcapital femoral fracture*

Introduction

Femoral neck fracture in an amputated extremity is not common and little has been published about this condition [1–6]. Prolonged disuse and/or protected weight bearing, may cause local osteoporosis, and thus femoral neck fractures can occur with minor trauma [5, 6]. The management of femoral neck fractures in patients with above knee amputations is challenging for the surgeon [2, 7]. The altered anatomy can complicate diagnosis, immobilization, surgical reduction, and stabilization, as well as post-operative rehabilitation [7]. The goal of treat-

ment is the return of the amputee to their pre-fracture status that includes satisfactory and functional use of the prosthetic limb [7].

In the present study we present a case of a high femoral amputee suffering a displaced femoral neck fracture of the same extremity, treated with a total hip replacement.

Case report

A 61-year-old Caucasian, male, above-knee amputee who was previously mobilizing using a prosthesis presented to the emergency department with sudden onset pain in his right thigh, following a fall whilst getting out of bed. Weight bearing wearing his prosthesis was no longer possible due to pain.

He had undergone an above knee amputation as a life-saving procedure, after a crush injury sustained eight months before. He had recovered from the amputation procedure, was using a prosthetic limb and had returned

Received: February 2022; Accepted after review: April 2022; Published: April 2022.

*Corresponding author: Panagiotis Christidis, Department of Orthopedic Surgery, General Hospital of Katerini, 7is Merarchias 26, Katerini 60100, Greece
Email: panagiotischristidis13@gmail.com



to his normal activities. His past medical history included chronic obstructive pulmonary disease, for which he was using an anti-cholinergic inhaler.

On clinical examination, there was tenderness in the greater trochanter and groin area. Right thigh stump showed tenderness on

the log roll test, and there was axial percussion pain. The overlying skin was intact, with a well healed surgical scar over the stump and normal sensation and circulation. No other injuries were identified. Radiographs demonstrated a Garden III femoral neck fracture (Figure 1).

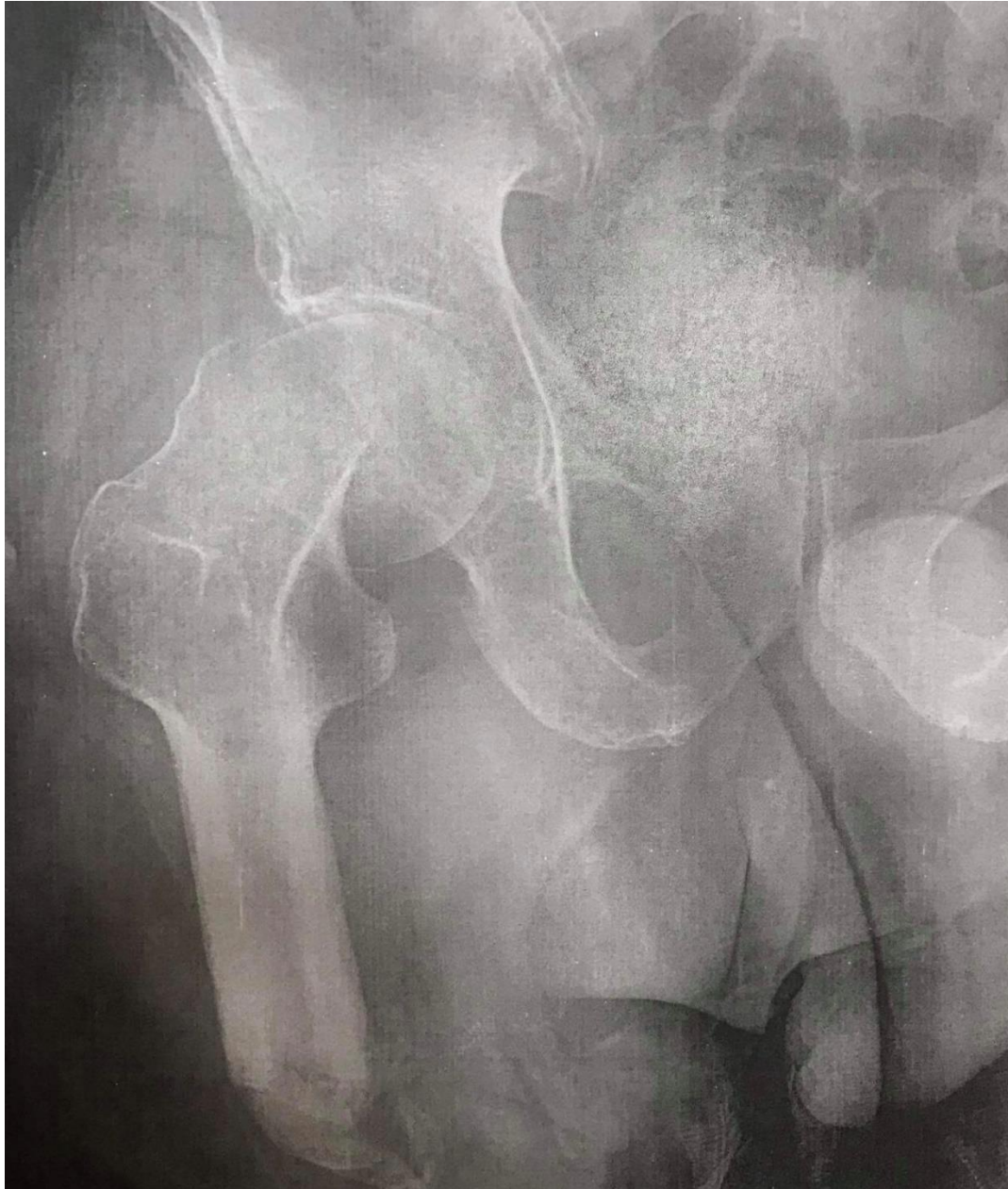

Fig. 1. A Garden III femoral neck fracture

Taking into consideration the patient's age (61 years), total hip arthroplasty (THA) was deemed appropriate. Given the extremity stump was relatively short, with a lesser trochanter to end of femoral stump distance of only 118 mm, a short stem prosthesis was

chosen. Following informed consent, the procedure was performed, under epidural anesthesia, with the patient in lateral decubitus position. A lateral surgical approach with a 10 mm skin incision was required. No Steinmann pin or other instrument was inserted in

anatomic landmarks to facilitate the control of the stump. A 54 mm porous coated uncemented acetabular shell (Medacta Co., International) was aligned with the transverse acetabular ligament. The acetabular shell was transfixed with two 6.5 mm cancellous screws (Medacta Co., International). A cementless size 5 type femoral stem was inserted (Medacta Co., International) and a 28 mm hooded Ultra High Molecular Weight Polyethylene (UHMWPE) liner was used (Medacta Co., International). Care was taken to properly align the femoral stem, regarding anteversion. As the patella could not be used as landmark (due to the trans-femoral amputation), the surgical team relied on palpation of the lesser trochanter and, visually, on the orientation of the femoral canal at the level of the femoral neck osteotomy. After trials, a 28 mm femoral head (Merete GmbH) was impacted and the hip was reduced. The patient received postoperative antibiotics and

anticoagulant therapy, according to departmental protocols.

Implant positioning was deemed optimal. The patient has an uneventful recovery. There was no infection, deep vein thrombosis, dislocation, or any other complication. During his hospitalization, he was allowed to seat and underwent supervised physiotherapy. He was discharged home a week after surgery. Two weeks postoperatively the wound had healed, and the patient began his rehabilitation program wearing his artificial limb, including gait retraining, endurance training and progressing on to stair practice.

At the most recent follow up, six months following THA, the amputated limb was in good condition (Figure 2). On examination he had good range of motion in his hip, without any pain. Wearing the prosthesis, no leg length discrepancy was noted. Radiograph showed well-incorporated femoral and acetabular components without any sign of osteolysis (Figures 3 and 4).

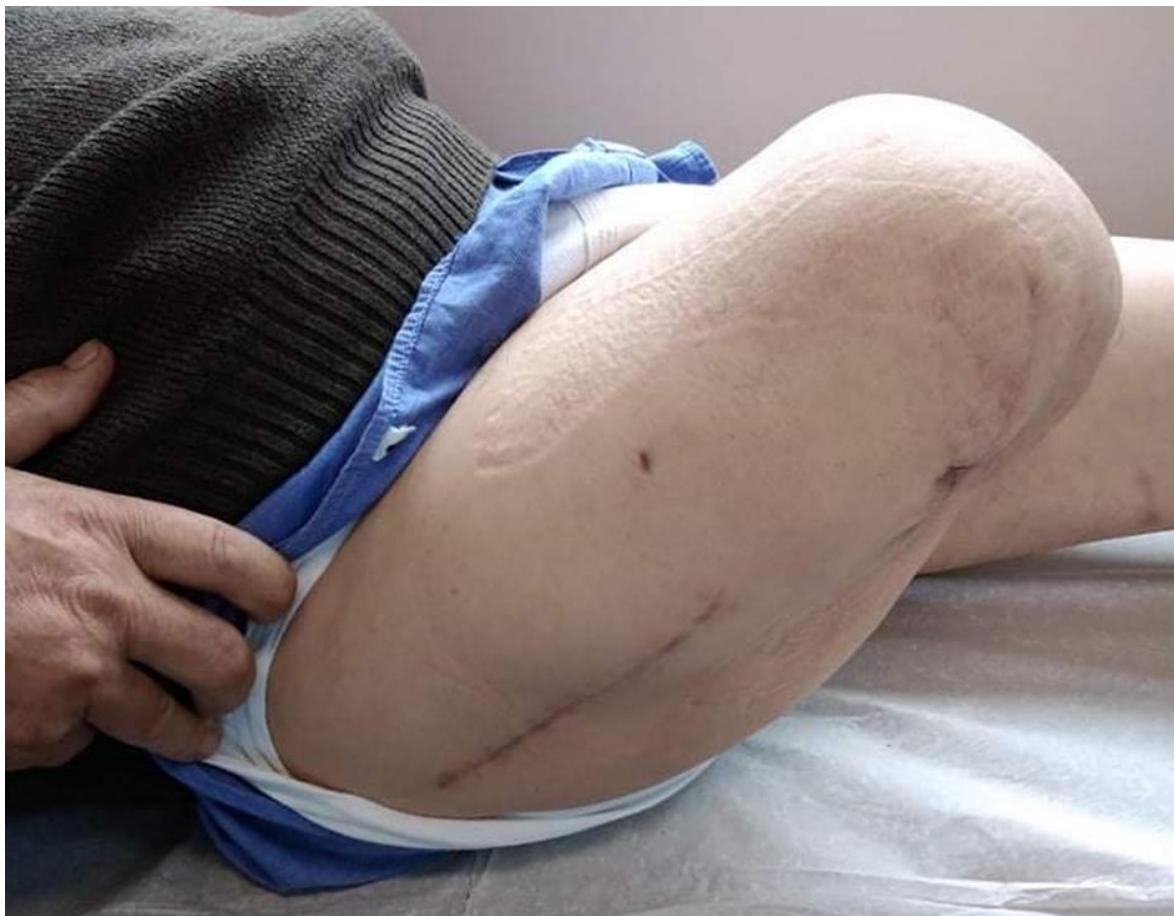

Fig. 2. At the most recent follow up at six months, there was no evidence of surgical site infection or wound dehiscence

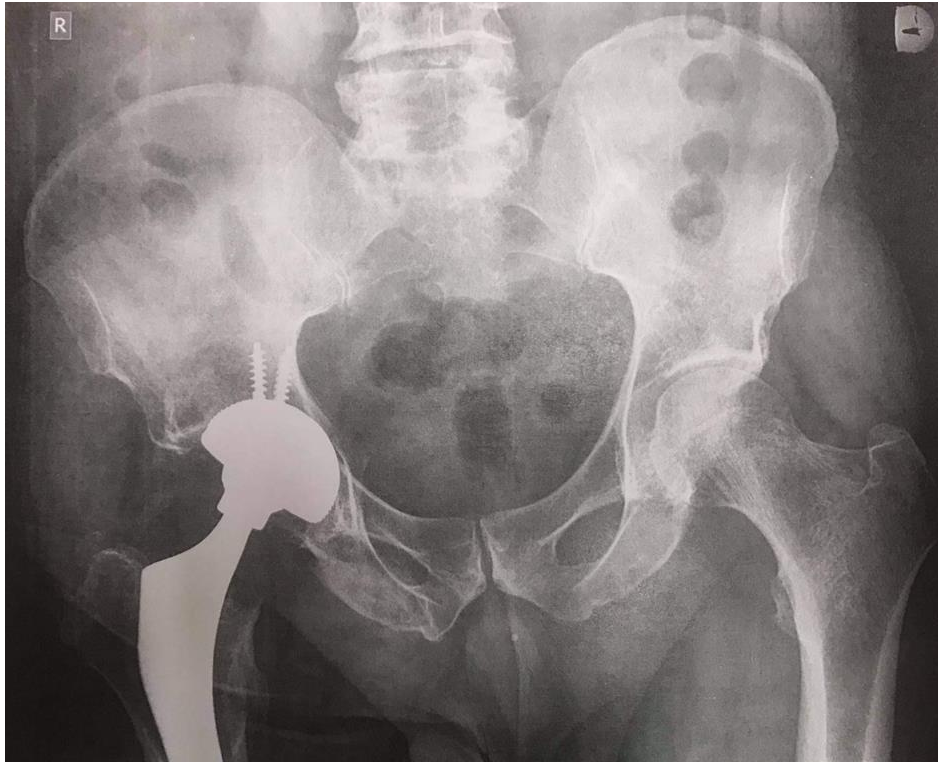


Fig. 3. Postoperative radiograph six months after the operation

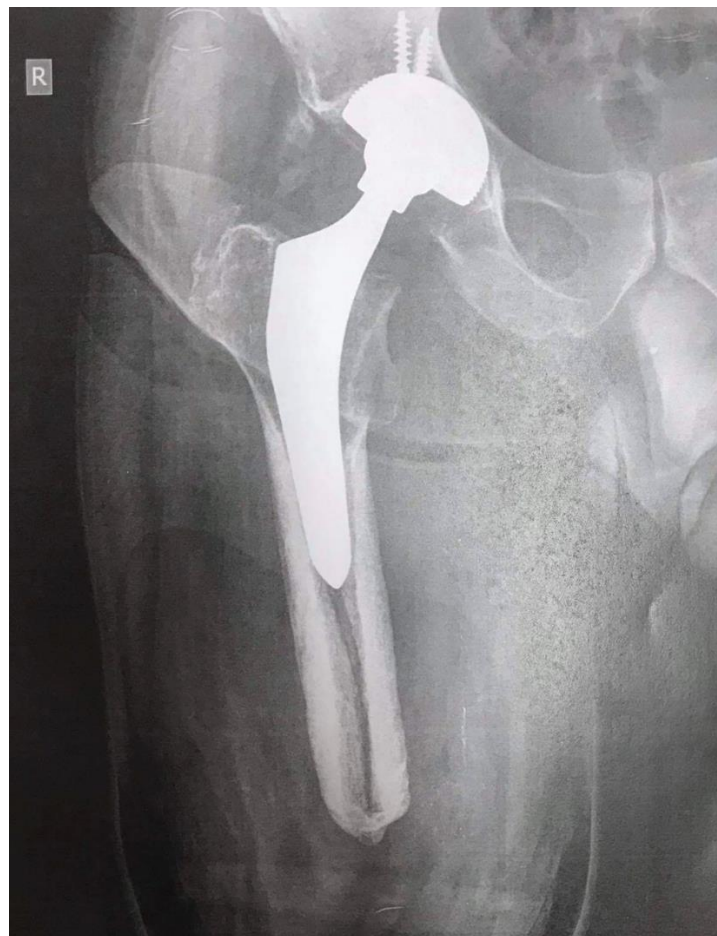

Fig. 4. Postoperative radiograph at 6 months. No osteolysis and a well incorporated prosthesis was noted

Discussion

This 61 years old, active, trans-femoral amputee underwent uncomplicated cementless THA and achieved his preoperative activity status, wearing his artificial limb prosthesis. No special equipment was required to perform his surgery, but the short-length femoral stump was taken into consideration during preoperative planning. Therefore, a short stem implant was used. We want to emphasize that it had taken our 61 years old, male, patient six months to be able to ambulate independently using an artificial limb prosthesis after his amputation, whilst he sustained the femoral neck fracture after minor trauma (fall from standing height) at 8 months

post-amputation. This may have been the result of local disuse osteoporosis, and the lever arm carried by the prosthesis, as also anticipated by other authors [5, 6].

Due to the altered anatomy, management of proximal femoral fractures in patients with lower-limb amputations poses significant challenges [8]. A reduced lever arm for dislocation/relocation in conjunction with the amount of remaining bone length and the osteoporosis are technical issues the surgeon needs to consider [5].

We performed a PubMed literature search to identify studies reporting on proximal femoral fractures in trans-femoral amputees (Table I). We identified five case reports [2–6].

Table I. Peri-operative characteristics of patients with above-knee amputation and femoral neck fracture

Study	Age (years)	Gender	Interval	Method of traction /manipulation	Approach	Operation	F-u (mo)	Outcomes
Kandel et al. 2009 [6]	68	M	58 y	bone holder in the subtrochanteric area	posterior	bipolar HA	60	No restrictions
Ma et al. 2015 [5]	67	M	47 y	Steimann pin on greater trochanter	posterior	cementless THA	24	No restrictions
Boussakri et al. 2015 [2]	81	M	11 y	bone holder in the subtrochanteric area	anterolateral	bipolar HA	30	No restrictions
Patnaik et al. 2017 [4]	30	M	3 mo	bone clamp below the lesser trochanteric area	MIS anterolateral	cementless THA	12	No restrictions
Perumal et al. 2017 [3]	75	M	same event	two Schantz Pin in distal fragment perpendicular to each other	anterolateral	bipolar HA	14	No restrictions
Present study	61	M	8 mo	-	anterolateral	cementless THA	6	Minimal restrictions

Abbreviations: y: years; f-u: follow-up; mo: months; M: male; MIS: minimal invasive surgery; HA: hemi-arthroplasty; THA: total hip arthroplasty

All patients were males with a mean age of 64.2 years (r, 30-81). The older patients (aged 68, 75 and 81) were treated with a bipolar hemi-arthroplasty [2, 3, 6], whereas the younger ones (aged 30 and 67) were treated with a cementless THA [4, 5]. Mean follow-up was 28.0 months (r, 12-60) and all the patients returned to their pre-injury activity status without further restrictions. All authors reported that they had used additional instrumentation (bone holder, Steimann pin) inserted in the area of the greater or lesser trochanters to manipulate the femoral stump. A posterior approach to the hip was used in two cases [5, 6] and the lateral in three [2–4].

We did not use any additional instruments for intra-operative stump manipulation as

length was sufficient enough to allow us to perform the necessary peri-operative maneuvers. We want to highlight that the biggest challenge in such procedures in above knee amputees may be the positioning of the femoral stem within the femoral canal, regarding anteversion. This was achieved by palpating the lesser trochanter and carefully following the anatomic alignment of the femoral canal, during its preparation for insertion of the uncemented femoral prosthesis.

Another important factor to be taken into consideration is placement of the skin incision to protect the scar subsequently from pressure related to the limb prosthesis [6]. We performed a lateral 10 mm incision away from



the previous scar and the area, where the prosthesis was attached. Of note, a larger femoral head (32-36 mm) with different tribological features (e.g., ceramic on polyethylene) could have been selected to ensure better stability, however this was not standard practice in our department.

Age, bone fragility, fracture site and the need for prosthesis to ambulate affect and hinder the rehabilitation process, promoting muscle atrophy and slowing down the return to the pre-injury status [2]. Our patient was mobilized in bed from the first post-operative day. He was allowed to seat, and two weeks after surgery, he began his rehabilitation program with gait retraining. In the published literature, similar patients had no restriction regarding limb movements, and returned to their pre-injury status [2–6].

Conclusion

In conclusion, treating transfemoral amputees with femoral neck fractures can be challenging. There may be no need for additional instrumentation to assist intra-operative maneuvers during hemi- or total hip

arthroplasty. Satisfactory functional outcome and return to pre-injury daily life activities can be achieved after THA.

Acknowledgements

Written informed consent was obtained from the patient, and the institutional review board of our hospital approved this report. The case report is presented in accordance with Surgical CAse REport (SCARE) guidelines.

Conflicts of interest

The authors declare that they have no competing interests.

Financial disclosure

No funding was received.

Authors contributions

All authors contributed to the preparation of the manuscript and approved its content. PC, FGS, TK, CK participated in the surgical procedure and supervised the patient's postoperative rehabilitation. PC and FGS did the follow up assessment and the acquisition of data. TK and CK made substantial contribution to data analysis and performed the literature search. GB and NG, as senior authors, assisted with preoperative planning, edited the manuscript, and gave the final approval.

References

1. Mirdad T, Khan MRH, Kazarah Y. Fracture of the femur in amputation stumps. *Ann Saudi Med.* 1997; 17(6):638–640. DOI: 10.5144/0256-4947.1997.638
2. Boussakri H, Alassaf I, Hamoudi S, et al. Hip arthroplasty in a patient with transfemoral amputation: A new tip. *Case Rep Orthop.* 2015; 2015: 593747. DOI: 10.1155/2015/593747
3. Perumal R, Gaddam SR, Vasudeva J, Dheenadhayalan J, Rajasekaran S. Bipolar hemiarthroplasty in a patient with above-knee amputation: Surgical technique. *J Orthop Case Reports.* 2017; 7(1):54–57. DOI: 10.13107/jocr.2250-0685.686
4. Patnaik S, Nayak B, Sahoo AK, Sahu NK. Minimally invasive total hip replacement in an ipsilateral post-traumatic above-knee amputation: A case report. *J Orthop Case Rep.* 2017; 7(2):3–6. DOI: 10.13107/jocr.2250-0685.722
5. Ma C, Lv Q, Yi C, Ma J, Zhu L. Ipsilateral total hip arthroplasty in patient with an above-knee amputee for femoral neck fracture: A case report. *Int J Clin Exp Med.* 2015; 8(2):2279–2283. PMID: 25932163
6. Kandel L, Hernandez M, Safran O, Schwartz I, Liebergall M, Mattan Y. Bipolar hip hemiarthroplasty in a patient with an above knee amputation: A case report. *J Orthop Surg Res.* 2009; 4:30. DOI: 10.1186/1749-799X-4-30
7. Nannaparaju M, Annavaram K, Anwar R, Khan WS, Hambidge J. Serial femoral fractures in an amputation stump: A case report. *Open Orthop J.* 2017; 11(1):316–320. DOI: 10.2174/1874325001711010316
8. Jain A, Bansal H, Mittal S, Kumar A, Trikha V. Intracapsular fracture of the proximal femur in a bilateral above-knee amputee: A case report with technical tips for intraoperative positioning and literature review. *Chin J Traumatol.* 2021; S1008-1275(21)00154-1. DOI: 10.1016/j.cjtee.2021.09.003

