



# Arthroscopic Medial Compartment Drive-Through Sign for Knee Medial Collateral Ligament Complex Injuries

Julien Billières, M.D., Graeme P. Hopper, M.D., F.R.C.S. (Tr.&Orth.),  
Alessandro Carrozzo, M.D., Alexandre Ferreira, M.D., Sylvain Guy, M.D.,  
Thais Dutra Vieira, M.D., and Bertrand Sonnery-Cottet, M.D.

**Abstract:** Acute injuries of the knee medial collateral ligament complex concomitant with anterior cruciate ligament injuries are common. The exact site of the injury may be difficult to diagnose preoperatively on magnetic resonance imaging. This study describes an arthroscopic sign that helps determine the site of the knee medial collateral ligament complex injury. The “medial compartment drive-through sign,” visualized during arthroscopy, is described as an excessive opening of the medial compartment. If this excessive opening is above the meniscus, it corresponds to a femoral-sided injury; conversely, if the excessive opening is below the meniscus, then it is a tibial-sided injury. This allows a precise surgical incision to be made, thereby avoiding extensive approaches and possible wound-related complications.

**M**edial collateral ligament (MCL) injuries are common and frequently associated with an anterior cruciate ligament tear.<sup>1</sup> Surgical treatment for an MCL injury should be offered to active patients with distal tibial avulsions, complete/grade III MCL tears with rotational instability, and valgus laxity in full extension resulting from a complete posterior oblique ligament (POL) tear.<sup>2-4</sup>

Assessment of valgus laxity in the acute setting can be difficult, and the exact localization of the lesion on magnetic resonance imaging can be challenging.<sup>5,6</sup>

Diagnostic arthroscopy is a useful tool to provide a more accurate description of an MCL complex injury and to guide treatment. This Technical Note describes the arthroscopic medial compartment drive-through sign for MCL complex injuries, which can guide surgical treatment.

## Surgical Technique (With Video Illustration)

This Technical Note presents the arthroscopic medial compartment drive-through sign for MCL complex injuries (Video 1). Pearls and pitfalls plus advantages and disadvantages of this procedure are described in Tables 1 and 2.

## Positioning and Diagnostic Arthroscopy

The patient is placed on the operating table in the standard arthroscopy position with a lateral support at the level of a padded tourniquet and a foot roll positioned to stabilize the leg at 90° of knee flexion. Knee stability examination is performed under anesthesia. Valgus opening at 30° of knee flexion and anteromedial rotatory instability is assessed to confirm an MCL injury. Valgus opening at 0° of knee flexion confirms involvement of the POL. High anterolateral and anteromedial portals are established. A diagnostic arthroscopy is performed and meniscal, cartilage, and other ligament injuries are addressed.

From the Hôpital de La Tour, Meyrin, Switzerland (J.B.); and Centre Orthopédique Santy, FIFA Medical Centre of Excellence, Groupe Ramsay-Générale de Santé, Hôpital Privé Jean Mermoz, Lyon, France (G.P.H., A.C., A.F., S.G., T.D.V., B.S.-C.).

The authors report the following potential conflicts of interest or sources of funding: B.S.-C. reports grants and personal fees from Arthrex, outside the submitted work. Full ICMJE author disclosure forms are available for this article online, as [supplementary material](#).

Investigation performed at Centre Orthopédique Santy, FIFA Medical Centre of Excellence, Groupe Ramsay-Générale de Santé, Hôpital Privé Jean Mermoz, Lyon, France.

Address correspondence to Thais Dutra Vieira, M.D., Centre Orthopedique Santy, 24 Avenue Paul Santy, 69008, Lyon, France. E-mail: [thaisdutravieira@hotmail.com](mailto:thaisdutravieira@hotmail.com)

© 2022 THE AUTHORS. Published by Elsevier Inc. on behalf of the Arthroscopy Association of North America. This is an open access article under the CC BY-NC-ND license (<http://creativecommons.org/licenses/by-nc-nd/4.0/>). 2212-6287/211687

<https://doi.org/10.1016/j.eats.2021.12.034>

**Table 1.** Pearls and Pitfalls

Pearls	Pitfalls
Exact identification and localization of MCL injuries.	If the lesion is not well defined, there is a risk of unnecessary and extensive medial approaches
Complex tears can be seen during medial compartment exploration and guide surgical treatment.	

MCL, medial collateral ligament.

### Medial Compartment Exploration

The “drive-through sign” is defined by an excessive medial compartment opening (greater than 1 cm) with valgus stress at 30° of flexion (Fig 1). Easy passing or complete insertion of the arthroscope between the medial femoral condyle and tibial plateau can be performed.

The position of the medial meniscus (MM) in relation to the tibia during valgus opening is then assessed. In cases with proximal MCL tears, the MM remains close to the tibia (“low-riding MM”) (Fig 2), whereas in cases with distal MCL and/or meniscotibial attachment of the deep MCL tears, the MM lifts off from the tibial plateau (“high-riding MM”) (Fig 3).

In the acute setting, tears of the deep MCL and posteromedial capsule can be visualized and probed via an anterior view or a transnotch view of the posteromedial compartment (Fig 4). Following identification of the site of the MCL complex injury, surgical repair can be planned.

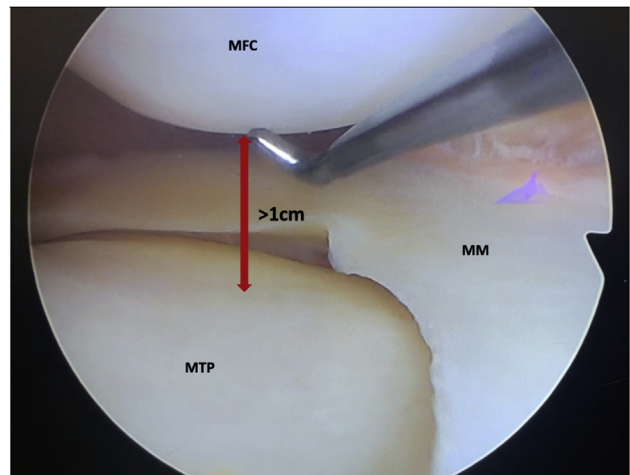
### Surgical Management of MCL Complex Injuries

The location and length of the medial knee incision depends on the location of the injury visualized under arthroscopy (Fig 5). If the lesion is on the femoral side,

**Table 2.** Advantages and Disadvantages

Advantages	Disadvantages
Assessment of location of the sMCL, dMCL, POL/posteromedial capsule.	Intra-articular fluid leak in acute cases can make the surgical approach more difficult.
Decreases the size of the incision for medial collateral ligament complex repair.	
Reduces the risk of wound complication.	
No additional invasiveness in using diagnostic arthroscopy if performed in conjunction with another ligamentous, meniscal or cartilage surgery.	

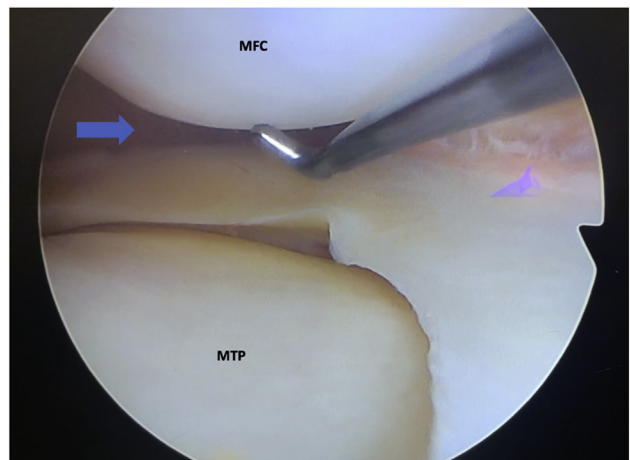
dMCL, deep medial collateral ligament; POL, posterior oblique ligament; sMCL, superficial medial collateral ligament.



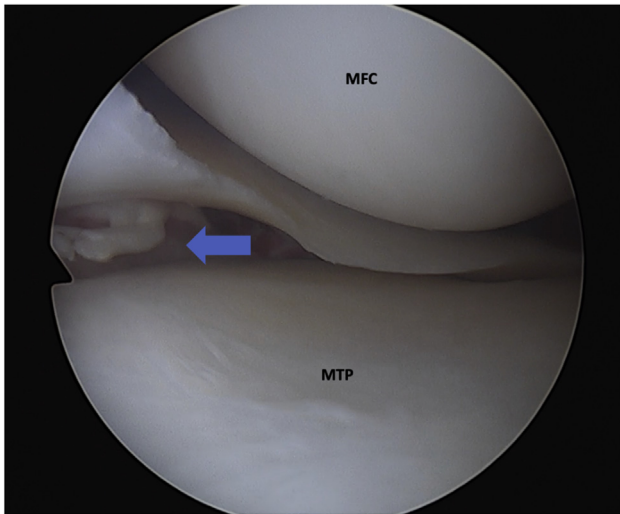
**Fig 1.** Drive-through sign. Right knee arthroscopic view of the medial compartment. Excessive medial compartment opening (greater than 1 cm, represented by the red arrow) with valgus stress at 30° of flexion indicating a medial collateral ligament complex injury. (MFC, medial femoral condyle; MM, medial meniscus; MTP, medial tibial plateau.)

the incision starts proximal to the medial epicondyle and extends to the joint line. If the lesion is on the tibial side, the incision extends from the joint line to the pes anserinus.

Acute proximal and distal superficial MCL lesions as well as lesions of the deep MCL and/or POL are repaired with Bio-SutureTak (Arthrex, Naples, FL) anchors (Fig 6).

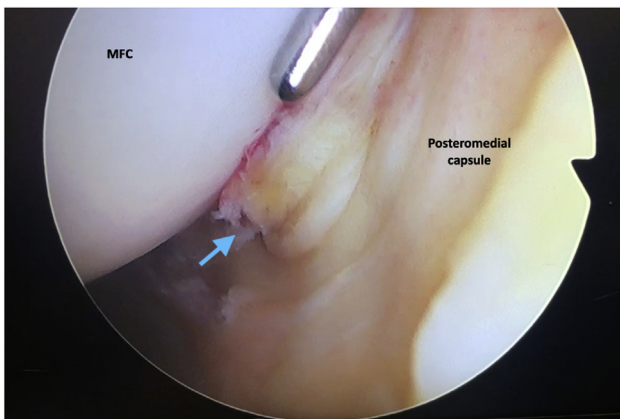


**Fig 2.** Low-riding MM. Right knee arthroscopic view of the medial compartment. Excessive medial compartment opening with low-riding MM, indicating a femoral-sided MCL injury. Blue arrow: femoral-sided opening. (MCL, medial collateral ligament; MFC, medial femoral condyle; MM, medial meniscus; MTP, medial tibial plateau.)



**Fig 3.** High-riding MM. Left knee arthroscopic view of the medial compartment. Excessive medial compartment opening with high-riding MM, indicating a tibial-sided MCL injury. Blue arrow: tibial-sided opening. (MCL, medial collateral ligament; MFC, medial femoral condyle; MM, medial meniscus.)

In cases in which the tissue is not amenable to repair, augmentation is performed with FiberTape (Arthrex, Naples, FL) or a semitendinosus tendon autograft, due to its low healing prognosis. Chronic medial complex injuries are treated with reconstruction using a 2-bundle technique as described by Lind et al.<sup>7</sup> with semitendinosus tendon autograft or a fresh frozen allograft.



**Fig 4.** Deep MCL (dMCL) lesion. Right knee arthroscopic view of the posteromedial compartment with a femoral-sided tear of the dMCL and posteromedial capsule (blue arrow). (MCL, medial collateral ligament; MFC, medial femoral condyle.)



**Fig 5.** Medial incision. The medial incision (red dotted line) for a femoral-sided MCL lesion, the incision starts proximal to the medial epicondyle (ME) and extends to the joint line. (MCL, medial collateral ligament.)

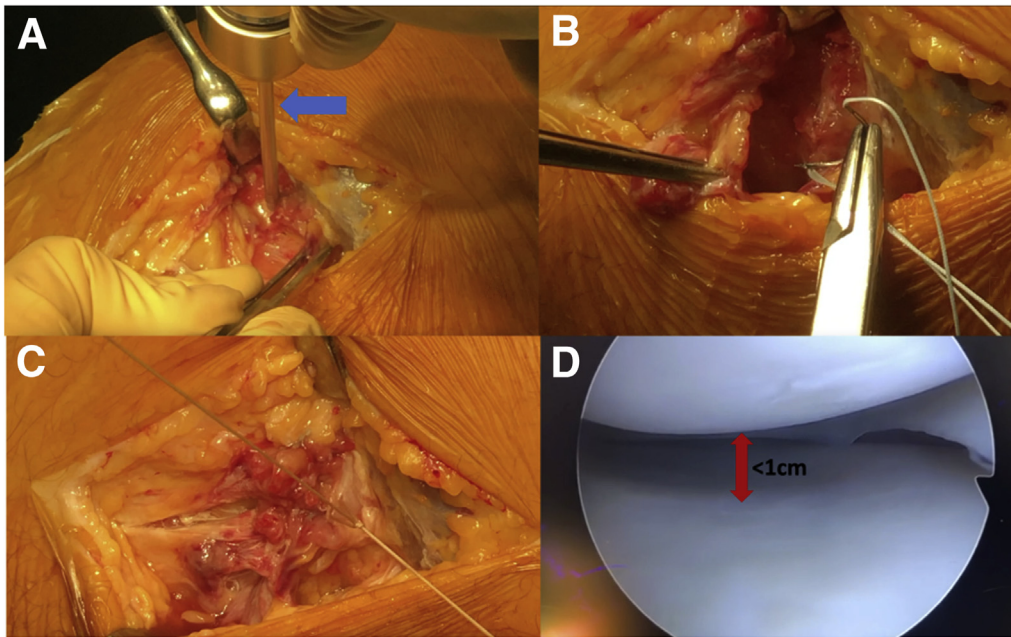
### Postoperative Rehabilitation

Postoperatively, the patient is placed in a hinged knee brace for 6 weeks. During the first 4 weeks, knee range of motion is started immediately between 0° and 90° of flexion. Full range of motion is achieved by 6 weeks. Early rehabilitation is focused on obtaining full extension and quadriceps activation. Pivoting—contact sports are allowed from 9 months after neuromuscular recovery.

### Discussion

This Technical Note describes the “medial compartment drive-through sign” during arthroscopy for MCL complex injuries. It can be used to assess the degree of medial compartment opening and to localize the site of the injury. This information allows a precise surgical incision to be made and therefore may reduce the risk of wound complications.

The “drive-through sign” corresponds to an excessive opening of the medial compartment (greater than 1 cm) at 30° knee flexion. Biomechanical studies have indicated that complete medial knee injuries yielded gapping of 9.8 mm at 20° for a clinician applied load.<sup>8</sup> The site of the lesion also can be detected by the displacement of the MM relative to the femur and tibia during valgus stress. A “high-riding MM” (large gap between the tibia and the meniscus) corresponds to an injury to the distal part of the MCL complex whilst a “low-riding MM” indicates a proximal lesion. These findings can guide the surgical approach for the repair or reconstruction. In summary, the arthroscopic medial compartment drive-through sign for MCL complex injuries is a helpful tool to detect and to guide the surgical management plan.



**Fig 6.** Medial collateral ligament complex repair. (A) Suture anchor positioning (blue arrow: predrilling). (B and C) Repair of the superficial MCL, deep MCL, and POL. (D) Arthroscopic view showing a decrease in the gap between the femur and tibia (red arrow). (MCL, medial collateral ligament; POL, posterior oblique ligament.)

## References

1. Fetto JF, Marshall JL. Medial collateral ligament injuries of the knee: A rationale for treatment. *Clin Orthop Relat Res* 1978;(132):206-218.
2. Figueroa D, Guiloff R, Vaisman A, Figueroa F, Schenck RC Jr. Medial side knee injuries: Simplifying the controversies: Current concepts. *J ISAKOS* 2020;5:134-143. <https://doi.org/10.1136/jisakos-2019-000396>.
3. Chahla J, Kunze KN, LaPrade RF, et al. The posteromedial corner of the knee: An international expert consensus statement on diagnosis, classification, treatment, and rehabilitation [published online October 26, 2020]. *Knee Surg Sports Traumatol Arthrosc.* <https://doi.org/10.1007/s00167-020-06336-3>
4. Hughston JC. The importance of the posterior oblique ligament in repairs of acute tears of the medial ligaments in knees with and without an associated rupture of the anterior cruciate ligament. Results of long-term follow-up. *J Bone Joint Surg* 1994;76:1328-1344. <https://doi.org/10.2106/00004623-199409000-00008>.
5. Loredó R, Hodler J, Pedowitz R, Yeh LR, Trudell D, Resnick D. Posteromedial corner of the knee: MR imaging with gross anatomic correlation. *Skelet Radiol* 1999;28:305-311. <https://doi.org/10.1007/s002560050522>.
6. Pedersen RR. The medial and posteromedial ligamentous and capsular structures of the knee: Review of anatomy and relevant imaging findings. *Semin Musculoskelet Radiol* 2016;20:12-25. <https://doi.org/10.1055/s-0036-1579710>.
7. Lind M, Jakobsen BW, Lund B, Hansen MS, Abdallah O, Christiansen SE. Anatomical reconstruction of the medial collateral ligament and posteromedial corner of the knee in patients with chronic medial collateral ligament instability. *Am J Sports Med* 2009;37:1116-1122. <https://doi.org/10.1177/0363546509332498>.
8. LaPrade RF, Bernhardtson AS, Griffith CJ, MacAlena JA, Wijdicks CA. Correlation of valgus stress radiographs with medial knee ligament injuries: An in vitro biomechanical study. *Am J Sports Med* 2010;38:330-338. <https://doi.org/10.1177/0363546509349347>.