

Single Case

Signet Ring Carcinoma of the Appendix Presenting as Crohn's Disease in a Young Male

Jonatan Vukovic^{a, b} Pavle Vrebalov Cindro^b Snjezana Tomic^{a, c}
Ante Tonkic^{a, b}

^aUniversity of Split, School of Medicine, Split, Croatia; ^bDepartment of Gastroenterology and Hepatology, University Hospital of Split, Split, Croatia; ^cDepartment of Pathology, University Hospital of Split, Split, Croatia

Keywords

Signet ring carcinoma · Appendix · Crohn's disease · Inflammatory bowel disease · Appendiceal signet ring carcinoma

Abstract

Primary signet ring cell carcinoma is a rare event in surgery. It looks like acute appendicitis and it is difficult to diagnose it on clinical grounds alone. The diagnosis is always confirmed by histopathology of a surgically removed appendix. A young man, 22 years old, presented with vomiting, diarrhea, and cramps in his abdomen without abdominal tenderness (mild abdominal discomfort in the right lower abdominal quadrant without signs of peritoneal irritation) during the previous month. The first endoscopic results showed only changes of mucosa that could be attributed to endoscopic and clinical representation of Crohn's disease. A few days after the initiation of the therapy with aminosalicylates and corticosteroids, the patient went into ileus and was transferred to the Department of Surgery, where he underwent an emergency right-sided hemicolectomy with resection of the transversal colon and forming of an ileostoma. The first pathohistological diagnosis was pseudomembranous colitis. Because the patient's condition was deteriorating, a revision of the pathohistological diagnosis was done. After careful revision and extensive sampling, a signet ring cell carcinoma arising in the appendix with infiltration of the ileocecal region was found. Immunohistochemically, tumor cells were positive for CDX-2, CK7, CK20, CK19, and carcinoembryonic antigen and negative for

chromogranin A. Sixteen isolated lymph nodes were negative. Although the patient had a disease that was localized to the appendix and ileocecal region with no apparent distal metastasis, his clinical condition was worsening rapidly and he died after 2 months. This case shows the aggressive biological behavior of the appendix signet ring cell carcinoma. Scrupulous histopathological examination of the appendix is an obligatory procedure. Elimination of the signet ring cell carcinoma from other carcinoma subtypes is of special importance as it has an exceptionally poor prognosis and is generally diagnosed in its advanced stages.

© 2018 The Author(s)
Published by S. Karger AG, Basel

Background

The majority of appendiceal tumors are neuroendocrine neoplasms (50–75%), while most of the remaining tumors are adenocarcinomas [1]. They constitute 0.12 cases per 100,000 people per year and less than 0.5% of gastrointestinal neoplasms [2, 3]. Apart from their rarity, the complexity of the spectrum of this malignant disease leads to confusion about the accurate description of the natural behavior of these tumors. Appendiceal adenocarcinomas are divided into 3 groups: mucinous adenocarcinomas, low-grade appendiceal mucinous neoplasms, and signet ring cell carcinomas [2]. Adenocarcinomas account for 58% of the malignant appendiceal tumors, with the median age at presentation in the sixth or seventh life decade. It can present as appendicitis and diagnosis is usually established after appendectomy [4]. The treatment for adenocarcinoma when confined to the appendix is appendectomy and right hemicolectomy [5]. If signet ring cells account for more than 50% of the neoplasms, the term “signet ring carcinoma” is appropriate. Such lesions should be included in the high-grade category. Primary signet ring cell carcinoma is a rare event in surgery [6]. More often, it presents as acute appendicitis, so it is hard to diagnose it on clinical grounds alone [7, 8] and the diagnosis is always confirmed by histopathology of a surgically removed appendix [9]. Preoperative diagnosis of this tumor can be confusing because it does not show specific clinicoradiological signs and can be misinterpreted as an inflammatory process. During the diagnosis, chances are high that the tumor has grown beyond the appendiceal wall [10, 11]. According to the National Cancer Institute’s surveillance epidemiology from 1973 to 2001, signet ring carcinoma was the least prevalent of the appendiceal tumors with only 4%. It has a very poor prognosis, with a 5-year survival of 7% [2, 6].

Case Presentation

A 22-year-old male patient was admitted to the Department of Gastroenterology and Hepatology with vomiting clear gastric contents, diarrhea, and abdominal cramps that had started 1 month before. The patient was healthy before this and his medical history was unrevealing. No smoking and no alcohol and drug abuse were recorded. Physical examination only showed abdominal tenderness (mild abdominal discomfort in the right lower abdominal quadrant without signs of peritoneal irritation). Routine laboratory results were within normal limits. Tumor markers were all in the reference levels (alpha-fetoprotein was 1.49 µg/L with a reference level of up to 8.78 µg/L, prostate specific antigen was 0.097 µg/L with a reference level of up to 4.00 µg/L, carcinoembryonic antigen was 2.97 µg/L with a reference level of up to 5.00 µg/L, cancer antigen 19–9– was 8.53 µg/L with a reference level of up to 37.00 µg/L, neuron-specific enolase was 16.4 µg/L with a reference level of up to 16.30 µg/L, and

cytokeratin 19 fragments (CYFRA 21–1) was 1.5 µg/L with reference levels between 0.1 and 3.30 µg/L). Colonoscopy was performed with multiple biopsies of the ileocecal region as well as extensive sampling of the rest of the colon. Histologically, the biopsy series contained pathohistological samples of the colonic wall that showed changes of the mucosa that could be attributed to an endoscopic and clinical representation of Crohn's disease. He was put on aminosalicylates (mesalazine) and corticosteroids (prednisolone), but a few days after the initiation of the therapy the patient stopped having bowel movement and went into ileus and was transferred to the Department of Surgery where he underwent an emergency right-sided hemicolectomy with resection of the transversal colon and forming of an ileostoma. The first pathohistological diagnosis was pseudomembranous colitis. The patient was in the intensive care unit (ICU) of the Department of Surgery for the following 6 days, but his condition was getting worse. He was still having abdominal pain, diarrhea, significant weight loss, and fatigue. A gastroenterologist was called in who suggested a transfer to the ICU of the Department of Gastroenterology and Hepatology. Because the patient's condition was deteriorating and we expected it to improve because of the therapy and surgery and tests to detect *Clostridium difficile* and its toxins were repeatedly negative, a revision of the pathohistological diagnosis was done. After careful revision and extensive sampling, a signet ring cell carcinoma arising in the appendix with infiltration of the ileocecal region was found. Immunohistochemically, tumor cells were positive for CK20 (Fig. 1), CDX-2 (Fig. 2), CK7 (Fig. 3), CK19 (Fig. 4), and negative for carcinoembryonic antigen (Fig. 5), chromogranin A (Fig. 6), synaptophysin, and CD 56. Sixteen isolated lymph nodes were negative. Aminosalicylate and corticosteroid therapy was stopped. In the meantime, the patient reported a partial loss of sight and epileptic seizure of a grand mal kind. A neurologist and an ophthalmologist were then consulted who asked for an emergency brain and orbit magnetic resonance imaging (MRI) which showed a brain edema and lesions that are common with extraintestinal changes of Crohn's disease. The patient was then treated for methicillin-resistant *Staphylococcus epidermidis* (MRSE) and *Candida parapsilosis* that came out positive from his blood cultures. Also from his bronchial aspirate, *Acinetobacter baumannii* and *Klebsiella pneumoniae* came out positive. After discussions with the oncology team, and given the patient's overall condition, cardiopulmonary instability, Eastern Cooperative Oncology Group (ECOG) performance status grade 3–4, and CT scans that showed that there was no remaining malignant disease, no oncological treatment was advised. It is important to emphasize that most of the time the patient spent in the Department of Gastroenterology and Hepatology, there was a massive return of secretion on the patient's nasogastric probe and a weaker filling of ileostoma. A surgeon was again called in who then decided to admit the patient to the ICU of the Department of Surgery for chronic ileus. The patient died in the ICU of the Department of Surgery just a few days after admission and after a new operation.

Discussion and Conclusions

Non-neuroendocrine appendiceal malignancies are very rare and represent less than 0.5% of all gastrointestinal malignancies. The prevalence rate in the literature is around 0.3% [6]. Adenocarcinomas of the appendix are less common than appendiceal neuroendocrine tumors, and since the first case was reported by Berger in 1882, there have been only a few hundred cases described in the literature. Because of the low incidence, there is still controversy concerning the optimal treatment for this kind of cancer. The mean age at presentation

is 63 years and, with 58%, men are more often affected than women [12]. Signet ring carcinomas are even rarer than adenocarcinomas and they constitute only 4% of all neoplasms of the appendix [6]. The signet ring cell carcinomas are most frequent in the stomach. The CDX-2 and CK20 marker is vital for confirmation of the diagnosis [13]. The majority of the appendix carcinomas are identified accidentally, and many are advanced at the time of diagnosis [14]. The extent of the tumor at the time of the diagnosis is an important determinant of the patient's future prognosis. As previous studies show, the prognosis of patients with diffuse, peritoneal metastases has a 5-year survival rate of only 6.7–14% [15]. Imaging of a primary appendiceal malignancy may resemble a more common regional disease, like inflammatory bowel disease (IBD), ischemia, or acute appendicitis [10, 11]. Numerous other diseases can also alter the imaging of the ileocecal region and create bowel wall thickening. Evaluation of various parameters, such as degree and extent of thickening, presence or absence of fat stranding, pattern of enhancement, and associated features including nodal status, can help in this distinction [16]. On CT imaging, neoplastic processes are more likely associated with wall thickening that is more than 3 cm, involvement of a short segment, and/or an abrupt transition point. On the other hand, more common findings in IBD are wall thickening less than 2 cm, a longer segment involvement, and/or a smooth transition to the normal bowel [17]. Heterogeneous attenuation is more common in ischemia and necrosis and seen in poorly differentiated gastrointestinal tumors. Fat stranding is more commonly associated with inflammatory conditions, while asymmetrical/eccentric wall thickening is associated with malignant processes [17]. However, IBD and signet ring carcinoma may not be mutually exclusive. Hristova et al. [18] showed that circumferential thickening of the colorectal wall and the presence of free-fluid effusion in the abdomen were related to signet ring carcinoma arising in association with IBD.

Signet ring carcinomas are considerably more likely to have extended at the time of diagnosis, as compared to other primary appendiceal tumors [2, 9]. Essentially, lymphatic-space metastases can closely mimic inflammatory conditions [14, 19]. The components of the ileocecal region (terminal ileum, appendix, cecum, ileocecal valve) are anatomically next to one another; so, the pathology may include more than a single anatomic area, causing difficulties in its diagnosis. Familiarity with the unclear clinical presentation of the disease, together with the radiologic features, colonoscopy results, and finally tissue sampling give the correct diagnosis.

Our patient was only 22 years old at the time of the diagnosis of his tumor. A case of appendiceal adenocarcinoma spreading to the ileocecal valve presenting as Crohn's disease in an 86-year-old man has been reported [19]. In our case, the tumor was showing lesions that could be typical for Chron's disease. We called for a revision of pathological results because our patient was getting worse in spite of the correct therapy for IBD. Unfortunately, our patient had a signet ring cell carcinoma. Interestingly, all tumor markers in the patient's blood were in the reference levels. Multiple CT scans of the abdomen did not detect remaining malignant disease. As stated by some other studies, signet ring cell carcinomas and poorly differentiated adenocarcinomas of the appendix have a high tendency for development of metastasis with a 5-year survival rate of only 7%. Hence, signet ring cell carcinoma is considered to be a separate type of tumor in the appendix on the grounds of its bad prognosis. The treatment of choice for all microscopic types of appendiceal carcinomas is right hemicolectomy, even in cases with perforation. In metastatic disease, the recommended treatment is systemic chemotherapy together with intraoperative intraperitoneal chemotherapy, peritonectomy, and cytoreductive surgery [2, 9]. Our patient was in such a bad condition (ECOG 3–4) and radiological imaging did not show any remaining disease. Therefore, he was not a candidate for any kind of chemotherapy.

To conclude, scrupulous histopathological examination of the appendix is an obligatory procedure. Elimination of signet ring cell carcinoma from other carcinoma subtypes is of special importance as it has an exceptionally poor prognosis and is generally diagnosed in advanced stages.

Statement of Ethics

We obtained approval and written informed consent for participation and publication from the next of kin because the patient died. The consent form is available from the Editor if requested.

The ethics committee of the University Hospital of Split has approved the study.

Availability of Data and Materials

The datasets used and/or analyzed during the current case report are available from the corresponding author on reasonable request. All data generated or analyzed during this study are included in this published article (and its supplementary information files). The data generated and/or analyzed during the current study are available at the University Hospital of Split archive. The data generated and/or analyzed during the current study are not publicly available due to confidentiality of private information but are available from the corresponding author and the University Hospital of Split on reasonable request.

Disclosure Statement

The authors declare that they have no competing interests.

Funding Sources

The authors have funded all research personally.

Author Contributions

J.V., P.V.C., and A.T. designed the report; S.T. performed the pathohistological analyses; V.J. and V.C.P. collected the patient's data; J.V., P.V.C., S.T., and A.T. analyzed the data and wrote the paper. All the authors gave their approval for the final version of the article to be published and all the authors agreed to be accountable for all aspects of the work in ensuring that questions related to the accuracy or integrity of any part of the work are appropriately investigated and resolved.

References

- 1 Behera PK, Rath PK. Primary appendiceal Mucinous Aden carcinoma. *Indian J Surg.* 2009;68:12261–5.
- 2 Carr NJ, Sobin LH. Adenocarcinoma of the appendix. In: Bosman FT, Carneiro F, Hruban RH, Theise ND, editors. WHO Classification of Tumours of the Digestive System, World Health Organization Classification of Tumours. Lyon: IARC Press; 2010. pp. 122–5.
- 3 Rutledge RH, Alexander JW. Primary appendiceal malignancies: rare but important. *Surgery.* 1992 Mar;111(3):244–50.
- 4 Katsuno G, Kagawa S, Kokudo Y, Muraoka A, Tatemoto A, Sone Y et al. Ureteral metastasis from appendiceal cancer: report of a case. *Surg Today.* 2005;35(2):168–71.
- 5 Park IJ, Yu CS, Kim HC, Kim JC. [Clinical features and prognostic factors in primary adenocarcinoma of the appendix]. *Korean J Gastroenterol.* 2004 Jan;43(1):29–34. Korean.
- 6 McGory ML, Maggard MA, Kang H, O'Connell JB, Ko CY. Malignancies of the appendix: beyond case series reports. *Dis Colon Rectum.* 2005 Dec;48(12):2264–71.
- 7 Connor SJ, Hanna GB, Frizelle FA. Appendiceal tumors: retrospective clinicopathologic analysis of appendiceal tumors from 7,970 appendectomies. *Dis Colon Rectum.* 1998 Jan;41(1):75–80.
- 8 O'Donnell ME, Badger SA, Beattie GC, Carson J, Garstin WI. Malignant neoplasms of the appendix. *Int J Colorectal Dis.* 2007 Oct;22(10):1239–48.
- 9 Ko YH, Jung CK, Oh SN, Kim TH, Won HS, Kang JH et al. Primary signet ring cell carcinoma of the appendix: a rare case report and our 18-year experience. *World J Gastroenterol.* 2008 Oct;14(37):5763–8.
- 10 Fusari M, Sorrentino N, Bottazzi EC, Del Vecchio W, Cozzolino I, Maurea S et al. Primary signet ring cell carcinoma of the appendix mimicking acute appendicitis. *Acta Radiol Short Rep.* 2012 Oct;1(9):29.
- 11 Mastoraki A, Papanikolaou IS, Kanakis D, Safioleas P, Sakorafas G, Safioleas M. A case of signet ring carcinoma of the appendix: dilemmas in differential diagnosis and management. *J Gastrointest Cancer.* 2010 Jun;41(2):141–4.
- 12 Bertuzzo VR, Coccolini F, Pinna AD. Peritoneal seeding from appendiceal carcinoma: A case report and review of the literature. *World J Gastrointest Surg.* 2010 Aug;2(8):265–9.
- 13 Nonaka D, Kusamura S, Baratti D, Casali P, Younan R, Deraco M. CDX-2 expression in pseudomyxoma peritonei: a clinicopathological study of 42 cases. *Histopathology.* 2006 Oct;49(4):381–7.
- 14 Hashash JG, Nasr JY, Francis F. Education and Imaging. Gastrointestinal: mucinous and signet cell adenocarcinoma of the appendix. *J Gastroenterol Hepatol.* 2013 Jun;28(6):903.
- 15 Ronnett BM, Zahn CM, Kurman RJ, Kass ME, Sugarbaker PH, Shmookler BM. Disseminated peritoneal adenomucinosis and peritoneal mucinous carcinomatosis. A clinicopathologic analysis of 109 cases with emphasis on distinguishing pathologic features, site of origin, prognosis, and relationship to "pseudomyxoma peritonei". *Am J Surg Pathol.* 1995 Dec;19(12):1390–408.
- 16 Hoeffel C, Crema MD, Belkacem A, Azizi L, Lewin M, Arrivé L et al. Multi-detector row CT: spectrum of diseases involving the ileocecal area. *Radiographics.* 2006 Sep-Oct;26(5):1373–90.
- 17 Macari M, Balthazar EJ. CT of bowel wall thickening: significance and pitfalls of interpretation. *AJR Am J Roentgenol.* 2001 May;176(5):1105–16.
- 18 Hristova L, Soyer P, Hoeffel C, Marteau P, Oussalah A, Lavergne-Slove A et al. Colorectal cancer in inflammatory bowel diseases: CT features with pathological correlation. *Abdom Imaging.* 2013 Jun;38(3):421–35.
- 19 Murdock T, Lim N, Zenali M. Lymphangitic spread from the appendiceal adenocarcinoma to the ileocecal valve, mimicking Crohn's disease. *World J Gastroenterol.* 2015 Feb;21(7):2206–9.

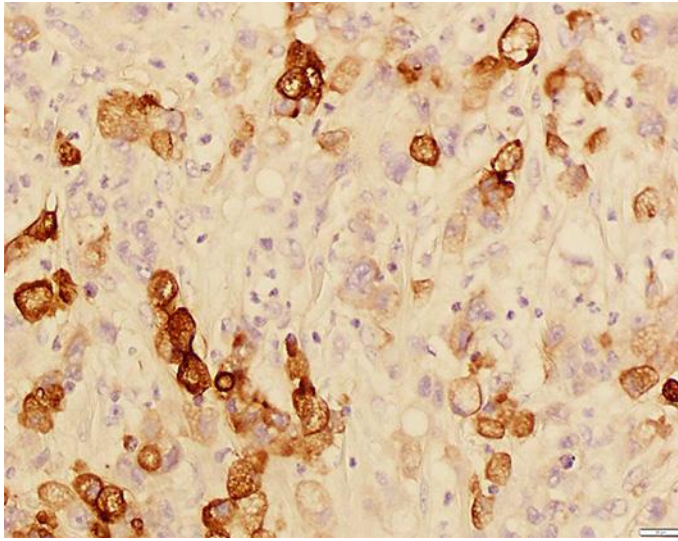


Fig. 1. Tumor cells with abundant cytoplasm full of mucin that displace the nucleus to the cell's periphery (signet ring cells). Immunohistochemically, tumor cells were positive for CK20. IHC $\times 400$

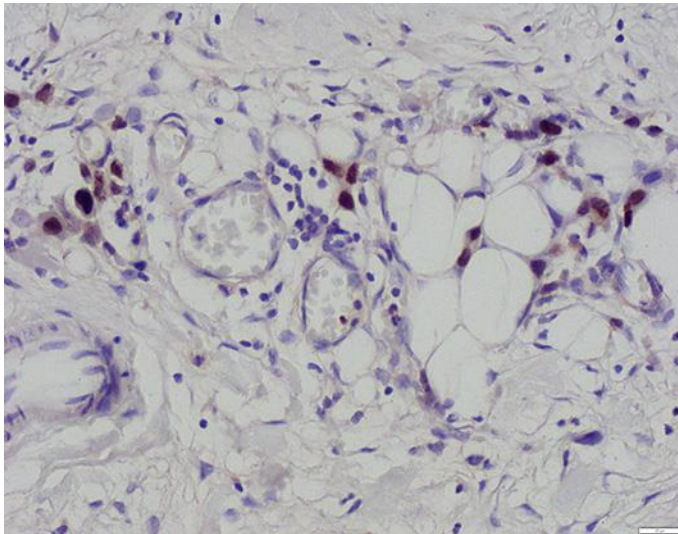


Fig. 2. Immunohistochemically, tumor cells were positive for CDX-2. IHC $\times 400$.

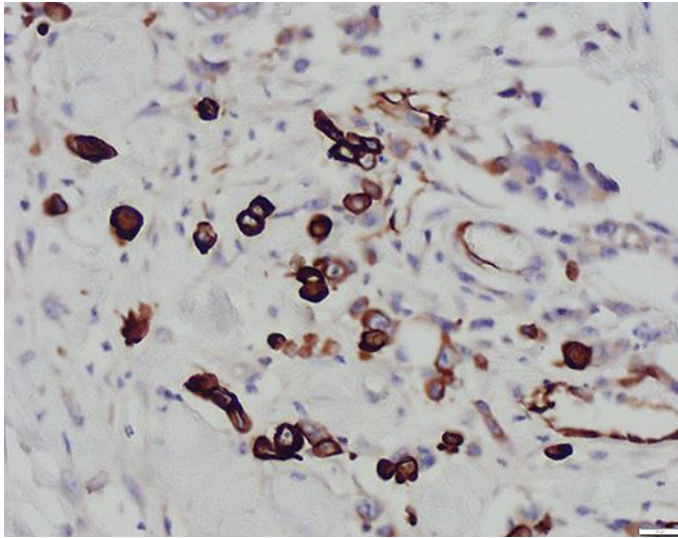


Fig. 3. Immunohistochemically, tumor cells were positive for CK7. IHC ×400.

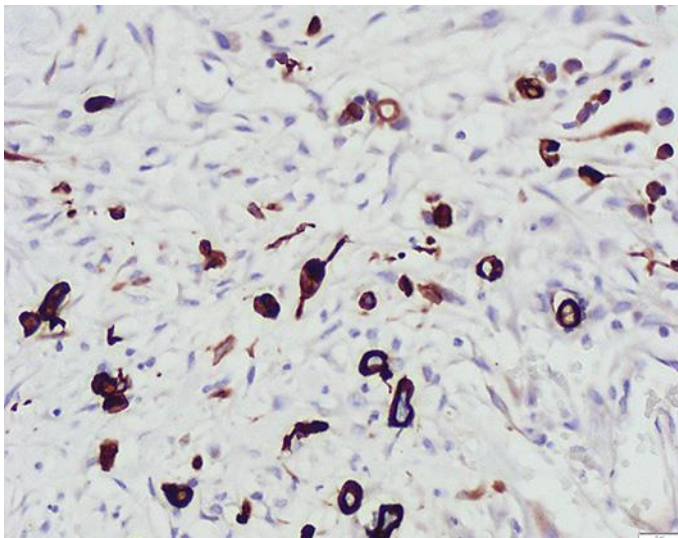


Fig. 4. Immunohistochemically, tumor cells were positive for CK19. IHC ×400.

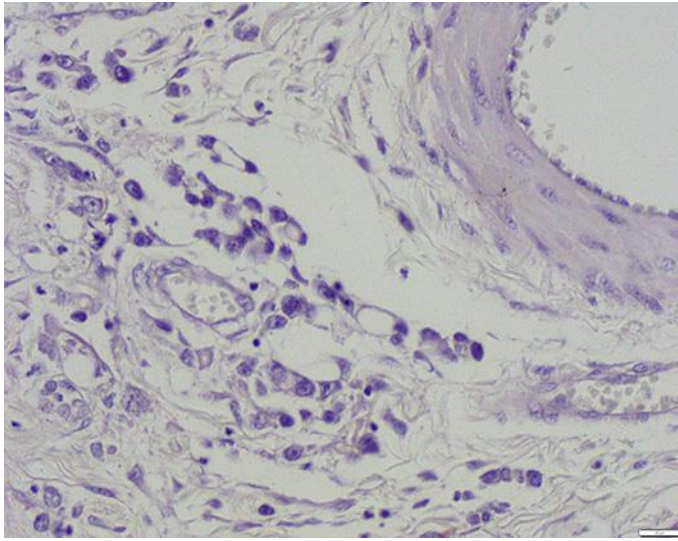


Fig. 5. Immunohistochemically, tumor cells were negative for CEA. IHC ×400.

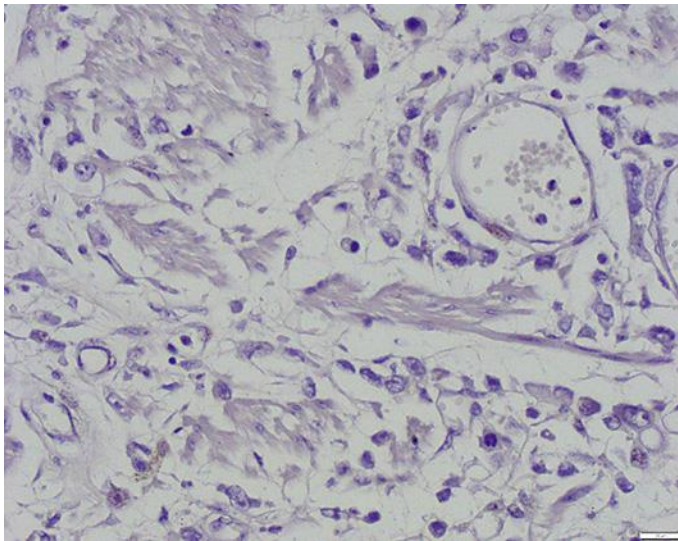


Fig. 6. Immunohistochemically, tumor cells were negative for chromogranin A. IHC ×400.