

## Case report

# Anti-infective therapy without antimicrobials: Apparent successful treatment of multidrug resistant osteomyelitis with hyperbaric oxygen therapy



Elsa Goerger<sup>a</sup>, Estelle Honnorat<sup>a,b</sup>, H el ene Savini<sup>d</sup>, Mathieu Coulange<sup>c</sup>, Eric Bergmann<sup>c</sup>, Fabrice Simon<sup>d</sup>, Piseth Seng<sup>a,b,e</sup>, Andreas Stein<sup>a,b,e,\*</sup>

<sup>a</sup> Service Des Maladies Infectieuses, Centre Hospitalo-Universitaire de la Conception, 147 boulevard Baille, 13005 Marseille, France

<sup>b</sup> Centre Interr egional de R ef erence des Infections Ost eo-articulaires M editerran ee Sud, 147 boulevard Baille, 13005 Marseille, France

<sup>c</sup> Centre De M edecine Hyperbare, P ole RUSH, H opital Sainte-Marguerite, Marseille, France

<sup>d</sup> Service de Maladies Infectieuses, H opital d'Instruction des Arm ees Laveran, 13013 Marseille, France

<sup>e</sup> Aix-Marseille Universit e, URMITE, CNRS UMR 6236, Facult e de M edecine, 27 Bd Jean Moulin, 13385 Marseille Cedex 05, France

## ARTICLE INFO

## Article history:

Received 9 May 2016

Received in revised form 16 September 2016

Accepted 17 September 2016

## Keywords:

*K. pneumoniae*

OXA-48

Carbapenemase producing

Osteoarticular infections

Osteomyelitis

Hyperbaric oxygen therapy

## Introduction

Infections due to multidrug-resistant bacteria have spread in the world and cause significant morbidity and mortality [1]. Bone and joint infection due to multidrug-resistant bacteria has become a major problem, limiting the efficacy of targeted treatment and compromising outcomes. Indeed, antimicrobial options are limited and extensive surgical procedures are required.

Adjunctive hyperbaric oxygen therapy (HBO) has been reported as an effective treatment in soft tissue infection caused by anaerobic bacteria, such as gas gangrene, necrotizing fasciitis and Fournier's gangrene. HBO has also been extensively used to improve wound healing in the treatment of diabetic foot infections and osteitis [2]. We report an apparent successful treatment of OXA-48 type carbapenemase-producing *K. pneumoniae* osteomyelitis with HBO without any concomitant antimicrobial.

## Case presentation

In December 2012, a 65-year-old French man was admitted to the infectious disease unit of the Laveran military teaching hospital in Marseille for a necrotic wound on the right foot. He treated with insulin regimens for an uncomplicated and controlled type 2 diabetes mellitus. The patient had no peripheral vascular disease. During a trip for thalassotherapy in Tunisia in November 2012, he was admitted to the emergency unit for excoriations and contusions on his right leg after a fall in a bathroom. A few days later, he was admitted to the intensive unit care (ICU) for septic shock, a complication of the skin infection on his right lower leg. The microbial analysis of blood cultures and wound swabs revealed negative. He was treated with norepinephrine and three-weeks of antimicrobial treatment i.e. amoxicillin/clavulanic acid, ofloxacin and fusidic acid. At the three weeks of his hospitalization, he was discharged from the ICU and was transferred from Tunisian hospital to the infectious disease unit of the Laveran military teaching hospital in Marseille, France.

On his arrival in Laveran hospital, he was afebrile, his pulse was 135 beats/min and he was normotensive. The physical examination showed painless ulcerations with a (7 × 6 cm) necrotic appearance on the dorsum of the right foot, (2 × 1.5 cm) on the plantar of the

\* Corresponding author at: Centre Interr egional de R ef erence des Infections Ost eo-Articulaires M editerran ee Sud; Service des Maladies Infectieuses, CHU de la Conception, 147, boulevard Baille, Marseille, France.

E-mail address: [andreas.stein@ap-hm.fr](mailto:andreas.stein@ap-hm.fr) (A. Stein).

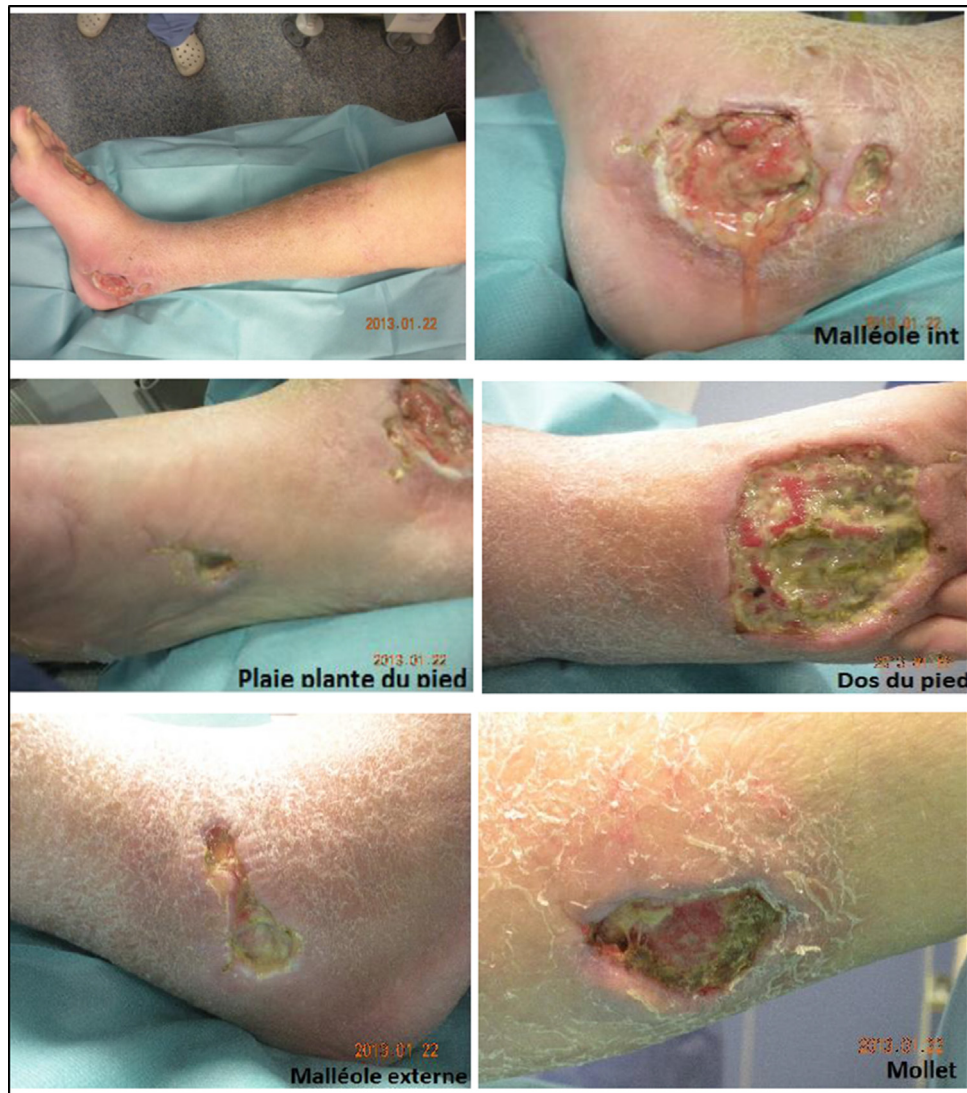


Fig. 1. Wound images on his admission.

right foot, (5.5 × 2.1 cm) internal and (6 × 2 cm) external malleoli and the (3.5 × 2 cm) right calf. The extensor digitorum longus tendons of the third, and fourth toes were exposed with a positive results of the probe-to-bone test. He also had an induration of the right leg and the distal portion and inner right thigh (Fig. 1).

Magnetic resonance imaging (MRI) of the leg showed an osteoarthritis of the midfoot with hypointense on T1 and hyperintense on T2 of midfoot and a talocrural joint effusion (Fig. 2) associated with a serious loss of skin substance at level of the dorsum foot, the lateral malleolus, the talus bone, the right foot muscles, and tenosynovitis of posterior tibial tendon (Fig. 3). Laboratory investigations revealed a high level of C-reactive protein (64.3 mg/L), a normal leukocyte count and a low hemoglobin concentration (7.5 g/L). Multiple skin and deep samples tested positive for OXA-48-type carbapenemase-producing *K. pneumoniae*. Urine and stool samples also tested positive for OXA-48-type carbapenemase-producing *K. pneumoniae*.

In December 2012, he was transferred to the reference center for bone and infectious disease in Marseille. All antimicrobials were stopped and hyperbaric oxygen treatment and wound care including a daily wound cleaning with antiseptic (povidone-iodine) covered with a sterile dressing with silver (AQUACEL® Ag Surgical dressings, ConvaTec Inc), were provided after a

multidisciplinary discussion. No topical antibacterial was used in wound care. The patient was placed in isolation during hospitalization. The clinical outcome noted a rapid improvement with persistence only of a clean and healthy wound on the back of the feet after 30 sessions of hyperbaric oxygen treatment (Fig. 4).

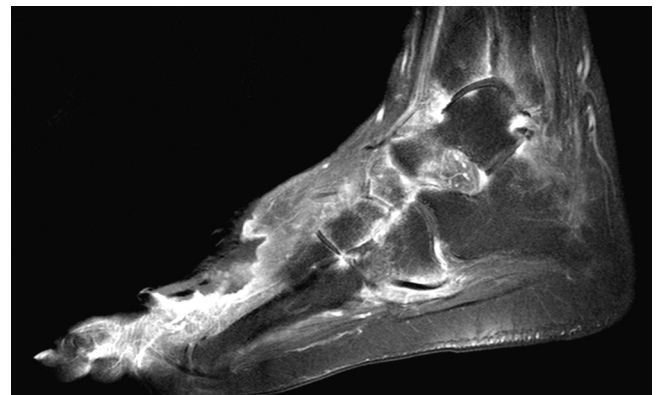
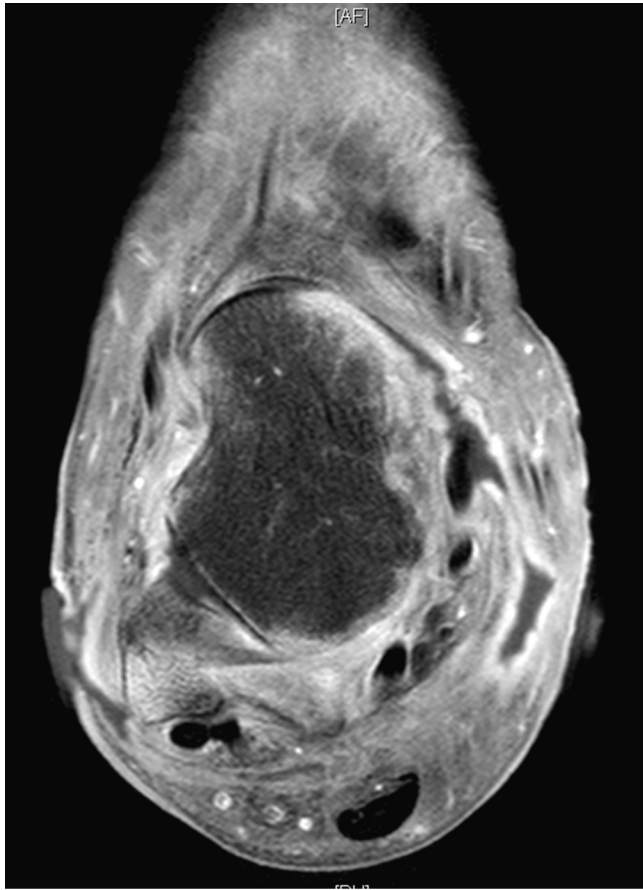


Fig. 2. Magnetic resonance imaging (MRI) of the leg showed an osteoarthritis of the midfoot and a talocrural joint effusion associated with a serious loss of skin substance at level of the dorsum foot.



**Fig. 3.** Magnetic resonance imaging (MRI) of the leg showed a tenosynovitis of posterior tibial tendon and loss of skin substance at level of the talus.

We used a multiplace hyperbaric chamber (CxPRO, COMEX®, Marseille, France) pressurized with compressed air. HBO2 was performed as usual by using local dive tables derived from the French COMEX 12, 18 and 30 tables. The chamber was pressurized to 2.8 atmospheres absolute and patients were

treated for 60 min with 100% oxygen as previously described [3]. Standard administration of HBOT was 30 sessions as previous study [4].

Treatment was given on a once-a-day basis, 5–7 days a week. Multiple bacteriological cultures of the wounds tested negative after one month of hyperbaric oxygen treatment and wound care. The cure of the presumed osteomyelitis in our case was determined by obtaining a complete healing of skin wounds, disappearance of pain, a resolution of biological inflammatory signs and by the absence of relapse at one-year follow-up. The patient was cured, but his urine and stools remained colonized with OXA-48-type carbapenemase-producing *K. pneumoniae* one year after being discharged. No secondary transmission at Laveran hospital and the reference center was detected.

## Discussion

The diagnosis of foot osteomyelitis is often confirmed by bone histopathology and culture. However, bone biopsies are unobtainable in many centers. In many cases, the diagnosis of foot osteomyelitis can be based on clinical criteria included positive results of the probe-to-bone test with MRI feature of osteomyelitis. Since chronic osteomyelitis generally requires debridement for cure, this presumed osteomyelitis may have been osteomyelitis although no pathology was available. In this report, we describe what appeared to be successful treatment of a multidrug-resistant osteomyelitis caused by OXA-48-type carbapenemase-producing *K. pneumoniae* acquired in Tunisia. Bone and joint infections due to multidrug-resistant bacteria are of increasing interest as they are extremely difficult to cure due to the lack of appropriate antimicrobials. OXA-48-type carbapenemase-producing *K. pneumoniae* bone and joint infections have a high mortality and colistin was previously the only antimicrobials option with tigecycline [1]. Only four cases of carbapenemase-producing *K. pneumoniae* osteomyelitis have been previously reported [5–7] (Table 1). All of these were treated with tigecycline or colistin and surgical treatment included two-stage exchange arthroplasty in one case, surgical debridement in one case and prosthesis removal without re-implantation in two cases. At the end of treatment, only two patients survived with increase of morbidity and disability. The antimicrobials used for all the patients were suitable for initially

**Table 1**  
Clinical characteristics, therapeutic options and clinical outcomes of the six cases of bone and joint infection caused by carbapenemase-producing *K. pneumoniae*.

Study	Age (years)	Sex	Site	Microbiologic characteristics	Bacterial co-infections	Medical Treatment	Surgical treatment	Outcome
This report	65	Male	Right leg (external malleoli and talus osteomyelitis)	<i>K. pneumoniae</i> blaKPC	No	Hyperbaric oxygen therapy	No	Cure
Gupta et al. [5]	32	Male	Right femur	<i>K. pneumoniae</i> blaNDM1 gene	No	Amikacin, Imipenem/cilastatin, Rifampin	Surgical debridement	Cure
De Sanctis et al. [6]	58	Male	Left knee arthroplasty	<i>K. pneumoniae</i> blaKPC	<i>Staphylococcus aureus</i> , <i>Alcaligenes faecalis</i> , <i>Acinetobacter baumannii</i> , <i>Candida parapsilosis</i>	Oxacillin, Piperacillin/tazobactam, Daptomycin, Doxycycline, Tigecyclin, Fluconazole; Colistin, Amikacin	Two-stage exchange arthroplasty; amputation	Death
De Sanctis et al. [6]	72	Male	Left knee arthroplasty	<i>K. pneumoniae</i> blaKPC	<i>Staphylococcus aureus</i> , <i>Proteus mirabilis</i> , <i>Acinetobacter baumannii</i> , <i>Enterococcus</i> sp.	Ciprofloxacin, Linezolid, Rifampin, Daptomycin, Vancomycin, Tigecyclin, Doxycycline, Oxacillin	Two-stage exchange arthroplasty	Death
De Sanctis et al. [6]	70	Female	Right knee arthroplasty	<i>K. pneumoniae</i> blaKPC	<i>Staphylococcus aureus</i> , <i>Streptococcus pneumoniae</i> , <i>Corynebacterium</i> sp., <i>Enterococcus</i> sp.	Vancomycin, Tigecyclin, Colistin, Ciprofloxacin, Clindamycin, Amikacin	Two-stage exchange arthroplasty, amputation and disarticulation of right hip	Cure
Córdova et al. [7]		Not mentioned	Not mentioned	<i>K. pneumoniae</i> blaKPC	Not mentioned	Antibiotherapy (no detail)	Not mentioned	Not mentioned

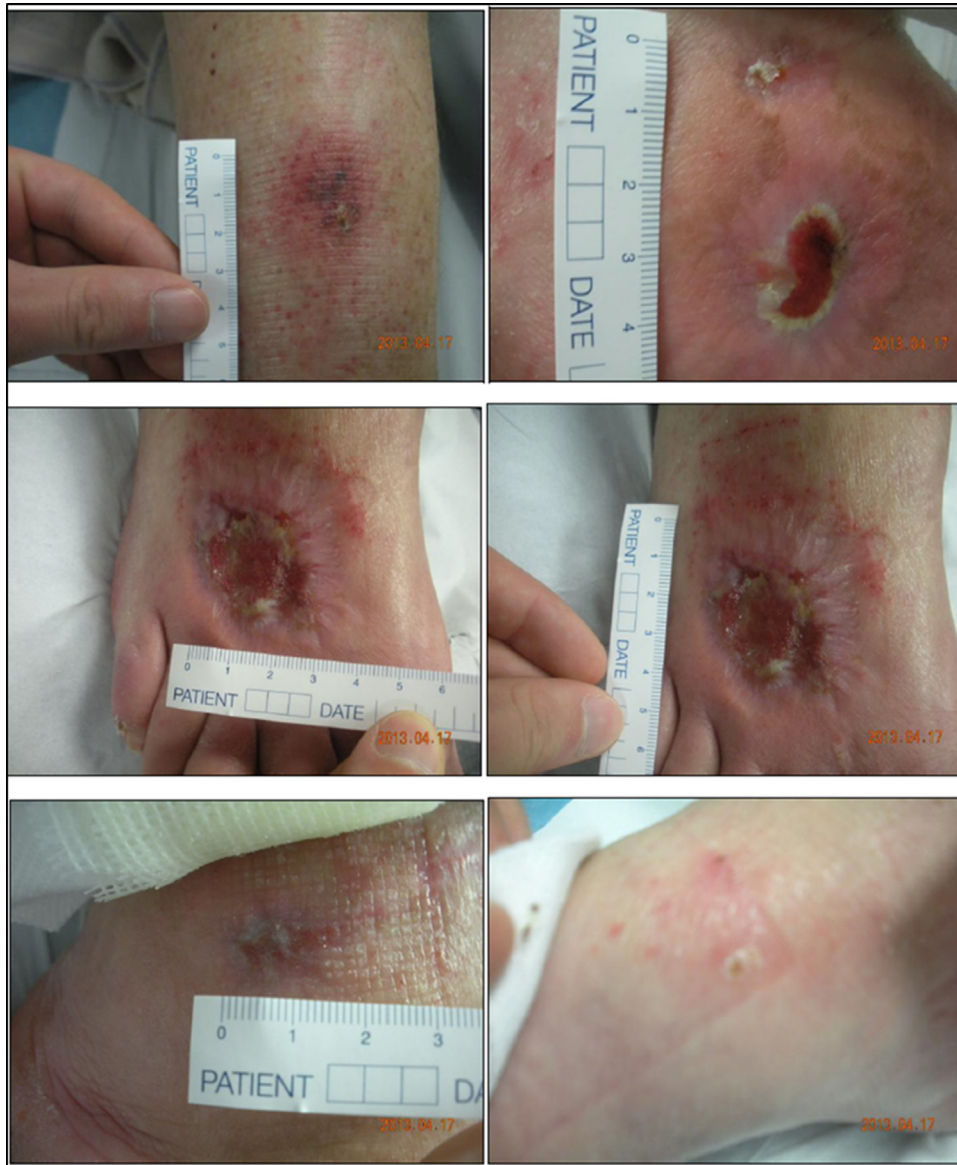

Fig. 4. Wound images at one month of thirty hyperbaric oxygen sessions.

sensitive strains. Antimicrobial treatment failure has been explained by the emergence of colistin-resistant KPC-producing *K. pneumoniae*.

Application of HBO in infectious disease is not commonly reported in the literature to date. However, this HBO therapy has been used for over sixty years in patients with cutaneous and bone infections as an adjuvant therapy including the treatment of refractory osteomyelitis [4,8,9] and the treatment of iatrogenic spinal infections [10,11]. Therapeutic effects of HBO on infections can be made by direct suppression the growth of anaerobic bacteria such as clostridia [2], and hyperoxygenation in tissues causes increase the fibroblasts and collagen proliferation, neo-vascularization of ischemic tissues and stimulation of bacterial lysis by leukocytes [2]. This last mechanism can play role in efficacy of HBO in treatment caused by other aerobic and anaerobic bacteria.

In our case, HBO combined with local care cured presumed bacterial osteomyelitis without any antimicrobials. Most of the cases of bone and joint infection in literature and those of our case

would be different. Nevertheless, when the cases of serious bone and infection with limiting the efficacy of targeted treatment and compromising outcomes, HBO should be considered a therapeutic option without the use of prolonged antimicrobial therapy or wide surgical excision or in some cases as an adjunctive treatment option. The apparent benefits of HBO as adjunctive treatment of bone and joint infection have been reported in some studies. We believe that the increasing of controlled and randomized studies would help us to finding significant effects on length of hospitalization, rapidity of wound repair, initial clinical outcome, or recurrence of infection. Despite his presumed osteomyelitis being cured, our patient's digestive and urinary tracts were still colonized by the same carbapenemase-producing organism three years after discharge.

#### Conclusions

Bone and joint infections due to multidrug-resistant bacteria are difficult to treat. Carbapenemase-producing *K. pneumoniae*

bone and joint infection is currently a therapeutic challenge in an era of increasingly difficult to treat infections. Antimicrobials and aggressive surgical procedures seem to be ineffective to date. Here we report a successful treatment without antimicrobials, only with HBO and local care. HBO is compatible with the management and prevention of multi-drug resistant infections and should be considered if antimicrobial therapy fails.

### Conflict of interest

The authors declare no conflicts of interest.

### Funding

The authors have no relevant affiliations or involvement with any organization or entity with a financial interest or conflict with the subject matter or materials discussed in the manuscript. No writing assistance was utilized in the production of this manuscript.

### Consent section

This study was approved by the institutional research ethics board (Comité de Protection des Personnes Sud Méditerranée 1), and written informed consent was obtained from the patient for publication of this case report and any accompanying images. A copy of the written consent is available for review by the Editor-in-Chief of this journal.

### Contributions section

- Dr Elsa Goerger: 1st author, clinical data collection; she has been involved in drafting the manuscript.
- Dr Estelle Honnorat: 2nd author; she has been involved in drafting the manuscript and manuscript revising.
- Dr H el ene Savini: 3rd author, clinical data verification, manuscript revising.
- Dr Eric Bergmann: 4th author, hyperbaric oxygen therapy and data verification, manuscript revising.
- Pr Mathieu Coulanges: 5th author, clinical data verification, manuscript revising.

- Pr Fabrice Simon: 6th clinical data verification, manuscript revising
- Dr Piseth Seng: 7th author, clinical data verification, manuscript revising.
- Pr Andreas Stein: last author and corresponding author, final approval of the version to be published

All authors read and approved the final manuscript

### References

- [1] Stein A, Raoult D. Colistin: an antimicrobial for the 21st century? *Clin Infect Dis Off Publ Infect Dis Soc Am* 2002;35:901–2, doi:<http://dx.doi.org/10.1086/342570>.
- [2] Kaide CG, Khandelwal S. Hyperbaric oxygen: applications in infectious disease. *Emerg Med Clin North Am* 2008;26:571–95, doi:<http://dx.doi.org/10.1016/j.emc.2008.01.005> xi.
- [3] Ouaissi M, Tran S, Mege D, Latrasse V, Barthelemy A, Pirro N, et al. Pelvic radiation disease management by hyperbaric oxygen therapy: prospective study of 44 patients. *Gastroenterol Res Pract* 2014;2014, doi:<http://dx.doi.org/10.1155/2014/108073>.
- [4] Chen C-E, Ko J-Y, Fu T-H, Wang C-J. Results of chronic osteomyelitis of the femur treated with hyperbaric oxygen: a preliminary report. *Chang Gung Med J* 2004;27:91–7.
- [5] Gupta V, Bansal N, Gupta R, Chander J. Klebsiella pneumoniae carrying bla NDM-1 gene in orthopedic practice. *Indian J Orthop* 2014;48:533–5, doi:<http://dx.doi.org/10.4103/0019-5413.139888>.
- [6] de Sanctis J, Teixeira L, van Duin D, Odio C, Hall G, Tomford JW, et al. Complex prosthetic joint infections due to carbapenemase-producing Klebsiella pneumoniae: a unique challenge in the era of untreatable infections. *Int J Infect Dis IJID Off Publ Int Soc Infect Dis* 2014;25:73–8, doi:<http://dx.doi.org/10.1016/j.ijid.2014.01.028>.
- [7] C ordova E, Lespada MI, G omez N, Paster an F, Oviedo V, Rodr iguez-Ismael C. Clinical and epidemiological study of an outbreak of KPC-producing Klebsiella pneumoniae infection in Buenos Aires, Argentina. *Enfermedades Infecc Microbiol Cl n* 2012;30:376–9, doi:<http://dx.doi.org/10.1016/j.eimc.2011.12.003>.
- [8] Delasotta LA, H anflik A, Bicking G, Mannella WJ. Hyperbaric oxygen for osteomyelitis in a compromised host. *Open Orthop J* 2013;7:114–7, doi:<http://dx.doi.org/10.2174/1874325001307010114>.
- [9] Fang RC, Galiano RD. Adjunctive therapies in the treatment of osteomyelitis. *Semin Plast Surg* 2009;23:141–7, doi:<http://dx.doi.org/10.1055/s-0029-1214166>.
- [10] Onen MR, Yuvruk E, Karagoz G, Naderi S. Efficiency of hyperbaric oxygen therapy in iatrogenic spinal infections. *Spine* 2015;40:1743–8, doi:<http://dx.doi.org/10.1097/BRS.0000000000001065>.
- [11] Ahmed R, Severson MA, Traynelis VC. Role of hyperbaric oxygen therapy in the treatment of bacterial spinal osteomyelitis. *J Neurosurg Spine* 2009;10:16–20, doi:<http://dx.doi.org/10.3171/2008.10.SPI08606>.