

# How I do it. Thoracic outlet syndrome and the transaxillary approach

Matthew Vuoncino, MD, and Misty D. Humphries, MD, Sacramento, CA

## ABSTRACT

Thoracic outlet syndrome (TOS) is a disease pattern that involves compression of neurologic venous or arterial structures as they pass through the thoracic outlet. TOS was first described as a vascular complication arising from the presence of a cervical rib. Over time, a better understanding of TOS has led to its wide range of presenting symptoms being divided into three distinct groups: arterial, venous, and neurogenic. Of the known cases, the current estimates of the incidence of neurogenic TOS, venous TOS, and arterial TOS are 95%, 3%, and 1%, respectively. The different types of TOS have completely different presentations, requiring expertise in the diagnosis, management, and treatment unique to each. We present our evaluation, diagnosis, and management method of TOS patients, with specific attention paid to the transaxillary approach. (*J Vasc Surg Cases Innov Tech* 2023;9:1-9.)

**Keywords:** Axillosubclavian thrombosis; Cervical ribs; Paget-Schroetter syndrome; Subclavian vein thrombosis; Thoracic outlet syndrome

Thoracic outlet syndrome (TOS) is characterized by a pattern of upper extremity symptoms due to compression of the neurovascular structures passing from the neck and chest to the upper extremity. TOS was first described in 1865 by Cooke<sup>1</sup> as a vascular complication arising from the presence of a cervical rib. Over time, a better understanding of TOS has led to its wide range of presenting symptoms being divided into three distinct groups: arterial, venous, and neurogenic. Of the known cases, the current estimates of the incidence of neurogenic TOS (nTOS), venous TOS (vTOS), and arterial TOS (aTOS) are 95%, 3%, and 1%, respectively.<sup>2</sup> The thoracic outlet extends medially from the lateral aspect of the first rib to the upper mediastinum and superiorly to the level of C5 (Fig 1). Three muscles comprise the two triangular spaces of the thoracic outlet: the anterior and middle scalene and subclavius muscles. The anterior and middle scalene muscles, along with the first rib, form the scalene triangle through which the subclavian artery and cervical nerve roots of the brachial plexus pass. The subclavius muscle and clavicle form the roof, and the first rib forms the base of the costoclavicular space, through

which the brachial plexus, subclavian artery, and vein pass. Anatomic variations of the scalene muscles, present in 65% of the general population, could predispose people to TOS.

vTOS is associated with axillosubclavian thrombosis (Paget-Schroetter syndrome or effort vein thrombosis), which results from repetitive injury of the subclavian vein, often in 20- to 40-year-old persons involved in high-performance athletics or who have congenital muscle abnormalities that cause vein compression.<sup>3</sup> Venous thrombosis develops when the vein becomes pinned between the subclavius muscle, first rib, and anterior scalene muscle in the dominant arm of high-performance athletes who perform repetitive shoulder movements (eg, bodybuilders, swimmers, and baseball and softball pitchers). The external compression causes inflammation, which leads to endothelial injury, fibrosis, and venous stasis. The result is venous thrombosis.<sup>4</sup>

aTOS is the product of embolization from degeneration of the subclavian artery due to extrinsic compression from a cervical rib or anomalous first rib, which causes post-stenotic dilatation and extrathoracic aneurysmal degeneration.<sup>5,6</sup> Turbulent flow within the dilated segment results in thrombus accumulation. The developing thrombus could slowly embolize to the smaller digital and forearm arteries, causing small vessel occlusion. When a more significant embolus breaks free, this can cause acute ischemia occluding the brachial, radial, or ulnar arteries. Although symptomatic aTOS shows no sex predominance, cervical ribs are more common in women.<sup>7</sup>

nTOS is a controversial diagnosis with multifactorial pathology. Patients with nTOS develop delayed symptoms from a combination of a congenital abnormality of the scalene triangle, the presence of a cervical rib or anomalous first rib, and/or repetitive or acute trauma to the neck or upper shoulder. Trauma to the scalene muscles

---

From the Division of Vascular Surgery, Department of Surgery, University of California Davis Health.

Author conflict of interest: M.D.H. is a paid consultant to Shockwave Medical Inc and Cook Medical Inc. M.V. has no conflicts of interest.

Correspondence: Misty D. Humphries, MD, Division of Vascular Surgery, Department of Surgery, University of California Davis Health, 2335 Stockton Blvd, NAOB 5001, Sacramento, CA 95811 (e-mail: [mdhumphries@ucdavis.edu](mailto:mdhumphries@ucdavis.edu)).

The editors and reviewers of this article have no relevant financial relationships to disclose per the Journal policy that requires reviewers to decline review of any manuscript for which they may have a conflict of interest.

2468-4287

© 2023 The Author(s). Published by Elsevier Inc. on behalf of Society for Vascular Surgery. This is an open access article under the CC BY-NC-ND license (<http://creativecommons.org/licenses/by-nc-nd/4.0/>).

<https://doi.org/10.1016/j.jvscit.2023.101128>

can result in hemorrhage and inflammation. Over time, the scalene muscles develop scarring, fibrosis, and shortening, which then apply pressure on the brachial plexus.<sup>8</sup> Alternatively, some patients with a predisposing muscle or bone abnormality could develop nTOS from repetitive neck strain.

## PREOPERATIVE EVALUATION

The first step to evaluating any patient with TOS is to obtain a thorough history, focusing on the patient's typical daily activities and trauma history. Each type of TOS results in subtle symptoms that patients might not have given significant attention. Specifically, in aTOS, early symptoms include exertional pain with activity similar to claudication. Patients with aTOS or nTOS might complain of occasional digit pallor. This can be misdiagnosed as Raynaud syndrome in younger patients. The presentation of nTOS is typically pain, paresthesia, and weakness. The pain can be poorly characterized. It can be localized to the shoulder, neck, or trapezius. It could also extend to the occiput and cause tension headaches, or to the face, resulting in neuralgia. It typically radiates to the medial or posterior arm and into the fourth and fifth digits, although some patients could also complain of thenar numbness. Although some patients will have pain at rest, most will describe positional triggers, such as elevation of the arms overhead.

On physical examination, it is crucial to observe the neck, shoulders, chest, and arm with the patient sitting. The neck and trapezius could be asymmetric due to muscle hypertrophy. Patients with TOS could have a forward rotation of the affected shoulder or both shoulders, resulting in a hunched-over appearance. With longstanding symptoms, they might drop the shoulder inferiorly. Evaluation of the arm could show color changes. Patients with vTOS could have a cyanotic appearance, and patients with aTOS might show localized pallor in the hand. Arm edema can extend to the shoulder and chest, and, during and after an episode of subclavian vein thrombosis, prominent subcutaneous collateral veins will develop along the anterior shoulder and chest.

To distinguish TOS from other conditions, palpation for trigger points or additional areas of muscular tenderness along the scalene and neck muscles should be performed. Patients with TOS will have point tenderness over the anterior scalene muscle, as opposed to trapezius pain with fibromyalgia or shoulder pain with rotator cuff injuries. In some patients with TOS, the anterior scalene could feel enlarged or fibrotic, or an accessory fibrous band might be palpable. It is essential to perform a thorough neurologic examination. The hands and forearms should be observed for asymmetry from muscle atrophy, which occurs in those with nTOS. The strength of the intrinsic muscles of the hand and the forearm, biceps, triceps, and shoulder muscles bilaterally should be tested.

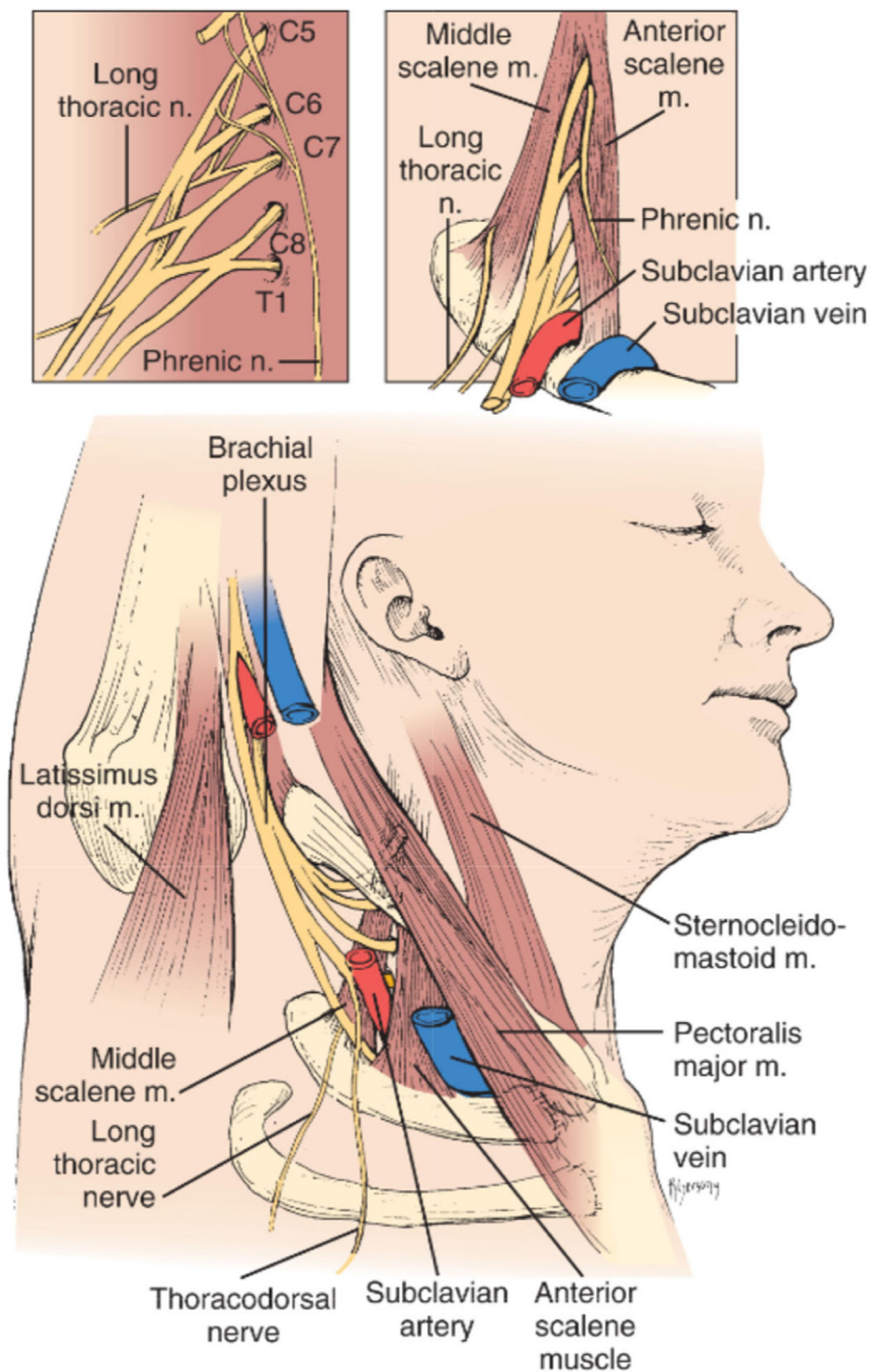
Also, sensation throughout each dermatome should be tested. The vasculature is examined by obtaining systolic blood pressure measurements in both arms. In rare cases, severe aTOS will cause a difference of >20 mm Hg between the arms. Palpation of the subclavian artery is difficult owing to its location behind the clavicle; however, a subclavian artery aneurysm could be easily palpable or even visible. Auscultation could reveal a bruit in the supraclavicular space when arterial stenosis is present. Palpation of the peripheral pulses in both arms should be compared for symmetry. Finally, provocative maneuvers such as the elevated arm stress test, Adson test, and upper arm tension test should be performed to elicit symptoms and determine the severity of the disease (Table I).

Practical imaging starts with a posteroanterior chest radiograph to evaluate for a cervical rib or anomalous first rib. Patients with J-shaped, incomplete, and high first ribs are at an increased risk of TOS. Many providers prefer a cervical spine series to look for dedicated cervical ribs; however, a chest radiograph can help determine how the cervical ribs lie compared with the first ribs. Duplex ultrasound can evaluate the patency of the supraclavicular subclavian artery and vein. In acute vTOS, the subclavian vein will be dilated and incompressible. If compressibility cannot be tested, a continuous Doppler waveform without respiratory variability obtained in the axillary vein supports the diagnosis of subclavian vein thrombosis. For patients with cervical ribs, duplex ultrasound can determine whether degeneration of the subclavian artery is present. Computed tomography angiography is typically reserved for cases of aTOS to delineate the aneurysm and for preoperative planning. Venography has a limited role in the preoperative evaluation of patients, although it can be helpful after thrombolysis or thrombectomy. Performance of provocative maneuvers during venography can demonstrate the degree of vein compression by the first rib.

## NONOPERATIVE TREATMENT OF nTOS

The initial treatment for all patients with nTOS is physical therapy (PT) with a protocol designed specifically for TOS. Lifestyle modifications, including limiting exacerbating activities, are also necessary. The best results with PT are for patients treated two to three times per week in a tailored 8- to 12-week protocol. With protocol completion, 60% to 90% of patients with nTOS will have improved and can avoid surgery.<sup>9,10</sup> The PT protocol should include the following:

- Restoration of range of motion to the entire shoulder girdle
- Improved flexibility of the upper cervical spine
- Activation and strengthening of the anterior, middle, and posterior scalene muscles, focused on maintaining posture throughout the day
- Stretching of the trapezius, sternocleidomastoid, levator scapular, and pectoralis minor muscles



**Fig 1.** Anatomy of the thoracic outlet and retropectoralis space. Reprinted, with permission, from Rutherford's Textbook of Surgery, 9th ed, chapter 121.

- Graduated resistance shoulder elevation exercises

Lidocaine injections into the anterior and middle scalene muscles under ultrasound guidance can help diagnose nTOS and determine the patient's potential

response to rib resection.<sup>11</sup> Lidocaine relaxes the muscle and temporarily relieves compression of the nerve roots. A successful block will result in temporary pain relief in the affected arm and decrease scalene tenderness. Ultrasound guidance can be used to avoid injecting the

**Table I.** Provocative maneuvers to test for thoracic outlet syndrome

Test	Maneuver	Positive test result
Adson test		
	1. Palpation of radial pulse	Diminished pulse
	2. Hyperextension and rotation of neck to ipsilateral side	Diminished pulse
	3. Deep inspiration	Diminished pulse
Upper limb tension test		
	1. Abduction of bilateral arms to 90° with elbows extended	Ipsilateral symptoms
	2. Addition of wrist dorsiflexion	Ipsilateral symptoms
	3. Addition of head tilt to elicit symptoms on contralateral side	Contralateral symptoms
Elevated arm stress test		
	1. Abduction of bilateral arms to 90° with elbows bent	Symptoms occur within 30-60 seconds of having hands overhead (symptoms will not occur for >3 minutes in those without TOS)
	2. Open and closing of hands	
TOS, Thoracic outlet syndrome.		

brachial plexus, because this causes numbness and weakness of the arm, obscuring the effect of the block on nTOS symptoms.

For patients who have sufficiently improved symptoms with lidocaine injections and want to avoid surgical intervention, botulinum toxin can also be used to provide longer term relief. Botulinum toxin will relax the anterior and middle scalene muscles, decreasing nerve compression. This is a therapeutic (as opposed to diagnostic) injection, with effects realized ~2 weeks after the injection with muscle relaxation, which lasts 3 to 6 months. This can also allow for increased participation in PT.<sup>12</sup> Botulinum toxin injections should be performed with image guidance (computed tomography or duplex ultrasound) to ensure accurate drug delivery and reduce potential severe side effects such as dysphagia.<sup>13</sup> Repeat injections over extended periods are not recommended, because they can cause scarring within the anterior scalene muscle, resulting in loss of effectiveness. A typical dose is 75 U of botulinum toxin per treatment, divided between the anterior and middle scalene muscles.

### NONOPERATIVE TREATMENT OF vTOS

Acute axillosubclavian venous thrombosis should be treated emergently with therapeutic anticoagulation, elevation, and compression. Anticoagulation therapy will not expedite the resolution of thrombus but will prevent new thrombosis from forming. The American College of Chest Physicians recommends outpatient low-molecular-weight heparin for acute deep vein thrombosis, transitioning to oral anticoagulation.<sup>14</sup> Newer oral direct thrombin or factor Xa inhibitors have yet to be tested explicitly for vTOS. Literature shows

that 50% to 85% of people treated with anticoagulation alone will have residual symptoms of tightness, numbness, intermittent paresthesia, fatigue, and/or superficial thrombophlebitis.<sup>15,16</sup> Patients with thrombosis provoked by repetitive work activity, sports, or weight lifting are more likely to have recurrent episodes of thrombosis or pain with use of the arm. These patients will have worse outcomes with anticoagulation therapy alone.<sup>17</sup> Compression therapy with elastic bandages to the level of the shoulder can relieve the symptoms of discomfort caused by edema. The elastic bandages can be changed to a compression sleeve once the initial swelling has decreased. Pharmacologic and mechanical thrombolytic therapy have emerged as first-line treatment in the acute setting. The success rate of either method has been reported at 100% if initiated within the first 7 days of symptom onset.<sup>18</sup> However, any benefit is negligible if performed >14 days after symptom onset.

### PREOPERATIVE PLANNING

The type of TOS, patient symptoms, and response to nonoperative management should determine the optimal treatment choice. Although little debate has occurred about operative intervention for aTOS, surgery for nTOS and, to a lesser extent, vTOS has remained controversial. The decision to operate and the approach for aTOS is determined by the Scher classification system (Table II). Classes 2 and 3 require arterial reconstruction, which cannot adequately be done via the transaxillary approach. In these patients, a paraclavicular approach is frequently needed. The paraclavicular approach is ideal for dissecting the entire subclavian artery and ligating branches, allowing for primary anastomosis of

**Table II.** Scher classification of surgical treatment for subclavian artery pathology

Stage	Arterial pathology	Treatment
0	Asymptomatic subclavian artery compression	No surgical treatment except for high-performance athletes or patients required to perform repetitive movements with affected arm; monitor for arterial wall degeneration
1	Subclavian artery stenosis with mild dilation but no intimal injury	Decompress thoracic outlet and reimaged subclavian artery
2	Subclavian artery aneurysm with mural thrombus	Decompress thoracic outlet and reconstruct subclavian artery
3	Arterial thrombosis or distal embolization with occlusion	Thrombectomy vs thrombolysis; decompress thoracic outlet and reconstruct subclavian artery

the subclavian artery after aneurysm resection and avoiding the placement of prosthetic grafts. In cases in which a graft is necessary, ringed polytetrafluoroethylene is ideal for preventing compression under the clavicle with overhead arm movements.

Given the controversy surrounding nTOS and vTOS, no strict indications are available for surgery.<sup>19</sup> For high-performance athletes, bodybuilders, those who perform repetitive work with the affected extremity, and those with recurrent episodes of thrombosis, thoracic decompression provides the best long-term outcomes in the setting of vTOS. Anticoagulation should be withheld before operative decompression. Patients with a significant clot burden can be bridged with enoxaparin sodium (Lovenox; Sanofi-Aventis, Paris, France) until the day of operative decompression. Patients who have received recent lytic therapy during the same or recent admissions should have their fibrinogen levels checked to ensure they do not have an increased bleeding risk during surgery. Data suggest that for patients who require lytic therapy, decompression during the same hospitalization is safe. For patients who undergo lysis where a vascular surgeon is not available, an expedited referral is ideal.

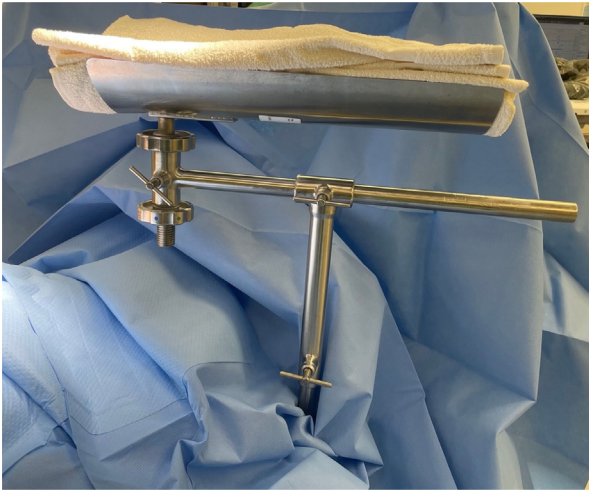
The decision to operate for patients with nTOS should be based on the patient's response to TOS-specific PT and lidocaine and/or botulinum toxin injections. Those with a plateau or recurrent symptoms could experience long-term relief with surgical decompression.<sup>20</sup> For patients undergoing surgery for nTOS, clear expectations for postoperative recovery should also be set. Individuals who smoke, patients aged >40 years, those with workers' compensation claims, and patients with long-term opioid use should be counseled because they are at an increased risk of not returning to their preinjury functional status.<sup>21-23</sup> Given the higher incidence of vTOS and nTOS in our patient population, the transaxillary approach is performed far more often at our institution. The technique can be used for all three types of TOS (ie, neurogenic, venous, and arterial); however, as stated, it is insufficient for arterial reconstruction. Additionally, an alternative approach would be preferred for patients with persistent TOS after prior transaxillary rib resection.

Our surgical technique section focuses on the transaxillary approach.

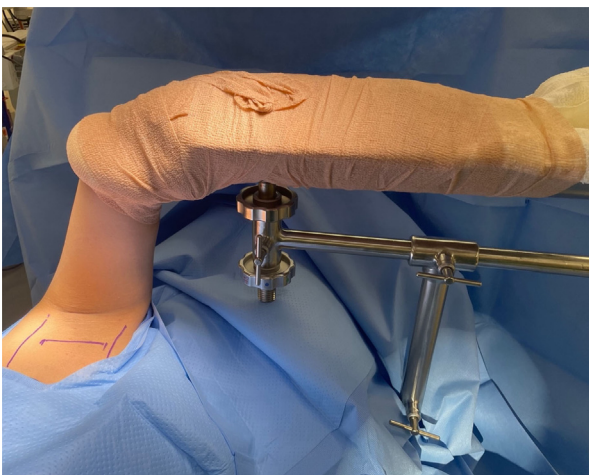### SURGICAL TECHNIQUE

The patient is positioned in the lateral decubitus position for the transaxillary approach with the affected arm up. A bean bag is used to hold the patient in place, and an axillary roll is placed under the down arm. The patient is padded appropriately to protect all bony prominences from pressure. The axillary hair is clipped, and the entire arm and hand are prepared for inclusion in the surgical field. The Machleder retractor is set up, and the tray is padded with white terry cloth towels (Fig 2). The arm is placed in a stockinette situated just above the elbow and wrapped with gauze bandages (Kerlix; Covidien, Dublin, Ireland) for additional padding. The arm is then positioned into the tray of the retractor and secured in place with a self-adherent wrap (Coban; 3M Co, St Paul, MN). The retractor provides ideal exposure to the transaxillary space that does not require manual retraction. If the retractor is unavailable, an assistant is placed on two steps to extend the arm upward during dissection. The use of manual elevation is not recommended because the person holding the arm can become fatigued over time and decrease the area of adequate exposure.

The external landmarks are marked on the skin once the arm is secured in the retractor (Fig 3). These include the latissimus dorsi muscle and pectoralis major muscle. A transverse incision is made at the base of the axillary hairline. Ideally, the incision is situated over the fourth rib, and the initial subcutaneous tissues are dissected down to the rib. It is crucial not to dissect upward into the axillary fat, because this can lead to a lymphocele or lymphatic leak. Once the chest wall is encountered, the arm is lifted in the retractor system. The connective tissue over the thoracic outlet is bluntly dissected, following the subclavian vein to the first rib. A lighted retractor and headlight are needed to provide the best visibility within the deep space of the outlet. A second retractor can be used on the opposite side of the incision to hold the tissue back and provide better exposure if the incision is small.



**Fig 2.** The Machleder retractor set up in the operating room and padded with terry cloth towels along the arm tray.



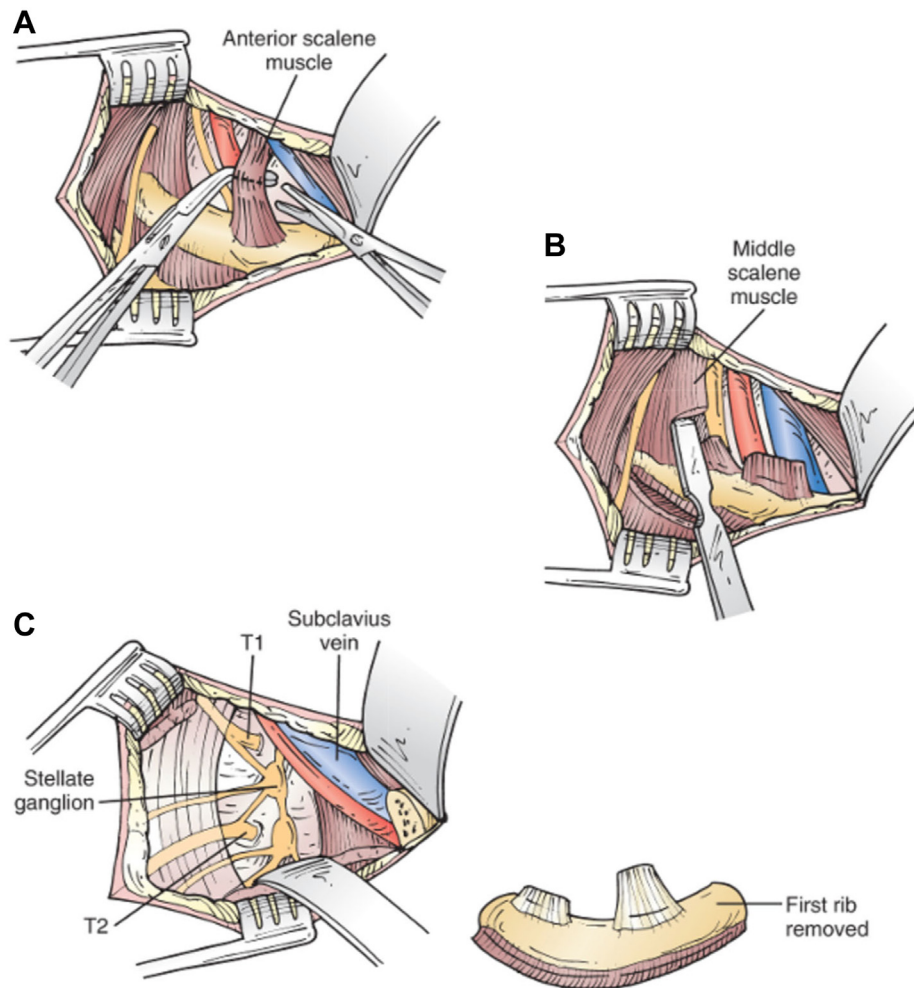
**Fig 3.** Positioning of the arm and marking of the external landmarks on the skin.

Small branches are ligated with clips as the dissection extends down the subclavian vein to the first rib. A long mechanical clip applicator will offer the best visualization. Blunt dissection of the vein using a pean clamp with cotton at the tip is carried past the first rib, and care is taken to separate the vein from the subclavius muscle. After complete vein dissection, the anterior scalene muscle is cleared of the surrounding connective tissue anteriorly and posteriorly. The phrenic nerve typically separates from the anterior scalene muscle. It enters the chest above where the anterior scalene muscle inserts on the first rib and, thus, is rarely encountered through the transaxillary approach. Next, the subclavius muscle and tendon are cut anteriorly using Metzenbaum scissors. A right-angle clamp is then passed posteriorly to the anterior scalene muscle, and the muscle is divided sharply (Fig 4, A). Electrocautery is avoided in this area, given

the proximity of the brachial plexus. The entire anterior scalene muscle does not need to be separated at once. Cutting the muscle slowly allows the surgeon to ensure that no surrounding structures are injured. The arm is lifted with the retractor at 10-minute intervals to prevent stretch on the brachial plexus. The arm is brought down for 1 to 2 minutes and the dissection resumed.

Once the subclavius and anterior scalene muscles are cut, a periosteal elevator is used to free up the intercostal muscle fibers along the lateral aspect of the first rib. The muscle fibers of the middle scalene muscle fibers are also elevated from the first rib. Using an elevator to separate the fibers can prevent injury to the long thoracic nerve by avoiding cutting those muscle fibers (Fig 4, B). A smaller periosteal elevator is then used under the first rib to separate the pleura from the inferior aspect of the rib. In cases of venous thoracic outlet syndrome, in which significant inflammation could be present, a pleural tear can easily occur. If a cervical rib is present, the periosteal elevator is also used to remove any muscle fibers from it. Although it might seem difficult to reach cervical ribs from the transaxillary approach, reports have shown that patients have good outcomes. Gelabert et al<sup>24</sup> described 70 patients who underwent transaxillary rib resection of the cervical or first rib, with a 92.3% rate of complete symptom resolution or only minor residual symptoms. This was likely due to the removal of small fibrous bands associated with cervical ribs, especially small ones. Finally, a right-angle clamp is passed under the first rib to separate all medial muscle fibers and attachments to the first rib. At that point, the anterior aspect of the first rib is transected with a Bethune rib cutter. Once the anterior portion is cut, the first rib will lift, and the pleura can be further separated inferiorly and posteriorly. The periosteal elevator is used to clear the rib's muscle fibers from the posterior aspect. The posterior part of the rib is then cut (Fig 4, C). It is essential that the rib is removed all the way to the spine but that the nerve roots are not injured during the cutting of the rib. This could require the rib to be cut more than once or in front of the nerve root, with removal of the residual rib with a first rib rongeur. The cervical rib can also be removed with the rongeur. Hemostasis can be achieved with packing, and the pleura should be inspected for tears. Filling the wound bed with normal saline and checking for air bubbling in the fluid during ventilation can be a helpful method to inspect for any tears. When a pleural tear is identified, a 19F round Blake drain can be placed to a pleural vacuum if the tear is large. For tiny pleural tears, air can be evacuated with a red rubber catheter placed in the pleura, keeping the end underwater after the arm is brought down.

The transaxillary approach has some disadvantages. Any significant arterial or venous reconstruction cannot be performed via the transaxillary approach. Similarly, the approach provides poor visualization of these critical



**Fig 4.** Steps of first rib removal. **A**, Sharp division of the anterior scalene muscle using a right-angle clamp to protect the subclavian artery. **B**, Elevation of the middle scalene muscle off the first rib, with avoidance of the long thoracic nerve. **C**, Removal of the rib with preservation of the brachial plexus nerves. Reprinted, with permission, from Rutherford's Textbook of Surgery, 9th ed, chapter 121.

structures proximally as they dive into the thorax. From this approach, proximal control of iatrogenic vascular injury can be troublesome and converting to another approach will require repositioning the patient. Should injury to the subclavian artery occur, proximal control using endovascular balloon occlusion either from femoral or upper extremity access can be helpful. Additionally, the surgical field can often become distorted, which could necessitate claviclectomy to facilitate arterial or venous reconstruction.

#### POSTOPERATIVE CARE

Postoperative pain control can be the central issue in most cases. Multimodal therapy for pain control should be used, including anti-inflammatory drugs, lidocaine patches, and heat and ice. Opioid narcotics can be used but should be tapered appropriately, and patients might need to be sent home with a short course.

Patients with longstanding pain with the use of chronic opioid medication might need to return home with a higher dose and instructions to taper over 6 weeks. For these patients, a pain taper schedule or pain contract should be set up before surgery, and clear expectations should be set with the patient for long-term pain control, if needed.

When a drain is placed in the chest for a pleural tear, it is transitioned from suction to a water seal overnight. The drain is removed if a chest radiograph on postoperative day 1 shows no evidence of a pneumothorax. All patients should start TOS-specific PT within 7 to 10 days after surgery. PT should include soft tissue massage to prevent scarring around the brachial plexus and mobilization to ensure patients have a full range of motion. PT should continue for 6 to 8 weeks to ensure the patients return to optimal function and to limit recurrent symptoms in the long term.

The importance of setting long-term expectations for people with nTOS regarding their ability to perform activities that evoked their symptoms preoperatively cannot be emphasized enough. Full function can be achieved in young, healthy patients with a short duration of symptoms; however, most people with nTOS will have had severe trauma that has rendered the affected side different for life. Decompression relieves the compression on the nerve, and PT treats the surrounding muscles, but a return to strenuous activity will not be possible for older patients with longstanding symptoms. Symptoms will recur in 30% to 35% regardless of the method of surgical decompression. Recurrent pain is more common in people with longstanding pain preoperatively and is likely activity-related, reiterating the need for lifestyle changes.

Patients with vTOS should begin anticoagulation therapy again after 48 hours. Interrogation of the subclavian vein by venography after decompression is performed in all patients. Although immediate venography in the operating room after surgical decompression has been described as safe, the need to reposition patients after transaxillary resection and the risk of bleeding has led us to perform venography ~5 to 7 days after the initial surgery.<sup>25,26</sup> We do not stop oral anticoagulation for venography. Minimally invasive endovascular techniques are preferred to extensive reconstruction because the long-term patency of the subclavian vein with patch angioplasty is unclear, with 53% of patients experiencing postoperative complications and as many as 22% requiring a second procedure.<sup>27</sup> No matter when venography is performed, balloon angioplasty of the residual stenosis is appropriate, and intravascular ultrasound could be helpful to characterize the stenosis fully.<sup>28</sup> Stent placement in the thoracic outlet should be avoided even after decompression. The primary patency of subclavian vein stents is <60% at 2 years, and, in active young patients, the risk of stent thrombosis is high.<sup>29,30</sup>

## CONCLUSIONS

Although patients present with different types of TOS, each requiring expertise in diagnosis and management, the transaxillary approach can decompress the thoracic outlet for all types of TOS, with certain limitations. In addition, many vascular providers are comfortable treating vTOS and aTOS; however, experience with all three types is essential for the treating surgeon to achieve superb outcomes. Therefore, we recommend that patients and providers consider treatment at high-volume centers. For patients who are not able to travel, the present guide to the transaxillary approach can help surgeons achieve good outcomes.

## REFERENCES

1. Coote ST. Bartholomew's Hospital. Good recovery in the case of recent removal of an exostosis from the transverse process of one of the cervical vertebrae. *Lancet* 1861;77:409.

2. Illig KA, Rodriguez-Zoppi E, Bland T, Muftah M, Jospitre E. The incidence of thoracic outlet syndrome. *Ann Vasc Surg* 2021;70:263-72.
3. Urschel HC, Razzuk MA. Paget-Schroetter syndrome: what is the best management? *Ann Thorac Surg* 2000;69:1663-8; discussion: 1668-1669.
4. Zell L, Kindermann W, Marschall F, Scheffler P, Gross J, Buchter A. Paget-Schroetter syndrome in sports activities—case study and literature review. *Angiology* 2001;52:337-42.
5. Coote H. Exostosis of the left transverse process of the seventh cervical vertebra, surrounded by blood vessels and nerves; successful removal. *Lancet* 1861;1:19861.
6. Durham JR, Yao JS, Pearce WH, Nuber GM, McCarthy WJ. Arterial injuries in the thoracic outlet syndrome. *J Vasc Surg* 1995;21:57-69; discussion: 70.
7. Haven H. Neurocirculatory Scalenus Anticus syndrome in the presence of Developmental Defects of the first rib. *Yale J Biol Med* 1939;11:443-8.
8. Machleder HI, Moll F, Verity MA. The anterior scalene muscle in thoracic outlet compression syndrome. Histochemical and morphometric studies. *Arch Surg* 1986;121:1141-4.
9. Novak CB, Collins ED, Mackinnon SE. Outcome following conservative management of thoracic outlet syndrome. *J Hand Surg Am* 1995;20:542-8.
10. Lindgren KA. Conservative treatment of thoracic outlet syndrome: a 2-year follow-up. *Arch Phys Med Rehabil* 1997;78:373-8.
11. Torriani M, Gupta R, Donahue DM. Sonographically guided anesthetic injection of anterior scalene muscle for investigation of neurogenic thoracic outlet syndrome. *Skeletal Radiol* 2009;38:1083-7.
12. Jordan SE, Ahn SS, Freischlag JA, Gelabert HA, Machleder HI. Selective botulinum chemodenervation of the scalene muscles for treatment of neurogenic thoracic outlet syndrome. *Ann Vasc Surg* 2000;14:365-9.
13. Christo PJ, Christo DK, Carinci AJ, Freischlag JA. Single CT-guided chemodenervation of the anterior scalene muscle with botulinum toxin for neurogenic thoracic outlet syndrome. *Pain Med* 2010;11:504-11.
14. Kearon C, Akl EA, Comerota AJ, Prandoni P, Bounameaux H, Goldhaber SZ, et al. Antithrombotic therapy for VTE disease: antithrombotic therapy and prevention of thrombosis, 9th ed: American College of Chest Physicians evidence-based Clinical Practice Guidelines. *Chest* 2012;141(2 Suppl):e419S-96S.
15. Archie M, Rigberg D. Vascular TOS—Creating a protocol and Sticking to it. *Diagn (Basel)* 2017;7:34.
16. Azakie A, McElhinney DB, Thompson RW, Raven RB, Messina LM, Stoney RJ. Surgical management of subclavian-vein effort thrombosis as a result of thoracic outlet compression. *J Vasc Surg* 1998;28:777-86.
17. Berzaczy D, Popovic M, Reiter M, Puchner S, Weber M, Minar E, et al. Quality of life in patients with idiopathic subclavian vein thrombosis. *Thromb Res* 2010;125:25-8.
18. Tsekouras N, Comerota AJ. Current trends in the treatment of venous thoracic outlet syndrome: a comprehensive review. *Interv Cardiol* 2014;6:103-18.
19. Dengler NF, Ferraresi S, Rochkind S, Denisova N, Garozzo D, Heinen C, et al. Thoracic outlet syndrome Part I: systematic review of the literature and consensus on anatomy, diagnosis, and classification of thoracic outlet syndrome by the European association of Neurosurgical Societies' Section of peripheral nerve surgery. *Neurosurgery* 2022;90:653-67.
20. Chandra V, Olcott C, Lee JT. Early results of a highly selective algorithm for surgery on patients with neurogenic thoracic outlet syndrome. *J Vasc Surg* 2011;54:1698-705.
21. Landry GJ, Moneta GL, Taylor LM, Edwards JM, Porter JM. Long-term functional outcome of neurogenic thoracic outlet syndrome in surgically and conservatively treated patients. *J Vasc Surg* 2001;33:312-7; discussion: 317-319.
22. Likes KC, Orlando MS, Salditch Q, Mirza S, Cohen A, Reifsnnyder T, et al. Lessons Learned in the surgical treatment of neurogenic thoracic outlet syndrome over 10 Years. *Vasc Endovascular Surg* 2015;49:8-11.
23. Orlando MS, Likes KC, Mirza S, Cao Y, Cohen A, Lum YW, et al. A decade of excellent outcomes after surgical intervention in 538 patients with thoracic outlet syndrome. *J Am Coll Surg* 2015;220:934-9.



