

Familial transverse testicular ectopia unrelated to persistent Müllerian duct syndrome

Eiji Hisamatsu, Shizuko Takagi, Yoshikiyo Nakagawa, Yoshifumi Sugita

Department of Urology, Kobe Children's Hospital, Kobe, Japan

ABSTRACT

Transverse testicular ectopia (TTE) is rare. Although several familial cases of TTE have been reported, most of them were associated with persistent Müllerian duct syndrome (PMDS), which may be inherited as an autosomal-recessive or X-linked recessive trait. We experienced two brothers with TTE unrelated to PMDS. A genetic etiology may be involved even in TTE unrelated to PMDS.

Key words: Inguinal hernia, nonpalpable testis, transverse testicular ectopia

INTRODUCTION

Transverse testicular ectopia (TTE) is rare. Although several familial cases of TTE have been reported, most of them were associated with persistent Müllerian duct syndrome (PMDS). We report our experience with two brothers with TTE unrelated to PMDS.

CASE REPORTS

Case 1

A 1-month-old boy was referred with a right hydrocele testis and a left nonpalpable testis. After a 7-month period of observation, he presented with a right inguinal hernia and a left nonpalpable testis. The right testis was located in the scrotum. At the time of surgery, left inguinal exploration was initially performed for the nonpalpable testis. When the left testis was delivered through the internal inguinal ring, the right testis could not be palpated in the scrotum. Laparoscopy was performed through an

infraumbilical incision. No Müllerian duct remnant was found. Subsequently, right inguinal exploration revealed that the testes were connected by a common vas deferens [Figure 1a]. The tunica albuginea of each testis was rough. A bilateral testis biopsy was performed. Then, both testes were brought down through the right inguinal canal and each was placed on its respective side of the scrotum. The biopsy specimen revealed normal testicular tissue. The karyotype was 46,XY. Both testes were located in the scrotum 3 years after the surgery. Testicular atrophy was not recognized.

Case 2

An 8-month-old boy (the younger brother of Case 1) was referred with a left inguinal hernia and a right nonpalpable testis. The left testis was located in the scrotum. Diagnostic laparoscopy was performed initially. This revealed that the right spermatic vessels and the vas deferens ran toward the left internal inguinal ring. The right testis was located just cephalad to the internal inguinal ring. No Müllerian duct remnant was found. Subsequently, left inguinal exploration revealed that the testes were connected by a common vas deferens. The tunica albuginea of each testis was as rough as that of Case 1 [Figure 1b]. Testis biopsy was not performed. Both testes were brought down through the left inguinal canal and each was placed on its respective side of the scrotum. The karyotype was 46,XY. Both testes were located in the scrotum 5 months after the surgery. Testicular atrophy was not recognized.

DISCUSSION

TTE is an uncommon form of ectopic testis. Several theories of TTE have been proposed. Müllerian duct remnants may mechanically inhibit testicular descent.^[1] However, no

For correspondence: Dr. Eiji Hisamatsu,
Department of Urology, Kobe Children's Hospital, 1-1-1
Takakuradai Suma-ku Kobe, Hyogo 654-0081, Japan.
E-mail: hisamatsu_kch@hp.pref.hyogo.jp

Access this article online	
Quick Response Code:	Website: www.indianjurol.com
	DOI: 10.4103/0970-1591.85446

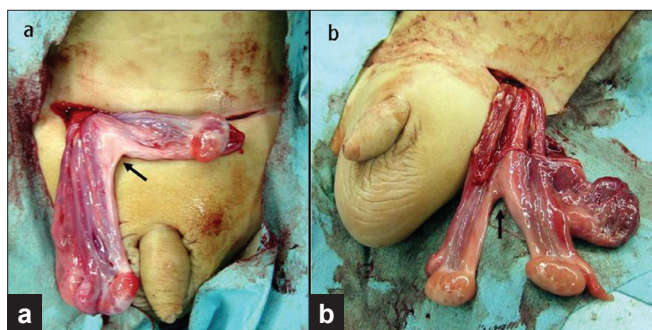


Figure 1: Inguinal exploration revealed two testes connected by a common vas deferens (arrow) in the older brother (a) and the younger brother (b). Each finding appears to be symmetrical

Müllerian duct remnant was found on laparoscopy in our cases. Fusion of the Wolffian ducts is also considered a plausible mechanism for cases such as ours.^[1] The common vas deferens initially appeared to be a Müllerian duct remnant, as shown in Figure 1. However, our cases are unlikely to be PMDS because appendices testis were found. The cause of PMDS is considered to be lack of Müllerian-inhibiting substance (MIS) synthesis or a defective MIS receptor.^[2,3] The presence of the appendices testis indicates that the MIS functioned well during the embryologic development.

Although some familial cases of TTE have been reported, most of them were associated with PMDS. There are few reports of familial TTE unrelated to PMDS. PMDS may be inherited as an autosomal-recessive or X-linked-recessive trait.^[2,3] Wuerstle *et al.* reported two brothers among nonidentical triplets who had TTE without Müllerian duct remnant.^[4] Our cases suggest that a genetic etiology is involved even in TTE unrelated to PMDS. The mode

of inheritance is not clear in our cases because there was no family history of TTE except for the affected brothers.

Various procedures have been described for the treatment of TTE. We performed a modified Ombrédanne operation.^[5] Orchiopexy could be performed without dividing the fused spermatic vessels and vasa deferens by this procedure.

In conclusion, TTE should be considered when an inguinal hernia and contralateral nonpalpable testis are present. A modified Ombrédanne operation is useful for TTE because it can avoid the injury of the spermatic vessels and vas deferens. A genetic etiology may be involved in TTE unrelated to PMDS.

REFERENCES

1. Karnak I, Tanyel FC, Akçören Z, Hiçsönmez A. Transverse testicular ectopia with persistent müllerian duct syndrome. *J Pediatr Surg* 1997;32:1362-4.
2. Diamond DA. Sexual differentiation: normal and abnormal. In: Wein AJ, editor. *Campbell-Walsh Urology*. 9th ed. Philadelphia: Saunders; 2007. p. 3826-7.
3. Bouvattier C. Disorders of sex development: Endocrine aspects. In: Gearhart JP, Rink RC, Mouriquand P, editors. *Pediatric Urology*. 2nd ed. Philadelphia: Saunders; 2010. p. 473
4. Wuerstle M, Lesser T, Hurwitz R, Applebaum H, Lee SL. Persistent müllerian duct syndrome and transverse testicular ectopia: Embryology, presentation, and management. *J Pediatr Surg* 2007;42:2116-9.
5. Pavão JM, Gonzaga RA, Cardoso JA, Ferreira A. Transverse testicular ectopia corrected by a modified Ombrédanne operation. *J Urol* 1984;132:1194.

How to cite this article: Hisamatsu E, Takagi S, Nakagawa Y, Sugita Y. Familial transverse testicular ectopia unrelated to persistent Mullerian duct syndrome. *Indian J Urol* 2011;27:397-8.

Source of Support: Nil, **Conflict of Interest:** None declared.