

Primary tuberculosis of the appendix: A common disease with rare location - a rare case report from rural India

 Mani Krishna,¹  Seema Dayal,¹  Adesh Kumar²

¹Department of Pathology, Uttar Pradesh University of Medical Sciences, Saifai, Etawah, India

²Department of Pulmonary Medicine, Uttar Pradesh University of Medical Sciences, Saifai, Etawah, India

ABSTRACT

Tubercular appendicitis is the appendicular infection with tubercular bacillus, which develops as an extension of ileocecal infection. Tuberculosis is either primary or secondary. Primary tuberculosis of the appendix is uncommon. Diagnosis is made by histopathological examination of the resected appendix. We report a rare case of tubercular appendicitis diagnosed on histopathology. Primary Tuberculosis of the appendix is a clinical rarity. Hence, it is being reported. The case report in this study emphasizes the importance of submitting all appendectomy specimens for histopathological examination and the occurrence of primary tuberculosis at a rare site, such as the appendix.

Keywords: Appendix; tuberculosis (TB); histopathology.

Cite this article as: Krishna M, Dayal S, Kumar A. Primary tuberculosis of the appendix: A common disease with rare location - a rare case report from rural India. *North Clin Istanbul* 2020;7(3):298–301.

Tuberculosis is endemic in India, and its assembles about one–fifth of the global incidence [1]. The causative agent for the tuberculosis is *Mycobacterium tuberculosis*. It primarily involves the lung and causes pulmonary tuberculosis. The other frequent sites which cause extrapulmonary tuberculosis include male and female genital tract, gastrointestinal system and meninges [2]. The prevalence of appendicular tuberculosis varies from 0.1% to 3% of the cases [3]. Primary appendicular tuberculosis is rare in our country, where tuberculosis is very common. Appendicular tuberculosis may be primary or secondary.

Tuberculosis of gastrointestinal tract most commonly involves the ileocecal region. The rarity of appendicular involvement is due to minimal contact of appendicular mucosa with the intestinal contents. Here, we have reported a case of tubercular appendicitis for its rare occurrence. Diagnosis of the primary

tubercular appendicitis ideally needs exclusion of involvement of other organs. We searched extensively by clinical, radiological and other relevant investigations for the exclusion of secondary involvement. In the present case, no foci of tuberculosis were found elsewhere in the body.

CASE REPORT

A young 18 years old female came to the outpatient department. She presented with acute abdominal pain in the right iliac fossa. She had no past history of tuberculosis. Her vital systems were normal. On palpation of abdomen tenderness in the right iliac fossa was noted. Complete Hemogram was normal except neutrophilic leukocytosis. The chest radiograph was normal. Other relevant haematological and biochemical investigations were within normal limits. Her HIV status was nil. Ul-



Received: April 15, 2019 *Accepted:* October 03, 2019 *Online:* April 13, 2020

Correspondence: Dr. Seema DAYAL. Uttar Pradesh University of Medical Sciences, Saifai, Etawah (U.P) India.
Tel: +91 05688 276564 e-mail: seemadayal5@gmail.com

© Copyright 2020 by Istanbul Provincial Directorate of Health - Available online at www.northclinist.com

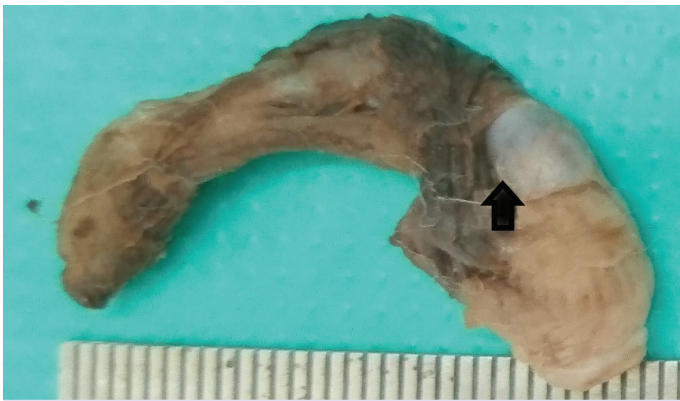

FIGURE 1. Gross picture of the appendix.

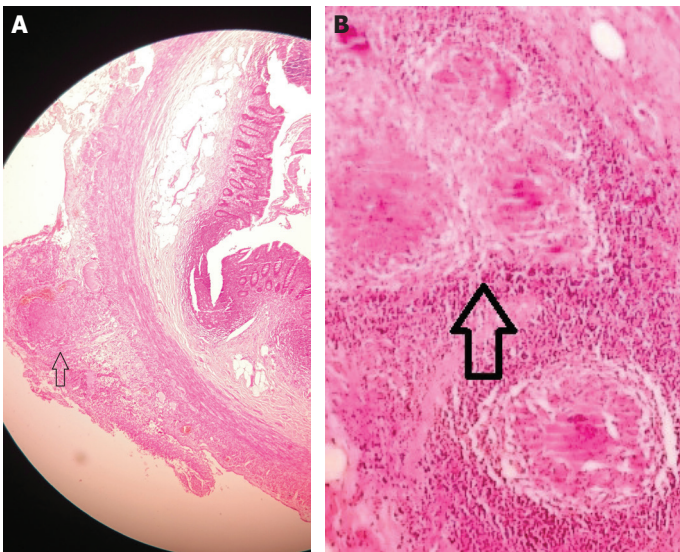


FIGURE 2. (A) H&E (4x) stained section of appendix showing mucosa, submucosa, serosa near to that is the presence of poorly formed epithelioid cell granulomas. **(B)** H&E (10x) stained section of appendix showing poorly formed epithelioid cell granulomas.

trasonography reported an inflamed, oedematous blind loop in the right iliac fossa. Appendicitis was the clinical diagnosis; hence, appendectomy was planned. Intraoperative appendix was found to be inflamed. The resected appendectomy specimen was sent for histopathology. On gross, the appendix was measuring 6 cm in length and inflamed. One patchy grey/white area was identified measuring 0.5x0.5 cm (Fig. 1) on cutting open the lumen was obliterated due to a fecolith.

On microscopic examination, Hematoxylin and Eosin (H&E) stained sections revealed the mucosa, submucosa and serosa along with tubercular granulomas in the vicinity of serosa (Fig. 2a) consisting of

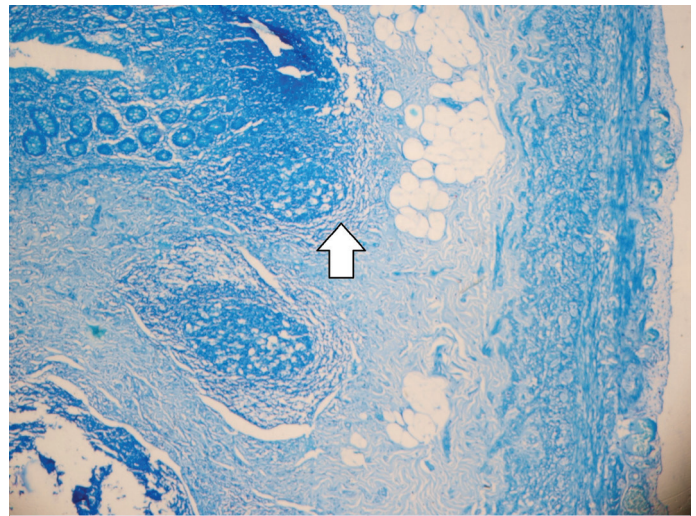


FIGURE 3. Ziehl Neelsen (4x) stained section of appendix showing mucosa, submucosa with lymphoid follicles and serosa and absence of tubercular bacilli.

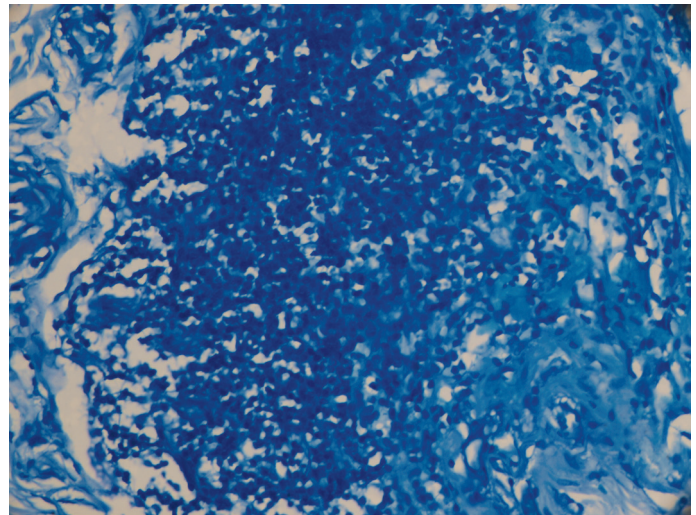


FIGURE 4. Ziehl Neelsen (100x) stained section of appendix showing the absence of tubercular bacilli.

poorly formed epithelioid cells granulomas and caseous necrosis (Fig. 2b). Ziehl Neelsen (ZN) stain for acid fast bacilli (AFB) was noncontributory (Fig. 3, 4). Based on location and histopathological examination, it was diagnosed as tubercular appendicitis Patient was started on antitubercular therapy for nine months (2HRZE/7HR) viz; nine months regime drug treatment having isonizid, rifampicin, pyrazinamide and ethambutol for two months followed by isonizid, rifampicin and ethambutol for seven months. The patient responded well to the treatment.

Informed consent was taken from the patient.

DISCUSSION

The appendix is a finger-like blind-ended tube connected to the cecum, which ranges from 2–20 cm and averages 6–9 cm in length. The appendicular obstruction may also occur because of obstruction.

Tubercular appendicitis is a rare manifestation of the appendix. Corbin was first to notice tubercular appendicitis. Deaver reported 16 cases of tubercular appendicitis (7610 appendectomies). Tauro et al. [3] reported appendix being primary tuberculosis. We have found a single case of primary tubercular appendicitis, which was diagnosed and treated with anti-tubercular drugs.

In non-pulmonary tuberculosis, gastrointestinal tuberculosis is common in India. This may arise in several ways, such as first tubercular bacilli, may enter the intestinal tract through the ingestion of infected milk or sputum. Tubercle bacilli may also enter into portal circulation or hepatic artery to involve solid organs like liver, pancreas and spleen. Another pathway is hematogenous spread from tubercular foci from elsewhere in the body to abdominal solid organs, kidney, lymph nodes and peritoneum. Sometimes direct spread to peritoneum is from infected adjacent foci, including fallopian tube, adnexa, psoas abscess and secondary to tubercular spondylitis. Another route of spread is through lymphatic channels from infected nodes. The commonest site of tubercular infiltration is ileocaecal but appendix infiltration with tubercular bacilli is rare, occurs via caecum [4, 5]. Appendicular tuberculosis may be primary or secondary. Primary appendicular tuberculosis is rare whereas secondary tuberculosis is sequel of primary pulmonary tuberculosis. Although the ileocecum is involved in over 40% of the cases of abdominal tuberculosis, the appendix is involved in about 1%. Appendicitis is clinically appreciated as acute or chronic appendicitis, sometimes diagnosed incidentally [6, 7].

Diagnosis of gastrointestinal tuberculosis is often overlooked because of its variable mode of insidious presentation with no specific pathognomy signs [8]. Due to fewer number of diagnosed and reported cases of the appendicular tuberculosis, clinical, laboratory and radiological investigations are not so significant in diagnosis and a presumptive diagnosis of tuberculosis is difficult to make [9]. Diagnosis is confirmed on histopathology examination. Surgery is advocated as the treatment of choice for tuberculosis of the appendix to avoid inflammation, which cannot be done

by antituberculous drugs. Anti-tuberculosis drugs are administered along with surgical treatment to control local complications, such as sinus formation [10]. The present case was also treated with antitubercular therapy for nine months (2HRZE/7HR) and tuberculosis resolved.

This case report highlights tuberculosis of appendix a rare site for tuberculosis to occur. Appendicular tuberculosis may mimic acute appendicitis. Drugs should be provided to prevent complications. Therefore, in all appendicitis cases, histopathological examination should be carried out and pathologists should keep in mind this rare possibility of tubercular infection.

Conclusion

Although the tubercular appendicitis is a rare disease even in the endemic area, surgeons and pathologists should be aware of the possibility. An antitubercular treatment regime should be started. Treatment of tubercular appendicitis is beyond surgical intervention. Hence, in all appendicitis cases, histopathological examination of the resected appendix is a must and pathologists should keep in mind of this rare possibility of tubercular infection.

Informed Consent: Written informed consent was obtained from the patient for the publication of the case report and the accompanying images.

Conflict of Interest: No conflict of interest was declared by the authors.

Financial Disclosure: The authors declared that this study has received no financial support.

Authorship Contributions: Concept – MK; Design – SD; Supervision – AK; Materials – MK; Data collection and/or processing – MK; Analysis and/or interpretation – SD; Literature review – SD; Writing – MK; Critical review – MK.

REFERENCES

1. WHO. Global Tuberculosis Report 2014. World Health Organization: Geneva. Available at: <https://apps.who.int/iris/handle/10665/137094>. Accessed Apr 6, 2020.
2. Park SW, Lee HL, Lee OY, Jeon YC, Han DS, Youn BC, et al. A case of appendicular tuberculosis presenting as acute appendicitis. [Article in Korean]. *Korean J Gastroenterol* 2007;50:388–92.
3. Tauro LF, Aithala PS, George C, Hanumanthappa, Martis J. Primary Tuberculosis of the Appendix. *Oman Med J* 2010;25:e003.
4. Singh MK, Arunabh, Kapoor VK. Tuberculosis of the appendix—a report of 17 cases and a suggested aetiopathological classification. *Postgrad Med J* 1987;63:855–7.
5. Rasheed S, Zinicola R, Watson D, Bajwa A, McDonald PJ. Intra-abdominal and gastrointestinal tuberculosis. *Colorectal Dis* 2007;9:773–83.

6. Shah RC, Mehta KN, Jalundhwala JM. Tuberculosis of the appendix. *J Indian Med Assoc* 1967;49:138–40.
7. Bobrow ML, Friedman S. Tuberculous appendicitis. *Am J Surg* 1956;91:389–93.
8. Wani I, Wani RA, Malik AA, Shah M, Wani M, Parray FQ, et al. Abdominal tuberculosis. *OA Case Reports* 2014;3:45.
9. Gupta SC, Gupta AK, Keswani NK, Singh PA, Tripathi AK, Krishna V. Pathology of tropical appendicitis. *J Clin Pathol* 1989;42:1169–72.
10. Nuwal P, Dixit R, Jain S, Porwa V. Isolated appendicular tuberculosis – A Case Report. *Ind J Tub* 2000;47:241.