



Ultrasound-Guided Intralesional Methylene Blue Injection for the Arthroscopic Decompression of Spinoglenoid Notch Cyst Causing Suprascapular Neuropathy

Kadir Buyukdogan, M.D., Burak Altintas, M.D., Özgür Koyuncu, M.D., İlker Eren, M.D., Olgar Birsell, M.D., Michael Fox, M.D., and Mehmet Demirhan, M.D.

Abstract: Symptomatic spinoglenoid ganglion cyst is a rare cause of shoulder pain and disability. Surgical treatment, which may be considered after failed nonoperative treatment, includes open or arthroscopic cyst debridement. Arthroscopic treatment is less invasive and has the advantage of addressing intraarticular pathologies; however, exposure of the cyst may be deemed difficult. Furthermore, the suprascapular nerve is susceptible to iatrogenic injury owing to its close proximity to the posterior glenoid rim. The purpose of this article is to present our technique for arthroscopic spinoglenoid cyst decompression after preoperative ultrasound-guided methylene blue injection.

Labral lesions can be accompanied by paralabral ganglion cysts and may be a source of pain and dysfunction depending on their size and location.^{1,2} The ganglion cyst is considered to be formed by a 1-way valve mechanism, in which the synovial fluid flows unidirectionally through the labral tear and accumulates outside the glenohumeral joint, or as a result of myxoid degeneration of the capsule.^{3,4} This cyst formation in proximity to the spinoglenoid notch has the potential to compress the suprascapular nerve (SSN) and may lead to infraspinatus atrophy with associated external rotation weakness and vague pain.⁴ Magnetic resonance imaging

(MRI) may be useful in demonstrating infraspinatus atrophy and in revealing the space-occupying lesion along the course of the nerve.⁵ Electromyography (EMG) and nerve conduction velocity (NCV) studies are of paramount importance in the diagnosis and localization of a suspected SSN injury.^{5,6}

Operative treatment can be performed by either open cyst excision or arthroscopic decompression.⁷⁻⁹ Because open surgery cannot address intra-articular pathologies, numerous arthroscopic techniques have been described to decompress symptomatic spinoglenoid cysts and concomitantly address labral pathology. Although arthroscopic treatment is a less invasive alternative, exposure of the cyst may prove difficult. Furthermore, excessive dissection may endanger the suprascapular nerve because of its close proximity to the glenoid rim.^{10,11} Therefore, we propose marking the cyst with methylene blue to assist with visually identifying the cyst, ensuring it is decompressed at the time of surgery, and avoiding iatrogenic suprascapular nerve injury.

In this article, we describe our surgical technique for ultrasound-guided intralesional methylene blue injection for arthroscopic decompression of spinoglenoid notch cysts.

Surgical Technique

Preoperative Ultrasound-Guided Methylene Blue Injection

After the administration of a regional interscalene block and the induction of general anesthesia, the

From the Department of Orthopedics and Traumatology, Koç University Hospital, Istanbul, Turkey (K.B., O.B.), the Hospital for Special Surgery, New York, NY, U.S.A. (B.A.), the Department of Orthopedics and Traumatology, VKV American Hospital, Istanbul, Turkey (Ö.K.), the Department of Orthopedics and Traumatology, Koç University School of Medicine, Istanbul, Turkey (İ.E., M.D.), and the Department of Orthopaedic Surgery, University of Pittsburgh, Pittsburgh, PA, U.S.A. (M.F.).

The authors report that they have no conflicts of interest in the authorship and publication of this article. Full ICMJE author disclosure forms are available for this article online, as [supplementary material](#).

Received April 15, 2020; accepted July 24, 2020.

Address correspondence to Kadir Buyukdogan, M.D., Department of Orthopaedic Surgery, Koc University Hospital, Davutpasa St, No. 4, 34010 Zeytinburnu/Istanbul, Turkey. E-mail: kbuyukdogan@gmail.com

© 2020 by the Arthroscopy Association of North America. Published by Elsevier. This is an open access article under the CC BY-NC-ND license (<http://creativecommons.org/licenses/by-nc-nd/4.0/>).

2212-6287/20677

<https://doi.org/10.1016/j.eats.2020.07.025>

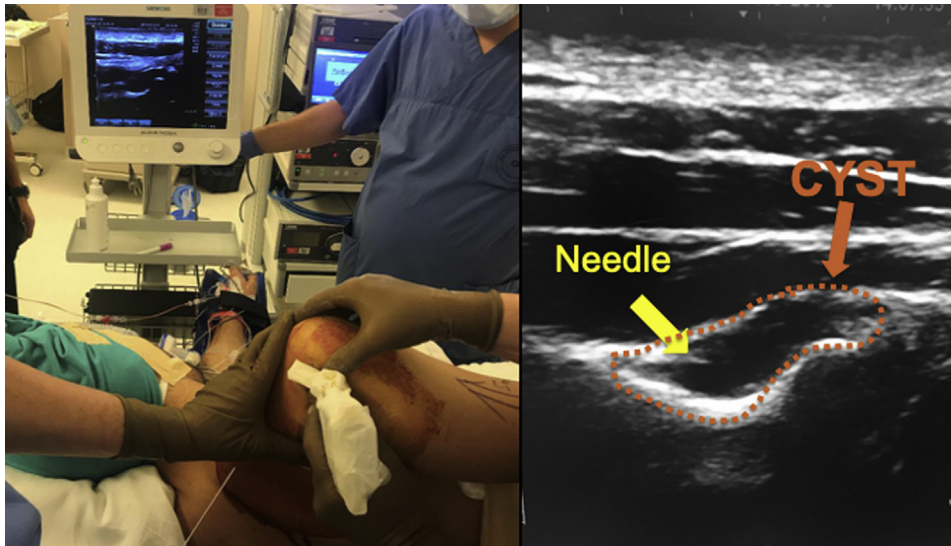


Fig 1. View of the right shoulder with the patient in lateral decubitus position. Note the introduction of the needle to the spinoglenoid notch ganglion cyst under real-time imaging ultrasound guidance.

patient is positioned in lateral decubitus position and the skin is prepared. A linear array transducer (CX50, 5 to 15 mHz; Philips, Bothell, WA) is placed over the scapular spine, and the infraspinatus fossa is identified. While imaging the infraspinatus muscle and the bony fossa underneath, the ultrasound transducer is moved laterally to locate the spinoglenoid notch cyst. With a linear probe used to visualize the cyst in the axial plane, an 18-gauge needle is directed into the cyst in an in-plane manner. Once the location of the needle tip has been confirmed to be inserted into the cyst with real-time imaging, 2 to 3 ml of methylene blue is injected into the cyst, paying attention to the underlying SSN (Fig 1).

Diagnostic Arthroscopy

Maintaining the patient in the lateral decubitus position, the operative extremity is draped free under sterile conditions with the arm secured in lateral traction. A standard posterior viewing portal is established and, under direct visualization, an anterosuperior portal is created with a 5.75-mm cannula (Crystal Cannula; Arthrex, Naples, FL). Diagnostic arthroscopy is then performed to identify and address any concomitant pathology. The long head of biceps tendon, superior labrum, rotator cuff, cartilage surfaces, and surrounding structures are evaluated thoroughly.¹²

Arthroscopic Decompression of the Spinoglenoid Cyst.

The arthroscope is switched to the anterosuperior portal to assess the posterior labrum. An 8.25-mm cannula (Twist-In Cannula; Arthrex) is inserted into the posterior portal. An accessory posterolateral portal is established with a 5.75-mm cannula to be used as a working portal. A liberator is introduced through the posterior portal, and the torn or frayed labrum is

elevated gently to visualize the spinoglenoid cyst lying beneath (Fig 2). Next, a 5.0-mm shaver (Arthrex) is introduced from the posterior portal. After careful debridement of the soft tissue posterior to the scapular spine, the cyst can be distinguished as a bulging structure with a bluish reflection (Fig 3). The cyst can then be decompressed safely using the shaver (Video 1). Viscous and bluish fluid egress into the joint cavity confirms decompression of the cyst (Fig 4). To avoid neurovascular injury, neither the shaver nor any instruments are advanced beyond 1 cm medial to the posterior border of the glenoid. Continuing debridement until the washout of methylene blue confirms the adequate decompression of the cyst.

The bone under the posterior labrum is then debrided to create a bleeding bone bed to facilitate healing of the

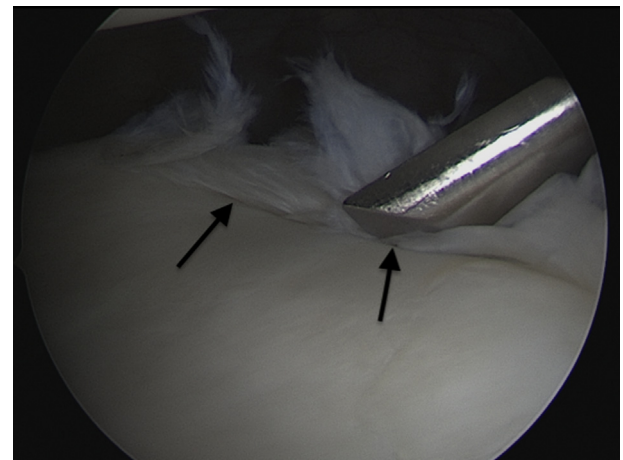


Fig 2. Right shoulder, view from anterosuperior portal in lateral decubitus position. A liberator is inserted through the posterior portal, and the torn or frayed labrum (black arrows) is elevated gently to visualize the spinoglenoid cyst.

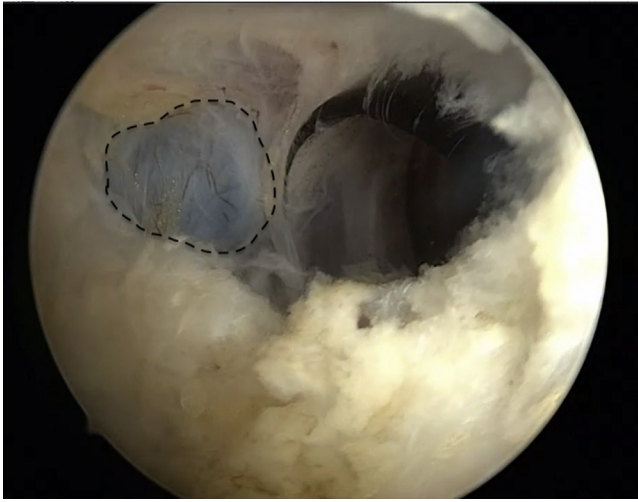


Fig 3. Right shoulder, view from anterosuperior portal in lateral decubitus position. After careful debridement of the soft tissue posterior to the scapular spine, the cyst can be distinguished as a large, dull, blue-tinged structure (dotted lines) that bulges into the joint cavity.

labrum while avoiding any additional damage to the labrum. The senior author (M.D.) prefers repair in cases with posteroinferior labrum lesions that extend beyond the posterior band of inferior glenohumeral ligament, which corresponds to a 9 o'clock (right shoulder) or 3 o'clock (left shoulder) position. Debridement is reserved for patients who present with posterosuperior labrum lesions that do not compromise the biceps anchor.

After the procedure, the incisions are closed. Pearls and pitfalls of the technique are outlined in [Table 1](#).

Postoperative Rehabilitation

Postoperative rehabilitation depends on concurrent procedures. For spinoglenoid cyst decompression with labrum debridement, sling immobilization for 1 week with immediate full active and passive range of motion is allowed. Patients with labrum repair are immobilized in a sling for 4 weeks. Passive and gentle active assistive range of motion exercises are begun, but no active internal rotation and forward flexion more than 90° is allowed. After 4 weeks, gentle stretching exercises are initiated to gradually improve range of motion. Pain-free, gentle internal rotation exercises are instituted at 6 weeks. Advanced strengthening including muscular strength is allowed after 8 weeks. Gradual return to sport activities is allowed after 12 weeks.

Discussion

Although the exact pathogenesis of ganglion cysts located at the spinoglenoid notch is not clearly understood, it is believed to be formed either from capsulolabral pathologies that act as a 1-way valve or as a result of myxoid degeneration of the capsule.⁴ The

suprascapular nerve is susceptible to external compression at the spinoglenoid notch, because the fibro-osseous tunnel formed by the spinoglenoid ligament and the lateral edge of the scapular spine keep the nerve tightly constrained at the notch.¹³ Therefore, even a small cyst may result in compression of the nerve, particularly the motor branches innervating the infraspinatus muscle.^{6,11} Furthermore, Tung et al.¹⁴ reported that signs of muscle denervation on MRI correlate with the size of cysts. The average diameter of cysts associated with muscle denervation was 3.1 cm, which was significantly larger than cysts not associated with muscle denervation.

MRI is the modality of choice for the diagnosis and localization of paralabral cysts. It is also useful in demonstrating denervation changes in the affected muscle with or without muscle atrophy. However, not all cysts located in the spinoglenoid notch will result in suprascapular nerve paralysis. The diagnosis of suprascapular neuropathy should be confirmed by electromyography (EMG) and nerve conduction velocity (NCV) studies.¹⁵ MRI is also helpful for detecting associated intra-articular lesions such as labral pathology. MRI arthrography, particularly T2-weighted images, may improve the accuracy of detecting labral tears accompanying with paralabral cysts.¹⁴

Treatment options for paralabral ganglion cysts vary from conservative management to open excision of the cyst. Patients with suprascapular neuropathy due to a ganglion cyst at the spinoglenoid notch reportedly have demonstrated poor results with nonoperative treatment.¹³ Piatt et al.¹⁶ followed up 11 patients who underwent needle aspiration of the cyst and reported

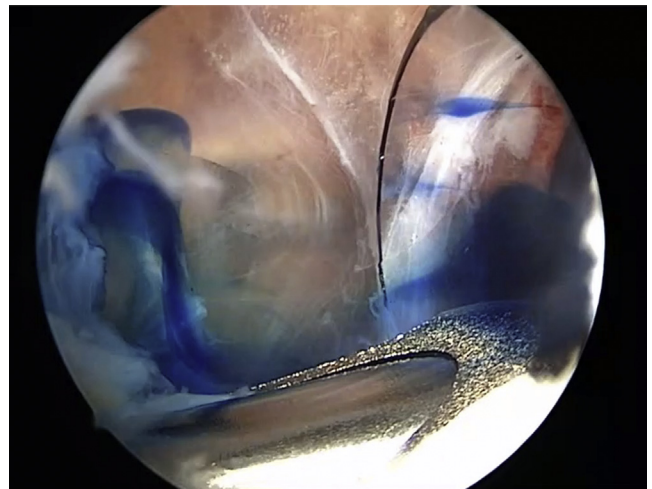


Fig 4. Right shoulder, view from anterosuperior portal in lateral decubitus position. Viscous and bluish fluid egress into the joint cavity confirms decompression of the cyst. Note that, to avoid neurovascular injury, neither the shaver nor any instruments were advanced beyond 1 cm medial to the posterior border of the glenoid.

Table 1. Pearls and Pitfalls

Surgical steps	Pitfalls	Pearls
Methylene blue injection	Difficulty identifying and injecting the spinoglenoid cyst	Use a linear probe and in-plane technique to accurately visualize the cyst and guide the needle.
Visualization of the spinoglenoid cyst	Iatrogenic injury of the neurovascular structures and extensive labrum and capsule debridement	Use a liberator to open the glenolabral interval and use the shaver while staying on the bone.

that 5 patients (45%) had recurrent cyst formation as evidenced by symptom recurrence and MRI evaluation. Open decompression may be performed through a posterior approach to the shoulder; however, this technique does not permit assessment of the glenohumeral joint and treatment of concomitant intraarticular lesions that may contribute to cyst formation.¹³ Arthroscopic decompression of the ganglion cyst located at the spinoglenoid notch is safe and effective and may entail less morbidity than an open procedure. Some authors have suggested that arthroscopic management of these cysts resulted in lower rates of recurrence with improved patient satisfaction.^{9,15-17} There is continuing debate over whether only repairing the labrum without decompression will provide complete cyst resolution. A recent systematic review showed that, despite the lack of high-quality evidence, both labrum repair alone or with concomitant decompression showed excellent results.¹

Although paralabral cysts are located in the same anatomic quadrant as labrum tears, it may be difficult for surgeons to localize the cyst. Given the proximity of suprascapular nerve medial to the posterior glenoid, identification of the cyst is of the utmost importance. Previous cadaveric studies demonstrated that the suprascapular nerve crosses medial to the posterior glenoid rim ~1.8 to 2 cm.^{10,11,18} Therefore, it is recommended to limit dissection only up to 1 cm medial to the glenoid during decompression to avoid nerve injury.¹⁵ To prevent iatrogenic injury to the nerve and excessive resection of both capsule and labrum, we propose marking the cyst with methylene blue. Blue dye leakage into the joint cavity enables us to accurately locate the cyst. In cases without dye egress to the joint, the blue tinged cyst can be easily identified during the procedure with a minimal debridement. Additionally, continuing the debridement of the cyst complete clearance of the methylene blue confirms adequate decompression of the cyst. Advantages and disadvantages of the technique are outlined in [Table 2](#).

Table 2. Advantages and Disadvantages

Advantages	Disadvantages
Easier identification of the cyst	Longer operation time due to the preoperative injection
Proof of cyst decompression due to methylene blue dye washout	Possible neurovascular injury during cyst injection

In summary, the presented technique for arthroscopic spinoglenoid cyst decompression following preoperative ultrasound-guided methylene blue injection is a promising and reproducible method and protects the critical neurovascular structures.

References

- Schroeder AJ, Bedeir YH, Schumaier AP, Desai VS, Grawe BM. Arthroscopic management of SLAP lesions with concomitant spinoglenoid notch ganglion cysts: A systematic review comparing repair alone to repair with decompression. *Arthroscopy* 2018;34:2247-2253.
- Zehetgruber H, Noske H, Lang T, Wurnig C. Suprascapular nerve entrapment. A meta-analysis. *Int Orthop* 2002;26:339-343.
- Jeong JJ, Panchal K, Park SE, et al. Outcome after arthroscopic decompression of inferior labral cysts combined with labral repair. *Arthroscopy* 2015;31:1060-1068.
- Lichtenberg S, Magosch P, Habermeyer P. Compression of the suprascapular nerve by a ganglion cyst of the spinoglenoid notch: The arthroscopic solution. *Knee Surg Sports Traumatol Arthrosc* 2004;12:72-79.
- Millett PJ, Barton RS, Pacheco IH, Gobezie R. Suprascapular nerve entrapment: Technique for arthroscopic release. *Tech Shoulder Elbow Surg* 2006;7:89-94.
- Boykin RE, Friedman DJ, Higgins LD, Warner JJP. Suprascapular neuropathy. *J Bone Joint Surg Am* 2010;92:2348-2364.
- Mall NA, Hammond JE, Lenart BA, Enriquez DJ, Twigg SL, Nicholson GP. Suprascapular nerve entrapment isolated to the spinoglenoid notch: Surgical technique and results of open decompression. *J Shoulder Elbow Surg* 2013;22:e1-e8.
- Schroder CP, Lundgreen K, Kvakestad R. Paralabral cysts of the shoulder treated with isolated labral repair: Effect on pain and radiologic findings. *J Shoulder Elbow Surg* 2018;27:1283-1289.
- Ghodadra N, Nho SJ, Verma NN, et al. Arthroscopic decompression of the suprascapular nerve at the spinoglenoid notch and suprascapular notch through the subacromial space. *Arthroscopy* 2009;25:439-445.
- Warner JP, Krushell RJ, Masquelet A, Gerber C. Anatomy and relationships of the suprascapular nerve: Anatomical constraints to mobilization of the supraspinatus and infraspinatus muscles in the management of massive rotator-cuff tears. *J Bone Joint Surg Am* 1992;74:36-45.
- Bigliani LU, Dalsey RM, McCann PD, April EW. An anatomical study of the suprascapular nerve. *Arthroscopy* 1990;6:301-305.

12. Altintas B, Pitta R, Fritz EM, Higgins B, Millett PJ. Technique for type IV SLAP lesion repair. *Arthrosc Tech* 2018;7:e337-e342.
13. Cummins CA, Messer TM, Nuber GW. Suprascapular nerve entrapment. *J Bone Joint Surg Am* 2000;82:415-424.
14. Tung GA, Entzian D, Stern JB, Green A. MR imaging and MR arthrography of paraglenoid labral cysts. *AJR Am J Roentgenol* 2000;174:1707-1715.
15. Westerheide KJ, Karzel RP. Ganglion cysts of the shoulder: Technique of arthroscopic decompression and fixation of associated type II superior labral anterior to posterior lesions. *Orthop Clin North Am* 2003;34:521-528.
16. Piatt BE, Hawkins RJ, Fritz RC, Ho CP, Wolf E, Schickendantz M. Clinical evaluation and treatment of spinoglenoid notch ganglion cysts. *J Shoulder Elbow Surg* 2002;11:600-604.
17. Iannotti JP, Ramsey ML. Arthroscopic decompression of a ganglion cyst causing suprascapular nerve compression. *Arthroscopy* 1996;12:739-745.
18. Demirhan M, Imhoff AB, Debski RE, Patel PR, Fu FH, Woo SL. The spinoglenoid ligament and its relationship to the suprascapular nerve. *J Shoulder Elbow Surg* 1998;7:238-243.