

# Preservation of Olfaction after Unilateral Endoscopic Approach for Resection of Esthesioneuroblastoma

Aaron Wessell<sup>1</sup> Ameet Singh<sup>2</sup> Zachary Litvack<sup>3</sup>

<sup>1</sup>School of Medicine, The George Washington University Medical Center, Washington, District of Columbia, United States

<sup>2</sup>Department of Surgery, Division of Otolaryngology, The George Washington University Medical Center, Washington, District of Columbia, United States

<sup>3</sup>Department of Neurosurgery, The George Washington University Medical Center, Washington, District of Columbia, United States

**Address for correspondence** Zachary Litvack, MD, MCR, Co-Director, Endoscopic Pituitary and Anterior Skull-Base Surgery Program, Department of Neurosurgery, George Washington University Medical Center, 2150 Pennsylvania Avenue, NW, Suite 7-420, Washington, DC 20037, United States (e-mail: zlitvack@mfa.gwu.edu).

J Neurol Surg Rep 2014;75:e149–e153.

## Abstract

**Objectives** We present a case of olfactory preservation after a unilateral transcribri-form transthemoidal endoscopic resection of esthesioneuroblastoma. We also discuss the oncologic results of endoscopic and transcranial approaches and describe the potential benefits and limitations of an endoscopic approach.

**Setting** Single academic medical center.

**Participant and Design** The clinical course of a 28-year-old patient who underwent endoscopic en bloc resection of esthesioneuroblastoma through a unilateral transcribri-form transthemoidal approach was reviewed.

**Results** Imaging demonstrated a left-sided nasal mass with cribriform plate involvement (Kadish C). Intraoperatively, the left olfactory bulb and epithelium were sacrificed. Negative frozen sections were obtained from the right olfactory epithelium and dura surrounding the right olfactory bulb. Reconstruction was performed using a multilayered closure of fascia, rigid buttress, and nasoseptal flap. Histology was consistent with esthesioneuroblastoma. Postoperative clinical evaluation, endoscopy, and magnetic resonance imaging demonstrated no evidence of residual or recurrent tumor at 18 months. The UPSIT smell testing revealed normal olfaction preoperatively, moderate microsomia at 3 months postoperatively, and mild microsomia at 18 months postoperatively.

**Conclusions** Endoscopic resection of esthesioneuroblastoma has demonstrated similar oncologic control while reducing postoperative morbidity and mortality over transcranial approaches. This case reveals the potential to preserve olfaction while achieving en bloc endoscopic resection of early stage esthesioneuroblastoma.

## Keywords

- ▶ endoscopy
- ▶ esthesioneuroblastoma
- ▶ skull-base
- ▶ olfactory preservation
- ▶ craniofacial

## Introduction

Esthesioneuroblastoma (ENB), also known as olfactory neuroblastoma, is a rare malignant tumor of neuroectodermal

origin arising from the olfactory epithelium. These tumors are often unilateral slow-growing masses presenting in the orbital rim or ethmoid sinuses. ENB comprises 1 to 5% of intranasal tumors<sup>1–4</sup> and represents < 1% of all malignant

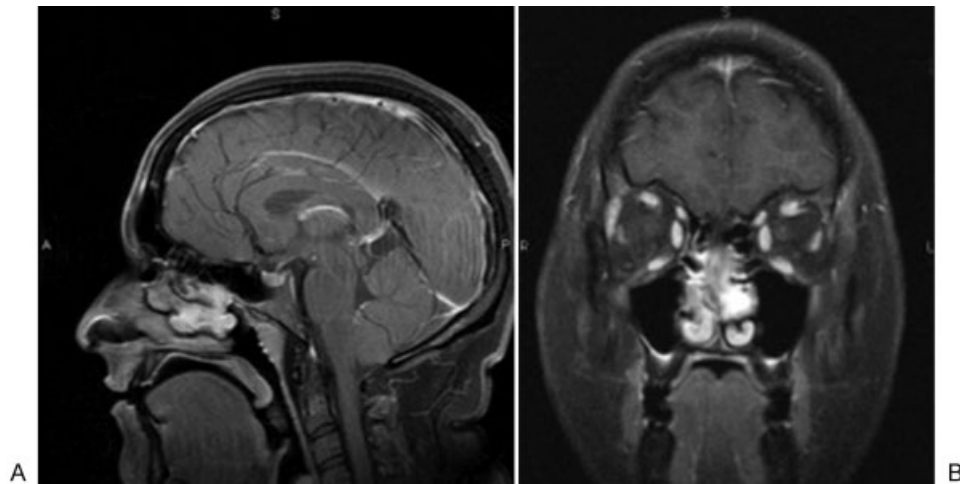
received  
January 29, 2014  
accepted  
April 3, 2014  
published online  
June 24, 2014

DOI <http://dx.doi.org/10.1055/s-0034-1376427>.  
ISSN 2193-6358.

© 2014 Georg Thieme Verlag KG  
Stuttgart · New York

License terms





**Fig. 1** Preoperative (A) sagittal and (B) coronal T1-weighted postcontrast magnetic resonance imaging demonstrating a  $2.8 \times 2.2 \times 1$  cm enhancing soft tissue lesion in the left nasal cavity located medial and inferior to the middle turbinate.

tumors.<sup>5</sup> Diagnosis of ENB tends to occur late in the disease course, most commonly presenting in the second and fifth decades of life as unilateral nasal obstruction and epistaxis.<sup>6–8</sup> Other presenting symptoms reported in the literature include headache, cheek fullness, proptosis, epiphora, retrobulbar pain, vision changes, infraorbital neuralgia, cranial nerve deficits, olfactory dysfunction, altered mental status, nausea, vomiting, and neuroendocrine abnormalities.<sup>9–11</sup>

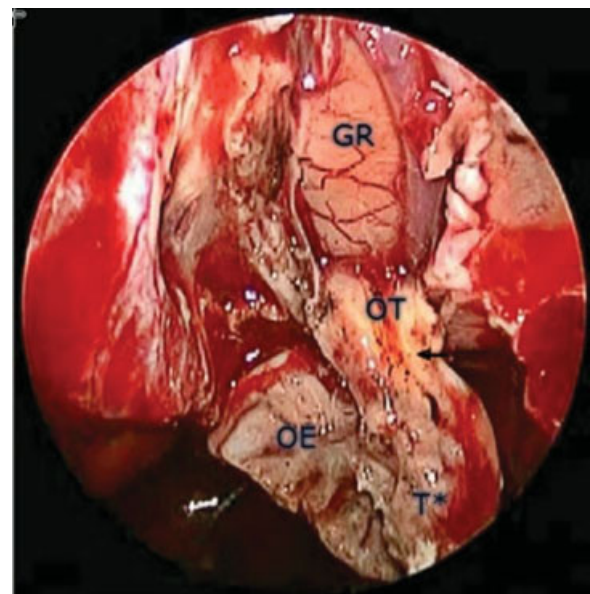
Traditional first-line treatment for ENB is craniofacial resection (CFR) with postoperative radiation therapy. The goal of surgery is to achieve a gross total resection with histologically negative margins. Although the importance of radiation and chemotherapy remains controversial in the literature,<sup>12,13</sup> surgical treatment in combination with adjuvant radiation and/or chemotherapy has undeniably improved outcomes since the first description of ENB in the literature in 1924.<sup>8,12,14,15</sup> More recently, the purely endoscopic endonasal approach (EEA) has increased in popularity, proving to be an effective method for ENB resection. This technique offers the benefits of reduced morbidity and mortality compared with traditional CFR while achieving comparable oncologic results.<sup>13–16</sup> Although critics argue that the endoscopic technique limits the ability to achieve a complete en bloc resection, a partial or unilateral resection may be appropriate in select cases. Here we describe a case of olfactory preservation after a unilateral transcribriform transtethmoidal resection of ENB.

## Clinical Presentation

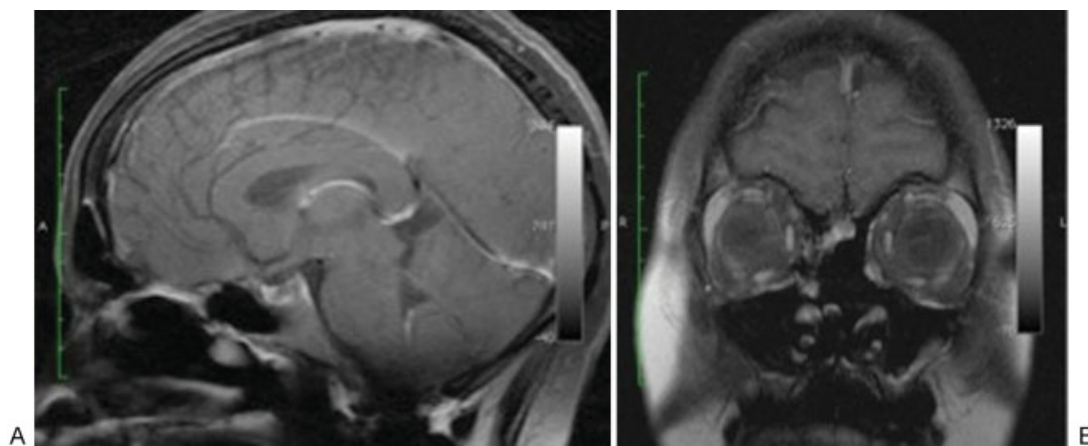
A 28-year-old woman presented to the outpatient otolaryngology clinic complaining of chronic bilateral nasal congestion. Direct endoscopic visualization revealed a left-sided mass of the sphenothmoid recess. Magnetic resonance imaging (MRI) demonstrated a  $2.8 \times 2.2 \times 1.0$  cm contrast-enhancing soft tissue lesion in the left nasal cavity with erosion of the cribriform plate (→**Fig. 1**). Preoperative histology was consistent with ENB. Preoperative University of

Pennsylvania Smell Identification Test (UPSIT)<sup>16</sup> revealed normal olfaction.

The patient underwent EEA resection via a unilateral transcribriform transtethmoidal approach. The olfactory apparatus (epithelium, cribriform plate, and olfactory bulb) was removed en bloc with the tumor, sectioning the olfactory tract 1 cm posterior to the tumor margin (→**Fig. 2**). This spared the right olfactory apparatus. Intraoperative frozen pathologic sections (ipsilateral olfactory tract, contralateral olfactory epithelium, cribriform dura and bulb) were obtained to confirm histologically negative surgical margins. A multilayered closure was performed using fascia, rigid



**Fig. 2** Intraoperative endoscopic image, left nasal cavity, demonstrating en bloc dissection of the olfactory apparatus prior to resection. The transition from tumor to normal olfactory tract is evident (arrow). GR, gyrus rectus; OE, olfactory epithelium; OT, olfactory tract; T\*, tumor.



**Fig. 3** (A) Sagittal and (B) coronal T1-weighted postcontrast magnetic resonance imaging at 18 months postoperatively showing resection of the bony nasal septum, portions of the middle nasal turbinates, ethmoidal air cells, and the medial wall of the left maxillary antrum. No evidence of tumor recurrence is visible.

buttress, and a vascularized nasoseptal flap with fibrin-based tissue sealant. No intraoperative complications were encountered. Postoperatively, the patient experienced a vigorous aseptic meningitis requiring high-dose steroid therapy for 7 days.

Immediate postoperative MRI revealed no evidence of residual tumor, and no adjuvant radiation therapy was prescribed. The patient was maintained on a regimen of nasal hygiene with twice daily nasal saline spray and routine rhinologic follow-up. Nasal debridement occurred on an as-needed basis at 10 days and 3 weeks postoperatively. UPSIT smell testing<sup>17</sup> revealed moderate microsomia at 3 months postoperatively and mild microsomia at 18 months postoperatively. The patient remained disease free at last follow-up of 18 months (► Fig. 3).

## Discussion

ENB is a rare malignancy with 5- and 10-year survival rates of ~ 80% and 50%, respectively.<sup>3,17-20</sup> Metastasis is reported at the time of diagnosis in 10 to 33% of cases.<sup>6,7,21-24</sup> Despite high rates of cervical metastases, with adequate treatment, ENB carries a superior prognosis compared with other superior nasal malignancies.<sup>25</sup> First-line treatment for ENB is CFR with postoperative radiation therapy, combining a bifrontal craniotomy and transfacial approach to achieve true en bloc resection. This technique is associated with high morbidity and mortality ranging from 30% to 50%.<sup>26,27</sup> Potential complications reported in the literature include intracranial hypertension, cerebrovascular accident, pneumocephalus, cerebrospinal fluid (CSF) leak, orbital complications, cosmetic complications, infection, and various systemic complications.<sup>17</sup> More aggressive approaches have been reported, using neoadjuvant concomitant radiation and platinum-based chemotherapy with limited success.<sup>28</sup>

Endoscopic-assisted CFR was first described in the 1990s, combining a bifrontal craniotomy with an endoscopic endonasal approach, for ENB resection.<sup>29-31</sup> More recently, purely EEA techniques have been used. The benefits of an endoscopic

approach include superior visualization, decreased operative time, reduced length of hospital stay, less postoperative pain, and avoidance of craniotomy and facial incision. The literature contains numerous reports of EEA ENB resection, with oncologic results comparable with that of traditional CFR.<sup>21,29,32,33</sup>

In 1999, Stammeberger et al performed a retrospective review of eight EEA ENB resections, with gamma knife adjuvant therapy used in select cases. All patients were found to be alive and disease free after a mean follow-up period of 37.2 months.<sup>32</sup> Castelnovo reported similar findings with nearly all patients remaining disease free at 38.1 months, demonstrating that a purely EEA approach can achieve histologically negative surgical margins. Of note, among this select group of patients, 90% received adjuvant radiation therapy and one patient received chemotherapy due to advanced disease.<sup>34</sup> Casiano et al support these findings with 80% of patients remaining free of disease at 31 months postoperatively.<sup>29</sup> Several retrospective studies describe similar experiences with the EEA approach, some involving late stage tumors.<sup>8,29</sup> The shorter follow-up times in the EEA studies relative to CFR studies limits comparison of these two approaches. Thorough evaluation of ENB resection techniques requires long-term follow-up because recurrence and metastases have been reported up to 10 years after initial treatment.<sup>35</sup>

To date, a handful of investigators have developed ENB classification schemes aimed at guiding surgical therapy and demonstrating varying degrees of prognostic significance.<sup>12,23,36,37</sup> The Kadish system, in particular, has been shown to have prognostic significance for recurrence and 2- and 5-year survival rates. The Kadish system classifies tumors as follows: Kadish stage A tumors are limited to the nasal cavity, and Kadish extend into the paranasal sinuses and stage C beyond the paranasal sinuses. Kadish stages A and B have lower rates of recurrence and increased survival compared with Kadish stage C.<sup>23</sup>

In 2009, a meta-analysis published by Devaiah et al compared the results for open and endoscopic ENB resection in 361 patients. Endoscopic surgery was found to improve survival rates significantly compared with open surgery with

no significant difference in follow-up time between groups. Notably, patients in the open surgical group possessed more complex tumors. A total of 63% of all open cases consisted of Kadish stages C and D tumors; 56% of endoscopic and 61% of endoscopically assisted cases were Kadish stages A and B.<sup>33</sup>

More recently, Komotar et al performed a thorough literature review comparing EEA with CFR and combined open/endonasal (CN) ENB resection. The study population consisted of 47 studies with 453 patients divided into three cohorts based on the respective surgical approach: CFR ( $n = 318$ ), EEA ( $n = 102$ ), and CN ( $n = 33$ ). The study revealed a greater rate of gross total resection for EEA cases (98.1%) compared with CFR (81.3%). Negative surgical margins were achieved in 93.8%, 95.8%, and 77.3% of EEA, CN, and CFR cases, respectively. The EEA approach was also associated with a decreased rate of regional metastases and greater survival at last follow-up. These findings support the notion that purely EEA or CN approaches do not result in significantly worse surgical and oncologic outcomes compared with traditional CFR, and they serve as viable alternatives for surgical resection.<sup>38</sup> However, much like the meta-analysis published by Devaiah and colleagues, one must consider the fact that high-grade tumors (Kadish stage C) are frequently treated with open surgical approaches, whereas endoscopic techniques are more often used for lower grade tumors (Kadish stages A and B).<sup>33</sup>

Despite the proven utility and benefits of a purely EEA, this technique is not without complication. Historically, postoperative CSF leak has been a concern with ENB, particularly when dural involvement is present.<sup>39,40</sup> Fortunately, newly developed endoscopic skull base reconstruction techniques have proven to be very effective. A new multilayered closure technique, called the gasket seal, has been used in combination with a vascularized nasoseptal flap for a variety of anterior skull base lesions with zero incidence of CSF leak in select studies.<sup>41</sup> Other potential complications reported in the literature include intraoperative bleeding, orbital hematoma, frontal lobe abscess, epistaxis, and prolonged nasal crusting.<sup>42</sup>

Most patients are able to undergo endoscopic resection safely and successfully in the hands of an experienced team of endoscopic neurosurgeons and otolaryngologists. However, patients frequently complain of prolonged nasal crusting during the postoperative period. In a quality of life analysis, 69% and 61% of skull base surgery patients complained of smell disturbance and nasal crusting, respectively.<sup>43</sup> Given the intimate relationship of ENB with the cribriform plate and olfactory nerves, olfactory function is often compromised, both from resection of olfactory epithelium and postoperative radiation-induced atrophic rhinitis. However, olfactory dysfunction can be reduced with the EEA approach relative to traditional CFR.<sup>38</sup> Castelnuovo et al demonstrate that olfactory preservation is possible with EEA approach for en bloc or piecemeal resection.<sup>34</sup> Critics of the endoscopic approach argue that this technique limits the ability to achieve en bloc resection, negatively impacting the rate of oncologic cure. However, one may make the claim that in the hands of an experienced endoscopic surgeon, there is little, if any, difference in the degree of tissue removed via the endoscopic

approach compared with CFR. Moreover, the literature supports the notion that piecemeal resection does not necessarily translate to an increased rate of local recurrence.<sup>21,31,44</sup>

This case provides further support that olfactory preservation is possible via an EEA in select cases of ENB. Olfactory preservation should be considered as an end objective, particularly in patients with low-grade tumors (Kadish stages A and B) and unilateral disease. Meticulous preoperative planning is necessary for olfactory preservation while achieving a sound oncologic resection. Preoperative MRI and axial and coronal computed tomography imaging must be reviewed to assess the extent of soft tissue invasion and bony erosion. The limitations of the EEA must be taken into consideration as well. For more extensive lesions that invade laterally into the maxillary sinus, pterygomaxillary fissure, or infratemporal fossa, and lesions that involve the soft tissues of the face, traditional CFR may be indicated. Adjuvant radiation therapy can be used in select cases to increase local control.<sup>3,13,34,45,46</sup> Follow-up care with a rhinologist is necessary to ensure proper wound healing. Additionally, long-term follow-up with direct endoscopic visualization and MRI imaging is advised, regardless of surgical technique, to monitor for local recurrence and metastasis.

## Conclusion

Endoscopic endonasal resection of ENB has demonstrated similar oncologic control while reducing postoperative morbidity and mortality over traditional transcranial approaches. This case illustrates the potential to preserve olfaction following en bloc resection of ENB. Further evaluation of surgical technique is required to improve preservation while ensuring adequate oncologic resection. Futures studies must incorporate long-term follow up to adequately assess the rate of oncologic cure compared with traditional approaches.

## Disclosures

The authors have no financial or materials support to disclose.

## References

- 1 Broich G, Pagliari A, Ottaviani F. Esthesioneuroblastoma: a general review of the cases published since the discovery of the tumour in 1924. *Anticancer Res* 1997;17: A2683-2706
- 2 Irish J, Dasgupta R, Freeman J, et al. Outcome and analysis of the surgical management of esthesioneuroblastoma. *J Otolaryngol* 1997;26(1):1-7
- 3 Foote RL, Morita A, Ebersold MJ, et al. Esthesioneuroblastoma: the role of adjuvant radiation therapy. *Int J Radiat Oncol Biol Phys* 1993;27(4):835-842
- 4 Beitler JJ, Fass DE, Brenner HA, et al. Esthesioneuroblastoma: is there a role for elective neck treatment? *Head Neck* 1991;13(4):321-326
- 5 Svane-Knudsen V, Jørgensen KE, Hansen O, Lindgren A, Marker P. Cancer of the nasal cavity and paranasal sinuses: a series of 115 patients. *Rhinology* 1998;36(1):12-14
- 6 Elkon D, Hightower SI, Lim ML, Cantrell RW, Constable WC. Esthesioneuroblastoma. *Cancer* 1979;44(3):1087-1094
- 7 Spaulding CA, Kranyak MS, Constable WC, Stewart FM. Esthesioneuroblastoma: a comparison of two treatment eras. *Int J Radiat Oncol Biol Phys* 1988;15(3):581-590



- 8 Walch C, Stammberger H, Anderhuber W, Unger F, Köle W, Feichtinger K. The minimally invasive approach to olfactory neuroblastoma: combined endoscopic and stereotactic treatment. *Laryngoscope* 2000;110(4):635–640
- 9 Levine PA, McLean WC, Cantrell RW. Esthesioneuroblastoma: the University of Virginia experience 1960–1985. *Laryngoscope* 1986;96(7):742–746
- 10 Koka VN, Julieron M, Bourhis J, et al. Aesthesioneuroblastoma. *J Laryngol Otol* 1998;112(7):628–633
- 11 Lund VJ, Milroy C. Olfactory neuroblastoma: clinical and pathological aspects. *Rhinology* 1993;31(1):1–6
- 12 Biller HF, Lawson W, Sachdev VP, Som P. Esthesioneuroblastoma: surgical treatment without radiation. *Laryngoscope* 1990;100(11):1199–1201
- 13 Morita A, Ebersold MJ, Olsen KD, Foote RL, Lewis JE, Quast LM. Esthesioneuroblastoma: prognosis and management. *Neurosurgery* 1993;32(5):706–714; discussion 714–715
- 14 Berger L, Luc H, Richard R. L'esthesioneuro epitheliome olfactif. *Bull Assoc Fr Etud Cancer* 1924;13:410–420
- 15 Dulguerov P, Calcaterra T. Esthesioneuroblastoma: the UCLA experience 1970–1990. *Laryngoscope* 1992;102(8):843–849
- 16 Doty RL, Shaman P, Kimmelman CP, Dann MS. University of Pennsylvania Smell Identification Test: a rapid quantitative olfactory function test for the clinic. *Laryngoscope* 1984;94(2 Pt 1):176–178
- 17 Levine PA, Gallagher R, Cantrell RW. Esthesioneuroblastoma: reflections of a 21-year experience. *Laryngoscope* 1999;109(10):1539–1543
- 18 Shah JP, Kraus DH, Bilsky MH, Gutin PH, Harrison LH, Strong EW. Craniofacial resection for malignant tumors involving the anterior skull base. *Arch Otolaryngol Head Neck Surg* 1997;123(12):1312–1317
- 19 Levine PA, Debo RF, Meredith SD, Jane JA, Constable WC, Cantrell RW. Craniofacial resection at the University of Virginia (1976–1992): survival analysis. *Head Neck* 1994;16(6):574–577
- 20 Spiro JD, Soo KC, Spiro RH. Nonsquamous cell malignant neoplasms of the nasal cavities and paranasal sinuses. *Head Neck* 1995;17(2):114–118
- 21 Batra PS, Citardi MJ, Worley S, Lee J, Lanza DC. Resection of anterior skull base tumors: comparison of combined traditional and endoscopic techniques. *Am J Rhinol* 2005;19(5):521–528
- 22 Skolnik EM, Massari FS, Tenta LT. Olfactory neuroepithelioma. Review of the world literature and presentation of two cases. *Arch Otolaryngol* 1966;84(6):644–653
- 23 Kadish S, Goodman M, Wang CC. Olfactory neuroblastoma. A clinical analysis of 17 cases. *Cancer* 1976;37(3):1571–1576
- 24 Eden BV, Debo RF, Larner JM, et al. Esthesioneuroblastoma: long-term outcome and patterns of failure—the University of Virginia experience 1960–1985. *Laryngoscope* 1994;104(9):742–746
- 25 Davis RE, Weissler MC. Esthesioneuroblastoma and neck metastasis. *Head Neck* 1992;14(6):477–482
- 26 Kraus DH, Shah JP, Arbit E, Galicich JH, Strong EW. Complications of craniofacial resection for tumors involving the anterior skull base. *Head Neck* 1994;16(4):307–312
- 27 Richtsmeier WJ, Briggs RJ, Koch WM, et al. Complications and early outcome of anterior craniofacial resection. *Arch Otolaryngol Head Neck Surg* 1992;118(9):913–917
- 28 Sohrabi S, Drabick JJ, Crist H, Goldenberg D, Sheehan JM, Mackley HB. Neoadjuvant concurrent chemoradiation for advanced esthesioneuroblastoma: a case series and review of the literature. *J Clin Oncol* 2011;29(13):e358–e361
- 29 Casiano RR, Numa WA, Falquez AM. Endoscopic resection of esthesioneuroblastoma. *Am J Rhinol* 2001;15(4):271–279
- 30 Yuen AP, Fan YW, Fung CF, Hung KN. Endoscopic-assisted craniofacial resection of olfactory neuroblastoma. *Head Neck* 2005;27(6):488–493
- 31 Thaler ER, Kotapka M, Lanza DC, Kennedy DW. Endoscopically assisted anterior cranial skull base resection of sinonasal tumors. *Am J Rhinol* 1999;13(4):303–310
- 32 Stammberger H, Anderhuber W, Walch C, Papaefthymiou G. Possibilities and limitations of endoscopic management of nasal and paranasal sinus malignancies. *Acta Otorhinolaryngol Belg* 1999;53(3):199–205
- 33 Devaiah AK, Andreoli MT. Treatment of esthesioneuroblastoma: a 16-year meta-analysis of 361 patients. *Laryngoscope* 2009;119(7):1412–1416
- 34 Castelnovo PG, Delù G, Sberze F, et al. Esthesioneuroblastoma: endonasal endoscopic treatment. *Skull Base* 2006;16(1):25–30
- 35 Loy AH, Reibel JF, Read PW, et al. Esthesioneuroblastoma: continued follow-up of a single institution's experience. *Arch Otolaryngol Head Neck Surg* 2006;132(2):134–138
- 36 Resto VA, Eisele DW, Forastiere A, Zahurak M, Lee DJ, Westra WH. Esthesioneuroblastoma: the Johns Hopkins experience. *Head Neck* 2000;22(6):550–558
- 37 Polin RS, Sheehan JP, Chenelle AG, et al. The role of preoperative adjuvant treatment in the management of esthesioneuroblastoma: the University of Virginia experience. *Neurosurgery* 1998;42(5):1029–1037
- 38 Komotar RJ, Starke RM, Raper DM, Anand VK, Schwartz TH. Endoscopic endonasal compared with anterior craniofacial and combined cranionasal resection of esthesioneuroblastomas. *World Neurosurg* 2013;80(1–2):148–159
- 39 Poetker DM, Toohill RJ, Loehrl TA, Smith TL. Endoscopic management of sinonasal tumors: a preliminary report. *Am J Rhinol* 2005;19(3):307–315
- 40 Folbe A, Herzallah I, Duvvuri U, et al. Endoscopic endonasal resection of esthesioneuroblastoma: a multicenter study. *Am J Rhinol Allergy* 2009;23(1):91–94
- 41 Leng LZ, Brown S, Anand VK, Schwartz TH. “Gasket-seal” watertight closure in minimal-access endoscopic cranial base surgery. *Neurosurgery* 2008;62(5, Suppl 2):E342–E343; discussion E343
- 42 Dave SP, Bared A, Casiano RR. Surgical outcomes and safety of transnasal endoscopic resection for anterior skull tumors. *Otolaryngol Head Neck Surg* 2007;136(6):920–927
- 43 Palme CE, Irish JC, Gullane PJ, Katz MR, Devins GM, Bachar G. Quality of life analysis in patients with anterior skull base neoplasms. *Head Neck* 2009;31(10):1326–1334
- 44 Har-El G, Casiano RR. Endoscopic management of anterior skull base tumors. *Otolaryngol Clin North Am* 2005;38(1):133–144, ix
- 45 Diaz EM Jr, Johnigan RH III, Pero C, et al. Olfactory neuroblastoma: the 22-year experience at one comprehensive cancer center. *Head Neck* 2005;27(2):138–149
- 46 O'Connor TA, McLean P, Juillard GJF, Parker RG. Olfactory neuroblastoma. *Cancer* 1989;63(12):2426–2428