




Case Report

Secondary hypophysitis associated with Rathke's cleft cyst resembling a pituitary abscess

Eri Inoue¹, Irfan Kesumayadi^{1,2}, Shingo Fujio^{1,3}, Ryutaro Makino^{1,3}, Tomoko Hanada^{1,3}, Keisuke Masuda¹, Nayuta Higa¹, Shigeru Kawade^{3,4}, Yuichiro Niihara^{3,5}, Hirosuke Takagi⁶, Ikumi Kitazono⁷, Yutaka Takahashi⁸, Ryosuke Hanaya¹

¹Department of Neurosurgery, Kagoshima University, Kagoshima, Japan, ²Department of Neurosurgery, Diponegoro University, Tembalang, Semarang, Indonesia, ³Pituitary Disorders Center, Kagoshima University Hospital, Departments of ⁴Diabetes and Endocrine Medicine, ⁵Obstetrics and Gynecology, ⁶Hematology and Rheumatology, ⁷Pathology, Kagoshima University, Kagoshima, ⁸Department of Diabetes and Endocrinology, Nara Medical University, Kashihara, Nara, Japan.

E-mail: Eri Inoue - ma.mere.loye13@outlook.jp; Irfan Kesumayadi - irfanksy@gmail.com; *Shingo Fujio - ofuji@m2.kufm.kagoshima-u.ac.jp; Ryutaro Makino - 775sen2014@gmail.com; Tomoko Hanada - hanat@m2.kufm.kagoshima-u.ac.jp; Keisuke Masuda - k3717663@kadai.jp; Nayuta Higa - nayuhiga@gmail.com; Shigeru Kawade - fk_ks0926@yahoo.co.jp; Yuichiro Niihara - nyan19860912@icloud.com; Hirosuke Takagi - hrsk.takagi@gmail.com; Ikumi Kitazono - k0400441@kadai.jp; Yutaka Takahashi - takahash@naramed-u.ac.jp; Ryosuke Hanaya - hanaya@m2.kufm.kagoshima-u.ac.jp



*Corresponding author:

Shingo Fujio,
Department of Neurosurgery,
Kagoshima University,
Kagoshima, Japan.

ofuji@m2.kufm.kagoshima-u.ac.jp

Received: 26 November 2023

Accepted: 06 February 2024

Published: 01 March 2024

DOI

10.25259/SNI_947_2023

Quick Response Code:



ABSTRACT

Background: Although rare, cases of hypophysitis resembling a pituitary abscess (PA) have been reported. Differential diagnosis between hypophysitis and PA is crucial as the two diseases require different treatments.

Case Description: A 38-year-old woman with headaches underwent head magnetic resonance imaging (MRI), which revealed an 11-mm mass lesion in the sella turcica. Due to breastfeeding, contrast-enhanced MRI was avoided. Pituitary adenomas and Rathke's cleft cyst (RCC) were suspected, and she was initially treated conservatively. Five months later, she acquired syndrome coronavirus two infections, and while the fever subsided with acetaminophen, the headache persisted. One month later, the headache worsened, followed by fever and diabetes insipidus. MRI revealed a pituitary cystic mass with ring-shaped contrast enhancement on T1-weighted MRI and increased signal intensity on diffusion-weighted imaging (DWI). PA was suspected, and emergency endoscopic transsphenoidal surgery was performed. The microbiological examination of the yellowish-brown content drained from the cystic mass was negative. Microscopically, the cystic lesion was covered with ciliated columnar epithelium and stratified squamous epithelium, with a dense inflammatory cell infiltrate consisting mainly of lymphocytes and plasma cells observed around the cyst. This supported the diagnosis of secondary hypophysitis associated with RCC without PA.

Conclusion: We report a case of hypophysitis secondary to RCC resembling PA with ring-shaped contrast enhancement on MRI and increased signal intensity on DWI. This case emphasizes the need for cautious diagnosis of secondary hypophysitis due to RCC in individuals with MRIs and clinical manifestations resembling an abscess.

Keywords: Coronavirus disease 2019, Hypophysitis, Pituitary abscess, Rathke's cleft cyst

INTRODUCTION

Hypophysitis is characterized by pituitary dysfunction resulting from acute or chronic inflammatory conditions.^[9] Primary hypophysitis is attributed to autoimmune or unidentifiable

This is an open-access article distributed under the terms of the Creative Commons Attribution-Non Commercial-Share Alike 4.0 License, which allows others to remix, transform, and build upon the work non-commercially, as long as the author is credited and the new creations are licensed under the identical terms.

©2024 Published by Scientific Scholar on behalf of Surgical Neurology International

causes, whereas secondary hypophysitis results from factors such as drugs, systemic disease (e.g., immunoglobulin G4-related hypophysitis [IgG4-RH]), infections, or local lesions/neoplasms (e.g., Rathke's cleft cyst [RCC] or pituitary adenoma). Primary hypophysitis can also be categorized based on histological findings, including lymphocytic, granulomatous, xanthomatous, and necrotizing subtypes. The lymphocytic type, characterized by chronic inflammation with lymphocytes and plasma cell infiltrates in the pituitary and hypothalamic infundibulum, is the most common and is often observed in young women during pregnancy and the postpartum period.^[9,39] Clinical presentations of hypophysitis can vary but often include headache, diabetes insipidus, and signs of anterior hypopituitarism. Treatment options for hypophysitis depend on the patient's condition and may involve glucocorticoids, surgery, follow-up, or combined approaches.^[39]

Diagnosing hypophysitis is challenging due to its rarity, affecting only approximately 1 in 9 million individuals per year^[9] and accounting for <0.4% of pituitary surgery cases.^[17] Clinical and imaging presentations can be ambiguous and mimic other conditions. Given these challenges, sharing clinical experiences among clinicians is highly encouraged. In this report, we aim to present a unique case of secondary hypophysitis resulting from an inflamed RCC, exhibiting clinical and radiological findings resembling pituitary abscess (PA). It is also worth mentioning that symptom exacerbation occurred following severe acute respiratory syndrome coronavirus 2 (SARS-CoV-2) infection.

CASE DESCRIPTION

A 38-year-old female patient, who usually suffers from mild headaches, presented with the chief complaint of a sudden severe headache. She was referred to our neurosurgery department after an 11-mm mass lesion was identified in the sella turcica. The patient had given birth one year earlier and was breastfeeding her child. Contrast-enhanced magnetic resonance imaging (MRI) was, therefore, not performed to avoid side effects on infants, as recommended in Japan. Pituitary adenomas and RCC were suspected [Figure 1]. Hydrocortisone (10 mg/day) was prescribed due to low levels of adrenocorticotropic hormone (09:00 h: 5.5 pg/mL, normal range: 7.2–63.3 pg/mL) and cortisol (09:00 h: 4.9 µg/dL, normal range: 7.07–19.6 µg/dL), along with hyper eosinophilia (8.2%), indicating mild adrenal insufficiency. Subsequently, her symptoms of headache improved. An endocrine check-up and contrast-enhanced MRI were scheduled after breastfeeding stopped.

Five months later, after her initial visit to our department, she was infected with SARS-CoV-2, even after receiving the first and second doses of the SARS-CoV-2 vaccine 7 and 6 months earlier, respectively. She had a fever of 38°C and a severe headache that persisted for several days, for which

acetaminophen was prescribed. The fever subsided, but the mild headache persisted. One month later, the patient revisited our department, complaining of a headache that had persisted for five days. Head MRI revealed mild enlargement of the lesion and sphenoid sinus mucosal thickening, leading to the diagnosis of pituitary apoplexy [Figure 2]. The dose of hydrocortisone was increased to 15 mg/day for sick day management, and the patient was monitored. Since then, the patient has experienced persistent headaches and an undulant fever with temperatures varying between 36°C and 39°C for two weeks. In addition, polyuria and polydipsia have begun. An investigation to identify the source of the infection was performed at a local physician's office and our emergency outpatient. The investigation included a polymerase chain reaction test of SARS-CoV-2, a urine test, and a computed tomography scan of the trunk of the body. However, no obvious abnormality was noted. Two days after visiting the emergency outpatient, due to persistent symptoms and having also started vomiting, the patient was reassessed by MRI, revealing a pituitary cystic mass with a ring-shaped contrast enhancement that partially extended into the third ventricle and increased signal intensity on diffusion-weighted imaging (DWI) [Figure 3]. From the symptoms and MRI findings, she was suspected of having a PA, although the inflammatory marker was slightly elevated, with a white blood cell count of 9230/µL and a C-reactive protein level of 1.33 mg/dL. She was in a critical condition, with complaints of severe headache, frequent vomiting, and persistent high fever. To promptly alleviate these symptoms, we decided to perform emergency endoscopic transsphenoidal surgery for drainage on the same day.

Intraoperative findings showed that the sphenoid sinus mucosa was thickened [Figure 4a]. The base of the sella turcica was opened, and the dura was incised to reveal the pituitary gland. When the pituitary gland was incised, a yellowish-brown content was drained [Figure 4b]. The tissue surrounding the cyst was degenerated and sclerotic; fibrous tissue was collected from the cyst margins and near the pituitary stalk [Figure 4c]. After thoroughly lavaging the inside of the cyst, we concluded the surgery. The cultures with a yellowish-brown content were negative for bacteria. Microscopically, the cystic lesion was covered with ciliated columnar epithelium and stratified squamous epithelium, and a dense inflammatory cell infiltrate consisting mainly of lymphocytes and plasma cells were observed around the cyst. A small number of neutrophils and eosinophils were also present. Storiform fibrosis was not observed [Figure 5a-c]. Immunohistochemical analysis showed more than 50 immunoglobulin G4 (IgG4)-positive plasma cells per high-power field and an IgG4/IgG ratio of 30–40%, thus close to fulfilling the histopathological diagnostic criteria for IgG4-RH^[39] [Figure 6]. However, due to the absence of storiform fibrosis in tissue, any other lesions in the body suggestive of

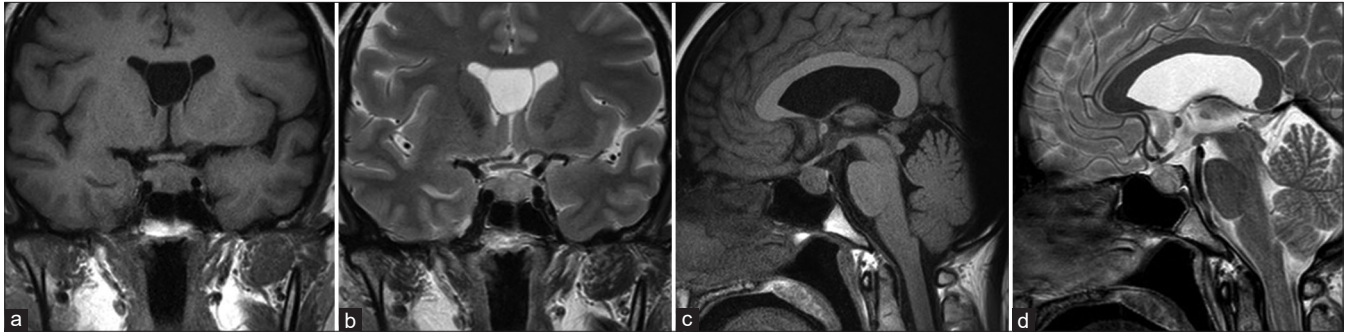


Figure 1: A magnetic resonance imaging finding at the initial visit showed an 11-mm mass lesion in the sella turcica. (a) Coronal T1- and (b) T2-weighted images, along with (c) sagittal T1- and (d) T2-weighted images.

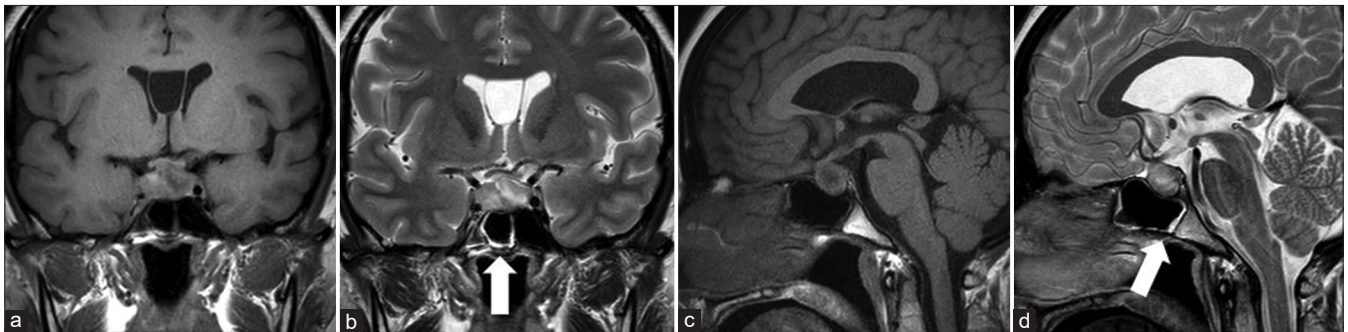


Figure 2: Magnetic resonance imaging findings when the headache worsened showed growth in tumor size. (a) Coronal T1- and (b) T2-weighted images, along with (c) sagittal T1- and (d) T2-weighted images showed a mixture of hypointense and hyperintense signals. Mucosal thickening was observed in the sphenoid sinus (arrows in b and d).

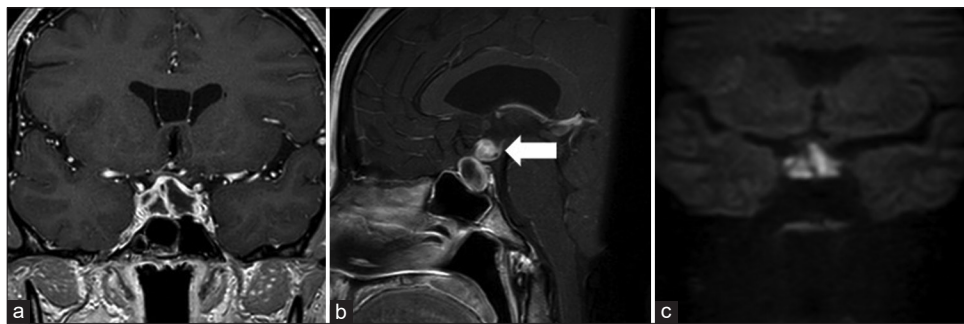


Figure 3: Magnetic resonance imaging findings at the time of fever: (a) coronal; (b) sagittal contrast-enhanced T1-weighted images revealed a ring-shaped contrast enhancement that partially extended into the third ventricle (arrow in b); and (c) coronal diffusion-weighted imaging showed a high signal intensity.

IgG4-related disease, and a normal preoperative serum IgG4 level (65.7 mg/dL, reference range 11–121 mg/dL), a final diagnosis of hypophysitis secondary to RCC was made. The bacterial culture of cyst content was negative, and a small number of neutrophils were observed in the tissue, which ruled out PA. Consequently, antibiotics were administered at routine doses, including an intravenous bolus of 1 g of cefazolin once intraoperatively and five times every eight hours postoperatively, followed by oral clarithromycin at 400 mg/day for ten days for sinusitis prophylaxis.

The headache and fever quickly subsided after surgery. The patient was prescribed prednisolone (45 mg/day) immediately after the diagnosis, and the lesions shrank promptly [Figure 7]. Over one year, the prednisolone effects gradually tapered off until it was discontinued, and there was no recurrence of hypophysitis. However, central hypothyroidism, central hypogonadism, and diabetes insipidus persisted. A growth hormone (GH)-releasing peptide-2 test 3 months after surgery revealed severe GH deficiency (peak GH: 5.6 ng/mL, whereas the normal value is

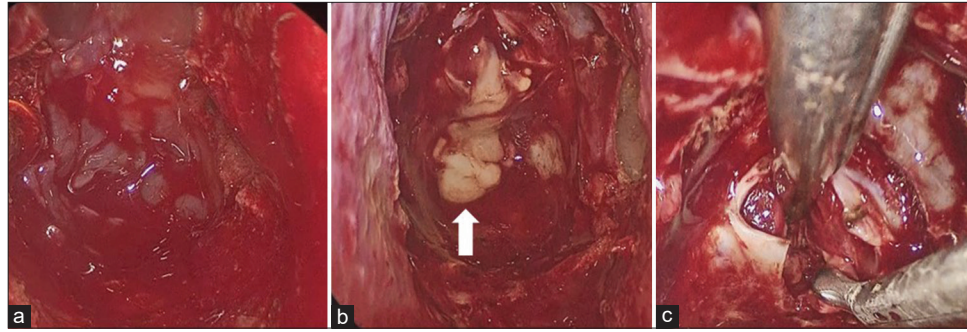


Figure 4: Intraoperative findings of the patient: (a) the sphenoid sinus mucosa was thickened. (b) When the thickened pituitary gland was incised, a yellowish-brown content was drained (arrow). (c) We biopsied the fibrous marginal tissue.

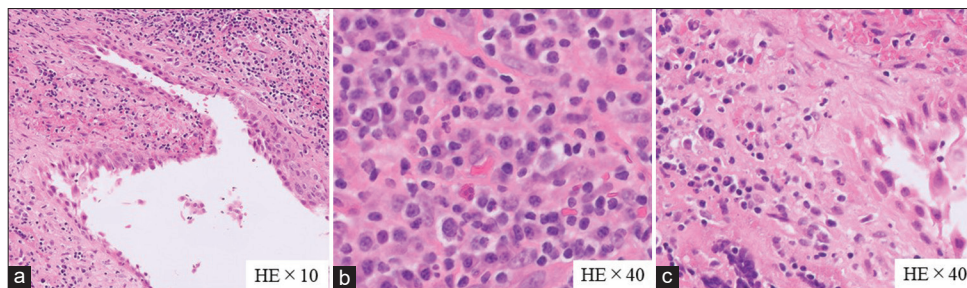


Figure 5: Microscopic findings. (a) A cystic lesion was covered with ciliated columnar and stratified squamous epithelium. (b) The surrounding cyst showed inflammatory cells infiltrate, mainly consisting of lymphocytes and plasma cells with a few eosinophils and (c) neutrophils.

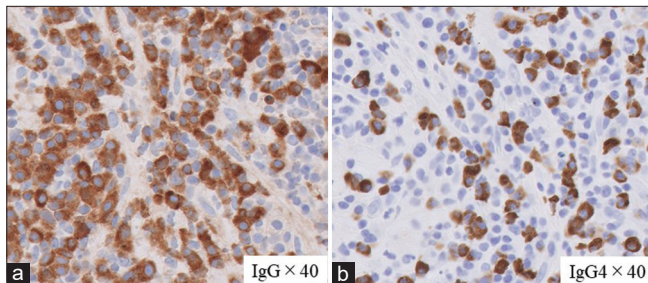


Figure 6: Immunostaining findings of the patient: (a) immunoglobulin (IgG) and (b) IgG4. The IgG4-positive plasma cells were 50/high-powered field or higher, and the IgG4/IgG-positive cell ratio was approximately 30–40%.

above 9.0 ng/mL), and GH replacement therapy was started a year and a half after the surgery.

DISCUSSION

Our report describes a case of hypophysitis secondary to RCC, with clinical manifestations and MRI findings resembling PA. Along with other pituitary diseases, the incidence of PA is <1% and is associated with a high mortality rate.^[15,23] The most frequent clinical signs of PA are headache, hypopituitarism, and diabetes insipidus.^[23] In addition, fever is a characteristic symptom of PA.^[11,23,40]

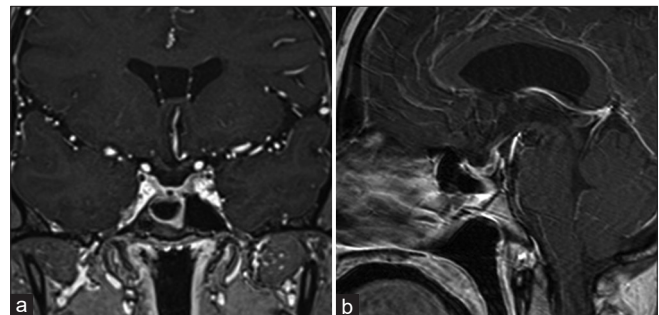


Figure 7: A magnetic resonance imaging finding three months after surgery: (a) coronal and (b) sagittal sections of contrast-enhanced T1-weighted images. The cystic lesions and mass in the sella turcica disappeared.

Draining the abscess and administering adequate antibiotics are the two primary aspects of PA therapy. Typical imaging findings include a cystic mass in the sellar region with rim enhancement after gadolinium injection on MRI^[11,23] and an increased signal intensity on DWI.^[40] Ring-shaped contrast enhancement is also a possible finding of secondary hypophysitis due to RCC.^[14,16,30,44] Visual disturbance, headache, and polyuria are typical symptoms of secondary hypophysitis due to RCC;^[14,16,30,44] however, high fever is rare. Our patient had a severe headache, fever, and polyuria, with an MRI showing a cystic sellar mass and ring-shaped

contrast enhancement, as well as an increased signal on DWI, consistent with PA.

We reviewed cases of RCC reported to be suspected of PA [Table 1].^[3,8,10,12,13,19,20,22,24,26,29,33,36,38,41-43] Of the 65 cases, 38 naïve cases with no history of pituitary surgery are shown in Table 2. The symptoms with the highest incidence were pituitary dysfunction (33/38), visual field disturbance (17/38), and headache (12/38), whereas fever (5/38) was less common. Of the 38 cases, 17 had negative abscess cultures. Fourteen of the 17 patients with negative abscess cultures had pituitary dysfunction, and two patients had fever. This frequency did not differ from that of cases in which the causal organism was known. Eight of the 17 patients with negative abscess cultures were not treated with antibiotics, and recurrence did not occur in any patient. Although no imaging information was available for those cases, we suspect that they could have included secondary hypophysitis resembling PA, like in our case, because PA is unlikely to be cured without antibiotics. Since hypophysitis is treated primarily with glucocorticoids, whereas PA is treated primarily with antibiotics, the two presentations require conflicting treatments. Therefore, the diagnosis of secondary hypophysitis due to RCC should be made with caution for those with abscess-like MR images and clinical manifestations.

Contrast-enhanced MRI was not performed during the initial examination, considering the patient was breastfeeding. If the contrast MRI had been performed and rim contrast enhancement had been discovered earlier, it would have been useful for aiding the diagnosis. However, given that the headache symptoms improve spontaneously, the therapy administered will remain conservative, with follow-up conducted accordingly. In this case, pathology revealed infiltration of lymphocytes and plasma cells into the anterior pituitary gland, with immunostaining showing massive IgG4-positive cells, mimicking IgG4-RH. In accordance with our case, the previous studies have shown that clusters of IgG4-positive plasmacytes may sometimes be observed in secondary hypophysitis and granulomatosis,^[6,31] indicating that clusters of IgG4-positive plasmacytes are nonspecific findings for IgG4-RH. A typical MRI result for IgG4-RH is an enlarged pituitary stalk or gland that is homogeneously enhanced,^[1,7] whereas ring-shaped contrast enhancement is a possible finding of secondary hypophysitis due to RCC.^[14,16,30,44] According to epidemiological data, most cases of IgG4-RH are represented by middle-aged and older males. Moreover, IgG4-RH is often associated with manifestations in other systemic organs.^[37] These features help differentiate between secondary hypophysitis associated with RCC and IgG4-RH.

It is unclear what caused hypophysitis in this patient. It might be related to a SARS-CoV-2 infection encountered a month before symptom exacerbation since hypophysitis as

Table 1: A series of RCCs resembling pituitary abscesses.

No	Articles	Sex/age	Symptoms	Imaging (peripheral rim/ring contrast enhancement)	Preoperative pituitary function	Microorganism	Antibiotics	Post-operative pituitary function	Recurrence
1	Obenchain and Becker (1972) ^[33]	F/50	HE, FEV, VD	Yes, CT	HYP	S.ep	PEN, INH, Ethambutol	HYP	Yes
2	Sonntag et al. (1983) ^[36]	M/39	HE, FEV, VD	Yes, CT	HPro	Gram stain: Gram-negative rods, Culture: Sterile	CML	Normal	Yes
3	Bognar et al. (1992) ^[8]	F/33	VD, DI, Amenorrhea	Yes, CT	DI, HYP	S.au, <i>Streptococcus pyogenes</i>	Yes	DI, HYP	Yes
4	Sato et al. (1995) ^[36]	F/53 M/67	DI Fatigue	Yes, CT Yes, MRI and CT	DI DI	Sterile Sterile	Yes Yes	DI HYP	No No
5	Jain et al. (1997) ^[20]	M/42	VD	Yes, CT	HYP	Sterile	NA	NA	Yes
6	Israel et al. (2000) ^[19]	F/13	VD	Yes, MRI	Normal	<i>Acinetobacter Iwoffii</i>	CRO	DI	Yes
7	Celikoglu et al. (2006) ^[10]	F/48 F/37	VD VD, Amenorrhea, Galactorrhea	Yes, MRI Yes, MRI	HPro HPro	Sterile Sterile	VAN, CRO, MET VAN, CRO, MET	Normal Normal	No Yes

(Contd...)

Table 1: (Continued).

No	Articles	Sex/ age	Symptoms	Imaging (peripheral rim/ring contrast enhancement)	Preoperative pituitary function	Microorganism	Antibiotics	Post-operative pituitary function	Recurrence
8	Komatsu <i>et al.</i> (2010) ²²¹	F/66	HE, FEV, Drowsiness, VD	NA	Normal	β-hemolytic <i>streptococcus</i>	NA	Normal	No
9	Tate <i>et al.</i> (2010) ⁴¹¹	M/60 F/20 F/20	DI Vomiting Amenorrhea, HPro	NA NA NA	DI HYP HPro	Sterile S.au, P.a, S.ep Sterile	No CRO CRO, MET	NA NA NA	No No No
		M/66 M/29 F/51 F/24 F/32	Obtundation HYP HE HPro DI	NA NA NA NA NA	HYP HYP Normal HPro HYP	Sterile Pa Sterile Sterile S.ep, Aspergillus fumigatus	No CRO No No NAF, Voriconazole	DI DI NA NA NA	No No No No No
		F/51 F/49 M/40 F/32 F/75 F/53 M/80 M/64	VD DI HYP HYP VD DI HE HYP	NA NA NA NA NA NA NA NA	HYP HYP HYP HYP HYP HYP HYP HYP	S.au, P.a, S.ep Pa S.ep Sterile Sterile Sterile S.ep, P.a MRSA, S.ep, Pepto <i>streptococcus</i> , P.a	NAF CRO PEN, Bactrim No No No VAN VAN	NA NA NA DI NA NA NA NA	No Yes No No No No No No
10	Uchiyama <i>et al.</i> (2011) ⁴³¹	F/50 F/48 F/45	VD VD DI	NA NA NA	HYP HYP HYP	S.ep Sterile Pa	NAF No VAN	NA NA NA	No No No
11	Mrelashvili <i>et al.</i> (2014) ²⁶¹	F/12	HE, FEV	Yes, MRI	Normal	Sterile	CRO, Meropenem	DI	Yes
12	Naama <i>et al.</i> (2014) ²⁹¹	M/45 F/64	HE, FEV HE, VD	Yes, MRI Yes, MRI	NA HYP	Sterile Gram stain: Gram-positive cocci	NA CRO, MET	NA HYP	No No
13	Coulter <i>et al.</i> (2014) ¹³¹	M/66	VD	No, MRI, DWI hyperintense	HYP	S.au	Flucloxacillin and fusidic acid	NA	No
14	Tsuda <i>et al.</i> (2018) ⁴²¹	F/80	HE	Yes, MRI, DWI hyperintense	Normal	Sterile	Yes	Normal	No

(Contd...)

Table 1: (Continued).

No	Articles	Sex/ age	Symptoms	Imaging (peripheral rim/ring contrast enhancement)	Preoperative pituitary function	Microorganism	Antibiotics	Post-operative pituitary function	Recurrence
15	Aranda et al. (2021) ^[3]	F/17	HE	Yes, MRI	HPPro, HYP	S.au, S.ep	CLX	NA	Yes
16	Coulden et al. (2022) ^[12]	M/31	VD HE, VD	Yes, MRI Yes, MRI	Hypothyroidism HH, HPPro	S.au, S.ep S.au	CLX CRO	NA HYP	No No
17	Lodha et al. (2022) ^[24]	F/21	HE, VD	Yes, MRI	HYP	S.ep	Yes	HYP	No
18	Present case	F/36	HE, FEV, DI	Yes, MRI, DWI hyperintense	ACTH deficiency, DI	Sterile	No (Postoperative routine only)	DI, HYP	No

RCCs: Rathke cleft cysts, F: Female, M: Male, HE: Headache, VD: Visual disturbance, FEV: Fever, DI: Diabetes insipidus, HYP: Hypopituitarism, HPPro: Hyperprolactinemia, HH: Hypogonadotropic hypogonadism, MRI: Magnetic resonance imaging, CT: Computed tomography, DWI: Diffusion-weighted imaging, S.ep: *Staphylococcus epidermidis*, S.au: *Staphylococcus aureus*, MRSA: Methicillin-resistant *Staphylococcus aureus*, Pa: *Propionibacterium acnes*, VAN: Vancomycin, CRO: Ceftriaxone, MET: Metronidazole, PEN: Penicillin, INH: Isoniazid, CLX: Cloxacillin, NAF: Nafcillin, CML: Chloramphenicol, NA: Not available, ACTH: Adrenocorticotropic hormone

Table 2: Result of review cases.

Variables	Cases n (%)
Review cases	
History of pituitary surgery	27 (41.5)
Naïve case	38 (58.5)
Symptoms of naïve case	
Pituitary dysfunction	33 (86.8)
Visual field disturbance	17 (44.7)
Headache	12 (31.6)
Fever	5 (13.2)
Microbiological examination of naïve case	
Positive culture	21 (55.3)
Negative culture	17 (44.7)
Symptoms of naïve cases with negative culture	
Pituitary dysfunction	14 (82.4)
Fever	2 (11.8)
Antimicrobial use of naïve cases with negative culture	
Antibiotics	9 (52.9)
No antibiotics	8 (47.1)

a sequela of coronavirus disease 2019 has been reported in five cases.^[18,21,25,32,45] Hypophysitis has also been reported in post-SARS-CoV-2 vaccination in three cases;^[2,27,28] However, it is important to note that the symptoms exacerbation of this patient occurred seven months after the second vaccination. Similar to our patient, these cases related to SARS-CoV-2 infection and vaccination presented with headaches and hormonal disturbances, pituitary stalk thickening, and pituitary gland enlargement on imaging, and they responded well to steroid treatment.^[2,18,21,25,27,28,32,45] There is no conclusive evidence yet showing that either SARS-CoV-2 infection or vaccination causes hypophysitis. However, the authors have hypothesized that SARS-CoV-2 might directly invade the central nervous system through the cribriform plate or by hematogenous dissemination.^[5] The hypothalamus and pituitary gland have also been reported to express the angiotensin-converting enzyme two receptor, indicating that they are susceptible to SARS-CoV-2 infection.^[34] Another plausible mechanism is that SARS-CoV-2 infection and vaccine could induce acute cytokine release,^[2,35] potentially leading to endocrinopathy.^[4]

CONCLUSION

We report a case of hypophysitis secondary to RCC with clinical and imaging findings similar to PA. The patient presented with severe headache, fever, and diabetes insipidus. The MRI showed ring-shaped contrast enhancement accompanied by increased signal intensity on DWI. Microbiological examination, however, was negative; pathological findings showed a cystic lesion covered with ciliated columnar epithelium and stratified squamous epithelium. Together, these findings support the diagnosis of

hypophysitis secondary to RCC. This case highlights that the diagnosis of hypophysitis secondary to RCC and PA should be made with caution, as both require conflicting treatments.

Ethical approval

The Institutional Review Board approval is not required.

Declaration of patient consent

The authors certify that they have obtained all appropriate patient consent.

Financial support and sponsorship

Nil.

Conflicts of interest

There are no conflicts of interest.

Use of artificial intelligence (AI)-assisted technology for manuscript preparation

The authors confirm that there was no use of artificial intelligence (AI)-assisted technology for assisting in the writing or editing of the manuscript and no images were manipulated using AI.

REFERENCES

- AbdelRazek MA, Venna N, Stone JH. IgG4-related disease of the central and peripheral nervous systems. *Lancet Neurol* 2018;17:183-92.
- Ankireddypalli AR, Chow LS, Radulescu A, Kawakami Y, Araki T. A case of hypophysitis associated with sARS-CoV-2 vaccination. *AACE Clin Case Rep* 2022;8:204-9.
- Aranda F, García R, Guarda FJ, Nilo F, Cruz JP, Callejas C, *et al.* Rathke's cleft cyst infections and pituitary abscesses: Case series and review of the literature. *Pituitary* 2021;24:374-83.
- Arzt E, Pereda MP, Castro CP, Pagotto U, Renner U, Stalla GK. Pathophysiological role of the cytokine network in the anterior pituitary gland. *Front Neuroendocrinol* 1999;20:71-95.
- Baig AM, Khaleeq A, Ali U, Syeda H. Evidence of the COVID-19 virus targeting the CNS: Tissue distribution, host-virus interaction, and proposed neurotropic mechanisms. *ACS Chem Neurosci* 2020;11:995-8.
- Bando H, Iguchi G, Fukuoka H, Taniguchi M, Kawano S, Saitoh M, *et al.* A diagnostic pitfall in IgG4-related hypophysitis: Infiltration of IgG4-positive cells in the pituitary of granulomatosis with polyangiitis. *Pituitary* 2015;18:722-30.
- Bando H, Iguchi G, Fukuoka H, Taniguchi M, Yamamoto M, Matsumoto R, *et al.* The prevalence of IgG4-related hypophysitis in 170 consecutive patients with hypopituitarism and/or central diabetes insipidus and review of the literature. *Eur J Endocrinol* 2013;170:161-72.
- Bognár L, Szeifert GT, Fedorcsák I, Pásztor E. Abscess formation in Rathke's cleft cyst. *Acta Neurochir (Wien)* 1992;117:70-2.
- Caturegli P, Newschaffer C, Olivi A, Pomper MG, Burger PC, Rose NR. Autoimmune hypophysitis. *Endocr Rev* 2005;26:599-614.
- Celikoglu E, Boran BO, Bozbuga M. Abscess formation in Rathke's cleft cyst. *Neurol India* 2006;54:213-4.
- Ciappetta P, Calace A, D'Urso PI, De Candia N. Endoscopic treatment of pituitary abscess: Two case reports and literature review. *Neurosurg Rev* 2008;31:237-46.
- Coulden A, Pepper J, Juszcak A, Batra R, Chavda S, Senthil L, *et al.* Rathke's cleft cyst abscess with a very unusual course. *Asian J Neurosurg* 2022;17:527-31.
- Coulter IC, Mahmood S, Scoones D, Bradey N, Kane PJ. Abscess formation within a Rathke's cleft cyst. *J Surg Case Rep* 2014;2014:rju105.
- Daikokuya H, Inoue Y, Nemoto Y, Tashiro T, Shakudo M, Ohata K. Rathke's cleft cyst associated with hypophysitis: MRI. *Neuroradiology* 2000;42:532-4.
- Dalan R, Leow MK. Pituitary abscess: Our experience with a case and a review of the literature. *Pituitary* 2008;11:299-306.
- Deguchi-Horiuchi H, Koide H, Sakuma I, Gao Y, Higuchi S, Nagano H, *et al.* Two cases of symptomatic secondary hypophysitis due to Rathke's cleft cysts treated with glucocorticoids: Long-term follow-up. *Endocr J* 2021;68:269-79.
- Faje A. Hypophysitis: Evaluation and management. *Clin Diabetes Endocrinol* 2016;2:15.
- Gorbova NY, Vladimirova VP, Rozhinskaya LY, Belaya ZY. Hypophysitis and reversible hypopituitarism developed after COVID-19 infection - a clinical case report. *Probl Endokrinol (Mosk)* 2022;68:50-6.
- Israel ZH, Yacoub M, Gomori JM, Dotan S, Fellig Y, Shoshan Y, *et al.* Rathke's cleft cyst abscess. *Pediatr Neurosurg* 2000;33:159-61.
- Jain KC, Varma A, Mahapatra AK. Pituitary abscess: A series of six cases. *Br J Neurosurg* 1997;11:139-43.
- Joshi M, Gunawardena S, Goenka A, Ey E, Kumar G. Post COVID-19 lymphocytic hypophysitis: A rare presentation. *Child Neurol Open* 2022;9:2329048X221103051.
- Komatsu F, Tsugu H, Komatsu M, Sakamoto S, Oshiro S, Fukushima T, *et al.* Clinicopathological characteristics in patients presenting with acute onset of symptoms caused by Rathke's cleft cysts. *Acta Neurochir (Wien)* 2010;152:1673-8.
- Liu F, Li G, Yao Y, Yang Y, Ma W, Li Y, *et al.* Diagnosis and management of pituitary abscess: Experiences from 33 cases. *Clin Endocrinol (Oxf)* 2011;74:79-88.
- Lodha P, Srinivas PR, Danda VS, Rao GP. Rathke's cleft cyst abscess-an unusual guest in the sella. *Indian J Neurosurg* 2022;11:73-5.
- Misgar RA, Rasool A, Wani AI, Bashir MI. Central diabetes insipidus (Infundibuloneuro hypophysitis): A late complication of COVID-19 infection. *J Endocrinol Invest* 2021;44:2855-6.
- Mrelashvili A, Braksick SA, Murphy LL, Morparia NP, Natt N, Kumar N. Chemical meningitis: A rare presentation of Rathke's cleft cyst. *J Clin Neurosci* 2014;21:692-4.
- Mungmunpantipantip R, Wiwanitkit V. Pituitary apoplexy and COVID-19 vaccination. *Med Clin (Engl Ed)* 2022;159:e11.
- Murvelashvili N, Tessnow A. A case of hypophysitis

- following immunization with the mRNA-1273 SARS-CoV-2 vaccine. *J Investig Med High Impact Case Rep* 2021;9:23247096211043386.
29. Naama O, Gazzaz M, Boulahroud O, Elmoustarchid B. Infection of a Rathke cleft cyst: A rare cause of pituitary abscess. *Surg Infect (Larchmt)* 2014;15:358-60.
 30. Nishikawa T, Takahashi JA, Shimatsu A, Hashimoto N. Hypophysitis caused by Rathke's cleft cyst. Case report. *Neurol Med Chir (Tokyo)* 2007;47:136-9.
 31. Nishioka H, Shibuya M, Haraoka J. Immunohistochemical study for IgG4-positive plasmacytes in pituitary inflammatory lesions. *Endocr Pathol* 2010;21:236-41.
 32. Nonglait PL, Naik R, Raizada N. Hypophysitis after COVID-19 infection. *Indian J Endocrinol Metab* 2021;25:255-6.
 33. Obenchain TG, Becker DP. Abscess formation in a Rathke's cleft cyst. Case report. *J Neurosurg* 1972;36:359-62.
 34. Pal R, Banerjee M. COVID-19 and the endocrine system: Exploring the unexplored. *J Endocrinol Invest* 2020;43:1027-31.
 35. Que Y, Hu C, Wan K, Hu P, Wang R, Luo J, *et al.* Cytokine release syndrome in COVID-19: A major mechanism of morbidity and mortality. *Int Rev Immunol* 2022;41:217-30.
 36. Sato M, Matsushima Y, Taguchi J, Matsumoto S, Tatsumi C, Ozaki M, *et al.* A case of pituitary abscess caused by infection of Rathke's cleft cyst. *No Shinkei Geka* 1995;23:991-5. (In Japanese)
 37. Shimatsu A, Oki Y, Fujisawa I, Sano T. Pituitary and stalk lesions (infundibulo-hypophysitis) associated with immunoglobulin G4-related systemic disease: An emerging clinical entity. *Endocr J* 2009;56:1033-41.
 38. Sonntag VK, Plenge KL, Balis MS, Raudzens PA, Hodak JA, Clark RJ, *et al.* Surgical treatment of an abscess in a Rathke's cleft cyst. *Surg Neurol* 1983;20:152-6.
 39. Takagi H, Iwama S, Sugimura Y, Takahashi Y, Oki Y, Akamizu T, *et al.* Diagnosis and treatment of autoimmune and IgG4-related hypophysitis: Clinical guidelines of the Japan Endocrine Society. *Endocr J* 2020;67:373-8.
 40. Takayasu T, Yamasaki F, Tominaga A, Hidaka T, Arita K, Kurisu K. A pituitary abscess showing high signal intensity on diffusion-weighted imaging. *Neurosurg Rev* 2006;29:246-8.
 41. Tate MC, Jahangiri A, Blevins L, Kunwar S, Aghi MK. Infected Rathke cleft cysts: Distinguishing factors and factors predicting recurrence. *Neurosurgery* 2010;67:762-9.
 42. Tsuda Y, Oguri T, Sakurai K, Watanabe T, Maeda N, Yuasa H. Intracellular xanthogranuloma with abscess formation in a patient with Rathke's cleft cyst. *Rinsho Shinkeigaku* 2018;58:411-3. (In Japanese)
 43. Uchiyama T, Sakai K, Asanuma M, Aoyama T, Hongo K. Pituitary abscess manifesting as meningitis and photophobia associated with Rathke's cleft cyst in a child. Case report. *Neurol Med Chir (Tokyo)* 2011;51:455-9.
 44. Yang C, Wu H, Bao X, Wang R. Lymphocytic hypophysitis secondary to ruptured Rathke's cleft cyst: Case report and literature review. *World Neurosurg* 2018;114:172-7.
 45. Zerrouki D, Assarrar I, Rami I, Rouf S, Latrech H. Coronavirus as a trigger of lymphocytic hypophysitis in an adolescent girl: An exceptional case report. *Int J Surg Case Rep* 2024;115:109218.

How to cite this article: Inoue E, Kesumayadi I, Fujio S, Makino R, Hanada T, Masuda K, *et al.* Secondary hypophysitis associated with Rathke's cleft cyst resembling a pituitary abscess. *Surg Neurol Int.* 2024;15:69. doi: 10.25259/SNI_947_2023

Disclaimer

The views and opinions expressed in this article are those of the authors and do not necessarily reflect the official policy or position of the Journal or its management. The information contained in this article should not be considered to be medical advice; patients should consult their own physicians for advice as to their specific medical needs.